

BIOLOGY
LIBRARY
G

ATLAS

OF

HISTOLOGY

ATLAS

OF

HISTOLOGY

BY

E. KLEIN, M.D., F.R.S.

LECTURER ON HISTOLOGY AT ST BARTHOLOMEW'S HOSPITAL MEDICAL SCHOOL

and

E. NOBLE SMITH, L.R.C.P., M.R.C.S.

FORMERLY SENIOR HOUSE-SURGEON TO ST MARY'S HOSPITAL

WITH FORTY-EIGHT COLOURED PLATES

THE ILLUSTRATIONS BY MR NOBLE SMITH FROM PREPARATIONS BY DR KLEIN

THE TEXT BY DR KLEIN

REESE LIBRARY OF THE UNIVERSITY OF CALIFORNIA.

LONDON

SMITH, ELDER, & CO., 15 WATERLOO PLACE

1880

[*All rights reserved*]

+QM551
K59
BIOLOGY
LIBRARY
G

21357

PREFACE.

THIS WORK is intended to be a pictorial and literal representation of the structure of the tissues of Man and other Vertebrates; its chief aim being to teach, not so much the history of histology as histology itself in its modern aspect. The subject is divided into chapters, each receiving its separate and due share of illustrations and text.

The Illustrations are drawn and executed by Mr. E. NOBLE SMITH. They are coloured and uncoloured. The first represent specimens stained with different dyes, to be specially mentioned in the explanation of the respective figures. Except, when a figure is rendered in an uniform purplish tint, it will be understood to represent a specimen stained with hæmatoxylin; and likewise, when a figure appears of an uniform pink colour, the corresponding specimen is stained with carmine. The uncoloured figures are taken either from fresh or unstained specimens, or—as is the case in a very few instances specially indicated in the respective places—are borrowed from other authors.

The Text comprises, besides the explanation of the illustrations themselves, a good deal of other matter that either need not be specially illustrated, being intelligible by means of the given figures, or that cannot be done so if the work is to be kept within a reasonable limit.

The subject-matter will be treated in this order: first, the elementary tissues—blood, epithelium, and endothelium, connective-tissues, muscular

tissue, the nervous, vascular, and lymphatic system; then follows a short chapter on 'Cells in general,' after which the compound tissues will be considered seriatim; the alimentary canal and its glands, the respiratory organs, the urinary and genital organs, the skin and special sense organs. The concluding chapter treats of organs the nature of which is not sufficiently well known, as the suprarenal capsule, the thyroid and coccygeal gland.

E. KLEIN.

CONTENTS.

CHAPTER		PAGE
I.	BLOOD	1
	1. Colourless Blood Corpuscles	1
	2. Coloured Blood Corpuscles	5
	Blood Crystals	9
II.	EPITHELIUM	11
III.	ENDOTHELIUM	19
IV.	CONNECTIVE-TISSUE CORPUSCLES	26
V.	FIBROUS-CONNECTIVE TISSUE	35
	Elastic Tissue	36
	Gelatinous Tissue	38
	Development of Connective Tissue	39
VI.	ADIPOSE TISSUE	42
VII.	PIGMENT CELLS	45
VIII.	CARTILAGE	48
	A. Hyaline Cartilage	48
	B. Fibrous Cartilage	50
	C. Reticular Cartilage	51
IX.	BONE TISSUE	55
	Endochondral Bone	61
	Intermembranous Bone	64
X.	UNSTRIPED MUSCLE	73
XI.	STRIPED MUSCLE FIBRES	75
XII.	CEREBRO-SPINAL NERVES	84
XIII.	THE SPINAL CORD	91
	The Membranes	91
	A. The Framework	93
	B. The White Matter	94
	C. The Grey Matter	95
XIV.	THE OPTIC NERVE	99

CHAPTER		PAGE
XV.	THE BRAIN	105
	The Membranes	105
	The Brain Substance	106
	A. The Framework	106
	B. The White Matter	107
	C. The Grey Matter	108
	The Cerebellum	111
XVI.	CEREBRO-SPINAL GANGLIA	114
XVII.	THE SYMPATHETIC SYSTEM	118
	A. The Sympathetic Nerve Fibres	118
	B. The Sympathetic Ganglia	119
XVIII.	PERIPHERAL DISTRIBUTION OF NERVES	124
	Special Terminal Organs	127
	A. Pacinian Corpuscles	127
	B. Endbulbs of the Conjunctiva	129
	C. The Endbulbs of the Genital Organs	129
	D. The End-Organs of the Beak and Tongue of Birds	130
	E. Touch-Cells	130
	F. Termination in Muscle	131
	G. Termination in Tendon	133
	H. Termination in Blood-Vessels	134
XIX.	BLOOD-VESSELS	137
	1. Capillary Blood-Vessels	137
	2. Arteries	138
	3. Veins	142
	4. Development of Blood-Vessels	145
	5. The Heart	147

CHAPTER		PAGE
XX.	LYMPHATIC GLANDS	154
	A. Compound Lymphatic Glands	154
	B. Simple Lymphatic Glands	158
XXI.	THE THYMUS	165
	A. The Framework	165
	B. The Gland Substance	165
XXII.	LYMPHATIC VESSELS	168
XXIII.	TEETH, STRUCTURE OF	181
	Development	184
XXIV.	SALIVARY GLANDS	188
XXV.		
	1. Mouth and Palate	194
	2. The Tongue	197
	3. The Pharynx	201
	4. The Œsophagus	201
	5. The Stomach	203
XXVI.	THE SMALL AND LARGE INTESTINE	215
	A. The Small Intestine	215
	B. The Large Intestine	222
XXVII.	THE PANCREAS	224
XXVIII.	THE LIVER	227
XXIX.	THE LARYNX AND TRACHEA, BRONCHI AND LUNG	236
	1. The Larynx	236
	2. The Trachea	239
	3. The Bronchi	241
	4. The Lung	242
XXX.	THE URINARY ORGANS	251
	The Kidney	251
	The Ureter and Bladder	263
XXXI.	THE MALE GENITAL ORGANS	268
	Testis and Epididymis	268
	Vas Deferens and Vesiculæ Seminales	277
	The Prostate Gland	278
	The Urethra	279
	Corpora Cavernosa	280
XXXII.	THE FEMALE GENITAL ORGANS	285
	The Ovary	285
	Development of Grafian Follicles	291
	The Oviduct	293
	The Uterus	294
	The Vagina	298
	The Urethra	299
	The Nymphæ, Clitoris, and Vestibulum	300
	The Mammary Gland	300
XXXIII.	THE SKIN	307
	The Epidermis	307
	The Corium	311
	The Sweat Glands	313
	The Hair Follicle and Hair	317
	The Sebaceous Gland	322
	The Muscle of the Hair	323
	The Nails	327
	The Blood-Vessels	329
	The Lymphatic System	330
	The Nerves	332
XXXIV.	THE EYELIDS AND CONJUNCTIVA	335
	The Lachrymal Glands	340
XXXV.	THE CORNEA AND SCLEROTIC	342
	The Cornea	342
	The Sclerotic	348
XXXVI.	THE IRIS, CILIARY PROCESSES, AND CHORIOIDEA	351
	1. The Iris	351
	2. The Ciliary Processes	353
	3. The Chorioidea	354
XXXVII.	THE LENS AND VITREOUS BODY	356
XXXVIII.	THE RETINA	360
	1. The Uvea	360
	2. The Rods and Cones	361
	3. The Limitans Externa	364
	4. The Outer Nuclear Layer	365
	5. The Outer Molecular Layer	367
	6. The Inner Nuclear Layer	367
	7. The Inner Molecular Layer	368
	8. The Layer of Ganglion Cells	369
	9. The Layer of Nerve Fibres	369
	10. The Limitans Interna	370
	11. The Macula Lutea and Fovea Centralis	371
	12. The Ora Serrata	372
	13. The Blood-Vessels	372
	14. The Lymphatics	372
	15. The Lamina Cribrosa	373

CHAPTER		PAGE
XXXIX.	THE OUTER AND MIDDLE EAR	389
	The Membrana Tympani	389
	The Tuba Eustachii	390
	The Cavum Tympani	391
XL.	THE INTERNAL EAR	393
	The Utricle, Saccule and the Semicircular Canals	393
	The Cochlea	396
	The Membrane of Reissner	398
	The Ligamentum Spirale	399
	The Membrana Basilaris	400
	The Organ of Corti	401
	The Lamina Reticularis	404
	The Crista Spiralis	405
	The Membrana Tectoria	406
XLI.	THE NASAL MUCOUS MEMBRANE	409
	The Olfactory Organ	411
	The Organ of Jacobson	415
XLII.	THE SPLEEN	423
XLIII.	THE DUCTLESS GLANDS	431
	1. The Hypophysis Cerebri	431
	2. The Thyroid Gland	432
	3. The Suprarenal Body	435
	4. The Glandula Coccygea and Carotica	438
XLIV.	THE INDIRECT DIVISION OF NUCLEI	439

LIST OF PLATES.

PLATE			PAGE
I.	Figures I.–VII.	Colourless Blood Corpuscles	Description on 2
	Figures VIII.–X.	Coloured Blood Corpuscles	
II.	Figures XI.–XVI.	Coloured Blood Corpuscles	„ „ 7
	Figures XVII.–XXI.	Blood Crystals	
III.	Figures I.–VIIIB.	Epithelium	„ „ 14
IV.	Figures IX.–XVIII.	Epithelium	„ „ 16
V.	Figures I.–VII.	Endothelium	„ „ 22
VI.	Figures VIII.–XIII.	Endothelium	„ „ 24
VII.	Figures I.–VII.	Connective-Tissue Corpuscles	„ „ 29
VIII.	Figures VIII.–XV.	Connective-Tissue Corpuscles	„ „ 32
IX.	Figures XVI.–XXII.	Connective Tissue	„ „ 40
X.	Figures I.–III.	Fat-Cells	„ „ 46
	Figures IV.–V.	Pigment Cells	
XI.	Figures I.–VIII.	Cartilage	„ „ 52
XII.	Figures I.–IV.	Bone	„ „ 67
XIII.	Figures V.–VIII.	Bone	„ „ 69
XIV.	Figures IX.–XIII.	Bone	„ „ 71
XV.	Figures I.–V.	Unstriped Muscle	„ „ 81
	Figures VI.–VIII.	Striped Muscle	
XVI.	Figures IX.–XVI.	Striped Muscle	„ „ 82
XVII.	Figures I.–VI.	Nerve Bundles	„ „ 87
XVIII.	Figures VII.–XIII.	Nerve Fibres	„ „ 89
XIX.	Figures I.–VIII.	Spinal Cord	„ „ 100
XX.	Figures IX.–XVII.	Spinal Cord	„ „ 102
	Figure XI.	Optic Nerve	
XXI.	Figures I.–VII.	Brain	„ „ 112
XXII.	Figures I.–VI.	Ganglia	„ „ 121
	Figure VII.	Nerve Ending in Blood-Vessels	
XXIII.	Figures VIII.–XV.	Sympathetic Ganglia and Nerves	„ „ 122

PLATE			PAGE
XXIV.	Figures I.–V.	DISTRIBUTION OF FINE NERVES	Description on 134
XXV.	Figures VI.–XIV.	NERVE ENDINGS	„ „ 135
XXVI.	Figures I.–IX.	BLOOD-VESSELS	„ „ 149
XXVII.	Figures X.–XVII.	BLOOD-VESSELS	„ „ 152
XXVIII.	Figures I.–VI.	LYMPHATIC GLANDS	„ „ 161
XXIX.	Figures VII.–XII.	LYMPHATIG GLANDS	„ „ 163
XXX.	Figures XIII.–XXII.	LYMPHATICS	„ „ 178
XXXI.	Figures I.–VII.	TEETH	„ „ 208
	Figures VIII.–IX.	SALIVARY GLANDS	
XXXII.	Figures X.–XVII.	SALIVARY GLANDS, TONGUE, AND MUCOUS GLANDS	„ „ 210
XXXIII.	Figures XVIII.–XXIX.	TONGUE, ŒSOPHAGUS, AND STOMACH . . .	„ „ 212
XXXIV.	Figures I.–X.	INTESTINES	„ „ 231
XXXV.	Figures XI.–XIII.	INTESTINES AND PANCREAS	„ „ 233
	Figures XIV.–XX.	LIVER	
XXXVI.	Figures I.–IX.	RESPIRATORY ORGANS	„ „ 247
XXXVII.	Figures X.–XIII.	LYMPHATICS OF RESPIRATORY ORGANS . .	„ „ 249
XXXVIIa.	Figures I.–III.	KIDNEY	„ „ 264
	Figure IV.	SPERMATOZOA	
	Figure V.	OVARY	
XXXVIII.	Figures I.–IX.	KIDNEY	„ „ 265
XXXIX.	Figures I.–XIII.	MALE GENITAL ORGANS	„ „ 281
XL.	Figures I.–XI.	FEMALE GENITAL ORGANS	„ „ 303
XLI.	Figures I.–IX.	SKIN	„ „ 375
XLII.	Figures X.–XVI.	SKIN	„ „ 378
	Figures XVII.–XX.	CONJUNCTIVA AND CORNEA	
XLIII.	Figures I.–XII.	CORNEA, SCLEROTIC, IRIS, AND CHORIOIDEA .	„ „ 381
XLIV.	Figures XIII.–XXI.	CORNEA, IRIS, CHORIOIDEA, LENS, AND VITREOUS BODY	„ „ 384
	Figures XXII.–XXX.	RETINA	
XLV.	Figures I.–XII.	THE LABYRINTH	„ „ 416
XLVI.	Figures XIII.–XX.	THE TUBA EUSTACHII AND NASAL MUCOUS MEMBRANE	„ „ 420
XLVII.	Figures I.–XI.	THE SPLEEN	„ „ 428
XLVIII.	Figures I.–VI.	THE DUCTLESS GLANDS	„ „ 445
	Figures *a*–*s*.	INDIRECT DIVISION OF NUCLEI	

ATLAS OF HISTOLOGY.

CHAPTER I.

BLOOD.

Blood of vertebrate animals contains suspended in a colourless plasma two kinds of corpuscular elements: (*a*) coloured or so-called red; and (*b*) colourless or so-called white corpuscles.

One hundred volumes of blood of man contain about sixty-four volumes of plasma and thirty-six volumes of corpuscles.

According to recent measurements (Hayem, Mallassez), there are 4·5 to 5·5 millions of coloured blood-corpuscles in one cubic millimètre (or $\frac{1}{25}$ cubic inch) of human blood. In some animals it is much greater, even as great as eighteen mill. (camels, &c.). The number varies greatly in different vertebrate animals. In birds it is smaller than in mammals, and in fishes it is smallest. The relation between colourless and coloured corpuscles in normal human blood varies from 1 for 1,250 to 1 for 650. There is no constant increase in the number of colourless corpuscles after meals. The number of colourless corpuscles after a meal and simultaneous drinking is increased, but seems to be decreased after a meal without drinking.

The size of coloured corpuscles varies in different vertebrate animals. The largest are possessed by amphibian animals (proteus, amphiuma), the smallest by mammals: *Moschus javanicus*, Meminna and musk-deer, have the smallest blood corpuscles.

[In Rollett's article on Blood in 'Stricker's Handbook' will be found a table, by Welker, of measurements of blood-corpuscles of the different classes of vertebrate animals. See also Gulliver, in 'Proceed. Zoolog. Society of London,' 1874 and 1875.]

1. Colourless Blood-Corpuscles.

The colourless blood-corpuscles are spherical, pale, and transparent, when observed in the circulating or perfectly fresh blood. In most instances they are larger than the coloured corpuscles, but there are in every blood some that are smaller. They possess

in no instance a limiting membrane, and are composed of a transparent jelly-like substance, called 'protoplasm.' This substance appears more or less distinctly granular; but, on more careful examination, and under suitable conditions (see below), it can be shown that it is composed of a very minute network of fibrils (Heitzmann). This network, which we shall know as the intracellular network, contains in its nodes minute dots—and these produce the granular appearance—which are, however, due to fibrils seen in optical section.

In the meshes of the network is contained a hyaline interstitial substance. The accompanying woodcut 1 shows these relations, and also that the kernel or nucleus (in this instance there are two) contains a similar network—intranuclear network—which is in direct connection with the intracellular network. But there are in every blood some colourless corpuscles that contain in the meshes of the intracellular network coarse bright particles, real granules; and these corpuscles represent *granular corpuscles* par excellence. In newt's blood, and also in human blood, they are often seen in considerable numbers.



1.

When examined in the fresh state, especially under the influence of heat, e.g. on the warm stage, but without the addition of any fluid reagent, the colourless corpuscles undergo changes of shape, and in consequence of these also changes of place, just like amœbæ, and hence the designation of amœboid movement and amœboid corpuscles. These changes are due to the contractility of the intracellular network.

In the best examples of human colourless blood-corpuscles examined fresh, without any reagent, these changes are sufficiently distinct, even to the unexperienced eye, but on applying heat (about blood heat), these movements become very pronounced in most of the colourless corpuscles.

PLATE I.

Figs. I. II. III. IV. V. VI. and VII. represent colourless corpuscles while undergoing changes of shape and place; drawn under a magnifying power of about 400 diameters.

Fig. I. A colourless corpuscle of human blood as observed on the warm stage, in different stages of movement. (The different stages follow each other in this, and the following figures, from left to right.) The movement consists in the protrusion of a hyaline film. This is withdrawn, and another is protruded; in the next moment this is reduced to a very minute filamentous process, whereas, on the opposite side, a new broad process makes its appearance. This alone is left in the next stage.

I.

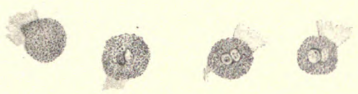

III.

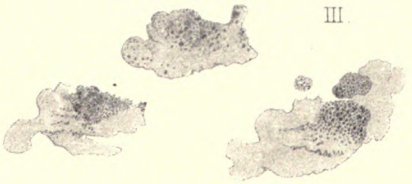

II.

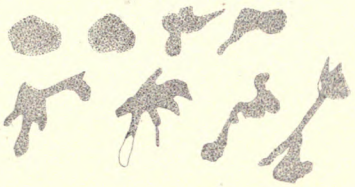

IV.

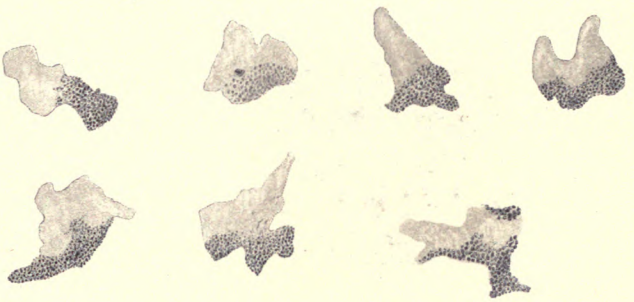

V.

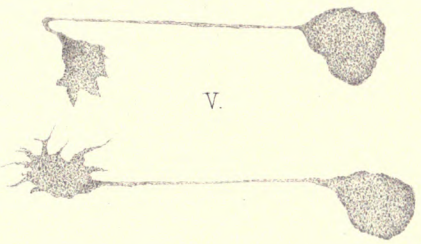

VI.

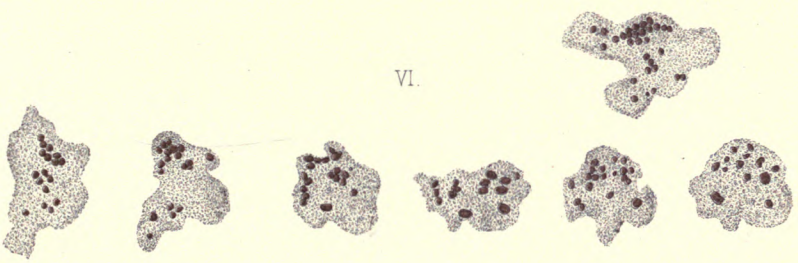

VII.

VIII.

IX.

X.

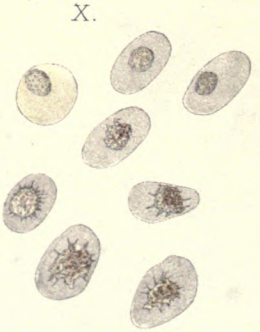

REESE LIBRARY
OF THE
UNIVERSITY
OF
CALIFORNIA

Fig. II. Another colourless corpuscle of human blood while performing amœboid movements. The corpuscle is seen to push out processes of various length and thickness, and thus to alter its shape in a considerable manner; in the last example of the lower row the corpuscle has almost separated into two lumps, united by a thin bridge.

Fig. III. A 'granular' corpuscle of newt's blood in three stages of amœboid movement while observed on the warm stage.

Fig. IV. Another granular corpuscle of the same blood in seven different stages of movement. The corpuscle showed not only rapid change of shape—there are several between each two here delineated—but moved very conspicuously along the field of the microscope.

In the 'granular' corpuscles we generally observe that the bright granules are not distributed uniformly throughout the protoplasm, but are collected in one or more groups. This is entirely due to the presence of large pale transparent nuclei in these corpuscles. The pale part in the corpuscles, represented in fig. IV., includes the nuclei but no granules. When watching the movements of a 'granular' corpuscle we often notice a flowing movement of the granules: this is entirely a passive movement; the protoplasm itself moves, and the granules embedded in it are carried to and fro.

These 'granular' corpuscles are few in numbers as compared with the other pale or ordinary colourless corpuscles, and they move much quicker. The greater number of colourless corpuscles are pale, indistinctly granular (see above); they move generally by throwing out finer or thicker, longer or shorter filamentous processes.

One of the most interesting forms of movement that may be observed in 'granular' as well as ordinary colourless corpuscles on the warm stage is this: the protoplasm of the corpuscle has collected into two—sometimes even three—lumps, connected by a thin bridge of the same substance. Each of these lumps alters its shape and place independently of the other. Now, either of two things may happen: (*a*) the two lumps move away into opposite directions, and by doing so they go on lengthening—at the expense of their own substance—the connecting bridge, until this breaks, and each lump, withdrawing its part of the bridge, continues to move like an independent individual (Klein); (*b*) or the mass of one lump—after a longer or shorter interval—flows again back into the other. If the two lumps are of unequal size, the larger one in its change of place is capable of dragging the smaller one, except this latter is fixed to the cover glass, or is jammed in between groups of blood-corpuscles: in this case the connecting bridge is drawn out to great fineness.

There is another mode of division of a colourless corpuscle into two; it is by a constriction appearing on the surface of the corpuscle, which after many changes ultimately

cuts through the whole depth of the substance, and thus divides the corpuscle into two (Klein, Ranvier).

In fig. V. a common or pale colourless corpuscle is shown after it has separated into two lumps connected by a thin bridge. The lower of the two figures is a later stage of movement of the one above.

In the blood of most vertebrate animals there are other colourless corpuscles besides the two kinds mentioned: they are much smaller, possess a relatively large nucleus, and show only slight amœboid movement. They represent corpuscles not yet fully developed. In newt's and frog's blood there are, in addition, oblong pale slightly flattened corpuscles, with an oval nucleus: these show only very slight amœboid movement, and are supposed to be the intermediary forms between colourless and coloured corpuscles.

Semmer describes in mammal's blood peculiar nucleated corpuscles somewhat larger than ordinary colourless corpuscles, but otherwise similar to them, except that they contain red granules, and are therefore called *red granular corpuscles*; they are supposed by this author and A. Schmidt to be intermediary forms between 'granular' colourless corpuscles and coloured ones.

The plasma of blood of most mammals contains, besides colourless and coloured corpuscles, minute bright but colourless, more or less angular granules, isolated or in groups (Max Schultze). Their nature is not definitely ascertained; their number varies in different animals and man, and also in one and the same individual at different times.

If pigment, e.g. vermilion, in a finely divided state is mixed with blood, either before or after withdrawing it from the vessels, the colourless corpuscles, in virtue of their movement, take up—'feed on'—the pigment particles. This process can be easily observed on newt's colourless corpuscles.

In fig. VI. an ordinary colourless corpuscle is represented that had taken up a few vermilion granules; the other examples represent the same corpuscle while undergoing amœboid movement; the vermilion granules are shifted about in its interior.

In the same way as a corpuscle takes up pigment granules it is capable also of swallowing any other particles of the surrounding medium. In some instances the corpuscle is capable of loading itself with a large burden of extraneous matter without losing its power of spontaneous movement. But the corpuscle may rid itself again of this, by ejecting one particle after another. In fig. VII. a corpuscle is represented before and after it has got rid of a portion of its load.

Many of the colourless corpuscles when fresh and living do not show the nucleus or nuclei in their interior; some, however, show distinct nuclei while moving; but all exhibit their nuclei—from one to four, and even more—when dead, or when treated with acids.

When watching the nuclei of a corpuscle while this is undergoing amœboid movement, it may be noticed that the nuclei also change their shape and place within the corpuscle; but this need not be due to any spontaneous movement on the part of the nuclei, for it can be readily explained in this way: the nuclei being soft are shifted about by the protoplasm within the corpuscle, and are capable of being squeezed into various shapes. But the nucleus of the small colourless corpuscles of newt and frog show spontaneous movements (Stricker), owing to the contractility of the intranuclear network. The nuclei are generally vesicular in aspect, and, as will be mentioned hereafter, include a minute network of fibrils, in some instances also what may be described as a nucleolus. The colourless corpuscles swell up on addition of water, and all of them show very distinct granules—these being fragments of the disintegrated network—which on a sufficient amount of water having acted on the corpuscles exhibit a quick oscillating movement, the so-called Brownian molecular movement, shown by any granular matter suspended in fluid in a sufficiently finely divided state. The nuclei within the corpuscle swell up and become very pale under the influence of water, and finally fuse into one. The final effect of water on colourless corpuscles is a total disintegration.

Under the influence of dilute acid they swell up slightly, the nuclei become distinct as irregularly shrunk bodies surrounded by what appears as a granular mass.

In fig. IX. a colourless corpuscle of newt's blood (the lower corpuscle on the right), and in fig. XVI. of the next Plate one of human blood, is shown under the action of dilute acetic acid.

In alkalies of sufficient strength the colourless corpuscles swell up and become finally disintegrated.

The effect of an electric shock of moderate strength produces a contraction of the living colourless corpuscle, after which the corpuscle resumes its movements again. Strong currents ultimately cause the corpuscle to swell up and disintegrate just as after water (Golubew).

The colourless corpuscles are regenerated from lymph-corpuscles of lymphatic glands and from certain endothelial cells of the serous membranes (see Chapter III.).

2. Coloured Corpuscles.

In fishes, amphibias, reptiles, and birds, the coloured corpuscles are elliptical discs of an almost uniform yellowish-green tint. A few fishes only (Cyclostomes), and most mammals, possess circular discs. Of mammals, only camelus and auchenia have elliptical blood-corpuscles. The blood-corpuscles of all mammals are without a nucleus, those of the rest of vertebrate animals have a central nucleus. In no instance have they, when fresh, a limiting membrane. They are soft structures and may, by pressure or otherwise, be

brought into various shapes; they are at the same time elastic and therefore capable of again returning to their original form. Under the influence of urea or overheating, the coloured blood-corpuscles break up into smaller or larger particles of the same colour and structure as when a whole. When extravasated into the living tissues, they also break up into smaller or larger particles, which ultimately give origin to amorphous brown pigment. The colour of the blood-corpuscles is due to hæmoglobin. When isolated they appear of a yellowish-green tint, which is of course deeper in a corpuscle seen edgewise than flat: only in thick layers do the corpuscles present a red tinge, which increases with the quantity of blood-corpuscles.

In fig. VIII. fresh blood-corpuscles of newt are represented. There are amongst them two colourless corpuscles, one of which is an ordinary colourless corpuscle in the act of moving—possessed of numerous minute processes; the other one—to the left and above—is a colourless corpuscle of the small kind, undergoing only slight amœboid changes; below there is a free nucleus of a coloured corpuscle—mechanically pressed out. Some of the coloured corpuscles are seen flat, others edgewise, most of them show their pale oblong nucleus; a few of them are slightly shrunk, the hæmoglobin at the same time being irregularly distributed in them, i.e. some parts of the disc being of a lighter, others of a darker tint.

Under a good power the nucleus of coloured blood-corpuscles of newt, frog, and especially toad, show a beautiful delicate network.

In fig. IX. three coloured and one colourless corpuscle of newt are shown after having been acted upon by dilute acetic acid; the coloured corpuscles have become decolorised, presenting now a pale transparent, well-defined disc, and in it the oblong nucleus greatly shrunk, and therefore opaque. The colourless corpuscle of this figure has been mentioned above.

In fig. X. coloured corpuscles of newt's blood are shown after treatment with a two per cent. solution of boracic acid. The result of the action of boracic acid is in this instance twofold: *a*) In some corpuscles the boracic acid produces, after a slight swelling, a discolouration of the disc, there being at the same time an imbibition of the nucleus with colouring matter; the upper three corpuscles are in different stages of this change; or *b*) the disc is discoloured and the nucleus becomes stained by the colouring matter, but is seen to be possessed of minute processes which are in connection with fibrils of the disc itself. In some instances—not represented here—these latter may be seen to form a network. Thus we have to regard the coloured blood-corpuscle as a disc in which a network of fibrils is to be distinguished from the transparent ground substance; this network of fibrils is in



2.

REESE LIBRARY
OF THE
UNIVERSITY
OF
CALIFORNIA.

XI.

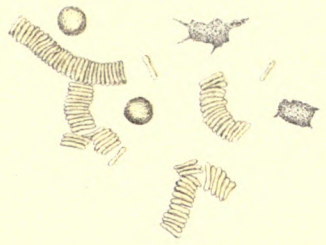

XII.

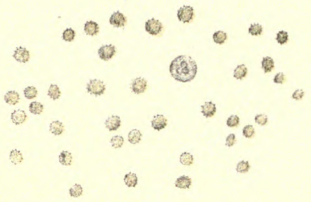

XIII A.

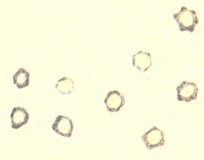

XIII B.

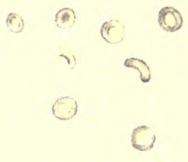

XIV.

XV.

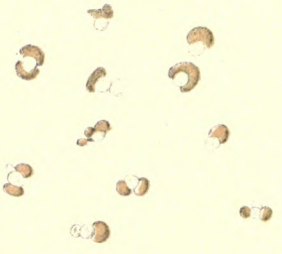

XVI.

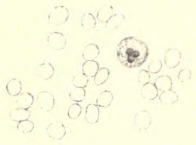

XVII.

XVIII.

XIX.

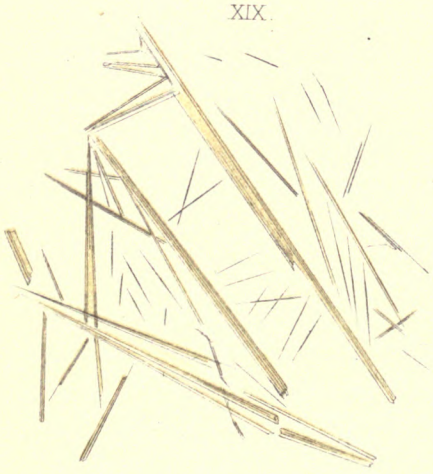

XX.

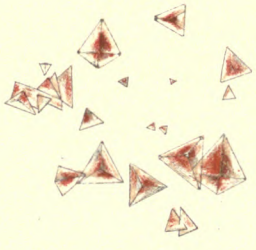

XXI.

connection with the network forming the nucleus, as represented in the accompanying woodcut 2.

In the blood-corpuscles of newt we have therefore to distinguish:

a) Network of fibrils of disc.

b) Interfibrillar hyaline ground substance of disc: both *a* and *b* together form the stroma.

c) Nucleus composed of limiting membrane and network of fibrils in connection with those of disc.

d) Hæmoglobin contained in the hyaline ground-substance of the meshes of the network of the stroma.

In some instances boracic acid shows a different effect from the above—viz. a collection of hæmoglobin in the central part of the corpuscle, the hæmoglobin not having, however, altogether withdrawn from the stroma; a star-shaped figure of hæmoglobin is thus produced in the pale disc (Zooid of Brücke). A similar effect may be easily obtained in frog's blood after adding water in the proportion of two to one, before covering it with a cover-glass (Kneuttinger).

Water makes the coloured blood-corpuscles—disk and nucleus—to swell up and to become entirely deprived of their hæmoglobin; they are then very pale and transparent, with very faint outlines.

PLATE II.

Figs. XI.–XVI. represent human blood-corpuscles as seen with a magnifying power of about 400. Figs. XVII.–XXI. are blood crystals viewed with a lower power—about 200–250.

Fig. XI. Human blood in a fresh microscopic specimen made without the addition of any fluid. There are two colourless corpuscles in the act of moving, being possessed of minute processes. The other corpuscles are coloured ones, most of them arranged in rouleaux-form, and thus seen edgewise; the cause of this appearance, always observed in similar microscopic specimens of any mammalian blood, is not known. There are several isolated corpuscles seen in profile—they appear biconcave; when seen from the broad surface—as shown in two other isolated examples—they appear as circular discs, which show a transparent centre and a more opaque peripheral part of a yellowish tint.

NOTE.—When focussed well, the corpuscle, seen from its broad surface, shows greater transparency in the centre than in the periphery, the former being at the same time less tinted than the latter. The reason is very simple: the corpuscle being a biconcave disc, is thinner in the centre than in the periphery, and therefore less hæmoglobin is present in the former than in the latter. In many books (Quain, Kölliker, Frey, Rollett, Ranvier) the coloured corpuscles are delineated as

if showing an opaque centre and a light periphery, but they appear such only because it is meant to convey that the former is *out* of focus when the latter is *in* focus.

In every preparation of mammals' blood and man there are a few coloured corpuscles conspicuous amongst the rest by their smallness; they are called mycrocytes. They have been found very numerous in pernicious anæmia (Osler). Hayem regards them as young growing corpuscles, being more numerous in all cases—physiological and pathological—in which a reparation of blood occurs, e.g. menstruation, loss of blood, in convalescents after acute diseases, &c.

Fig. XII. Human blood-corpuscles in $\frac{3}{4}$ per cent. solution of common salt. The coloured blood-corpuscles have become horsechestnut-shaped. When mammalian blood is diluted with saline solution or any other indifferent fluid, e.g. solutions of neutral salts in a certain percentage, serum or kindred fluids, or if blood be spread out in a very thin layer under a cover glass, without the addition of any reagent, the coloured corpuscles undergo the following changes: they lose their smooth circular outline, and become possessed of minute angular prominences—crinate; these increase in number, and are gradually distributed over the whole surface of the corpuscle, and the corpuscle losing its discoid shape, becomes more like a sphere slightly flattened,—horsechestnut-shape: the more this last stage is reached the smaller the corpuscle.

If to corpuscles after having become crinate, like those in fig. XIII.A, carbonic acid gas be added, their outline again becomes smooth and circular, but the corpuscles generally do not resume their biconcave form, most of them becoming convex-concave, i.e. saucer-shaped, like those represented in fig. XIII.B.

The most probable explanation of the phenomenon of the crinate and horsechestnut-shaped corpuscles is this: when blood is removed from the vessels and spread out in a thin layer or diluted with an indifferent reagent, a disturbance in the equilibrium of the carbonic acid of the plasma and corpuscles must necessarily take place; in consequence of the loss of carbonic acid by the plasma, a loss of carbonic acid is also suffered by the corpuscles, and this is followed by the shrinking (coagulation ?) of a part of the stroma—probably the network of fibrils;—the more perfect this contraction of the network the smaller and the more spherical the corpuscle, and hence also the more horsechestnut-shaped. On adding carbonic acid to the corpuscle the network resumes its previous character, and the former discoid shape is restored.

If the coloured corpuscles of mammal's blood are subjected to a succession of electric discharges of a Leyden jar, they also lose their smooth outline, becoming first crinate, then horsechestnut-shaped, and finally, after having swollen up again, they become decolorised (Rollett).

Figs. XIV. and XV. represent coloured corpuscles of human blood after the addition of 2 per cent. tannic acid. The blood-corpuscles (suspended in plasma diluted with $\frac{3}{4}$ per cent. saline solution) were allowed to become crinate and horsechestnut-shaped

before the addition of tannic acid. On this latter being added in sufficient quantity, the blood-corpuscles are seen to undergo changes represented in fig. XV., i.e. a collection of the hæmoglobin in one, two or more droplet-shaped masses—they are occasionally fanlike—takes place at the periphery of a pale disc, which in some instances is single, in others double. In other cases each blood-corpuscle presents at the periphery of a decolorised disc a highly refractive, smaller or larger, particle (Roberts), which may be easily stained by passing dyes through the specimen. The appearances delineated in figures XIV. and XV. are no doubt analogous—viz. being due to a separation of the hæmoglobin from the stroma of the blood-corpuscles.

Fig. XVI. When to human blood a weak acid, e.g. dilute acetic acid, is added, the coloured corpuscles are decolorised and converted into pale circular discs, each with a sharp outline; in the colourless corpuscles the small nuclei are brought out, as mentioned above.

The coloured corpuscles are formed from colourless ones, these altering in shape and the hyaline ground-substance, contained in the meshes of the intracellular network, becoming filled with hæmoglobin.

In the fœtus all blood-corpuscles are at first colourless; these soon become converted into coloured ones, which even in mammals retain the nucleus for a short period. Böttcher, however, maintains that also the adult coloured corpuscles possess a nucleus. It is doutbful whether what Böttcher demonstrates is a nucleus at all.

According to Neumann and Bizzozero, the marrow of bones of mammals contains nucleated coloured blood-corpuscles, i.e. intermediary forms between colourless and coloured corpuscles.

Blood Crystals.

Fig. XVII. Hæmin-crystals of human blood. The amorphous blood-pigment (Hæmatin) obtained by the decomposition of hæmoglobin can be converted, by means of chlorides, into nut-brown rhombic crystalline plates, hæmin or Teichmann's crystals, i.e. hydrochlorate of hæmatin. They are formed when dry blood is decomposed by glacial acetic acid in the presence of chloride of sodium (common salt).

In most cases the crystals are notched in at the narrow sides, at the same time they do not appear quite flat, but slightly trough-shaped.

Fig. XVIII. Hæmatoidin-crystals.

Red-brown crystalline needles, singly or in bundles, found in extravasated blood. In the present instance the crystals are contained in blood that had been extravasated into the submucous tissue of intestine of pig.

The so-called blood-crystals *par excellence* are the hæmoglobin crystals; in many kinds of blood they represent rhombic plates of a bright crimson colour, when obtained from a sufficient quantity of blood. In most mammals they are rhombic plates, e.g. fig. XXI. (copied from Preyer's book on 'Blood-crystals'); in the guinea-pig they are tetrahedral (fig. XX.), and in the squirrel hexagonal plates.

Hæmoglobin crystals of ox and pig are very difficult to obtain, or not at all.

Figure XIX. represents hæmoglobin crystals (?) of blood of pig; they were seen in a very thin layer of fresh blood two to three days after having been mounted as a microscopic specimen. The animal from which the blood had been obtained was diseased.

CHAPTER II.

EPITHELIUM.

EPITHELIAL CELLS are nucleated cells covering mucous membranes and skin, or lining secreting or kindred glands. The epithelial cells vary in shape and arrangement. They are columnar or pavement cells: the former again—conical, cylindrical or prismatical, spindle-shaped, pear-shaped or club-shaped; the latter—tessular or cubical, polyhedral and more or less flattened, scaly or squamous.

In this chapter will be considered the epithelium covering the skin and mucous membranes only; the epithelium of glands will be treated in connection with the latter in later chapters.

As regards their arrangement, epithelial cells form either simple columnar or simple pavement epithelium, i.e. are arranged in a single layer, or they aggregate into stratified columnar or stratified pavement epithelium, formed of several layers of columnar cells (of various shapes), or of several layers of pavement cells (of various shapes). As regards the substance of the epithelial cells, it is invariably composed of what appears at first sight as 'granular' protoplasm, but what is in reality (when examined under certain favourable conditions) a minute network (Heitzmann, Eimer, Klein)—*intracellular network.* The meshes of this network contain a hyaline interfibrillar substance, the amount of which determines the closeness of that network. The intracellular network is uniformly distributed throughout polyhedral cells—like that represented in woodcut 3—but it possesses a longitudinal arrangement in columnar cells like the one represented in woodcut 4; i.e. the greater number of fibrils run parallel with the long axis. In all instances, however, there are small dots or 'granules' seen in the network, chiefly in the nodes, which are fibrils viewed in optical section, hence the 'granular' appearance is the more distinct the closer the network, i.e. the more numerous the fibrils.

3.

Some epithelial cells possess a fine limiting membrane, others are without it; thus, for instance, most columnar epithelial cells have a membrane, so also the squamous epithelial cells of the superficial layers of stratified epithelium, whereas the polyhedral cells of the deeper strata of the latter are without it. But wherever it is present, it is merely a denser part of the cell-substance, probably in consequence of a process of 'hardening,' due to evaporation.

The nucleus of epithelial cells is oval in most columnar cells, spherical or nearly so in polyhedral cells; the more flattened these latter the more flattened also their nucleus. The nucleus consists of a limiting membrane and contents; this latter is a minute network (Fromann, Flemming, Eimer, Klein)—*intranuclear network*; and in the meshes of it a hyaline substance. The small dots or 'granules' present in the meshes of this network are due, like those of the intracellular network, to fibrils viewed in optical section. Besides these there are contained in the intranuclear network occasionally—but not very frequently—one or more larger highly refractive particles (nucleoli), which in some instances represent the remnants of the primary substance out of which the intranuclear network has developed; in other instances they are part of the shrunken network. Epithelial cells are grouped together by the aid of a homogeneous clear semifluid albuminous substance, which is placed in thin layers between the individual cells; hence it is termed 'intercellular cement,' or simply 'cement substance.' In sections through hardened specimens this cement-substance presents itself as a fine membrane separating neighbouring cells, but in the fresh state it is clear and viscid. Into this substance extend, from the subepithelial membrane, branched cells and their processes—connective-tissue cells (see further below). We shall have to return to this cement-substance on a later occasion.

Owing to the soft condition of the cell-substance and the semi-fluid nature of the cement-substance, the epithelium covering a membrane is capable—temporarily of course—of changing to a certain extent its character, if this latter (membrane) is subjected—in a natural or artificial manner—to certain mechanical alterations, such as contraction and expansion. If e.g. the membrane be greatly expanded, the epithelium, if stratified, becomes less stratified; or if only in a single layer, its cells become shorter in a vertical diameter, i.e. become flattened. If on the contrary the membrane shrinks *ad maximum*, the epithelium, if stratified, becomes more so, and if in a single layer, its cells become longer in a vertical diameter, i.e. thicker.

Both columnar as well as pavement epithelial cells are occasionally provided on their free surface with a smaller or larger bundle of fine hairs—cilia, which are prolongations of the fibrils of the intracellular network, as represented in woodcut 4, projecting through the thin membrane covering the free cell border. These cilia during the living condition of the cell are all simultaneously in rapid to-and-fro motion. It is quite possible that this movement is caused by the contraction of the intracellular network in this way: supposing the intracellular network contracts to one side in a horizontal diameter, each such contraction acts naturally on the lower end of the cilia, which thereby are pulled to the same side, while the outer or freely projecting portion of the cilia is driven in the opposite direction, each cilium representing a lever, the short arm



4. 5.

of which is within the cell in connection with the intracellular network, the long arm being the freely projecting part, and the fulcrum or fixed point lying in the membrane covering the free cell-border. When in the next moment the contraction of the intracellular network ceases the cilia move again in the opposite direction. These two phases would correspond to the to-and-fro movement of the cilia.

When ciliated cells are stimulated with moderate electric currents, the movement, if it has become slow, is again accelerated (Engelmann). Slight heat increases likewise the movement. And the same effect is produced to a certain extent by any fluid-current, no matter what it contains (Klein); not merely by liquor potassii, as often assumed, but by any other fluid; it is probably the mechanical stimulation produced by the current that acts on the ciliary movement. Carbonic acid added in sufficient quantities slackens and then arrests the movement; replacing it by air, the movement sets in again. But in the first place the addition of carbonic acid, just like the addition of any other reagent, produces an acceleration of the movement. All those reagents which, when added in sufficient quantities, destroy or impair the movement of amœboid cells have the same effect also on ciliary movement.

Columnar epithelial cells that reach a free surface, no matter whether they are ciliated or not, undergo occasionally a change of shape, which is associated with the secretion of mucous by them (F. E. Schulze); it consists in the conversion of the hyaline interfibrillar or interstitial substance, i.e. the hyaline substance contained in the meshes of the intracellular network, into hygroscopic mucin, and consequently the swelling up of it. Owing to the bulk of the cell-substance occupying the part of the cell nearest the free surface (see woodcut 5), and owing to the cell being covered on its free surface with a membrane, the swelling up of the interfibrillar substance produces a change of shape of the cell—from a columnar cell into a goblet-shaped element—goblet cell (see woodcut 6). It is intelligible how the nucleus, with a small portion of protoplasm surrounding it, is pressed into the distal end of the cell (see woodcut 6). The membrane covering the free border of the cell ultimately becomes detached, and, in the case of the ciliated cell, of course also the cilia fixed in it—and the mucus is finally poured out. The mucous contents of these goblet cells stain deep purple-blue in hæmatoxylin, and thus obscure the intracellular network, whose meshes are now much larger.

6.

PLATE III.

Figs. I. II. IV. V. VI. VII. VIII.A are drawn under a magnifying power of about 350. Figs. III. and VIII.B under a magnifying power of about 550.

Figure I. Epithelial cells of trachea of dog, in groups and isolated. Those that reach the free surface of the membrane are provided with fine cilia; they are conical, their free basis directed towards the surface. Between these fit others, more or less spindle-shaped or of an inverted conical shape, having their pointed extremity directed upwards—stratified columnar epithelium. Both the basis of the latter and the pointed extremity of the former and latter are provided in many instances with two or more fine branches. An oval nucleus is found in each superficial cell.

Some of the minute details of structure are not shown in this or many of the following drawings of Plates III. and IV., since the shape and arrangement of the cells is at present our principal object.

Fig. II. From a transverse section through the trachea of cat, showing the stratified epithelium composed of the superficial conical cells with cilia and the deeper non-ciliated cells of an inverted conical shape, i.e. their base directed downwards. This base contains the spherical nucleus. In the right section of the figure some of the superficial cells have lost their cover and cilia, and are goblet cells containing mucus which is being poured out. Underneath the epithelium is seen a connective-tissue membrane with the nuclei of the connective-tissue corpuscles; these latter are not represented; and finally underneath this layer is one that contains a great number of bright dots, being the cut ends of elastic fibres running a longitudinal course.

A similar stratified columnar epithelium (ciliated) is present in other parts of the respiratory tract; e.g. nasal cavity, larynx (except the epiglottis, the true and part of the false vocal cords) and larger bronchi. The central canal of the spinal cord, the small bronchi, the fundus uteri and the oviduct contain simple columnar epithelium with cilia. So does also the mucous membrane of the mouth, pharynx and œsophagus of amphibian animals.

Fig. III. The first (unlettered) cell is a goblet cell of stomach of newt, showing the intranuclear network in connection with fibrils of the intracellular network; the upper part of the cell is greatly swollen up by the presence of mucus, stained slightly with carmine.

a) A nucleus of a glandular epithelial cell of stomach of newt, showing the intra nuclear network.

b) A similar nucleus of an epithelial cell of the surface of the same organ.

I.

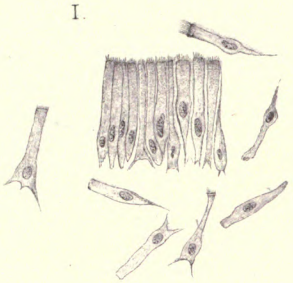

II.

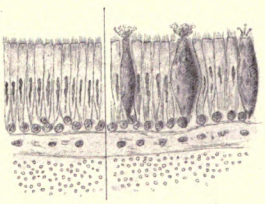

III.

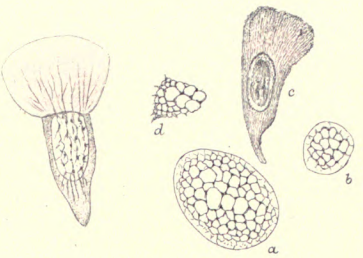

IV.

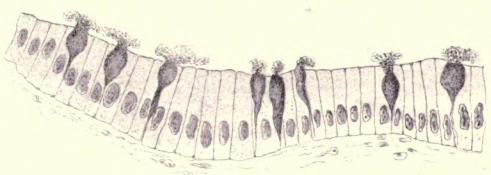

V.

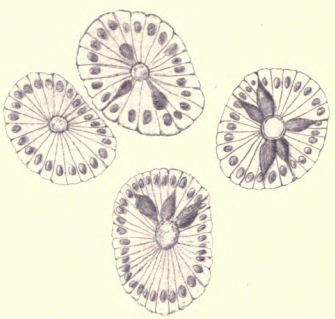

VI.

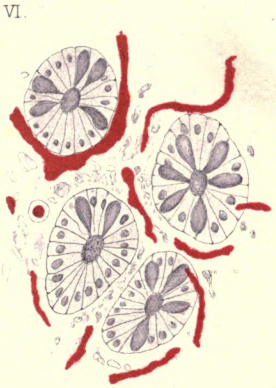

VII.

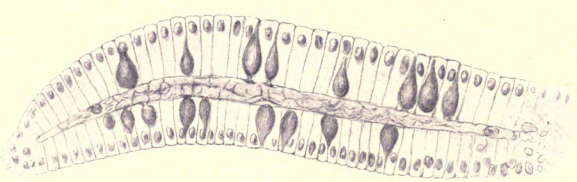

VIII.A

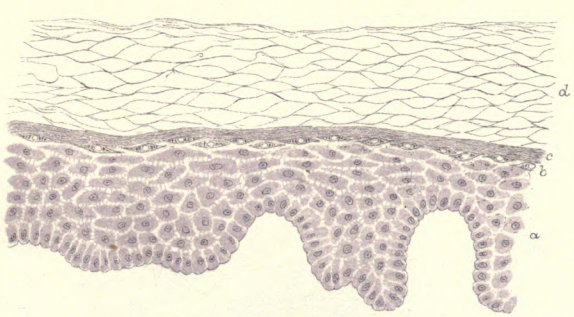

VIII.B

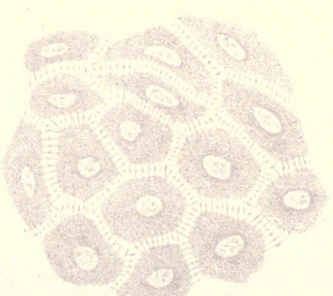

c) An epithelial cell of the surface of the same organ, showing the intracellular fibrils ; the network of these is not well seen.

d) An isolated fragment of the intranuclear network of an epithelial cell of the same organ.

Fig. IV. Columnar epithelial cells lining the surface of the mucous membrane of large intestine—simple columnar epithelium. Some of the epithelial cells are goblet cells pouring out their mucous contents.

The same relation exists in the simple gland tubes situated in the mucous membrane of the small and large intestine—crypts of Lieberkühn. The epithelium lining them is a simple columnar epithelium, and some of its cells are in a state of mucous secretion, i.e. are goblet cells. The number of these varies in different animals, in different states of digestion, and under different reagents. Thus they are most numerous in carnivorous animals during digestion, and in preparations treated with a chromium compound, e.g. chromic acid, bichromate of potash, Müller's fluid, chromate of ammonia. This refers both to the epithelium covering the free surface of the mucous membrane of the intestine, and to those lining the crypts of Lieberkühn.

Figs. V. and VI. represent such crypts transversely cut; fig. VII. the same cut longitudinally—at any rate, the greater part of the tube is cut longitudinally.

Figs. V. and VII. are from the large intestine of pig ; fig. VI. from that of cat. In this last-named figure the capillary blood-vessels—cut in different directions—surrounding the crypts are injected with carmine gelatin.

Fig. VIII. A vertical section through the epithelium covering the skin—epidermis. The epidermis is composed of the following different strata :

a) Rete Malpighii or rete mucosum.

b) Granular layer (Langerhans).

c) Stratum lucidum (Schrön).

d) Stratum corneum.

a) The rete Malpighii is a stratified pavement epithelium, composed of a deepest layer of more or less columnar cells each with an oval nucleus ; then follow several layers of polyhedral cells, each with a more or less spherical nucleus. Towards the surface the cells and their nuclei become more flattened. The lower surface of the rete Malpighii is not flat, but adapts itself to the minute papillæ with which the surface of the true skin is provided.

b) The granular layer, or more appropriately called the layer of the granular cells, is a stratum of flattened cells, spindle-shaped looking in vertical section, each with a more or less distinct clear nucleus, from the poles of which extend rod-like or disc-

shaped granules, gradually diminishing in size from the nucleus outwards. These granules stain deeply blue in hæmatoxylin, and thus become very conspicuous.

c) The stratum lucidum is a bright homogeneous or indistinctly striated membrane, composed of closely packed scales, in some of which minute traces of a staff-shaped nucleus may be occasionally distinguished. As a rule it is homogeneous.

d) The stratum corneum is composed of many layers of horny cuticles, each of which is composed of horny non-nucleated scales. They are best shown in liquor potassii.

The thickness and distinctness of these various layers is very different in the skin of different regions.

The rete Malpighii is the one stratum that alters least in its thickness, whereas the stratum corneum of some parts, e.g. of the volar side of the hand and plantar side of the foot, many times surpasses in thickness that of other parts. Also the stratum lucidum and the granular layer are in some places more distinct than in others ; they are generally best developed at and near the mouth of hair follicles, and also near the nails.

The cells of the deepest layer of the rete Malpighii contain, in coloured skins, a considerable amount of dark pigment granules ; these are generally accumulated in the cell-substance *around* the nucleus.

The polyhedral cells of the rete Malpighii are connected with each other by fine filaments (Bizzozero, Heitzmann), the so-called prickles of the prickle-cells (Max Schultze). In fig. VIII.B this is well shown. The substance of these cells is not simply granular, but it is a very dense network, and the prickles are fibrils uniting the network of adjacent cells ; but the cells are separated from each other by the ordinary transparent cement-substance mentioned above. Under inflammatory conditions this intercellular substance increases to a considerable extent, and hence the cells become more separated from each other, and the prickles or connecting filaments, on account of their greater length, are then better seen.

The same condition, i.e. prickle cells, is noticed also in stratified pavement epithelium other than the rete Malpighii, e.g. the stratified pavement epithelium covering the mucous membrane of the mouth.

PLATE IV.

Fig. IX., drawn under a magnifying power of about 550 ; the other figures under a magnifying power of about 350.

Figs. IX. and X. Simple columnar epithelium covering a villus of small intestine, goblet cells amongst them. Besides the oblong nuclei belonging to the columnar epithelial cells there are several round nuclei of lymph-corpuscles ; these are not, how-

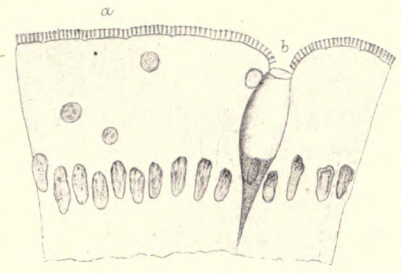

IX.

X.

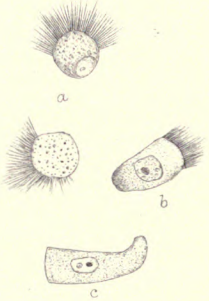

XI.

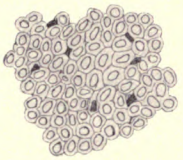

XII.

XIII.

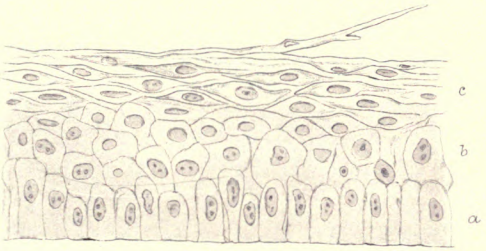

XIV.

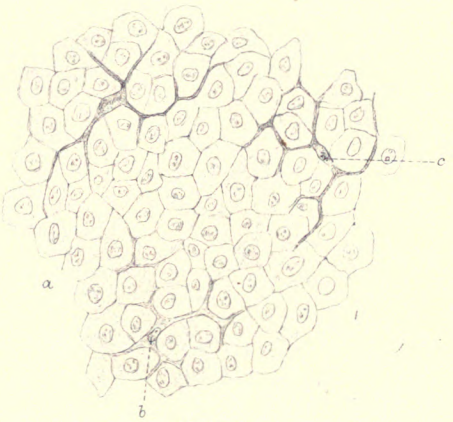

XV.

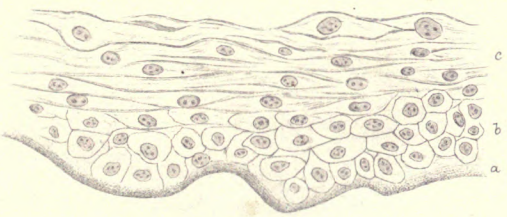

XVI.

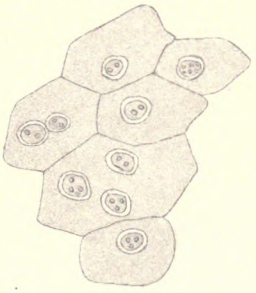

XVII.

XVIII.

REESE LIBRARY
OF THE
UNIVERSITY
OF
CALIFORNIA.

ever, contained in the substance of the epithelial cells themselves, but between these latter—i.e. below or above those represented in the figure. The columnar epithelial cells show on their free border a fine striation. These striæ, as shown in woodcut 5, are prolongations of the fibrils of the cell-substance. Usually these striæ are represented as if contained in a broad bright cuticular substance covering the free surface of this epithelium; but, as is seen in figs. IX. and X., these striæ or fibrils may be present without such bright cuticle, so that this latter cannot be actually covering the epithelial cells, but is probably due to a prolongation of the intercellular cement-substance, and thus in a profile view it appears as if covering the free surface of the cell itself, although in reality it is above or below it.

Fig. XI. Fresh epithelial cells of mouth of frog. Three are ciliated, one is without cilia; the two cells to the left appear as if spheroidal in shape, but in reality they are columnar, just like the third ciliated cell in this figure, only the former are viewed obliquely.

Fig. XIII. Scaly epithelial cells contained in saliva of mouth of man. They are derived from the superficial layers of the stratified epithelium of the mucous membrane of the mouth. Four cells are seen from the broad, one from the narrow surface; one spherical granular cell, a so-called salivary corpuscle with a nucleus in it. These salivary corpuscles, probably derived from amœboid corpuscles that have emigrated from the mucous membrane, appear somewhat swollen up, owing to the influence of the watery saliva; their granules are in a rapid oscillation (Brücke), just as in the colourless blood-corpuscles treated with water.

Figure XIV. Vertical section through the epithelium covering the anterior surface of the cornea. The epithelium is stratified pavement epithelium, of a similar arrangement as the rete Malpighii of the epidermis, or as the epithelium lining the mucous membrane of the mouth, of the lower part of pharynx and of the œsophagus of mammals, the vagina, the fossa navicularis of the male urethra, part of the male and female urethra. The epithelium of these different organs varies in the number of layers and in the presence of larger or smaller papillæ of the mucous membrane. According to the length of these the epithelium projects against the mucous membrane as longer or shorter *interpapillary processes*. The membrane of the cornea not possessing any papillæ is therefore covered by an epithelium with smooth under-surface.

The very different shapes presented by the columnar cells of the deepest layer of stratified pavement epithelium suggest that by horizontal division they produce the polyhedral cells above them, a proposition that can be proved by careful examination of isolated cells. The cells of the lowest stratum elongate, and by so doing have to adapt themselves to the space available to them. Thus some are club-shaped, pear-

shaped, or columnar; their nucleus divides into two, and then also the cell divides horizontally, and thus gives origin to a polyhedral cell above and a short columnar cell below (Lott, Rollett). This last one again elongates, &c. The cells of the deepest layer are in different stages of this process. As the production of the polyhedral cells by the deepest cell-layer proceeds, those first formed are pushed towards the surface by those formed last, and the nearer they are brought to the surface the more flattened do they become (as well as their nucleus). Those on the surface are subjected to evaporation and hornification, and in consequence of mechanical influences they become gradually removed altogether.

Between the cells of the stratified pavement epithelium are seen from place to place branched nucleated cells—connective tissue cells; in fig. XII. we see these in a surface-view of the deeper layer of the epithelium of the cornea. The processes of these cells become identified with the intercellular cement-substance; this is well shown in figure XV., representing the epithelium covering one side of the tail of a tadpole, viewed from the surface. These branched cells are seen to extend with their processes amongst the epithelial cells; the two upper ones are pigmented, the third lower one is quite colourless.

Fig. XVI. is a vertical section through the stratified pavement epithelium covering the (true) vocal cord of man; the epithelium is placed on a thick homogeneous elastic basement membrane. Some of the most superficial cells have become altogether detached.

The epithelium lining the alveoli of the lung is a simple pavement epithelium (see the chapter on Lung).

The epithelium lining the mucous membrane of the urinary bladder is stratified epithelium, of which the most superficial layer is composed of polyhedral cells of various sizes, each with one, two, or three nuclei—Figure XVII., and several other layers of columnar cells, which are club-shaped and spindle-shaped; those next the superficial layer of polyhedral cells are large club-shaped cells, those of the depth are smaller and more spindle-shaped; each has an oval nucleus—Fig. XVIII.

This stratified epithelium is therefore a mixed epithelium, and is generally called transitional epithelium. Similar transitional epithelium may be found at those places where stratified columnar epithelium passes into stratified pavement epithelium, e.g. larynx, upper part of palate, upper part of pharynx, &c.

The polyhedral (hexagonal) cells covering the external layer of the retina, and containing in most animals (except albinos) dark pigment granules, will be specially described in the chapter treating of the Retina.

CHAPTER III.

ENDOTHELIUM.

ENDOTHELIUM is understood to be the layer of flattened cells lining the free surface of any membrane, or cavity, or canal that is *not* a mucous membrane, or that is *not* the cavity or canal of a secreting gland respectively. The cells of these structures are epithelial cells, they form the epithelium, and are derived, as a rule, from the epiblast or hypoblast of the embryo. The cavities of the heart, of all blood-vessels and lymphatic vessels, lymphatic sacs and sinuses, the free surface of all serous and synovial membranes, the cavity of the tendinous sheaths, the subdural and subarachnoidal cavities, the chambers of the eye, &c., are lined with cells which form the endothelium.

The endothelium, in common with connective-tissue cells, to which it is closely related, and with which it forms a continuous group, as will be shown below, is derived from the mesoblast of the embryo. It is composed, with few exceptions, of a single layer of flattened cells—endothelial cells—each of which consists of a transparent elastic plate with an oval nucleus generally situated excentrically. The cells are held together by the same semifluid albuminous cement-substance mentioned at the epithelium. On account of the nucleus being thicker in vertical diameter than the cell itself, this latter, when viewed in (real or optical) vertical section, appears spindle-shaped.

A careful examination of the endothelial plates of different regions (blood-vessels, serous membranes, lymphatic sacs) in the fresh state, but still better after reagents, shows that their substance is not homogeneous, but possesses within a hyaline *ground-plate* a plexus of minute fibrils, which in many places are again connected with each other so as to form a network—*intracellular network* (Klein). The nucleus of each endothelial plate contains—like other nuclei—within a limiting membrane a dense network of fibrils—intranuclear network. This latter is connected by minute fibrils with the network of the cell itself. In those nuclei which may be regarded as in a ripe state the intranuclear network is uniform in its structure, other nuclei—probably in different stages of unripeness—possess one, two, or more large particles—nucleoli—included in the network. But in most cases we find also here the small bright dots—optical sections of fibrils—in the nodes of the network. Most endothelial cells possess a single oval nucleus with smooth outline, and in a given group most of the nuclei are approximately of the same size. But there are always isolated cases where one cell contains either two nuclei,

or one conspicuously large nucleus with or without indications of division, being hour-glass shaped, kidney-shaped, or lobate. On account of the very slight difference in refractive power of the endothelial cells, and the intercellular cement-substance, the outlines of the former cannot be easily ascertained. But with the aid of nitrate of silver this difficulty is entirely obviated (v. Recklinghausen). Any membrane covered with endothelium when steeped in a dilute solution of nitrate of silver ($\frac{1}{8}$—$\frac{1}{2}$ per cent.) for a few minutes, after exposure to the light, shows the outlines of the individual cells of the endothelium with great distinctness, the cement-substance being now visible as a black line.

The substance of the cells themselves and their nucleus is, as a rule, under these circumstances —except after prolonged staining with nitrate of silver—not discernible. Sometimes the former is recognisable by a granular precipitate, the latter being then noticeable as a clear space. But by staining with carmine or hæmatoxylin or other dyes, the nucleus of the endothelial plates can be always very prominently brought out.

A comparison of the endothelium of different organs shows considerable differences as regards the shape and outline of its cells. Thus, for instance, the endothelial cells lining small arteries and small lymphatic vessels are very elongated (flattened) with tolerably smooth outlines, whereas those of veins are less elongated, and their outlines are much more crinate and wavy. Again, the endothelial cells lining the large lymph-sacs of batrachian animals (subcutaneous and internal lymph-sacs), or those lining the so-called lymphatic capillaries, are more or less polygonal with a wavy or sinuous outline. Or, the endothelial cells covering the mesentery, the pleura, and pericardium of mammals are polyhedral cells with straight outlines.

But in every given place there are certain irregularities consisting in some cells deviating more or less in shape and outline from their neighbours.

The endothelial plates being elastic, and their interstitial cement-substance very soft, they, just like epithelium mentioned in the preceding chapter, are capable of altering their shape, size, and thickness, according to the state of contraction or expansion of the subjacent membrane, or the direction in which this is being drawn. If, for instance, the omentum, or the mesentery, or any other delicate membrane covered with endothelium, be drawn in a certain direction—of course within reasonable limits, so as not to disturb the continuity of its elements—the endothelial cells will be found to become elongated in the same direction, and if the membrane be then brought back to its former state, or drawn into a different direction, the endothelial cells will be found to change their shape accordingly. And also their outline may undergo corresponding variations; viz. it may be straight, or wavy, or sinuous, according to the state of expansion or contraction of the membrane.

The endothelial plates vary in size in the different organs, and also in one and the

same organ in different parts. Thus, for instance, they are considerably larger in the subcutaneous lymph-sacs than in blood-vessels of frog; in mammals they are far larger in the sheaths of tendons and nerve-bundles than in serous membranes, and amongst these the omentum is covered with larger endothelial plates than the pericardium. In many instances we find, however, isolated, or larger or smaller, groups of endothelial plates smaller than their neighbours, they are at the same time less flattened, more polyhedral, and even in the fresh state easier recognised, on account of their substance being more 'granular,' less transparent than that of the ordinary large flat endothelial plates. The nucleus of these small polyhedral cells is either single, or in a state of division, or it is already divided into two. These cells represent *germinating* endothelial cells (Klein). They are present in many serous membranes of young and adult individuals, on synovial membranes, on the tunica albuginea testis, on the endocardium of young individuals. They acquire a very great extension under pathological processes.

The omentum and pleura mediastini of mammalian animals are especially rich in smaller or larger groups of such germinating endothelial cells. In many instances they are found on the surface of special thickenings of the normal membrane—to be described in a later chapter—which present themselves to the unaided eye, according to their size, as larger or smaller opaque patches, nodules, or cords, many of them in connection with the vascular system. In some instances the germinating endothelial cells are found on peculiar villous or papillary projections, found especially under pathological conditions,—e.g. chronic, and also acute inflammations—in serous and synovial membranes, in the processus vaginalis and tunica albuginea testis, and the membranes of the central nervous system.

In some cases, e.g. omentum and pleura mediastini, the germinating endothelium contains cells which are in the act of division, or such as are becoming gradually altogether detached from the membrane. In the latter instance we find them club-shaped or pear-shaped, and connected with the membrane by a thinner or thicker, longer or shorter stalk. When this breaks the cell is free of the membrane. While in the process of detaching itself the cell becomes possessed of the power of amœboid movement, and it thus also in this important character approaches the nature of a lymph-corpuscle or colourless blood-corpuscle. After these cells have become freed of the membrane, they find their way into the lymphatic vessels, and hence into the blood-vessels, as colourless blood-corpuscles. In many mammals the amount of such germinating endothelium in the omentum and pleura mediastini is very great indeed, and hence these membranes play an important part in the generation of lymph- and colourless blood-corpuscles.

Besides these last-named membranes, there are others which contain germinating

endothelial cells. The peritoneal surface of the diaphragm—especially the central tendon—contains broader or narrower streaks of small endothelial cells, and amongst these there are germinating endothelial cells arranged around the stomata (Klein), i.e. the openings by means of which the lymphatics of the diaphragm communicate with the peritoneal cavity (see below). In the frog's mesentery, mesogastrium, and septum cisternæ lymphaticæ magnæ, there are also isolated or groups of germinating endothelial cells amongst the ordinary large flat transparent cells. In female individuals these germinating cells are ciliated, being possessed on their free surface of a bundle of fine hairs. This is especially the case about the spawning time (Dogiel and Schweigger-Seidel). On the peritoneal surface of the septum cisternæ lymphaticæ magnæ—the large lymphatic cavity extending on each side along the vertebral column and behind the peritoneum of the whole abdominal cavity—we find in some frogs, amongst the ordinary large flat cells, continuous and anastomosing streaks, composed entirely of the small polyhedral granular, i.e. germinating endothelial cells, which in females during the spawning season are all ciliated. As will be pointed out presently, the septum cisternæ lymphaticæ magnæ is perforated by numerous holes—by means of these an open communication is established between the peritoneal cavity and the cisterna lymph. —which in many instances are surrounded by a special layer of germinating endothelial cells. These are ciliated in females about the spring and are possessed of contractility; in consequence of this they are able to influence the state of dilatation of the stomata which they surround.

Similar contractility may be noticed under suitable conditions also on some germinating endothelial cells of the mesogastrium and the mesentery of frog.

PLATE V.

All figures, except fig. IV., are drawn under a magnifying power of about 350; fig. IV. about 500.

The brown tint in many figures of this and the following two plates is owing to their respective preparations having been stained in nitrate of silver.

Fig. I. Surface view of the endothelium covering the mesentery of cat. The mesentery had been first stained in nitrate of silver, and then in hæmatoxylin; by the first process, the outlines only of the endothelial cells, i.e. the interstitial cement-substance, is shown, the cell-substance being marked by a uniform brown tint; by the second process the oval and excentric nuclei of the individual cells are brought out in addition.

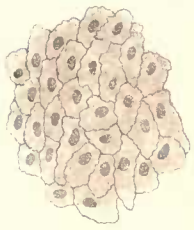

I

II

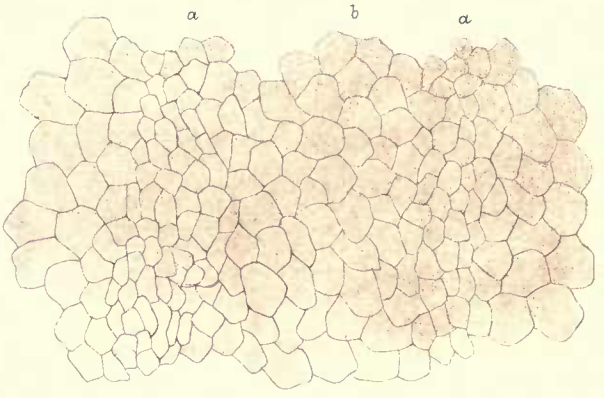

III

IV.

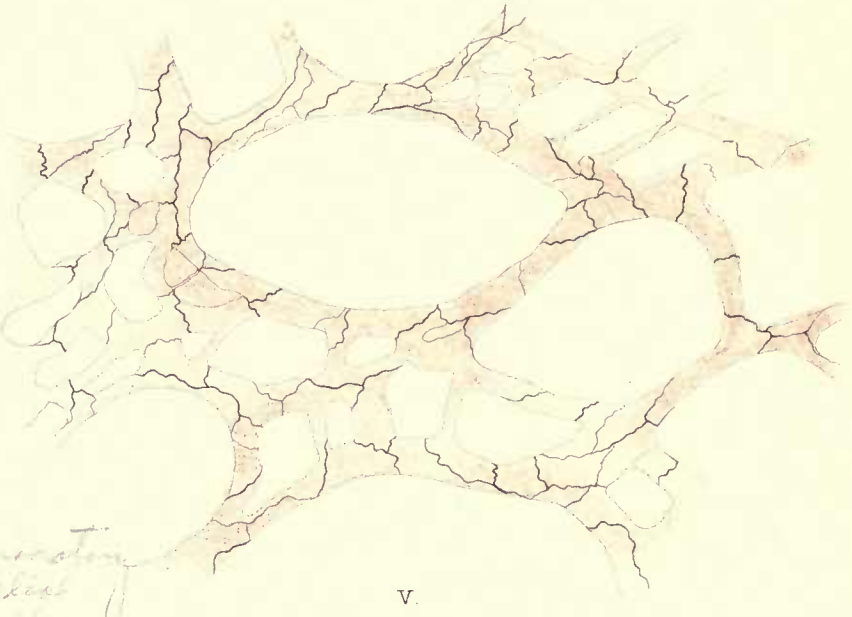

V.

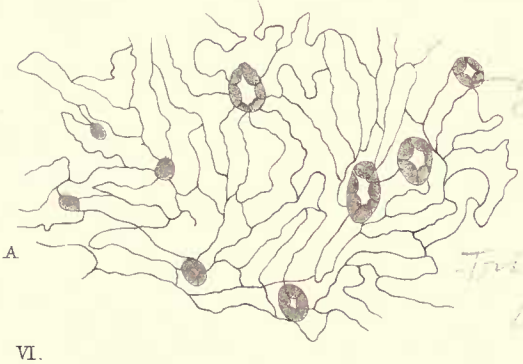

VI.

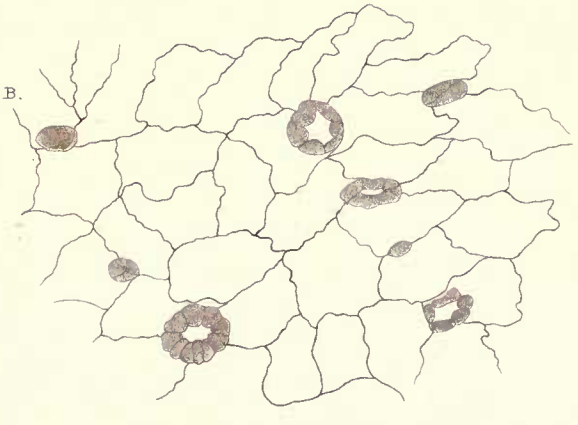

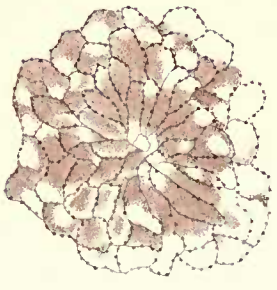

A

VII.

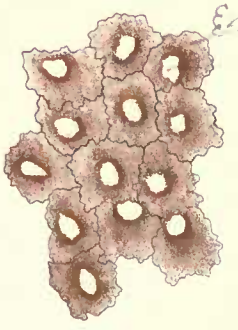

B

Fig. II. Part of a plexus of connective-tissue bundles from the fenestrated omentum—stained in carmine—of a rat. The omentum of many mammals—dog, cat, guinea-pig, rat, mouse, man—is, in the adult individual, a plexus of broader and narrower trabeculæ, composed of bundles of connective-tissue fibres. These trabeculæ are covered with, or ensheathed in endothelium, the meshes between the bundles being left entirely uncovered, as represented in figure V. Such a membrane is called a fenestrated membrane, and is present in other organs besides the omentum ; e.g. the pleura mediastini of many mammals, the mesogastrium of frog, the fenestrated membranes of the ligamentum denticulatum of the spinal cord, and of the ligamentum pectinatum iridis, &c. Endothelial cells of these and similar organs, e.g. surface of tendon, outer surface of nerve trunks, or blood-vessels that pass through a lymph-sac, are in so far different from those of a flat surface, e.g. mesentery, as the endothelial cells constituting the ensheathing endothelial membrane are curved, this latter adapting itself to the more or less curved surface of the respective organs.

The same holds good also for the endothelial cells that line a tube, e.g. blood vessels and lymphatic vessels.

In the present figure II. the ensheathing endothelium is recognisable only in profile, i.e. on the edges of the trabeculæ ; the substance of the endothelium being quite transparent, it is not noticeable on the surface of the trabeculæ.

Fig. III. Surface view of the endothelium covering the peritoneal side of the central tendon of the diaphragm. The preparation being stained in nitrate of silver, we find only the intercellular cement-substance, i.e. the cell-outlines, represented.

a. Narrow streaks of small endothelial cells.

b. Broader streaks of large endothelial cells.

The membrane (peritoneum) on which the latter (*b*) are situated covers the tendon bundles themselves, whereas that corresponding to the former (*a*) covers the interfascicular lymph-channels (see chapter on Lymphatics).

Fig. IV. Two endothelial plates of mesentery of newt, stained with picrocarmine. Each endothelial plate contains in a hyaline slightly stained ground-plate a plexus of fine fibre-bundles—intracellular network—in connection with the intranuclear network.

Fig. V. Fenestrated omentum. Only the outlines of the endothelial cells (not their nuclei) ensheathing the trabeculæ are shown.

Fig. VIA. Surface view of endothelium covering the peritoneal side of the frog's septum cisternæ lymph. magn. The germinating endothelial cells bordering the stomata are well shown. Some of these are widely distended, others are quite collapsed.

Fig. VIB. Surface view of the endothelium of the cisternal side of the same

membrane. The character of the endothelium is quite different from that of the peritoneal side. The germinating cells surrounding the stomata, especially the open ones, are well shown. Copied from Klein's 'Anatomy of the Lymphatic System,' Part I.

Fig. VII. The endothelium of the same membrane more intensely stained with nitrate of silver. In A, seen from the peritoneal; in B, from the cisternal side. The substance of the individual endothelial plates is indicated as a brownish granular matter, the nucleus being left clear; especially well shown in B. This need not necessarily mean that the cell-substance has actually become stained by the nitrate of silver and the nucleus not, for it is quite possible that the brown matter is a precipitation in the serous fluid of the surface only; owing to its greater thickness, the nucleus projects beyond the general surface of the cell, and this part of the surface retains therefore least of that serous fluid, and hence contains least of the precipitation.

The intercellular cement-substance of A contains a uniform precipitation of large and distinct granules.

The outlines of the endothelial cells of B are very sinuous. The same endothelium is found on the membranes lining the subcutaneous lymph-sacs of frog.

PLATE VI.

Figs. VIII. IX. XII. XIII. drawn under a magnifying power of about 300; figs. X. and XI. under one of about 450.

Figs. VIII. IX. X. and XI. are copied from Klein's 'Anatomy of the Lymphatic System,' Part I.

Fig. VIII. Germinating endothelium covering nodules and cords freely projecting over the surface of the fenestrated pleura mediastini of a healthy cat.

Fig. IX. Part of an opaque patch and its surrounding of the omentum of rabbit.

a. Ordinary transparent flattened endothelium.

b. Opaque patch covered with germinating endothelial cells. Amongst them many minute openings—stomata—leading into subjacent lymph-spaces.

Fig. X. Portion of fenestrated omentum (guinea-pig) in chronic inflammation.

a. Connective-tissue trabeculæ covered with ordinary flat endothelium, marked here by its outlines.

b. Trabeculæ covered with richly germinating endothelial cells.

Fig. XI. From the mesentery of frog.

F Ground substance not represented.

a. Capillary blood-vessels containing a few blood-corpuscles. Each of these

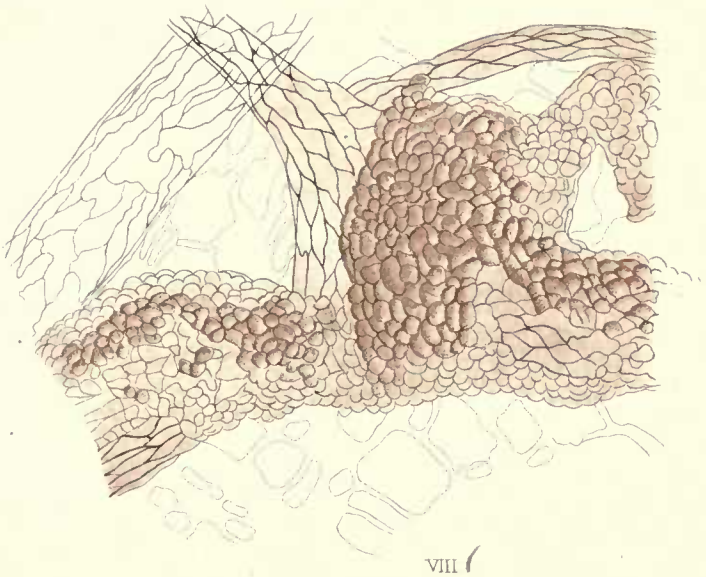

VIII.

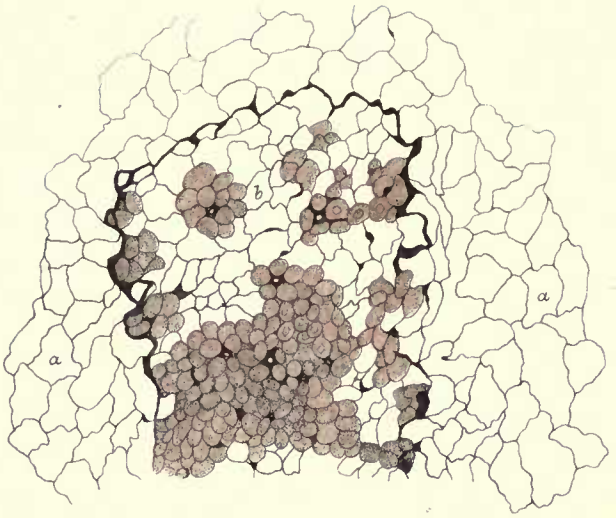

IX.

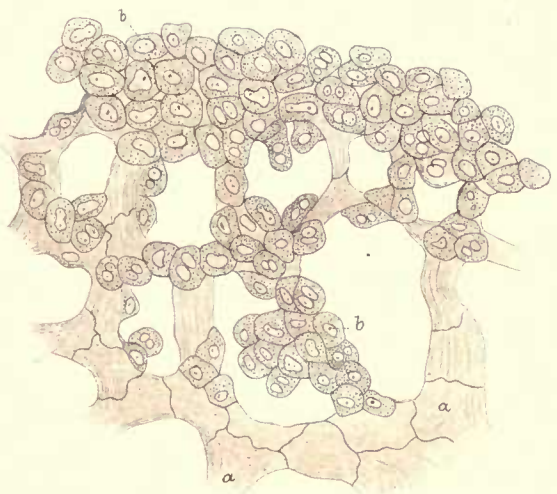

X

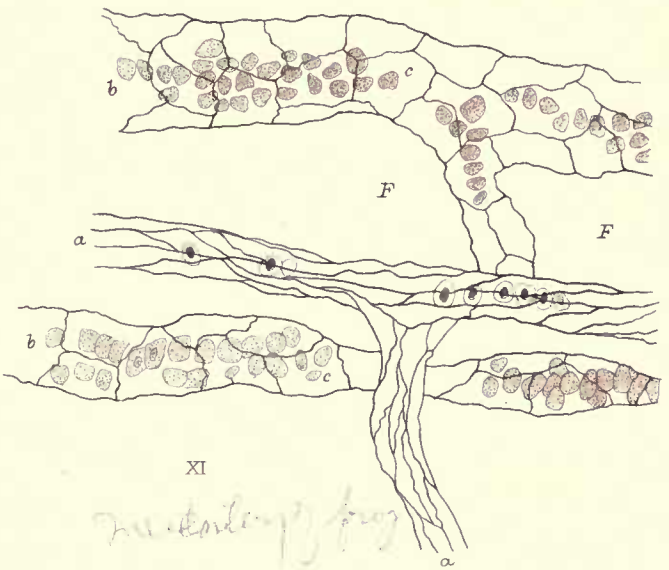

XI

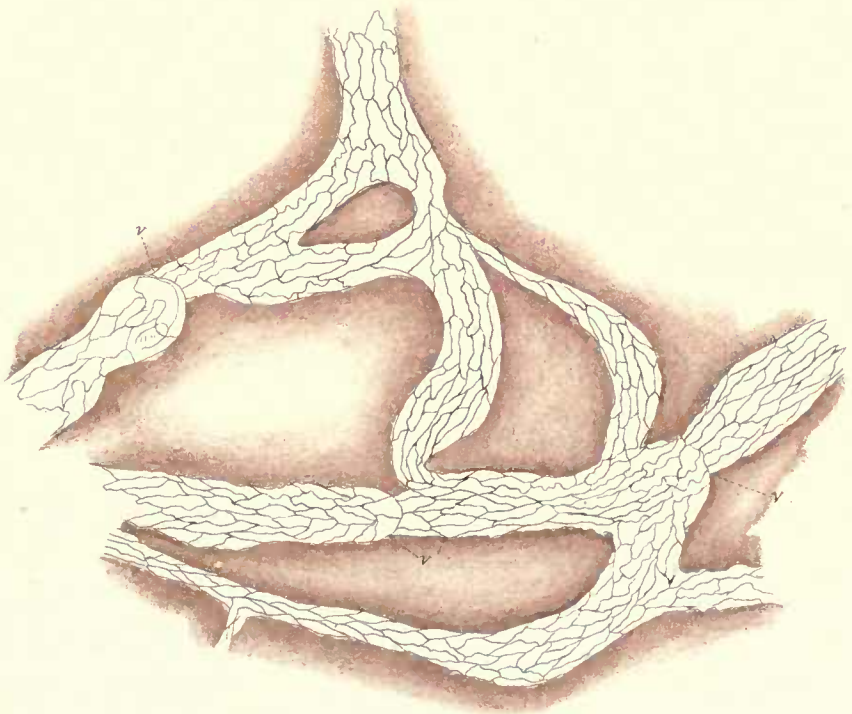

XII.

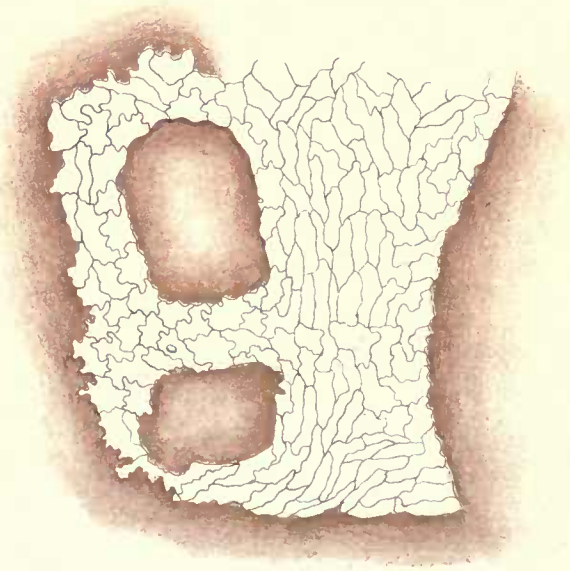

XIII.

E. Noble Smith. fecit

Mintern Bros. imp.

REESE LIBRARY
OF THE
UNIVERSITY
OF
CALIFORNIA

vessels is a simple endothelial membrane, rolled into a tube. The outlines only—i.e. the cement-substance—of the endothelial cells are shown; these (cells) are very elongated plates.

b. Lymphatic vessels, containing numerous lymph-corpuscles of different sizes. The wall of the lymphatic is also made up of only a single layer of endothelial plates, more or less polyhedral in shape. In this drawing only the upper wall of the lymphatics is represented.

Fig. XII. Plexus of lymphatic tubes of the diaphragm of dog. Their wall is a single layer of elongated endothelial plates; only the upper wall of the vessels is represented.

At v. semilunar valves are seen in profile, their broad surface being directed towards the lumen of the vessel. Corresponding to the valves, the vessels are possessed of saccular dilatations.

The tissue in which the lymphatics are embedded is marked by a brown tint in this and the next figure.

Fig. XIII. Lymphatic capillaries from the diaphragm of rabbit.

The endothelial plates are less elongated than in the lymphatic tubes possessed of valves, like those of fig. XII., and show a very sinuous outline.

In addition to the endothelium described in the foregoing, the basement membrane is to be mentioned, which in many mucous membranes separates the epithelium of the surface from the subjacent connective tissue of the mucosa. This membrane is not homogeneous, but being an endothelial membrane—the subepithelial endothelium, first described by Debove of the bladder, bronchi and intestine—is composed of flattened nucleated cells, the shape of which varies in different organs, being in some places polyhedral, in others more elongated cells, with straight or sinuous outlines.

The membrana propria of the ducts of some glands, e.g. sweat glands (Czerny), is also a membrane composed of a single layer of endothelial plates,

CHAPTER IV.

CONNECTIVE-TISSUE CORPUSCLES.

THE great bulk of tissue which for many organs—glands, nerve trunks, vessels, muscle, &c.—serves as the supporting and connecting substance, while in others,—serous and synovial membranes, tendons and fasciæ, skin and mucous membranes,—it forms the ground-substance, is composed of what is ordinarily called common or fibrous-connective tissue. With elastic tissue, cartilage, and bone, it represents the great group of 'connective tissues,' all these being in morphological and histogenetical respects intimately connected with one another.

In the present chapter we shall have to deal only with the cellular elements found in fibrous connective tissue. They are of two kinds: A. migratory or wandering connective-tissue cells (v. Recklinghausen), and B. fixed connective-tissue cells, or connective-tissue corpuscles *par excellence.*

A. The migratory connective-tissue cells are the amœboid cells found in fibrous connective-tissue; they are protoplasmic cells, just like colourless blood-corpuscles, with one, two, or three nuclei; they also resemble them in size. In connective-tissue of loose arrangement, e.g. subcutaneous and submucous tissue, they are more numerous than in parts of a denser structure. They are found more numerous in connective tissue which is richly supplied with blood-vessels, e.g. the connective-tissue in and around glands and muscle. In the superficial parts of the corium and mucosa and the cornea, they are found more often than in the deeper parts of these organs. Under inflammatory conditions the connective-tissue contains great numbers of migratory cells —pus cells,—many of which are however derived from colourless blood-corpuscles that have emigrated from the vessels (Cohnheim). But of course it is impossible to distinguish the one from the other.

If pigment matter, such as vermilion or carmine, is injected into the circulating blood in a finely divided state, some pigment granules are taken up by colourless blood-corpuscles, others not, and these may find their way into the connective-tissue of different regions, being carried through the wall of the capillary vessels by the natural current that passes from the latter into the surrounding tissue; here they (pigment granules) may be taken up by migratory connective-tissue cells and through these may be distributed to distant regions. But the pigment-granules may be carried through the walls of

the capillary vessels by means of the colourless blood-corpuscles that had swallowed them within the vessels. Having left the blood-vessel, these cells migrate about in the surrounding connective tissue, and, as has been mentioned in Chapter I., may during this time gradually eject and leave behind their load of pigment granules. These may be swallowed again by migratory connective-tissue cells, which have had no immediate connection whatever with the capillary vessels. If, then, we inject carmine into the circulating blood of a frog, and we produce an inflammation in some connective tissue—e.g. tongue, or cornea, or web of foot, and we find in the inflamed part many migratory cells—pus cells—containing carmine granules, we are not justified in concluding that these cells are all colourless blood-corpuscles that have emigrated from the vessels, for the pigment granules contained in them are no index of their origin. The pigment granules may have been imported into the inflamed part by migratory connective-tissue cells that found them in the connective-tissue whither they were carried by other agencies (Stricker).

In addition to the migratory cells, as described above, there exist other corpuscles which show only very slight amœboid movement, are larger than the ordinary migratory cells, contain a single relatively large nucleus, are unbranched, and, in many instances, contain real granules which stain very markedly deep blue in hæmatoxylin, and become hereby very conspicuous. They are to be found in the vicinity of small blood-vessels, in the serous membranes, submucous tissue, in the connective-tissue sheath of nerve trunks, in the trabeculæ of lymphatic glands, in the intermuscular tissue of tongue, and in the intermuscular connective tissue in general. These corpuscles correspond to the plasma-cells of Waldeyer, and have been noticed by many previous observers.

B. The fixed or connective-tissue corpuscles proper are transparent, more or less elastic, and flattened nucleated cells, which bear a definite relation to the connective-tissue ground-substance in which they are situated.

The connective-tissue ground-substance is in most instances composed of larger or smaller cylindrical or bandlike bundles of minute fibrils, and it is the peculiar arrangement of these bundles which determines the shape and nature of the connective-tissue corpuscles.

In tendon and in kindred connective tissue (fascia, aponeurosis) the bundles are arranged parallel with each other, and they form groups. Between each two groups we find a more or less straight channel—interfascicular lymph-channel; in these channels lie the connective-tissue cells, forming for each such channel a single continuous row of flattened cell-plates—the so-called tendon cells (Ranvier). This row of cell-plates covers only a section of the circumference of the channel (the other section being left uncovered), and in doing so the cell-plates have to adapt themselves to the more or less

curved surface of the tendon-bundles which surround the channel. Generally five to eight (sometimes even less) bundles surround, or rather form, the channel by joining into one group, and of the free surface of these—i.e. the surface forming part of the boundary of the channel—only two or three are covered with the row of the cell-plates, so that each of these cell-plates is correspondingly composed of two or respectively three concave sections, which join in a straight ridge, single in the former, double in the latter case (elastic stripe or stripes of Boll). The cell being flattened, a transverse section shows either two slightly curved lines joining in a projecting ridge, or two such lines joined by a middle horizontal line, also concave. In this latter instance we have to do with a cell-plate possessed on each side with a winglike expansion (Grünhagen).

The shape of these tendon-cells is more or less oblong, each being separated from its neighbour at each end by a linear cement-substance. But laterally the cell-plates are possessed of fine processes extending into the depth. These processes are better seen in cells of adult than in those of young tendon.

In the skin, mucous membranes, and similar organs, the connective-tissue bundles cross each other in groups or singly, and are at the same time branched, and exchange fibrils with their neighbours: in this way a very complex system of spaces is formed between the groups of bundles. These spaces—interfascicular spaces—vary in size according to the looseness or density of arrangement of the bundles, and contain the connective-tissue corpuscles, which are flattened nucleated cells possessed of more or less branched processes. As in tendon so also here the cell-plate is of a complex nature, being possessed of two or more membranous projections according to the cell-plate covering the breadth of several bundles, and sending between them membranous projections. Generally there is one section of the cell-plate which is the largest, and which usually contains the nucleus. This is the chief plate, whereas the other smaller ones coming off from it under various angles are the secondary plates (Waldeyer). All these membranous parts of the cell-plate are drawn out into fine processes, which vary considerably in length, and which often are again branched and connected with each other.

In the serous membranes, synovial membranes, and other similar membranous or lamellar expansions of connective tissue, the connective-tissue corpuscles are likewise flattened nucleated cells possessed of processes more or less branched and connected with each other. The cells expanding prominently in a level parallel to the surface of the membrane, there is not much chance of their being possessed of chief and secondary plates; each cell being a plate from which processes—some filamentous, others membranous—come off chiefly in the level of the cell-plate. But there are in some instances more or less distinct indications of membranous processes passing upwards or downwards in a more or less vertical direction. The same applies also to the cornea; here the connective tissue possesses a distinct lamellar arrangement, and the connective-tissue

REESE LIBRARY
OF THE
UNIVERSITY
OF
CALIFORNIA.

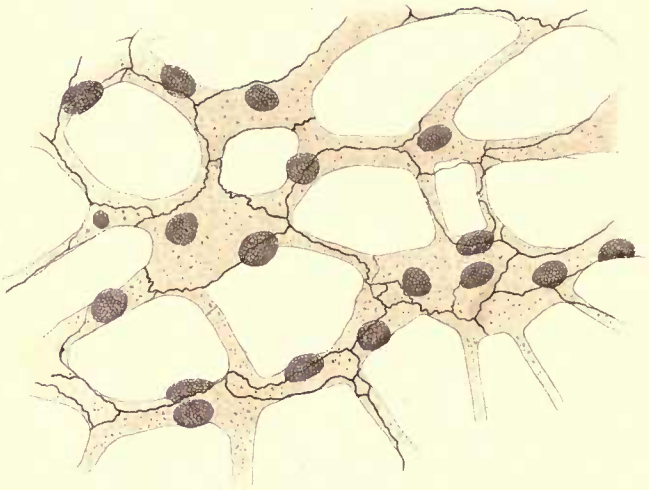

I.

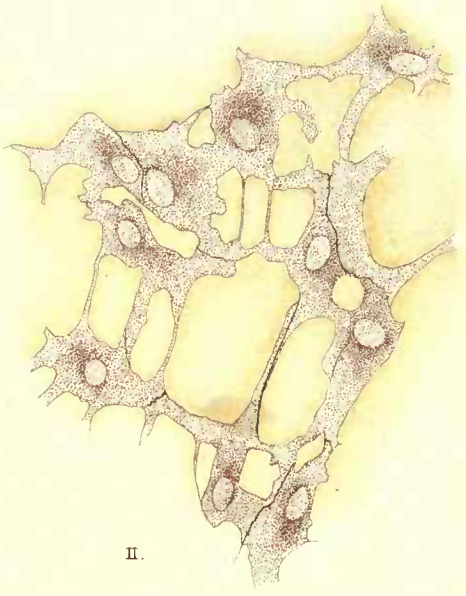

II.



III.



IV.

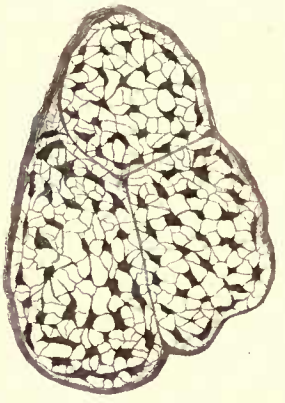

V.

VI.

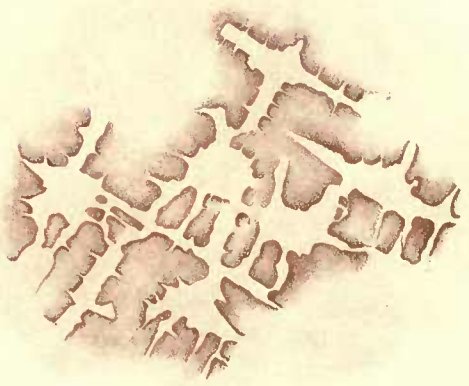

VII.

corpuscles are found to expand chiefly between the lamellæ in a horizontal manner, but there are also such cells as are arranged obliquely, or even vertically, to the general direction of the lamellæ (Rollett).

In the case of cornea, serous membranes, and other membranous expansions of connective tissue, e.g. the connective-tissue lamellæ that can be obtained from the subcutaneous or submucous tissue, it can be shown that each connective-tissue corpuscle is composed of two distinct substances (Klein) : (*a*) a hyaline plate—*ground-plate*—which contains the oval nucleus, the substance of which is a dense network—intranuclear network ; and (*b*) a second substance—a network of minute fibrils, *intracellular network* —arranged always more copiously at one side of the nucleus than at the other, and extending from here beyond the limits of the ground-plate, as finer or thicker branched or unbranched processes. This second substance is in connection with the intranuclear network. The ground-plate extends only on the more membranous processes.

It is probable that also in the case of the connective-tissue cells possessed of a chief plate and secondary plates with fine filamentous processes, we have to distinguish the hyaline substance containing the nucleus from the network of minute fibrils extending beyond the limits of both chief and secondary plates ; the difference being only that here the ground-plate is not a single flat plate, as is the case in the serous membranes, but sends off under different angles several other plates—secondary plates.

The 'granular' appearance of the connective-tissue cells is due to the density of the intracellular network. The branched nucleated corpuscles, entirely composed of 'granular' protoplasm, as they represent themselves under various conditions, are only one part of the corpuscle, viz. the nucleus and the surrounding network of fibrils, i.e. substance *b* mentioned above, the hyaline ground-plate not being then perceptible. Whereas the representation of connective-tissue corpuscles as hyaline unbranched plates with an oval nucleus refers also only to one part of the connective-tissue corpuscle, viz. nucleus and the ground-plate, i.e. substance *a* mentioned above.

PLATE VII.

Figures I. II. and IV. drawn with a magnifying power of about 450 ; the other figures with one of about 350.

Fig. I. A portion of fenestrated omentum of adult guinea-pig. The omentum had been stained first in nitrate of silver and then in logwood. The plexus of connective bundles forming the fenestrations is stained faintly in hæmatoxylin ; it is covered on both surfaces with endothelium, as mentioned on a former occasion ; the nuclei of the endothelial cells are brought out very well, and contain a uniform dense network. The

nuclei represented here belong to the endothelial plates of the upper or the lower surface. There are no other nuclei, i.e. no other cells, e.g. connective-tissue cells, except those of the endothelium of the surface. If a portion of the omentum as represented here is compared with a portion where the connective-tissue trabeculæ are larger, and the holes, i.e. fenestræ, smaller and scarcer, it will be found that in addition to the endothelial cells of the two surfaces there are flattened connective-tissue corpuscles between the bundles of connective-tissue fibres.

In those animals in which the omentum is fenestrated (see the previous chapter) in the adult condition, it is not, or only imperfectly so, in the young condition, being then a continuous membrane composed of a layer of connective-tissue bundles. It has been shown (Klein) that the fenestration is produced by cavities appearing between the connective-tissue bundles, which cavities open through the interstitial cement-substance of the surface-endothelium. The connective-tissue corpuscles situated previously between the connective-tissue bundles are then used to cover the lateral surfaces that have now become free. So that a direct transition of connective-tissue corpuscles into endothelial cells of the surface is hereby established.

Fig. II. Surface view of part of a lamella of cornea of kitten, prepared first with caustic potash, and then with nitrate of silver. The lamellæ of connective-tissue bundles are separated from each other by the same semifluid albuminous cement which has been mentioned at the epithelium and endothelium, and in this albuminous substance are situated the flattened banched connective-tissue corpuscles, the so-called corneal corpuscles. When a cornea is prepared with nitrate of silver only, the spaces for these corpuscles are brought out as clear lacunæ in a brown ground-substance, as represented in figures VI. and VII. The lacunæ indicate the general shape of the corneal corpuscles, and these latter being possessed of processes by means of which neighbouring cells anastomose, also the lacunæ show a number of canals for those processes. The lacunæ and canals form the lymph-canalicular system (v. Recklinghausen) of the cornea. The brown ground-substance is the albuminous interlamellar cement-substance. But in a cornea first prepared with caustic potash and then with silver (Stricker) the cells themselves become marked in the lymph-canalicular system by a red-brown granular matter. To each cell corresponds a large, clear, oval nucleus. As is seen in the figure, the cells lie in some places in close contact; we then find a dark line—cement-substance stained in silver—separating them, like those of ordinary endothelium. The fine canals of the lacunæ are not well shown here.

Fig. VI. is a surface view of part of a cornea of kitten prepared simply with nitrate of silver. The nuclei of the corneal corpuscles are indicated in the lacunæ of the lymph-canalicular system.

Fig. VII. is a surface view of part of a cornea of frog, prepared simply in nitrate

of silver. The corneal corpuscles themselves are not brought out. It is seen that a difference exists between the cornea of frog and kitten in the arrangement of the corneal corpuscles, or, what means the same, the lacunæ of the lymph-canalicular system ; in the former the corneal corpuscles (or lacunæ respectively) do not form groups as in the latter, but are more isolated, and anastomose with each other chiefly by processes.

Fig. III. A portion of tendon of mouse, fresh stained with hæmatoxylin. The rows of oblong tendon-cells are seen between the bundles of fibrous tissue; these latter are indistinctly marked. The cells are slightly shrunk and therefore appear discontinuous. Being flat and curved, as stated above, they present themselves in various aspects ; in some rows they are viewed from the surface, i.e. are broad ; in others they are viewed in half profile, i.e. are narrower, and still in others they are seen in profile, and appear therefore like staff-shaped bodies.

Fig. IV. From a tendon treated with dilute acid, in consequence of this the connective-tissue bundles have greatly swollen up. The fine processes coming off from the sides of the cell-plates are not represented. Some of the cells of the upper row show two longitudinal linear marks, those of the lower row show each one such mark. They have been explained on a former page as being due to each tendon-cell being composed of two or three small plates joining in one or respectively two ridges, according to whether the cells have to adapt themselves to the surface of two or three bundles.

Above the upper row is a fine elastic fibre. In both figures III. and IV. the nuclei of the adjacent tendon cells of one row are in the contiguous extremity. This is easily explained by their being numerous cells in which division of the cell and its nucleus into two takes place.

Fig. V. Transverse section through a group of three microscopic tendons of tail of mouse, after staining them first in chloride of gold and then in logwood.

The three tendons are contained in a common sheath of connective tissue, but each tendon has its own homogeneous elastic sheath. When isolated in the fresh state, and stained in nitrate of silver, it is seen that this elastic sheath is a membrane composed of a single layer of large endothelial plates.

In the transverse section of each of these tendons we recognise large dark masses, being the channels between the groups of the tendon-bundles in transverse sections, mentioned above as interfascicular channels ; these channels contain, besides the tendon-cells—not distinguishable here as such—also the albuminous fluid plasma, that in the fresh and living state circulates through them like through other lymph-spaces. This substance has here become stained deeply with chloride of gold, just like the tendon-cells, and hence these latter are not discernible separately. In connection with these channels are fine septa,—the fine dark lines in the drawing,—which represent the cement-substance by means of which the contiguous bundles are held together.

It is also noticed in this figure that the interfascicular channels are flatter near the surface of the tendons than in the depth.

PLATE VIII.

All figures of this plate, except fig. XV., are drawn under a magnifying power of about 450; fig. XV. about 350.

Fig. VIII. Three connective-tissue corpuscles of mesentery of newt, prepared first with chromate of ammonia and then with carmine. The distinction between the two substances, viz. hyaline ground-plate and intracellular network of fibrils, is very clear. The latter substance forms a larger or smaller accumulation at one side of the nucleus, with the network of which it is intimately connected, and is drawn out into the longer or shorter branched processes. Some of these resemble, at one point or other, membranous, not filamentous expansions.

Fig. IX. Vertical section through perichondrium and hyaline cartilage stained first with chloride of gold and then in logwood.

a. Loose connective tissue around perichondrium; the thin bundles of connective-tissue fibres leave between them relatively large spaces containing the connective-tissue cells; in most of them only the nucleus is brought out.

b. Perichondrium, composed of connective-tissue bundles; most of these being arranged longitudinally—especially in the right part of the figure—are all cut transversely. It is seen that here, just as in tendon, exist large spaces—interfascicular lymph-spaces—between groups of connective-tissue bundles; in these spaces lie the connective-tissue cells (their nucleus being shown here only); the small spaces passing from the large interfascicular spaces between the individual bundles contain the cement-substance uniting contiguous bundles.

c. Hyaline cartilage ground-substance containing the nucleated cartilage-cells.

Fig. X. From a preparation of the tail of tadpole, stained with chloride of gold and logwood.

m. Two migratory connective-tissue cells; the other cells are the ordinary branched cells, each with an oblong nucleus. Many of the processes of these corpuscles are not filamentous, but membranous: this is, however, not brought out well in the figure.

Fig. XI. Corneal corpuscles—viewed from the surface—of frog; chloride of gold specimen.

Fig. XII. The same of kitten; chloride of gold specimen. The distinction that had been pointed out in figs. VI. and VII. is also observable in these two figs. XI. and XII.; viz. that in frog the corneal corpuscles are more isolated than in kitten, they being here in many places grouped together.

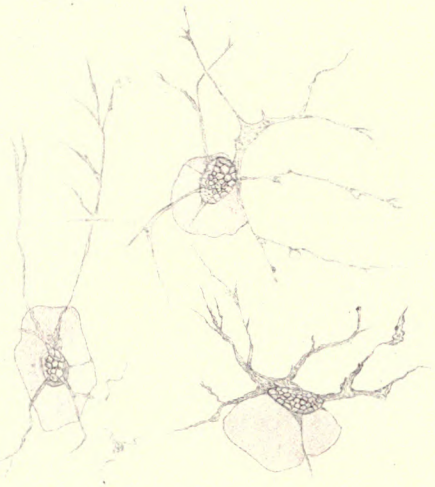

VIII.

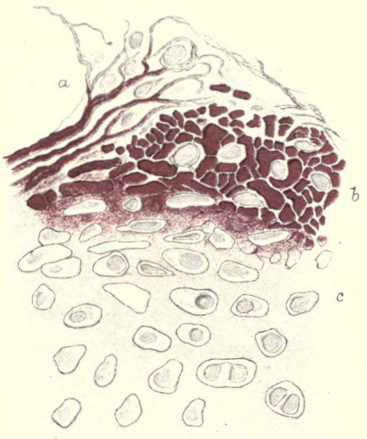

IX.

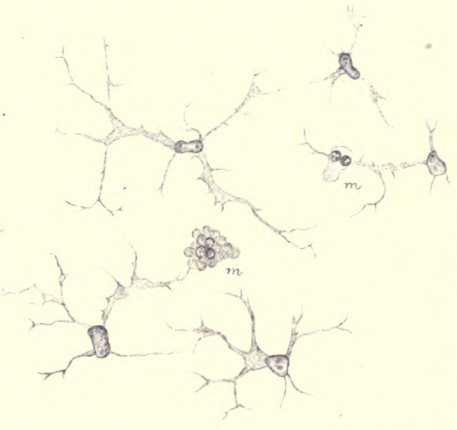

X.

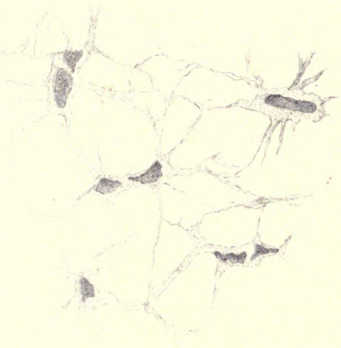

XI.

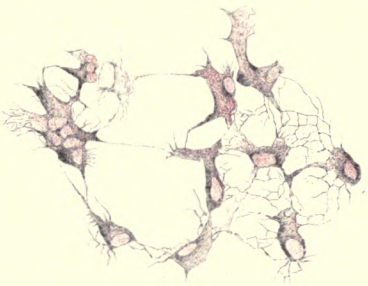

XII.

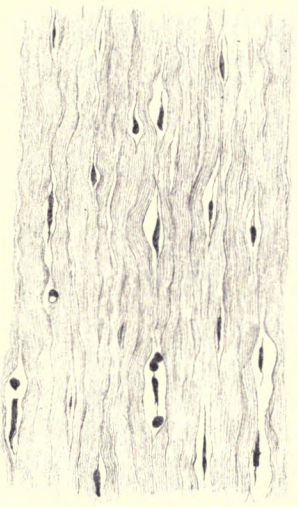

XIII.

XIV.

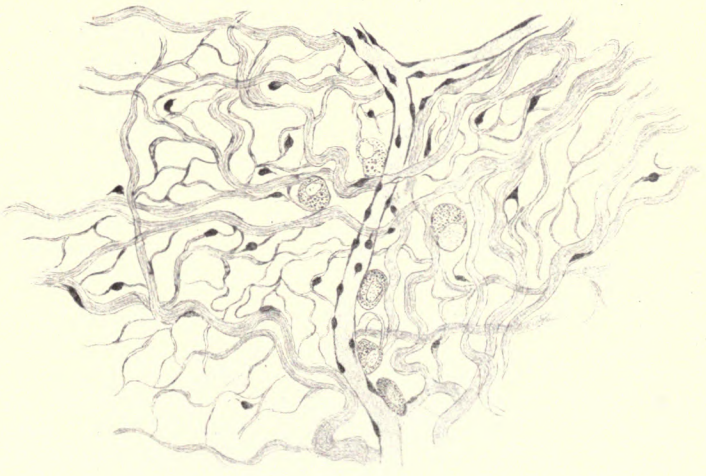

XV.

RLESF LIBRARY
OF THE
UNIVERSITY
OF
CALIFORNIA

In fig. XI. the substance of the corneal corpuscles is less stained than the nucleus or nuclei. The cornea had been slightly inflamed and we find many corpuscles possessing two nuclei, the originally single nucleus having undergone division.

In fig. XII. the nucleus is transparent as compared with the cell-substance.

If we compare these two figs. XI. and XII. with figs. VI. and VII., we have to regard the former as the positive images of the latter, i.e. the negatives; the former being the cells themselves, brought out by chloride of gold, occupy the spaces, i.e. the lymph-canalicular system of the latter, brought out by nitrate of silver. But it will be noticed that the corpuscles brought out by chloride of gold do not, as regards size, completely coincide with the lacunar system brought out by nitrate of silver. The very same difference may be shown to exist when comparing the lacunar system of a silver-preparation of mesentery—the surface-endothelium having been pencilled off before staining with silver—with the network of branched corpuscles of a gold specimen of the same membrane, viz. the latter is much smaller than the former. The explanation of this is very simple, it has been given above: in chloride of gold specimens we miss the ground-plate (see fig. VIII.), and we see only the nucleus with the substance that we called previously the intracellular network of fibrils.

Fig. XIII. From a vertical section through the tissue of cornea, hardened in bichromate of potash and stained in logwood.

The ground-substance is composed of bundles of fibrillar connective tissue. Between groups of bundles we see the interfascicular, or rather interlamellar lymph-spaces; these are viewed here in profile, the cornea being cut vertically, and the lymph-spaces, i.e. the lacunar system, having, as mentioned above, an expansion parallel to the surface of the lamellæ. The lacunæ of the lymph-canalicular system are represented here as large, widely-distended spaces, the canals by means of which they anastomose (see figs. VI. and VII.) are (except in two or three instances) not shown here for obvious reasons. A section placed vertically on figs. VI. and VII., and then viewed sideways, would only in very few instances show the canals connecting neighbouring lacunæ.

In our vertical section, fig. XIII., the lacunæ are abnormally distended, and in them are seen, in profile, the flattened nucleated corneal corpuscles; in some lacunæ we see in addition one or two round nuclei belonging to migratory cells.

As in the case of tendon and other connective tissues, so also in the cornea the interfascicular lacunar system contains, besides the connective-tissue cells, also the irrigating albuminous fluid-plasma; and this lacunar system represents at the same time the passages through which the amœboid corpuscles find their way.

Fig. XIV. From a transverse section through the external part of œdematous skin.

a. Lymphatic vessels lined with endothelium, seen here in profile. *b* is a section through a valve of a lymphatic. The ground-substance of the skin is composed of

connective-tissue bundles cut in different directions, some longitudinally, others obliquely, and many others transversely, this being due to the fact that in the upper part of the skin the connective-tissue bundles cross each other in all different directions. The flattened connective-tissue corpuscles are seen here mostly in profile as spindle-shaped or angular corpuscles. The cause of this latter appearance has been explained above, viz. the corpuscles are composed of two or three plates (chief and secondary plates, Waldeyer) according to whether they have to adapt themselves to the surface of two or three bundles. Now, the difference between a section through ordinary normal skin or mucous membrane and one through œdematous skin or mucous membrane is very conspicuous. It is this: in a section through ordinary skin the lymphatic vessels are generally difficult to recognise, being found collapsed, whereas in œdema they are distended by the excessive amount of exuded plasma and are therefore easier discernible. And further, in ordinary skin or mucous membrane, as in other connective tissues, the bundles are arranged in groups, and between them we find the interfascicular lymph-spaces intercommunicating with each other; in œdematous skin or mucous membrane we find the lymph-spaces extending between almost all individual bundles, the excessive amount of plasma present in the tissue having separated these from one another.

The œdema is usually, especially if of some duration, associated with emigration of colourless blood-corpuscles from the minute blood-vessels, and these (corpuscles) pass through the interfascicular lymph-spaces into the lymphatic vessels. But when, e.g. in acute inflammation, the migratory cells accumulate in too great numbers in these spaces —infiltration of the tissue with pus-corpuscles,—the connective-tissue bundles having become destroyed, the interfascicular spaces become all confluent, and in this way an abscess is formed.

In this figure XIV. the direct and open connection of the interfascicular lymph-spaces with the lymphatic vessels is clearly shown, and hence also the unity of the endothelial cells lining the lymphatic vessels and the connective-tissue corpuscles situated in the interfascicular lymph-spaces.

Fig. XV. From the omentum of a rat, stained with logwood, showing connective-tissue bundles of various sizes anastomosing with each other; numerous nucleated spindle-shaped-looking cells—endothelial cells and connective-tissue cells viewed in profile; a capillary blood-vessel showing the nucleated endothelial membrane forming its wall; several large coarsely granular cells, each with a large clear nucleus. These last-named cells correspond to the plasma-cells of Waldeyer; in the omentum of rat and mouse they become converted into fat-cells.

The membrana propria of the alveoli of secreting glands, e.g. lacrymal-, mucous-, salivary-, and other glands, is a network of nucleated, branched, and flattened connective-tissue cells (Boll, v. Ebner, Watney, and others).

CHAPTER V.

FIBROUS-CONNECTIVE TISSUE.

THE fibrous-connective tissue or white fibrous tissue has a very great distribution, as has been mentioned in the preceding chapter. It consists of more or less cylindrical bundles of different sizes; these, being arranged in smaller or larger groups, form broader or narrower trabeculæ. The bundles are generally more or less wavy, but this depends in a great measure on the state of contraction or expansion of the respective tissue of which they form part. Each bundle is composed of minute homogeneous fibrils, elementary fibrils. These are held together, within the bundle, by an albuminous and homogeneous cement-substance. By dissolving this the fibrils become distinct and isolated; permanganate of potash (Rollett), lime-water or baryta water, especially a 10 per cent. solution of chloride of sodium (Schweigger-Seidel), are used for this purpose.

The elementary fibrils swell up to a great extent in acids and alkalies, and after boiling. Hereby the bundles lose their fibrillar appearance and become more homogeneous. This effect is produced on account of the fibrils containing a substance which by boiling and dilute acids is converted into glutin or gelatin.

In many connective-tissue organs, as in tendon, fascia, subcutaneous tissue, subarachnoidal tissue, &c., the bundles are surrounded by a more or less complete hyaline elastic sheath. When therefore these bundles are treated with acids, i.e. are made to swell up, they show more or less numerous annular constrictions.

It has been mentioned in the preceding chapter that in many instances the connective-tissue bundles branch and anastomose. The branching means a division of a large group of fibrils into smaller groups, but not a division of the elementary fibrils; the anastomosing is due to an aggregation of two or more small bundles into one, but not to an anastomosis of the primitive fibrils. (See fig. XV. of Plate VIII.)

The fibrous bundles of connective tissue are arranged in various ways:

a) As fenestrated membranes, in the omentum and pleura mediastini of mammals, ligamentum pectinatum iridis, ligamentum denticulatum of spinal cord and the subarachnoidal tissue; here the bundles form lamellar expansions composed of larger or smaller trabeculæ, which branch and again reunite with one another.

b) Or, the bundles are arranged in parallel groups, as in tendons, ligaments and fasciæ; in the latter the lamellæ of parallel bundles may cross each other under various angles. To this category belongs also the cornea, although bundles of one lamella anastomose with those of the next upper or lower one.

c) In the loose cellular tissue, such as subcutaneous-, submucous- and intermuscular tissue, or in the connective tissue around vessels, nerves and glands, &c., the connective-tissue bundles are arranged as smaller or larger trabeculæ which branch and anastomose with one another, and crossing each other in more than one direction, they leave between them spaces of relatively considerable size,—the 'cells' of gross anatomists; and hereby the tissue possesses a certain loose and spongy structure. These spaces belong to the lymphatic system, as will be described in detail in a future chapter. By the injection of air, mercury, water or other fluids, or warm (fluid) gelatine (Ranvier) into this tissue, its bulk becomes of course enlarged, but the enlargement is uniform, owing to the air or fluids being able to spread into all its spaces ('cells'), these intercommunicating with each other. In œdema it is chiefly such loose connective tissue that swells up by the exuded plasma to a greater extent than other parts.

d) Dense connective tissue, as in skin, mucous membranes, many serous-, synovial- and kindred membranes, and dura mater, contains bundles of fibrous tissue very closely arranged, these being much branched and crossing each other in all different directions. In this manner a dense feltwork is produced. In serous- and synovial membranes, as well as in the dura mater, there are, however, parts, especially in the immediate neighbourhood of the large vessels, where the connective-tissue bundles possess a parallel arrangement.

In combination with fibrous-connective tissue we always find a greater or less amount of elastic tissue (yellow elastic tissue). This tissue differs in morphological and chemical respects from fibrous-connective tissue: elastic-tissue fibrils do not as a rule form bundles like the fibrils of fibrous-connective tissue; they are branched and anastomose with each other so as to form a real network; they do not swell up, but remain unaltered by boiling, acids or alkalies, and do not yield glutin but elastin; when torn they curl up at their ends.

The arrangement and distribution of elastic fibres is this:—

1) They are fine homogeneous and sharply outlined fibrils branching and anastomosing with each other in a network; the network is in some places close, in others very open, owing to the richness or scarcity of the number of the fibrils and their branches; the fibrils are straight or they are very wavy and twisted, but this depends in a great

measure on the state of contraction or expansion of the tissue in which those fibrils are contained. Of this character we find the elastic tissue in the skin and mucous membranes, subcutaneous and submucous tissue, serous-, synovial- and kindred membranes, the lungs, the loose connective tissue separating or connecting adjacent organs, and the intermuscular connective tissue. The matrix of elastic cartilage and the bulk of the mucosa of the true vocal cords (human) are made up of networks of these fibrils, and also in the coats of arteries and veins we find this form of elastic tissue, but not so abundant as other forms (see below). The relation of the network of elastic fibrils in many connective tissues is this: the elastic fibrils are situate on the surface of, but outside, the connective-tissue bundles, and in close proximity to the connective-tissue cells covering the bundles (Axel Key and Retzius).

2) Thick, cylindrical or bandlike, solid, sharply outlined homogeneous fibres branching and anastomosing into a network. They are present, in addition to those mentioned before, in the skin and mucous membranes, e.g. mouth and pharynx. In the inner superficial portion of the trachea and large bronchi they form, in connection with a small amount of fibrous-connective tissue, a special longitudinal layer. They obtain their greatest development in yellow ligaments, e.g. ligamentum nuchæ of ox, ligamenta flava, &c.: here they form the chief constituents, containing only a small amount of fibrous-connective tissue with the ordinary connective-tissue corpuscles. They are broader or narrower cylindrical or bandlike fibres richly branched and anastomosing; the fibres with their branches are arranged longitudinally, so that at first sight the tissue appears composed of parallel fibres; but in a thin section, especially when pulled out transversely, the branching and anastomosing of the fibres can be easily ascertained. By prolonged treatment with strong solutions of caustic potash Schwalbe has demonstrated that these fibres possess a thin sheath.

In larger blood-vessels, especially arteries, they obtain a great development. (See a later chapter.)

3) Perforated elastic membranes (membrana fenestrata, Henle); these result from the individual elastic fibres being very broad and anastomosing into a network with few and small meshes. Of this nature is the elastic tissue in arteries (intima and media), and also veins (media), as will be mentioned in the chapter on Blood-vessels.

4) Continuous elastic membranes. These membranes possess all the chemical characters of elastic tissue; they appear in many instances homogeneous, but under suitable conditions can be shown to contain bundles of minute fibrils. To this form of elastic tissue belong:

a) The anterior elastic membrane (Bowman) of the human cornea, situated im-

mediately underneath the epithelium of the anterior surface. In the cornea of the human eye this membrane is very conspicuous on account of its thickness; but in the cornea of the domestic animals it is of great thinness, and therefore not easily perceived.

b) The posterior elastic membrane of the cornea (membrana Descemeti); this membrane is on account of its great thickness everywhere easily perceptible; it appears quite homogeneous, but with the aid of a 10 per cent. solution of chloride of sodium bundles of minute fibrils can be demonstrated in it (Schweigger-Seidel).

c) Similar in structure is the subendothelial hyaline layer of the human serous membranes described by Bizzozero.

d) The thick homogeneous-looking membrane directly underneath the epithelium, lining the mucous membrane of the respiratory organs, especially the human nasal cavity (Heiberg), true vocal cords and trachea of man. In all these instances this subepithelial elastic membrane is without any nuclei, and contains the anastomosing branches of the lymph-passages of the epithelium and mucosa. (See chapter on Lymphatic System.)

A similar thick elastic membrane is present on the outer surface of the mucosa of stomach of cat (Zeissl); here the membrane is perforated by numerous fibres, blood-vessels, muscles, &c., ascending from the tissue underneath into the mucosa.

Elastic membranes of other organs (capsule of lens, sheath of muscle fibres, limitans interna and externa of retina, elastic membranes of Pacinian corpuscles) will be mentioned at the respective places.

The elastic membranes composed of endothelial plates (basement membrane, membrania propria of glands) have been mentioned in the preceding chapters.

Besides the fibrous connective tissue and the elastic tissue, there are other forms of connective tissue, in morphological respects closely related to both, although differing from them in some essential respects.

a) The gelatinous tissue (Virchow) present in the fœtal umbilical cord in an early stage as the so-called Wharton's tissue, the fœtal skin, the tissue of fœtal tooth-sac, the tissue in the rhomboidal sinus of the cord of birds, in the electric organs of fishes, and in different localities of other fishes and especially invertebrate animals, the tissue contained in the infraorbital fossa of young rabbits, in pathological conditions (myxomatous tumours), &c. The gelatinous tissue is a transparent jelly-like substance containing in the meshes of a framework a hyaline mucous substance. The tissue varies according to the nature of the framework, this being in some instances (early stage of fœtal umbilical cord or fœtal skin)

a network of cells and their processes; in the later stages the fœtal umbilical cord, although still of a gelatinous aspect, contains already numerous bundles of fibrous-connective tissue; in other instances it is composed of non-nucleated fibrous bands (fishes, invertebrate animals, &c.), and in a third group it contains, besides cells, blood-vessels and bands of connective-tissue fibres, also fat-cells in different states of development. In this last instance the gelatinous tissue is the precursor of fat-tissue, as is the case with the tissue of the infraorbital fossa of young rabbits and the fœtal subcutaneous tissue, and therefore, strictly speaking, should not be placed in the same group with the tissues mentioned before.

b) The network of homogeneous fibrils that forms the matrix of the central nervous system, including the optic nerve, the so-called neuroglia, will be considered minutely in a future chapter.

c) The reticulum of homogeneous membranes and filaments forming the matrix of lymphatic tissue, the so-called adenoid reticulum, will be considered in detail in connection with the lymphatic glands.

Both neuroglia and adenoid reticulum are in chemical respects neither identical with fibrous-connective tissue nor with elastic tissue.

The reticulated tissue representing the supporting framework in different glandular organs, e.g. the reticular tissue between the urinary tubes of cortex of kidney, the reticular tissue supporting the liver cells, the reticulum of the pulp of spleen, &c., does not form a special group, being a honeycombed structure composed of nucleated, membranous, branched, and anastomosing connective-tissue cells.

Fibrous-connective tissue is developed directly from embryonal connective-tissue corpuscles (Max Schultze, Brücke, Obersteiner, and others). These are at first spherical, then elongated, spindle-shaped cells with an oval nucleus. Each cell gives origin to a bundle of connective-tissue fibres (Breslauer, Boll), the nucleus gradually disappearing. But besides this mode of direct transformation of the original protoplasm of the cell into a bundle of connective-tissue fibres, there is another mode, consisting first in the production of a homogeneous (peripheral) substance by the embryonal cells themselves and subsequent formation of bundles of fibrous tissue in it (Henle, Rollett, and others).

The former, viz. direct mode of formation of bundles of connective-tissue fibres is to be observed in tendon, skin, intermuscular tissue, nerve trunks, loose cellular tissue, &c. In the umbilical cord and serous membranes there is, besides this, also the other, viz. indirect mode of formation.

In various abnormal conditions, as in chronic inflammation, tumours, certain specific diseases, &c., new fibrous-connective tissue is being formed in great masses. Its mode of formation is the same as in the normal (embryonal) state, being derived either directly or indirectly from cellular elements in the manner stated above.

The elastic fibrils are formed by the direct conversion of nucleated embryonal cells and their processes (Henle, Thin). The nucleus is lost as the development proceeds.

The neuroglia and the adenoid reticulum are developed in the same manner by the direct conversion of nucleated cells (see later chapters).

PLATE IX.

The figures of this Plate are drawn under a magnifying power of about 350.

Fig. XVI. This figure properly belongs to the chapter illustrated on the preceding Plate, for it represents corneal corpuscles of rabbit. The cornea had been inflamed and prepared with chloride of gold. In addition to the ordinary branched corneal corpuscles we find small cells, each with two or three nuclei; these cells are (migratory) pus-cells. In the figure it is seen that these pus-cells are oblong, and that they are in close proximity to the corneal corpuscles. The reason is simply this: the passages through which these pus-cells migrate are the same in which the corneal corpuscles are situated, viz. the lymph-canalicular system. When a pus-cell has to squeeze itself through a canal it must elongate its body; these canals being at the same time the spaces for the processes of the corneal corpuscles (see previous chapter), it follows that many pus-corpuscles *appear* connected with those processes; in reality they are only above or below them, but in the same canal.

Fig. XVII. (*a*) A layer of more or less sharply outlined, parallel, and wavy bundles of connective-tissue fibrils, from the mesentery of rabbit. On the surface of this layer is (*b*) a network of fine elastic fibres.

Fig. XVIII. (*a*) Branching and anastomosing bundles of fibrous-connective tissue. (*b*) Network of fine elastic fibres. From the mesentery of cat.

Fig. XIX. A bundle of fine connective-tissue fibres (*b*) ensheathed in an endothelial membrane (*a*) seen in profile. (*c*) Fine elastic fibres; they are not situated within the bundle of connective-tissue fibres, but on the surface of this and underneath the endothelium. From the subarachnoidal tissue of man.

Fig. XX. A portion of elastic lamella, dense network of fibrils, separated by teasing from the middle coat of aorta of rabbit, after being acted upon by acetic acid.

XVI.

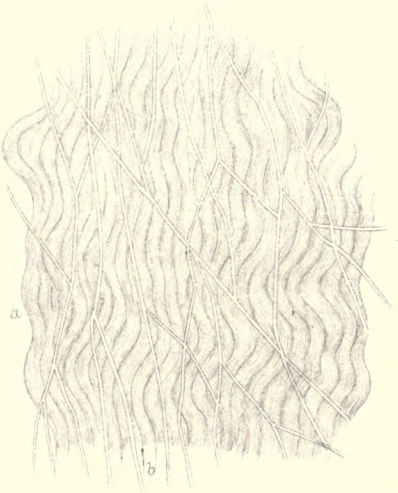

XVII.



XVIII.

XIX.



XX.

XXI.

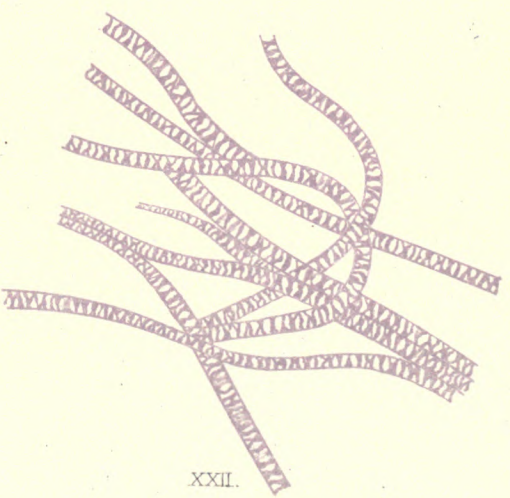

XXII.

REESE LIBRARY
OF THE
UNIVERSITY
OF
CALIFORNIA.

Fig. XXI. Network of thick elastic fibres, in a longitudinal section of ligamentum nuchæ of ox; the section had been treated with dilute acetic acid.

Fig. XXII. From a section through ligamentum nuchæ of giraffe. The preparation had been stained in hæmatoxylin and then teased out. The elastic fibres are here much thicker and bandlike; they possess within a distinct sheath irregular transverse thickenings.

CHAPTER VI.

ADIPOSE TISSUE.

ADIPOSE or fat-cell tissue in its ripe state possesses several characters which place it in a group with glandular tissue (Toldt, Klein). It is a tissue possessed of an afferent artery, one or more efferent venous branches, and a rich network of capillary vessels supplying the elements of the tissue, viz. the fat-cells. The meshes of the network are relatively small, in some places embracing only one, in others two or three elementary fat-cells. These latter are arranged, by means of connective tissue, in smaller or larger groups, lobules, and these again are aggregated into lobes. As in other gland-tissue, so also here each lobe and lobule have their respective branch of artery and vein (or veins).

The elements of ripe adipose tissue, such as occurs in continuous masses in the subcutaneous, submucous, serous, and subserous tissue, in the intermuscular and other loose cellular connective tissue, are the so-called fat-cells; they are closely aggregated, apparently spherical cells, containing a large fat-globule occupying the bulk of the cell. The protoplasm of the cell is reduced to a thin mantle surrounding that globule on all sides, and containing at one place an oblong more or less compressed nucleus. Between the fat-cells of a lobule there may be demonstrated, besides capillary blood-vessels from place to place, flattened nucleated connective-tissue cells. At the free edge of the lobules also a certain amount of fibrous connective tissue, in the form of thin bundles, can be traced between the fat-cells.

In some places, as in subcutaneous and submucous tissue, intermuscular and other loose connective tissue, the fat-cell tissue is derived from ordinary fibrous connective tissue in which the connective-tissue cells, having increased in number, become changed into fat-cells (Flemming); increasing in size, this tissue becomes richly vascularised. In other places, e.g. serous membranes, the great mass of the fat-tissue is derived from a peculiarly changed connective tissue (Klein); in many places (especially in connection with the large vessels) there appear in the connective-tissue matrix of the serous membrane patches, nodules or cords, which are made up of multiplying connective-tissue cells. As the number of the cells increases, the matrix in which they are embedded becomes transformed into a reticulum; lymph-corpuscles appear amongst them, and after the tissue has become richly vascularised by an afferent artery, efferent vein (or veins) and a rich network of capillaries, it resembles in morphological respects lymphatic tissue. The

serous membranes of many mammals and man possess in the young and adult state a considerable amount of this species of lymphatic tissue. In some animals it is found to have a greater development than in others; in some places it is arranged more in the shape of cords or patches, in others more as nodular masses along the larger branches of vessels which supply them with their vascular system. The small, i.e. the youngest cord, patch, or nodule, does not possess any vascular system, but this soon appears as that organ enlarges: first it is represented by a simple capillary loop derived either from a neighbouring patch or nodule, or directly from a larger vascular branch; then numbers of new capillaries are formed either directly in connection with the existing capillary vessel, or independently of this, from connective-tissue cells of the patch or nodule in a manner which will be described minutely in the chapter on Blood-vessels; one branch of the original capillary loop is changed into an artery, the other into a vein, and we have then a patch or nodule of lymphatic tissue possessed of its own system of blood-vessels. By elongating and fusing they (patches or nodules) form a longer or shorter cord. As has been mentioned in a previous chapter, generally one or occasionally both surfaces of these lymphatic structures are covered, not with the ordinary flat large endothelial cells, but with germinating cells.

In many instances these lymphatic structures have a long duration; they contain lymph-corpuscles, which are most probably produced in these structures by the connective-tissue corpuscles; we have then these structures acting like lymphatic glands. In other instances we find them only of a transitory character, being destined to change into fat-cell tissue; they then become deprived of their lymph-corpuscles, and the connective-tissue cells, forming the bulk of the nodule, patch or cord, are transformed into fat-cells. We have then here a tissue possessed of its special system of blood-vessels and at one time functioning as lymphatic tissue, at another as fat-cell tissue. In some animals (guinea-pig, rabbit) and man a great part of the tissue in question remains lymphatic tissue, except under very favourable conditions of alimentation, when it is transformed into fat-tissue; in others (carnivorous animals, mouse, rat) it is more readily changed into fat-tissue.

Besides these there are small masses (small groups) of fat-cells found in some places of the serous membranes, which (fat-cells) are embedded in ordinary fibrous connective tissue and are derived from ordinary connective-tissue cells.

In some connective tissues, as in the gelatinous tissue, mentioned in the preceding chapter, in the infraorbital fossa of rabbit and in loose cellular tissue, we find a similar condition, viz. vascularised groups of multiplying connective-tissue corpuscles preceding the appearance of fat in those cells.

In all instances the transformation of a protoplasmic connective-tissue corpuscle

into a fat-cell takes place in this way: there appear, in the protoplasmic substance of the connective-tissue corpuscle, small fat-globules, which increasing in number soon become confluent in one or two larger drops. The bulk of the cell becomes hereby, of course, greatly increased; while the cell-body is thus filled with one or two large fat drops, the nucleus is pressed into the periphery, this being now the original protoplasm of the cell-substance. In the ripe state the fat-cell contains one large fat-drop surrounded by a thin mantle of original protoplasm, in one place of which the oblong nucleus is to be seen. Thus the fat-cell may be described as a vesicle, whose wall is the original cell-protoplasm containing the nucleus, and whose contents is one large fat-drop.

During starvation the fat-globule of the fat-cell disappears, and its place is taken by a clear serous fluid. In waste also this fluid disappears, and the fat-cell returns to the state of a solid protoplasmic corpuscle whence it started.

In some instances fat-cells are formed also in other than the fixed connective-tissue corpuscles, viz. in the cells, which were mentioned in a former chapter as plasma-cells (Waldeyer), being larger than ordinary amœboid connective-tissue corpuscles, possessed of a single relatively large nucleus, and showing only slight amœboid movement. They contain occasionally coarse granules staining deeply blue in hæmatoxylin; these granules are converted into fat-globules, which gradually become confluent, and we have then a fat-cell that does not differ from the fat-cell above described. This is, however, not the typical mode after which fat-cell tissue is produced, but only an incidental formation of fat in plasma-cells, especially to be observed under favourable conditions of alimentation. In the omentum of mouse and rat isolated plasma-cells may be noticed to undergo this change; also in the mesentery, in the subcutaneous tissue, in the connective tissue surrounding large vessels and nerve trunks, occasionally also in the intermuscular tissue of the tongue and other organs, the same change may be noticed.

CHAPTER VII.

PIGMENT-CELLS.

PIGMENT-CELLS proper (Chromatophores) are nucleated and branched connective-tissue corpuscles, the substance of which is filled, more or less uniformly, with pigment-granules. Their distribution is greater in the lower than in the higher vertebrates, and varies in different organs; thus, for instance, the skin of lower vertebrates (fishes and amphibia) is by far the richest in pigment-cells, the internal connective tissues possess also a certain amount of pigment-cells, and the eye is supplied with pigment-cells in all vertebrates except albinos. The pigment-cells in the skin of lower vertebrates are as a rule flattened and larger than ordinary not-pigmented connective-tissue corpuscles; their pigment varies not only in its colour—being under the microscope black, yellowish, bluish, greenish, or grey—but also in the shape of its particles, these varying from very minute spherical or angular granules to large elliptical or irregularly shaped plates and clumps. The amount and distribution of pigment in a cell determines the deeper or lighter shade of its colour.

In the skin of lower vertebrates the pigment-cells in the state of rest are exceedingly richly branched cells, each with a nucleus, their dark (pigmented) branches anastomosing with each other and with those of their neighbours. The cell-substance seems, in some instances, to be almost entirely distributed in the pigmented processes, that is to say, there is not a conspicuous mass of pigmented matter as cell-body to be noticed around the nucleus.

The same holds good for the serous membranes of lower vertebrates where the network of pigmented cells forms more or less continuous sheaths around arteries and veins. In the tissue of the iris and chorioides, and in the suprachorioides of man, and especially of dark-eyed mammals (sheep, ox), the pigment-cells are flattened nucleated cells, in which a relatively large cell-body surrounding the nucleus gives off numerous filamentous or platelike processes anastomosing with each other and with those of neighbouring cells.

Pigment-cells alter their shape; they are contractile under various influences, being capable of gradually withdrawing their pigmented processes: first they change from richly branched cells into cells with fewer processes, then the number of processes becomes smaller and these at the same time less branched, and finally all the pigment is retracted into an oval or slightly angular or spherical mass. This change has been

shown, at any rate for the cutaneous pigment-cells, to take place under the influence of chemical, mechanical and electrical irritation; it is under the control of the nerves (Lister), and is influenced, as a reflex action, through the retina (Pouchet). The variation in the contraction of the pigment-cells of the skin in fishes and amphibian animals determines the change of colour observed in these animals (Leydig, v. Wittich, Brücke, v. Siebold, and others). The distribution of the pigment in a pigment-cell does not indicate the whole outline of the cell, and also the retraction of the pigment towards the centre, i.e. towards the nucleus, is not equivalent to a retraction of the cell-processes (Klein), inasmuch as only part of the cell-substance is retracted. It has been shown (Klein) that the substance of the pigment-cells when deprived of the pigment possesses a fibrillar structure, and interpreting this by the light of the experience on the structure of ordinary connective-tissue corpuscles—see Chapter IV. p. 29—it is probable that the contractile part of a pigment-cell, viz. that containing the pigment matter, is only the fibrillar substance, intracellular network of fibrils, as distinct from the groundplate. It thus becomes intelligible that the extent of the pigment does not indicate the outline of the cell, nor do all parts of the cell contract while the pigment is being retracted towards the nucleus.

Pigment granules are found, in the adult, in other organs than branched connective-tissue cells, as in the substance of hairs, in the deeper cells of the rete Malpighii of the epidermis, and in those of the epithelium of the mucous membrane of mouth of some mammals, in the endothelium lining the posterior surface of the iris and processus ciliares, in the epithelium lining the external surface of the retina, &c. In the superficial parts of the true skin in man and some mammals there are to be met with migratory connective-tissue cells containing a smaller or greater amount of dark brown pigment granules: it is highly probable that these migrants carry it to the rete Malpighii of the epidermis; also in the skin of lower vertebrates (batrachian animals) migratory pigment-cells have been observed.

PLATE X.

Fig. I. drawn under a magnifying power of about 90; fig. III., under one of about 30; figs. II. IV. and V., about 350.

Fig. I. From the omentum of cat, the blood-vessels of which had been injected with carmine-gelatin; it shows (*a*) minute artery, (*v*) minute vein; these two vessels are embedded in a cord of fat-cells (*b*) richly supplied with a network of capillary blood-vessels. The fat-cells are not represented as such, but their size may be recognised in most places, the meshes of the network of capillary blood-vessels not being larger than a fat-cell.

(*c*) Lymphatic nodules; only the nuclei of their cells are represented; they are richly supplied with capillary blood-vessels from the same artery and vein as the cord of fat-cells. These lymphatic nodules are here the precursor of fat-tissue.

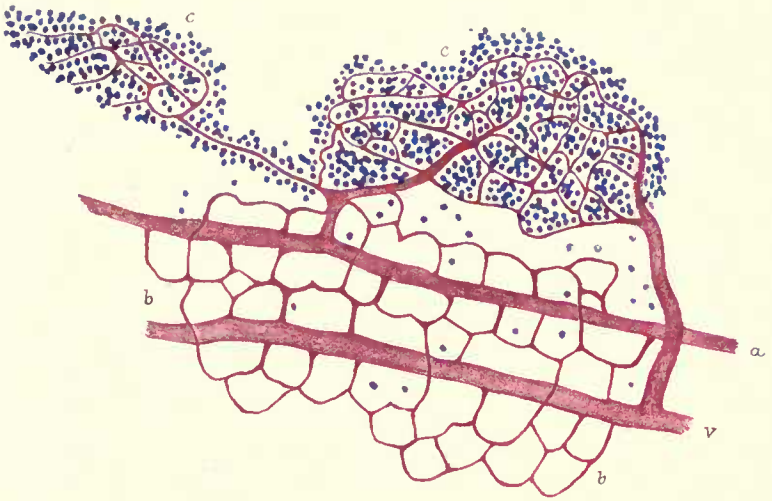

I.

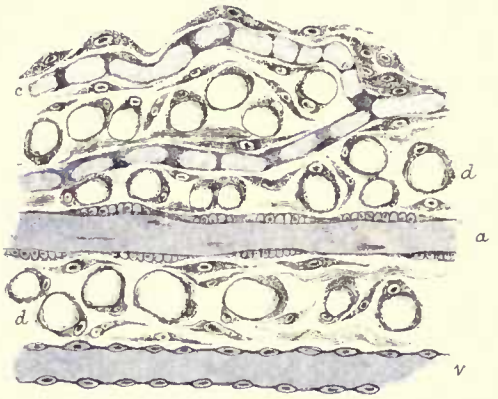

II.

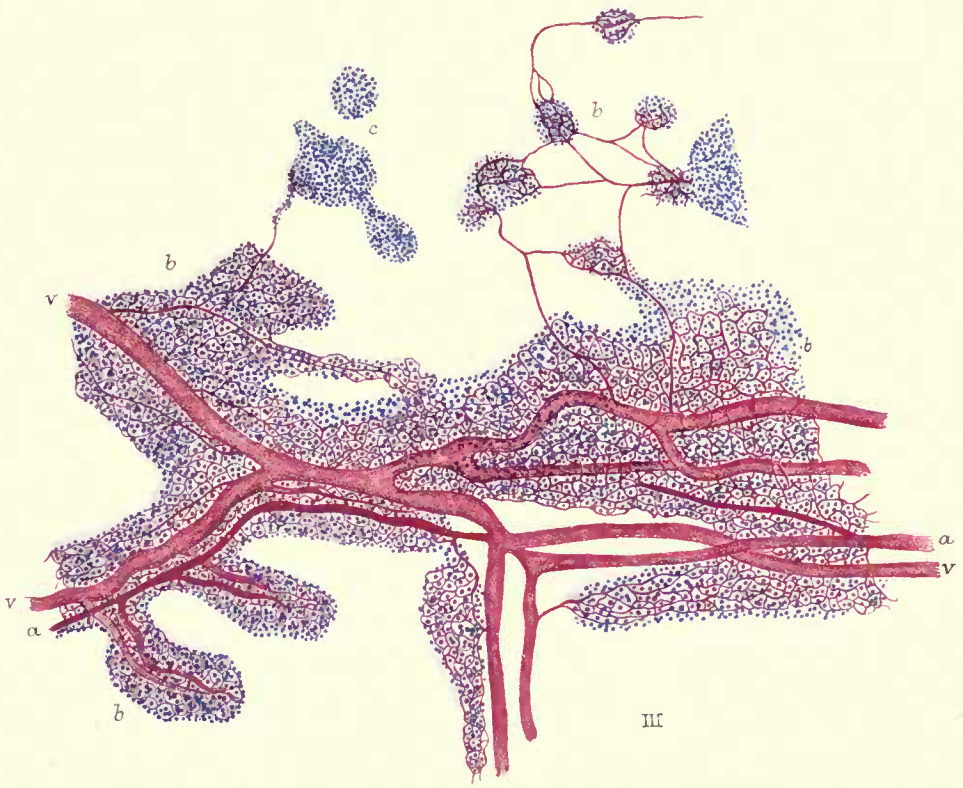

III.

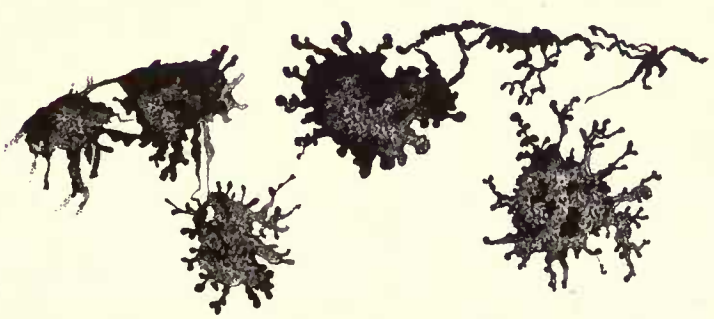

IV.

V.

REESE LIBRARY
OF THE
UNIVERSITY
OF
CALIFORNIA

Fig. III. From the omentum of guinea-pig, whose blood-vessels had been injected with carmine-gelatin: (*a*) artery, (*v*) vein, (*b*) cord-like and nodular masses of cells, richly supplied with capillary blood-vessels. There is no fat formed yet in these lymphatic nodules and cords. In the young examples of these (*c*) blood-vessels have not developed yet.

Fig. II. From the omentum of young guinea-pig:

(*a*) Minute artery.

(*v*) Minute vein.

(*c*) Capillary blood-vessels in the course of formation: they are not hollowed out yet completely, there being still left in them protoplasmic septa. As will be minutely described in the chapter on blood-vessels, the capillaries develope from nucleated cells, which become hollowed out; this process consists in the vacuolation of cells, each of these possessing one, two, or three vacuoles finally becoming confluent; gradually increasing they are brought in contact and ultimately fuse at their ends; or one cell grows out into a nucleated solid protoplasmic filament or cylinder, in which vacuoles appear; these increase in size and number, and ultimately fuse into one. The at first solid protoplasmic cylinder is thus transformed into a tube, the protoplasmic remains separating the vacuoles having all disappeared.

(*d*) The ground-substance contains numerous nucleated cells, some of them are more distinctly branched and more flattened than others, appear, therefore, more spindle-shaped. These cells become converted into fat-cells, their interior becoming filled with one, two, or more fat-globules and their nucleus being pressed to the periphery; so that in a fully-formed fat-cell we find one large fat-drop occupying the centre of the cell, and the original protoplasm, containing the nucleus, forming a mantle or cover round it.

Fig. IV. Flat pigmented branched connective-tissue cells, pigment-cells, from the sheath of a large blood-vessel of mesentery of frog. The pigment is not distributed uniformly throughout the cell-substance; being in some places collected in denser masses than in others, some parts of the cell look more black than others. Uncontracted state.

Fig. V. Pigment-cells of a similar preparation as the preceding figure, but the cells have withdrawn more or less their pigment into the cell-body; so that they appear smaller, more black, and less branched; somewhat contracted.

CHAPTER VIII.

CARTILAGE.

THIS represents another division of connective tissues. In cartilage, as in other connective tissues, the cells, cartilage cells, are to be distinguished from the ground- or intercellular substance. The former are oval or spherical, occasionally flattened and branched, nucleated cells; the latter varies in different cartilages, being in some quite hyaline, in others fibrous, and in others reticular; hence the division into hyaline, fibrous and reticular cartilage.

All cartilage, except the free surface of articular cartilage, is covered with a thin vascular connective-tissue membrane, the perichondrium, composed of fibrous connective-tissue bundles, between groups of which we find the interfascicular lymph-spaces, and in these the flattened connective-tissue corpuscles mentioned on former occasions.

A. HYALINE CARTILAGE.

Hyaline cartilage has a very wide distribution in the adult body, being present in some nasal cartilages, parts of sternum, ribs, larynx, and trachea; on the articulation surface of bone as articular cartilage, no matter whether this surface is part of a free articulation or not.

In most hyaline cartilages the cells are spherical or oval protoplasmic structures containing generally one spherical nucleus. The protoplasm of the cells contains numerous fibrils twisted and crossing each other so as to form a feltwork (Schleicher, Flemming). In embryonal cartilage (very probably also in growing cartilage of adult) this fibrillar protoplasm is contractile (Schleicher). Occasionally smaller fat-globules are present in the cell-protoplasm. The nucleus contains within its limiting membrane a more or less well-defined network (Flemming).

Each cartilage cell is placed in a cavity, lacuna, enclosed by a greater or smaller amount of hyaline ground-substance, a firm structureless substance yielding chondrin. The hyaline ground-substance around each cell represents a more or less polyhedral mass derived from the cartilage cell itself; so that we may consider a given section of hyaline cartilage as composed of an aggregate of blocks, more or less polyhedral in shape, being pressed against one another, each of which consists of a hyaline matrix and a cartilage cell placed in its centre.

On macerating hyaline cartilage in acids, the outlines of these blocks become occasionally discernible.

It has been shown (Tillmanns, Baber) that in the ground-substance of some adult hyaline cartilages (articular cartilage, cartilage of ribs) bundles of exceedingly minute fibrils can be demonstrated.

Hyaline cartilages differ amongst each other in the distribution of the hyaline ground-substance around the cells. Either the cells are surrounded by almost equal-sized masses of ground-substance as in hyaline cartilage of trachea and larynx of man and mammals, sternal cartilage of newt, &c.; or the distribution of ground-substance is less regular, as in some articular cartilages, being present around the cells in some parts in a larger amount than in others. Again, in some parts of one and the same cartilage, the cells are placed much more closely, the hyaline ground-substance being much less abundant, than in others; comparing, for instance, the parts near the edge or free surface of a cartilage with the deeper parts, we notice that the cells lie much closer together in the former than in the latter.

When the cells are so closely placed together that hardly any, or at any rate no conspicuous amount of, hyaline ground-substance is to be noticed, the cartilage is called parenchymatous cartilage; embryonal cartilage at an early stage, the marginal parts of some adult cartilages, and certain other cartilages are of this nature.

In the fresh and living state the cartilage cells are filling up almost entirely their respective lacunæ, but after death, and especially after reagents, they shrink away from their wall in a greater or lesser degree, and are converted into irregular-shaped, angular or even star-shaped masses. Under these circumstances a delicate homogeneous limiting membrane becomes visible, forming the boundary between the lacuna and the hyaline ground-substance. In growing cartilage this limiting membrane becomes gradually thickened and represents a special layer of hyaline substance formed from the periphery of the cell-substance. In such cartilage we therefore distinguish two different parts of the hyaline ground-substance, viz. one portion that is the general matrix, and another that forms a thinner or thicker *capsule* directly around the cartilage cells (Kölliker). The former is older than the latter, this being more recently formed.

In growing cartilage the cells undergo division: the cell that is to divide enlarges, its nucleus divides—cartilage cells with two nuclei; then the cell-substance divides, and thus two daughter-cells are formed.

In some cartilages the two daughter-cells very soon give origin to a new generation, thus forming a group of four cells; or to two generations successively, thus forming a group of eight cells; in others the first two daughter-cells, before again dividing, become separated by a considerable amount of hyaline matrix derived from them.

The irregular distribution of hyaline ground-substance around the cartilage-cells, mentioned above, is in a great measure due to some cartilage-cells, or groups of them, undergoing a more rapid increase in number, and hence are surrounded by less hyaline ground-substance than others.

It is doubtful whether in the process of reproduction the division of the cell-substance is *always* caused by a septum in conjunction with the capsule, and therefore it is also doubtful whether the daughter-cells are primarily disconnected from each other, being enclosed in their separate lacuna (Leidy, Claparède, Heidenhain, and especially Schleicher), seeing that in many instances the first two daughter-cells, and even a group of cartilage cells, may be seen aggregated within a common lacuna.

The ground-substance of hyaline cartilage is not altogether solid, but contains numerous fine channels permeating it (Bubnoff); these channels form the anastomosing canals between neighbouring lacunæ (Heitzmann, A. Budge). Arnold has shown that the capsule of each cartilage cell is permeated by numerous very fine radiating canals. Thus the hyaline cartilage possesses, just like fibrous-connective tissue, an anastomosing system of lacunæ and canals (A. Budge, Arnold, Nykamp), which will be mentioned in the chapter on the Lymphatics as forming the lymph-canal system of the hyaline cartilage in connection with the lymphatics of the perichondrium. Near the perichondrium the cartilage cells become flattened and smaller than those of the depth, and in some localities, e.g. near the surface of articular cartilage and near the junction of this and the synovial membrane, are even branched (Hüter, Albert, Rayner), and in the latter place form a direct connection with the branched connective-tissue corpuscles.

A peculiar arrangement of cartilage-cells—viz. in more or less paralled rows—exists in the hyaline cartilage that unites the diaphysis with the epiphysis of long bones. This is called ossifying or, better, intermediary cartilage, and will be more particularly noticed, in connection with the growth of bone, in the next chapter.

The ground-substance of hyaline cartilage becomes occasionally, especially in the process of development of bone in cartilage, in advancing age, or under pathological conditions, the seat of a deposit of lime matter, calcification of cartilage, in the form of opaque roundish angular or irregularly shaped masses. The deposit of lime matter commences next to the cartilage cell (Ranvier).

No nerves or blood-vessels have been seen in hyaline cartilage except those of its perichondrium.

B. Fibrous Cartilage.

This form of cartilage is also called white fibrous- or connective-tissue cartilage. It occurs as cartilagines interarticulares, ligamenta intervertebralia, cartilago symphysis

pubis, sesamoid cartilages, the cartilages forming the margin of a fossa glenoidalis, &c. In all these instances the ground-substance is composed of bundles of ordinary fibrous tissue, forming occasionally more or less distinct lamellæ, which in a few instances (ligam. intervertebr. and cartilago symphysis pubis) possess a concentric arrangement. On the surface of the bundles, or rather of groups of bundles, are placed, similarly as in tendon or fasciæ, rows of slightly flattened elastic cells (Boll), each with a round nucleus and *enclosed in a distinct capsule.* As a general rule, where this form of cartilage is present in large and continuous masses, there is no hyaline cartilage substance to be seen around the cells; but when it is interspersed in tendinous tissue, as in the tendo Achillis, near the insertions of tendons on bone, besides the above form, also isolated cells or groups of them may be seen surrounded by a smaller or larger amount of hyaline matrix.

When tendinous tissue passes into fibrous cartilage, as where tendinous tissue is fixed on the fibrous cartilage (ligamenta intervertebralia) or in the cartilagines sesamoideæ of tendons, the bundles of connective tissue of the tendon pass without interruption into those of the fibrous cartilage, and so do also the cells, retaining their arrangement in rows, and their relation to the surface of the group of bundles, but the cells, besides being less flattened at the point of transition into the fibrous cartilage, become invested, as mentioned above, in a thin capsule.

At the point of transition of fibrous into hyaline cartilage, as at the margin of the ligamenta intervertebralia, or the cartilago symphysis pubis, the fibrous matrix of the former passes insensibly into the hyaline substance of the latter, and the cells of the one into those of the other; when entering the hyaline cartilage, the cells of course change their shape, losing their flattened character, and their arrangement is no longer in rows.

C. Reticular Cartilage.

This is also called yellow or elastic cartilage. It occurs in the ear-lobe, larynx (epiglottis, cartilagines Wrisbergi and Santorini, the cartilaginous nodule or rod occasionally found in the true vocal cord) and tuba Eustachii. Reticular cartilage in the adult state is hyaline cartilage permeated by elastic fibrils. These are arranged so as to form the trabeculæ of a reticular or spongy framework; within the trabeculæ the elastic fibrils branch repeatedly, and anastomose with each other and cross one another in all directions. The meshes of the reticular framework contain the cartilage-cells singly or in groups, surrounded by a smaller or larger amount of hyaline cartilage substance.

Different cartilages of this species vary in the relative amount of hyaline ground-

substance and elastic framework, and the same may be said of one and the same reticular cartilage in different states of development. They all commence as hyaline cartilage enclosed in perichondrium; as development advances numbers of elastic fibres appear in the hyaline ground-substance; these branch and anastomose with one another. In a still further stage the networks of elastic fibres reach such an extent that they constitute a conspicuous part of the ground-substance, forming the network of trabeculæ, as described above. The hyaline cartilage-substance is now limited only to the meshes of the reticular framework containing the cartilage cells.

In the cartilaginous nodule, present in some instances near the margin of the human true vocal cord, we find the elastic fibres not arranged so as to form a reticular framework of trabeculæ, but permeating the cartilage as a uniform network of fibrils.

Examining sections through the epiglottis of children, we find the reticular framework of elastic fibres not reaching quite up to the superficial part, viz. that next the perichondrium, this (superficial part) being still almost entirely composed of hyaline substance. The cartilage is, in children, not a continuous plate, as usually represented, but in many instances consists of several isolated plates placed in a longitudinal series. As growth proceeds they become gradually confluent into a reticulate plate. In the epiglottis of some mammals (dog, cat, rabbit) a great portion of the reticular framework of elastic fibres does not contain hyaline cartilage in its meshes, but fat-cells singly or in small groups.

As in ordinary hyaline cartilage, so also in reticular cartilage, we meet with a perichondrium composed of vascular fibrous connective tissue and with the flattened connective-tissue corpuscles in the interfascicular spaces.

A communication, by means of broader or narrower canals, between the interfascicular spaces of the perichondrium and the lacunæ of the cartilage cells, mentioned in ordinary hyaline cartilage, exists also in reticular cartilage. Here the lacunæ of the cartilage cells anastomose with each other throughout the cartilage.

PLATE XI.

Figs. I. and III. drawn under a magnifying power of about 350; fig. II., about 90; figs. IV. and V., about 150; figs. VI. and VIII., about 350; and fig. VII., about 450.

Fig. I. From a longitudinal section of tail of mouse; portion of intervertebral fibrous cartilage (connective-tissue cartilage) viewed from the surface. Bundles of fibrous-connective tissue in two layers crossing each other at a right angle; between, or respectively on, the bundles are roundish or oblong cartilage cells, each with a clear nucleus; the cells are each enclosed in a capsule, and are flattened when viewed in profile.

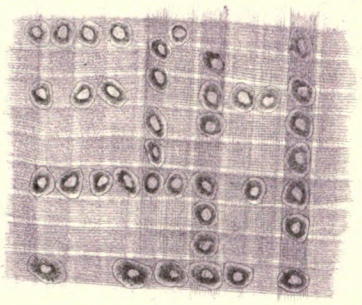

I.

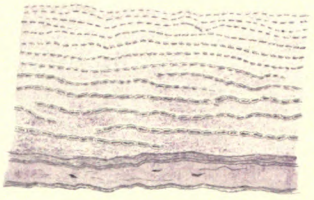

II.

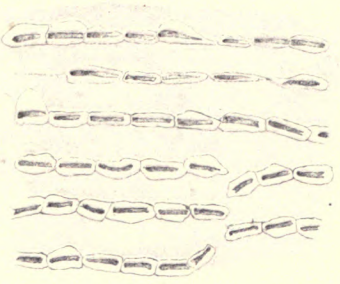

III.

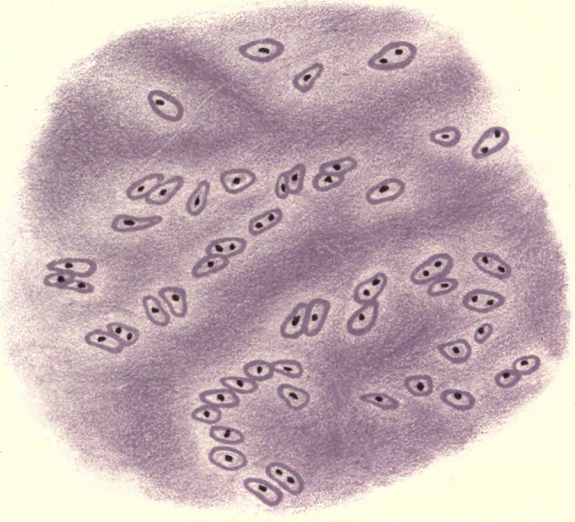

IV.

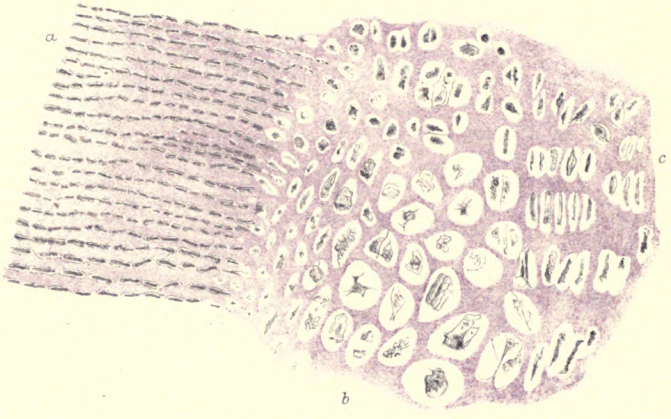

V.

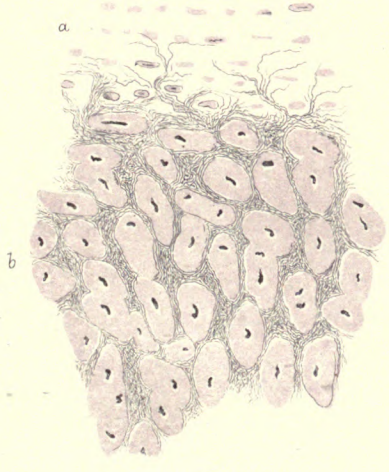

VI.

VII.

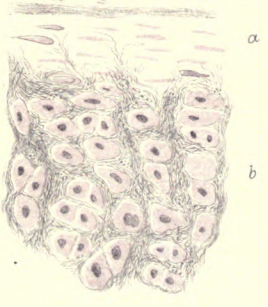

VIII.

E. Noble Smith fecit

Mintern Bros imp

REESE LIBRARY
OF THE
UNIVERSITY
OF
CALIFORNIA.

Fig. II. Transverse section through the same intervertebral cartilage. This being composed of concentric lamellæ (of fibrous tissue) arranged around a central cavity filled with gelatinous substance, shows in a transverse section parallel strata. The lower edge of the figure is the part next that central cavity, the lamellæ are here less distinct, and this part becomes more deeply stained in logwood. Between the lamellæ are the cartilage cells, arranged in rows. The cells are in this and the following figure III. represented as seen in profile; being flattened, they appear staff-shaped. As figure III. (higher magnifying power) proves, each cell lies in a capsule. A distinction between nucleus and cell-substance is not indicated in this drawing.

Fig. IV. Ordinary hyaline cartilage of trachea of a child. The cartilage cells are enclosed singly or in pairs in a capsule of hyaline substance. The distinction between nucleus and cell-substance of the cartilage-cells is not brought out, owing to the low magnifying power under which the drawing was made. This capsule of hyaline substance is the most recently formed part of the cartilage matrix. The rest of the hyaline matrix shows a differentiation into a less stained substance in the vicinity of the cartilage cells and their capsules, and a more deeply tinted part, farther away from the cartilage cells. The cause of this is not easily ascertained.

Fig. V. From a longitudinal section through tail of mouse, showing the transition of fibrous cartilage (*a*) into ordinary hyaline cartilage (*b*), and this again into intermediary cartilage (*c*); in this latter the cartilage-cells are arranged in vertical rows; it corresponds to the intermediary cartilage placed between epiphysis and diaphysis of long bones (see chapter on Bone). The fibrous nature of the matrix of (*a*) is, on account of the low magnifying power, not shown. The cartilage cells of (*b*) and (*c*) are much shrunk.

Fig. VII. From the same preparation as fig. IV., but under a higher power, representing a group of cartilage cells. Some of these cells possess one nucleus, others two. It is here seen that the capsule of hyaline substance is derived from the cell-substance, owing to a peculiar change of its periphery.

Fig. VI. From a vertical section through the reticular (yellow or elastic) cartilage of epiglottis of a child.

a. Perichondrium; the connective-tissue bundles forming the matrix of this membrane are not represented, only the flattened (therefore in profile staff-shaped) nuclei of the connective-tissue corpuscles are shown here.

b. The part of the elastic cartilage next the perichondrium. The matrix, composed of networks of minute fibrils, is arranged as a network of trabeculæ; in the meshes lie cartilage-cells embedded in hyaline (stained) substance. The cell-substance of the cartilage-cells is not well shown here, and their nucleus is much shrunk.

Fig. VIII. From a vertical section through the elastic cartilage of ear-lobe of pig. The explanation is here the same as in fig. VI.

In both these instances, viz. figs. VI. and VIII., the cartilage-cells are embedded in hyaline substance; it has been, however, omitted to represent the cells as situated in lacunæ, which anastomose with each other by finer or broader canals. The same communication exists also between the lacunæ of the cartilage-cells and those of the cells of the perichondrium. In this latter place they are the interfascicular spaces, as has been figured in fig. IX. of Plate VIII., and mentioned on p. 32.

CHAPTER IX.

BONE TISSUE.

Bone or osseous tissue forms the third section of the group of connective tissues, fibrous tissue, including elastic tissue, being one, and cartilage the other section. Osseous tissue has, in the adult, a greater distribution than either of the other two, forming the whole skeleton and part of the teeth, the cement; in lower vertebrates it is found, in addition, also in other parts, as skin, sclerotic membrane, &c.

As in other connective tissues, so also in bone we distinguish the ground-substance, or matrix, from the cells, bone corpuscles, embedded in it. The matrix is a firm brittle substance uniformly impregnated with insoluble inorganic salts, chiefly lime salts (carbonate of lime, basic phosphate of lime, magnesia, &c.); it appears transparent when examined in a thin section under the microscope. By adding acids to it, the insoluble lime salts are converted into soluble ones, and the bone ground-substance is thus gradually freed of them. The organic basis of the ground-substance, the ossein, presents itself, under these conditions, as a dense mass of minute fibrils, arranged either parallel or interlacing each other in a complex manner or joined in a network. The arrangement of these fibrils into well-defined groups determines the lamellar nature of the ground-substance (v. Ebner). These fibrils comport themselves in chemical respects like fibrous connective tissue, swelling up by the action of acids, and yielding, when subjected to boiling, glutin or gelatin.

The bone corpuscles are more or less elongated lacunæ possessed of numerous fine branched and unbranched canals, by means of which neighbouring lacunæ anastomose with one another. The processes pass in all directions, and are more or less wavy and twisted. Each lacuna with its canals contains a flattened nucleated protoplasmic cell, the bone cell proper, possessed of numerous fine processes. The relation between the bone lacuna and canals, on the one hand, and the bone cell and its processes, on the other hand, is precisely the same as that mentioned of the connective-tissue corpuscles of the cornea (see Plates VII. and VIII. p. 30), viz. the lacunæ with their anastomosing canals form one intercommunicating system of spaces, the lymph-canal system, lined with the flattened nucleated branched and anastomosing bone cells.

The osseous ground-substance possesses in most instances lamellar structure, the lamellæ being then separated by rows of the oblong-bone corpuscles. The corpuscles

placed between two contiguous lamellæ anastomose by fine transverse processes; owing to the great number of these processes the lamellæ possess a fine transverse striation. In some bones, as in microscopically thin bone-plates, the ground-substance does not exactly present the lamellar structure, showing an arrangement in band-like stripes; the bone corpuscles are then distributed more or less regularly between these bands.

There are two principal modes of arrangement of osseous tissue: (A) as compact, and (B) as spongy substance. The bone-matter surrounding the central or marrow cavity of the shaft of all long bones, and the outer crust of all short and flat bones, is compact substance; whereas the spongy network of bone lamellæ and bone trabeculæ, containing in its meshes vascular marrow, is present in the centre of the epiphysis and in the extremities of the diaphysis of long bones; the diploë of short bones and that of flat or tabular bones is likewise made up of spongy bone-substance.

A. In the compact bone-substance we distinguish the following parts:—1. Haversian canals: these are fine canals of various lengths pervading the compact substance in a longitudinal direction, and anastomosing with one another by more or less oblique or transverse branches; they open not only into the central or marrow cavity (or cavities) of the bone, but also on the outer free surface. Near the marrow cavity the Haversian canals are larger than those next the outer surface. Each Haversian canal contains a blood-vessel, one or two lymphatics, and, according to its size, a greater or lesser amount of connective tissue, which is identical with that of the tissue of the marrow, to be described below. 2. Bone lamellæ and the corresponding bone corpuscles between them. The bone corpuscles next to the Haversian canals, by their canaliculi, freely anastomose with the lymphatics of the latter (A. Budge).

The lamellæ possess in the compact substance of human bones the following typical arrangement:—

a) Concentric or Haversian lamellæ directly surrounding the Haversian canals. Each of these canals possesses its own system of such concentric lamellæ. Their numbers vary in different parts, from four to fifteen being found in one system. The number of lamellæ is always smaller near the external surface of the bone than in its deeper parts.

The fine radiating striation of these concentric lamellæ is owing, as has been explained above, to the numerous fine canaliculi passing between the neighbouring bone corpuscles.

b) The interstitial or ground lamellæ. The lamellæ interposed between the Haversian systems of concentric lamellæ form also groups running in various directions more or less curved: they are the interstitial or ground lamellæ. The size of these groups

depends of course on the closeness of the position of the Haversian systems, being very small when these latter are in almost immediate contact, and larger when they are further apart.

c) Those groups among the interstitial lamellæ which possess a direction parallel to the surface of the bone are designated under the special name of the circumferential lamellæ. They are best seen near the external free surface of adult long bones (Tomes and de Morgan).

Not only in the compact substance of long bones, but also in that of short and flat bones, we find the above arrangement of the bone lamellæ, provided the thickness of the bone is sufficiently great to permit of it; but when, as in some instances of short and flat bones, the compact substance forms only a thin cortex, the bone lamellæ are reduced to groups that run parallel to the surface.

B. In spongy bone the lamellæ are arranged as larger or smaller groups, branching and anastomosing so as to form a network of broader or smaller plates and trabeculæ; the meshes of this network, viz. the marrow cavities, intercommunicate with each other, and are filled with a very vascular connective tissue of a peculiar structure, to be described below as red marrow. The bone corpuscles between the lamellæ of the above plates and trabeculæ anastomose by means of their canaliculi with the marrow cavities.

Spongy bone-substance varies in different parts, according to the manner of arrangement of its plates and trabeculæ; thus, in the extremities of the shaft of long bones the meshes are pre-eminently oblong in a longitudinal direction, and hence the spongy substance when viewed with the unaided eye or a lens appears longitudinally striated.

The lamellæ of compact substance are perforated by more or less perpendicular fibres, the perforating fibres of Sharpey. They are fibrous bundles, and run either singly or in groups, and, just like the lamellæ, are impregnated with lime salts. As will be described below, they are present in all bone developed in connection with the periosteum, and they themselves owe their origin to this latter, hence the perforating fibres in the adult are still connected with the periosteum (Kölliker). Some of the perforating fibres are very fine, and of the nature of elastic tissue (H. Müller, Schäfer).

Besides the branched cells situated in the lacunæ and canaliculi of the ground-substance, and the vessels mentioned in the Haversian canals, there are two other soft tissues to be considered in connection with bone, viz. the periosteum and the marrow.

The *periosteum* is the layer of tissue covering the free surface of a long, short, or flat bone. It consists in all instances of (*a*) an external dense, and (*b*) an internal loose layer.

a) The external layer is a dense fibrous tissue, hence it is called the fibrous layer. In some bones it is thin, and composed of a single layer of bundles of

fibrous tissue; in others the bundles are arranged in two or more layers. Between the groups of bundles, viz. in the interfascicular spaces, we meet with the ordinary flattened connective-tissue corpuscles. A limited number of capillary blood-vessels supply this fibrous layer. *b*) The internal layer, or osteogenetic layer, contains a plexus of more or less slender bundles of connective-tissue fibrils; embedded in it are numerous capillary blood-vessels and a great many cells, each of which possesses a round or oval nucleus. The cells vary in shape, being either spherical, oval, spindle-shaped, or branched. They occupy the meshes between the fibre-bundles. In some places the plexus of these is very regular, and their meshes are completely filled with the cells. In growing bone we find a network of (young) bone lamellæ, terminating in the shape of pointed trabeculæ within the osteogenetic layer of the periosteum; these young bone lamellæ are in many places covered with an epitheloid layer of those cells, called osteoblasts (Gegenbaur). The osteoblasts are concerned in the formation of these young bone lamellæ, as will be described minutely below.

The *marrow* contained in the cavities of bone is of a twofold nature, yellow and red. Both possess a rich supply of blood-vessels (arteries, veins, and capillaries), of which even the largest branches are notable for their exceedingly thin wall. The yellow marrow filling the central cavity of long bones is chiefly composed of fat cells, and hence its yellow appearance; between these are membranes of flattened connective-tissue cells, and various numbers of polyhedral, spherical, or oval cells, each with one or two nuclei. These latter represent the marrow-cells proper; they resemble lymph corpuscles as regards size and aspect. Red marrow is the vascular substance filling the meshes of spongy bone; it contains only few fat cells, and is chiefly made up of marrow cells. Amongst these there are in many localities, as in ribs, bodies of vertebræ, extremities of diaphysis of long bones, peculiar cells, each of which is slightly larger than a coloured blood-corpuscle, and whose substance is of a uniform yellowish-green tint, like that of a coloured blood-corpuscle. They contain, in addition, a nucleus. They are supposed to be transitional forms between marrow-cells and coloured blood-corpuscles (Neumann, Bizzozero).

If this be the case, the marrow of spongy bone has the important function of the formation of coloured blood-corpuscles. That the marrow of bones, especially the red marrow, has an intimate relation to the lymphatic glands is made probable by the fact that the former is found frequently diseased with the latter.

Conspicuous amongst the marrow cells, especially in red marrow, are the multinuclear giant cells (myeloplaxes, Robin); their function and their relation to bone and cartilage will be mentioned below in connection with the development of bone. All these cells show amœboid movement when examined under suitable conditions.

Where spongy bone is in immediate contact with hyaline cartilage, as is the case in the apophyses and extremity of the shaft of long bones, in some parts of short and flat bones there exists a peculiar relation between the two tissues. Passing from the hyaline cartilage into the spongy bone the following layers may be distinguished :—

1) After passing the *ordinary* hyaline cartilage we enter into a broader or narrower layer of hyaline cartilage, in which the lacunæ for the cartilage cells are greatly enlarged, and hence the hyaline ground-substance is much reduced in amount; the cartilage cells themselves are very transparent, and their nucleus much swollen; in many instances their disintegration has commenced. This layer of 'large cartilage lacunæ' is for obvious reasons more transparent than the other hyaline cartilage, and hence is easily recognised even on inspection with the unaided eye.

2) In the next layer the lacunæ of the cartilage cells become more or less confluent, and the cells themselves are seen gradually to break down into irregular amorphous matter, the hyaline ground-substance of the cartilage becoming at the same time impregnated with lime-salts, i.e. calcified. This and part of the following layer represent what is sometimes called the *zone of ossifying cartilage*; but as the cartilage does not ossify—that is to say, is *not converted into bone*, but is merely calcified—it should be more appropriately called the *zone of calcified cartilage.*

3) In this layer the lacunæ of the previous zone are large intercommunicating cavities filled with marrow, chiefly capillary blood-vessels and marrow-cells. The blood-vessels form loops, and do not pass into the previous layer.

The spongy network of hyaline ground-substance separating the cavities—marrow-cavities—is also here calcified.

We speak of the parts of the framework of this and other spongy matter as 'trabeculæ.'

The marrow cells next the trabeculæ of calcified cartilage arrange themselves so as to form a more or less continuous epitheloid covering, osteoblasts, the individual cells being either oblong, or spherical, or branched; they are slightly larger than the other cells of the marrow cavities. Amongst the osteoblasts are multinuclear giant cells.

Passing on towards the depth, there appear thinner or thicker laminæ of osseous substance *on the surface of the calcified cartilage trabeculæ*; and the further we pass the more continuous do these osseous laminæ become—that is to say, the more perfectly do the *calcified cartilage trabeculæ become covered with osseous substance* (bone matrix and bone corpuscles); the calcified cartilage diminishes in amount as a greater depth is reached.

4) Finally, we arrive at a spongy substance that possesses all the characters of spongy bone, but differs from this in so far as its trabeculæ are not so thick, and as they include,

from place to place, in their centre a thinner or thicker, longer or shorter, remnant of unabsorbed calcified cartilage. The surfaces of the now osseous trabeculæ are covered with osteoblasts, among which multinuclear giant cells are still to be met with.

The different layers described in the preceding are not sharply defined from, but gradually merge into one another. Their thickness and distinction vary in different bones; it is best marked in long bones, where the articular cartilage joins the spongy bone of the epiphysis, and at the point of contact of the intermediary cartilage and the spongy bone of the extremity of the diaphysis. In the latter instance the character of the layers is one of a distinctly longitudinal design, owing to the peculiar nature of the intermediary cartilage.

This cartilage contains longitudinal rows of cartilage cells. The individual cells are more or less distinctly flattened in a transverse direction. Near the distal end, that is the end further away from the diaphysis, the cartilage cells are more flattened and more closely placed within the same row than at the proximal end; they are at the same time conical, and so placed within the row that with their thinner part—the wedge of the cone—they are, as it were, pushed over one another (Aeby). This appearance is due to each cell dividing in a diagonal. Approaching the proximal end, the cartilage cells become larger in a vertical diameter, and the individual rows become further apart from each other: the result is that the amount of hyaline ground-substance separating the individual cells *within* a row is reduced, while that *between* the rows increases.

The layers which now follow up to the spongy bone are the same as those described above, but possess, for obvious reasons, a pre-eminently longitudinal design, as explained above.

To repeat, they are: first, the transparent layer or the layer of large cartilage lacunæ, then the zone of calcified cartilage, further the layer containing already vascular marrow in the cavities, and osteoblasts on the surface of the calcified cartilage trabeculæ, then the layer in which, in addition, the calcified trabeculæ become ensheathed with laminæ of osseous tissue, and finally true spongy bone, the calcified cartilage having altogether disappeared (by absorption).

The description given here of the nature of the junction of hyaline cartilage and spongy bone indicates at the same time the manner in which the development of bone in cartilage, *and the growth in length of the spongy bone of the diaphysis*, i.e. its encroachment on the intermediary cartilage, take place; it is only necessary to remember that it is the vascular marrow, with its osteoblasts, which gradually grows into the cartilage, and at the line of contact produces in it the definite changes which receive their expression in the above layers.

All bones, except the tegmental bones of the cranium, and the greater part of the

facial bones, are at an early stage of embryonal life preceded by solid hyaline cartilage. This does not ossify at any time, and does not therefore become converted into the bone tissue, but is *replaced* by bone formed directly or indirectly from the periosteum. Sharpey, E. H. Weber, Lovén, and others first taught this doctrine; the researches of H. Müller, Gegenbaur, Landois and Waldeyer fully established it. The same mode of development, viz. from the periosteum, exists also in the case of the tegmental bones of the skull and those of the face, and there is no essential difference in the development of bone in cartilage, intracartilaginous or endochondral (Strelzoff) bone, and in bone that is formed without the intervention of cartilage in membrane, intermembranous or periostal bone.

Endochondral Bone.

1st Stage. Solid hyaline cartilage covered by perichondrium; this latter is identical with the periosteum whose place it holds in this and the subsequent stage. It consists, like the periosteum, of an external and internal layer; owing to the early stage neither of these two layers possesses any fibrous tissue yet, but instead of it, spindle-shaped embryonal cells, similar to other connective tissues in the fœtal state. But there is a definite distinction between the two layers, the internal or osteogenetic layer containing numerous spherical cells (the future osteoblasts), and many blood-vessels, whereas the outer layer has the uniform structure of embryonal connective tissue.

2nd Stage. The osteogenetic layer of the perichondrium penetrates, in the shape of longer or shorter processes (periostal processes, Virchow), into channels of the cartilage formed for them, and probably by them, through absorption. Thus the cartilage becomes gradually permeated by a system of anastomosing channels, cartilage-channels, containing a vascular tissue, rich in cells, and derived from the osteogenetic layer of the perichondrium. This change may be appropriately called that of Chondroporosis, and it starts at the so-called points of ossification.

3rd Stage. The cartilage around the oldest cartilage-channels becomes more transparent owing to the lacunæ of the cartilage cells becoming larger and the cells themselves more transparent. Then the lacunæ next the channel become confluent with this latter, the corresponding cartilage cells having been disintegrated, and the trabeculæ of ground-substance separating the lacunæ having undergone calcification. Instead of the single cartilage-channels with smooth outline of the former stage, we now find in these places irregular cavities, into which projects a network of trabeculæ of calcified cartilage. These irregular cavities, primary marrow cavities, are filled with the tissue that was originally contained in the cartilage-channels, viz. the periostal processes derived from the osteogenetic layer of the periosteum, the tissue in question having, of course, undergone

great increase. This tissue, which, as stated above, contains numerous vessels and cells, is now, viz. when filling the primary marrow cavities, called primary marrow. The reader has no doubt become already aware, that the primary marrow cavities, the primary marrow, the surrounding calcified cartilage and the adjoining zone of large and transparent cartilage cells, are in every respect analogous to the structures present at the point of junction of spongy bone and hyaline cartilage in the growing and adult bone, as described on a former page. And just as in the case of the growing and adult bone, so also in the first development of endochondral bone, the cells of the marrow arrange themselves (by active multiplication) as an epitheloid layer, osteoblasts, on the surface of the calcified cartilage trabeculæ, and these become gradually ensheathed in true osseous tissue produced by those osteoblasts.

4th Stage. The number of primary marrow cavities, filled with marrow, increases, and the trabeculæ of calcified cartilage, having become ensheathed with a considerable layer of osseous tissue, are gradually absorbed. We have now, instead of a network of calcified cartilage trabeculæ, as in the previous stage, a network of osseous trabeculæ, including in their interior remains of the unabsorbed calcified cartilage. These remains are gradually reduced to longer or shorter angular masses, and finally disappear altogether, so that the trabeculæ are now altogether composed of osseous substance. We have then the condition of embryonal spongy bone. The further away from the 'point of ossification' the younger and the thinner are the trabeculæ, and the more of the remains of unabsorbed calcified cartilage do they contain.

The nearer to the 'point of ossification,' the place whence the process originated, the thicker do we find the trabeculæ, and the more does the tissue as a whole resemble spongy bone.

The surface of the osseous trabeculæ is in all parts covered with osteoblasts, and the cavities separated by the trabeculæ are filled with marrow, rich in vessels and cells.

In the embryonal spongy bone the osseous matrix does not possess lamellar structure, but forms a peculiar trellis-work (v. Ebner).

5th Stage. The next stage is the absorption of the endochondral spongy bone, beginning in the centre, and gradually extending towards the periphery, the trabeculæ becoming thinner, and finally altogether disappearing; the meshes of the spongy bone become hereby confluent into one large cavity, the central marrow cavity, filled with marrow.

Simultaneously with this, another very important change takes place, viz. the development of bone from the periosteum *around* the endochondral bone. The osteoblasts of the osteogenetic layer of the periosteum form (by multiplication) longer or shorter anastomosing rows of cells, which give origin, in the manner described below, to a network of trabeculæ of osseous substance. New layers of osteoblasts (derived from the cells of

the osteogenetic layer) appear on the surface of these trabeculæ, and by undergoing the same change, viz. into osseous matrix and corpuscles, the trabeculæ increase in thickness.

The formation of new osseous tissue extends gradually in breadth and depth, and we thus obtain in connection with the osteogenetic layer of the periosteum a stratum of spongy periostal bone around the previously formed endochondral bone. The trabeculæ are covered with osteoblasts ready to be converted into osseous substance. This is especially well shown in the immediate neighbourhood of the osteogenetic layer, where the youngest trabeculæ are found; these generally originate, as pointed masses, in connection with isolated and bundles of fibres of the periosteum. The continuity of the fibres of the periosteum with the youngest layer of bone trabeculæ persists, and represents the rudiments of the perforating fibres of Sharpey. The amount of the periostal bone is in an inverse ratio to that of the endochondral bone. In the shaft of long bones we find, for instance, the periostal bone of great thickness in the centre, at a time when at the extremities only the first trace of it makes its appearance. Again, at a time when the endochondral bone in the former locality has been already almost entirely absorbed into the central marrow cavity, in the latter place, viz. the extremities of the shaft, it is as yet only in the third or fourth stage.

The meshes of the spongy periostal bone are the so-called *Haversian spaces*, and contain marrow, which is merely a continuation of the tissue of the osteogenetic layer of the periosteum.

6th Stage. In this stage all or nearly all endochondral bone is absorbed, and the spongy bone constituting the shaft is all derived from the periosteum. But also a certain amount of the trabeculæ of this bone becomes absorbed, whereby the meshes of the spongy bone become enlarged (Osteoporosis, Schwalbe).

After this a system of concentric lamellæ is formed in each Haversian space by its marrow. The spaces are hereby gradually reduced to the *Haversian canals*, and the spongy bone is thus transformed into compact substance.

The remains of the original trabeculæ of the spongy (periostal) bone represent the interstitial or ground-lamellæ separating the systems of concentric (Haversian) lamellæ. The process of osteoporosis and the formation of concentric lamellæ comprises only the deeper and middle portions, it does not involve the superficial or youngest layer.

At birth the original endochondral bone has already entirely disappeared in many bones, and the compact and spongy substance present are derived from the periosteum, except the spongy bone in the apophyses and in the extremities of the diaphysis, this being endochondral bone. As the formation of bone by the osteogenetic layer of the periosteum continues, the oldest parts, viz. those first formed, and situated near the

central marrow cavity, become absorbed: after birth we find that in this way even portions of the original periostal bone have already been absorbed in the central cavity.

The primary formation of spongy bone by the osteogenetic layer of the periosteum, and the conversion of it into compact bone, as described above, represents at the same time the manner, in which all bones increase in thickness during fœtal life as well as after birth, as long as they continue to grow. When new bone is formed under abnormal conditions, as in plastic operations, osseous tumours, &c., it is eminently the osteogenetic layer of the periosteum which produces the new bone-substance. The growth in length of the diaphysis of long bones has been described before as an encroachment of the spongy bone of the extremity of the diaphysis on the intermediary cartilage.

In this and in all other instances of the formation of osseous substance, the osteoblasts are the elements which produce both the osseous matrix and the bone corpuscles (Gegenbaur, Waldeyer), in this manner: each osteoblast, by the peripheral portion of its cell-substance (Waldeyer), gives origin to the osseous ground-substance, while the central protoplasm around the nucleus persists with this latter as the nucleated bone-cell. The bone-cell and the space in which it lies become branched. For a row of osteoblasts we then find a row of oblong or round territories, each composed of matrix, and in it a branched nucleated cell. The outlines of the individual territories are gradually lost, and we have then a continuous osseous lamina, with its bone cells. The ground-substance is from the outset a network of fibrils, it is at first soft, but soon becomes impregnated with inorganic salts, this process commencing at the 'point of ossification.' The bone cells, with their processes, are situated in corresponding lacunæ and canaliculi, just as in the adult osseous substance.

Intermembranous Bone.

The tegmental bones of the skull and the bones of the face are developed, without the intervention of cartilage, directly from a membrane which, in its structure and its function, corresponds to the future periosteum of those bones. This membrane, like that of long bones, consists of an inner osteogenetic and outer fibrous portion, the osteogenetic portion containing the same elements as in former cases, viz. blood-vessels and nucleated cells. As development proceeds there appears a reticulum of fibres, or bundles of fibres, in the meshes of which these cells are contained. The formation of bone from this periosteum is in all respects identical with that of the periostal bone, described on a former page.

1st Stage. The cells of the osteogenetic layer increase in number and form more or less continuous groups. These cells, osteoblasts, produce osseous substance (matrix and bone corpuscles) in the manner described above, and thus give origin to a more or less dense plexus of young bone-trabeculæ, which, by new layers of osteoblasts, gradually increase in thickness. Many of these terminate or rather originate in the osteogenetic layer with pointed extremities; their ground-substance is everywhere connected with the fibres of the osteogenetic layer, and their surface covered with osteoblasts. We have here, therefore, to deal with the identical appearances that we described of the formation of the outer or periostal bone of the shaft of long bones. The production of the plexus of osseous trabeculæ by the osteoblasts starts from the 'points of ossification,' and gradually extends towards the periphery, the plexus being closest and the trabeculæ thickest in the former locality.

But the plexus of trabeculæ extends also into the depth, new trabeculæ being constantly formed in the osteogenetic layer. The result is, here just as in the shaft of long bones, that we find at a certain time underneath the (osteogenetic layer of the) periosteum a thicker or thinner stratum of spongy bone, the meshes (Haversian spaces) of which contain a vascular and cellular tissue, viz. marrow, derived from, and in continuity with the osteogenetic layer of the periosteum.

2nd Stage. Portions of the osseous trabeculæ are absorbed, osteoporosis; during and after this process concentric lamellæ are formed by the marrow in the Haversian spaces, which hereby become reduced to the Haversian canals. The systems of concentric lamellæ are separated by the unabsorbed remains of the osseous trabeculæ of the primary spongy bone, these acting now as the interstitial or ground-lamellæ. We have thus compact substance formed from the spongy bone.

The process of osteoporosis and the formation of compact substance embraces the inner and middle parts, that is those that have been formed first; the superficial layers next the periosteum being still in the young state of spongy bone.

We see, then, that the formation of intermembranous bone, as in the tegmental bones of the skull and the bones of the face, is in every respect the same as the formation of periostal bone in all other bones.

Comparing, for instance, a section of the embryonal lower jaw (horizontal portion) or of the embryonal parietal bone with one through the middle of the shaft of an embryonal long bone, at a stage when all endochondral bone has disappeared in the central marrow cavity, and when the bone present is entirely periostal bone, it is impossible to distinguish the two by their histological characters, both being identical in development and structure.

From the foregoing description it is clear that the development and growth of bone in length and thickness is essentially a process of apposition of new layers or new masses of osseous substance, as had been maintained by experimenters like Hunter, Flourens, Duhamel, Ollier, and others, against Volkmann, Wolf, and others; the last-named observers regarding growth of bone due to interstitial enlargement of osseous matter once formed. Osseous substance once formed, undergoes only slight interstitial growth, as is proved by the slight change of distance of the bone corpuscles at different ages (Ruge).

In several instances absorption has been mentioned in connection with the different stages of development of bone. As long as bone grows there is also absorption going on in some place or other. In long bones there is a constant absorption of bone near the marrow cavity as long as the periosteum continues to produce new layers of bone—that is to say, as long as the bone grows in thickness. The absorption of compact substance next the marrow cavity proceeds in a manner contrary to that of the formation of it; the concentric lamellæ, which are the parts last formed, succumb first; hereby the Haversian canals are widened, and are again transformed into Haversian spaces; after the disappearance of the concentric lamellæ the interstitial lamellæ are absorbed, and the Haversian spaces become lost in the central marrow cavity. And a similar process occurs in the conversion of compact into spongy bone, as exemplified in the diploë of flat and short bones. Absorption of bone is also present in the spongy bone of the apophyses and the extremities of the diaphysis of the adult long bones, while these continue to grow in length. Just as in the embryonal spongy bone, so also in the spongy bone formed in the adult in the places just named, greater or smaller portions of the osseous trabeculæ, first formed, are absorbed, and replaced by lamellar bone substance.

Many bones possess on their surface, underneath the periosteum, larger or smaller, deeper or shallower, circular, oblong, or irregular pits—Howship's lacunæ—which owe their origin to absorption of bone. Absorption of osseous substance is a never-failing companion of many diseases of bone. The absorption of osseous substance is in most instances (embryonal and adult) associated with the presence of the multinuclear giant cells (Kölliker) mentioned on former pages, and being regarded as the chief agencies of absorption, are called Osteoclasts (Kölliker). Osteoclasts have been noticed also in absorption of bone under pathological conditions (Wegner, Morison, and others). But in the course of absorption of calcified cartilage, as during the development of endochondral bone in general, and especially at the extremities of the shaft of long bones,

REESE LIBRARY
OF THE
UNIVERSITY
OF
CALIFORNIA.

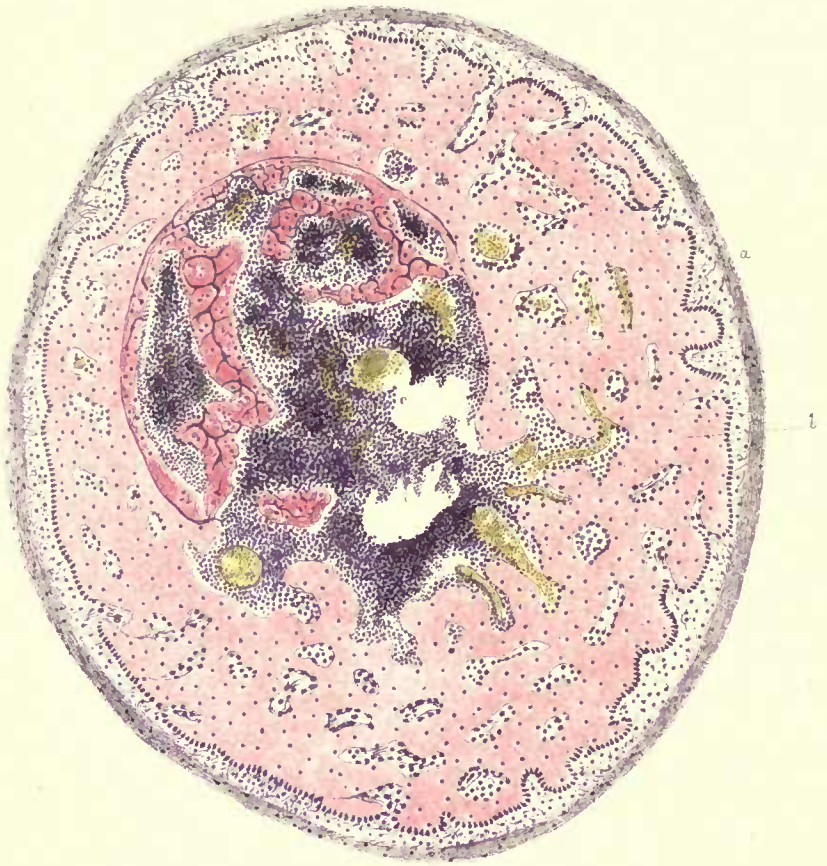

I.

II.

III.

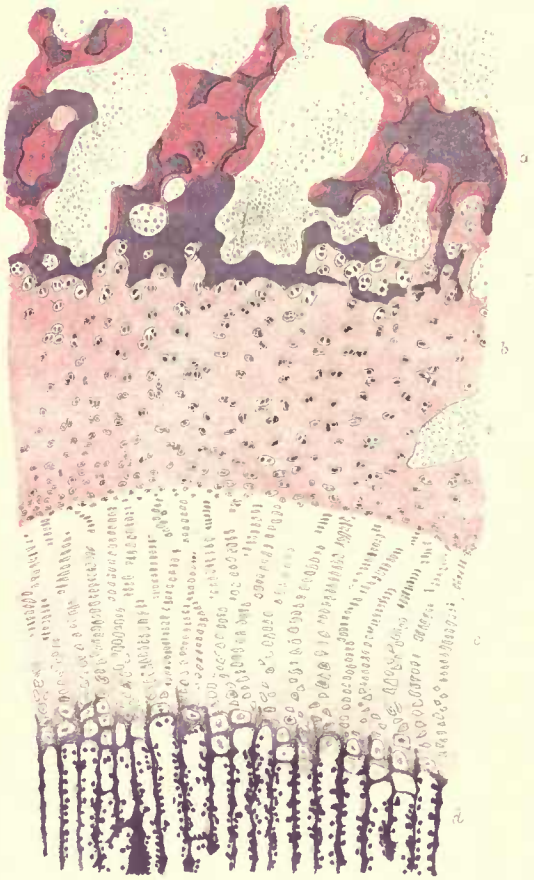

IV.

E. Noble Smith del.

Mintern Brothers

we find that this is also supported by multinuclear giant cells; they may be then appropriately called Chondroclasts.

The solution and absorption of calcified cartilage and osseous substance cannot be explained merely by the action of the blood-vessels of the marrow, for the simple reason that the insoluble lime-salts of those tissues cannot be dissolved by the alkaline plasma exuded from the blood-vessels. To convert those salts into soluble matter requires an acid which, in all probability, is formed *in loco*; and it is equally probable that the osteo- and chondroclasts are the means by which it is produced. As a matter of fact, these giant cells comport themselves in microchemical respects as if of acid reaction.

But not all multinuclear giant cells, found at the different places where absorption of calcified cartilage or of osseous substance occurs, are merely destructive agents; for there are other places where they can be shown to be concerned in the *formation* of osseous substance, just like the ordinary uni-nuclear osteoblasts. And the multinuclear giant cells are indeed only derived from osteoblasts, some of them having undergone an exceptional increase in size, and their nucleus a repeated division. The giant cells connected with absorption are generally on one side of a more or less opaque appearance, and transversely striated; with this part they are closely applied to the surface that is to be absorbed.

PLATE XII.

Figs. I. and IV. drawn under a magnifying power of about 45; fig. II. under one of about 180; and fig. III. of 90.

Fig. I. Transverse section of shaft of tibia of fœtal kitten. The section had been stained first in carmine and then in hæmatoxylin. All bone represented in this and the following two plates had been first macerated in chromic acid to deprive it of its inorganic salts.

a) Periosteum, showing the outer fibrous and inner osteogenetic layer.

b) Fœtal spongy bone, produced by the periosteum. The osseous substance is of a pink colour, and contains numerous bone corpuscles, of which only the nuclei are here shown. The trabeculæ next the osteogenetic layer are the most recently formed, they are covered with a regular epitheloid layer of osteoblasts. The cavities of the spongy bone, the Haversian spaces, contain a vascular and cellular tissue, which on the one hand passes into the marrow of the central cavity, and on the other is continuous with the osteogenetic layer of the periosteum.

c) The central or marrow cavity containing blood-vessels filled with blood, and numerous marrow cells. In it are still left the (unabsorbed) remains of the endochondral

spongy bone, whose trabeculæ still include thin (linear) masses of calcified cartilage, stained deeply purple. On the left side of the section there is still to be seen a definite boundary between the periostal and endochondral bone; in the right part of the section all endochondral bone has disappeared.

Fig. II. From a section through a dried frontal bone (not macerated) of man, showing the lamellar arrangement of the osseous ground-substance, and between the lamellæ the oblong lacunæ of the bone corpuscles with their numerous canaliculi. The bone having been dried, the bone cells and their processes contained in the lacunæ and their canaliculi have disappeared, the latter being now filled chiefly with air. In transmitted light they therefore appear black, the ground-substance being transparent; and in reflected light the lacunæ and canaliculi are bright, while the ground-substance is dark.

Fig. III. From a transverse section through part of shaft (compact substance) of dried radius (not macerated) of man.

a) Systems of concentric or Haversian lamellæ; between the latter are seen the lacunæ of the bone corpuscles; their canaliculi pass transversely through the lamellæ, and open into the central or Haversian canal.

b) Interstitial or ground-lamellæ, and between them the bone corpuscles.

The Haversian canals, owing to the bone having been dried, are filled with air and dry remains, and appear therefore black.

Fig. IV. From a longitudinal section through the head of humerus and adjoining portion of shaft of fœtal kitten; the section had been stained first in carmine and then in hæmatoxylin.

a) Part of epiphysis next the intermediary cartilage; it is spongy bone, of which here only a few broad trabeculæ (stained pink) are shown; they still include considerable masses of unabsorbed calcified cartilage, stained deeply in logwood. The bone corpuscles are indicated by their minute nuclei. Between the trabeculæ of this spongy bone is a vascular and cellular marrow, not detailed in this figure.

b) Hyaline cartilage, the remains of the fœtal cartilaginous epiphysis; on this cartilage encroaches the spongy bone of the epiphysis; the cartilage next to the part (*a*) is more transparent, owing to the cartilage lacunæ being enlarged; the cartilage ground-substance of this zone becomes gradually calcified, and therefore stains deeply in logwood.

c) Intermediary cartilage; the cartilage cells are arranged in longitudinal rows.

d) Extremity of the shaft; the cartilage near it is more transparent, owing to the lacunæ being enlarged; these lacunæ gradually merge into the marrow spaces of the spongy substance of *d*, while the cartilage cells disappear. The ground-substance

V

VII.

VI.

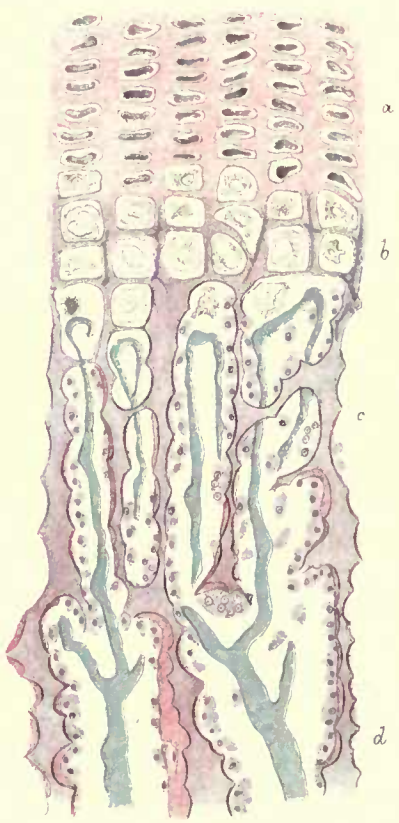

VIII.

of the cartilage is here calcified (stained deeply in logwood). Numerous osteoblasts cover the trabeculæ in the region *d*, and on some of these there are already indications of (pink) osseous substance.

e) Section through part of a cartilage-channel, containing cellulo-vascular tissue derived from the perichondrium (periosteum) as a periostal process of Virchow; see a former page.

PLATE XIII.

Figures V. VI. and VII. drawn under a magnifying power of about 350; fig. VIII. under one of about 450. All figures represent preparations of bone that had been macerated in chromic acid, and hereby deprived of its inorganic matter.

Fig. V. From a transverse section through the shaft of tibia of fœtal kitten, stained first in carmine and then in hæmatoxylin; from a similar preparation as fig. I. of the previous plate.

a) Fibrous layer of periosteum.

b) Osteogenetic layer of periosteum, containing nucleated cells in a plexus of fibres. Towards the depth the cells become larger in size, and some of them more or less drawn out in processes. These cells are the osteoblasts, in the act of forming osseous substance.

c) Spongy bone formed by the periosteum, periostal bone. In its matrix, stained pink, are contained the branched bone corpuscles. The meshes of this bone, viz. the Haversian spaces, contain numerous osteoblasts.

d) Endochondral formation of bone. The unabsorbed calcified cartilage trabeculæ (stained blue) become gradually covered with thinner or thicker laminæ of osseous substance (stained pink), and with numerous osteoblasts. In one marrow cavity is shown a blood-vessel; all the marrow cavities contain numerous cells.

e) Distinct boundary between the endochondral and periostal bone.

Fig. VI. From a longitudinal section of femur of rabbit, through the region in which the extremity of the shaft is in contact with the intermediary cartilage. The vessels of the bone had been injected with Berlin-blue, and the section had been stained first in carmine, then in hæmatoxylin. This figure illustrates the growth in length of the shaft of a long bone.

a) Intermediary cartilage. The cartilage cells are somewhat flattened and arranged in characteristic longitudinal rows.

b) The transparent region of the large cartilage lacunæ. The cartilage cells are very transparent and swollen up; the cartilage ground-substance is partly calcified.

c) The region in which the cartilage lacunæ have become confluent with the marrow cavities, the cartilage trabeculæ being calcified, and more or less covered with osteoblasts; into this region extend the capillary blood-vessels, terminating here as loops. Among the uninuclear osteoblasts there are a few multinuclear giant cells, which probably act here as chondroclasts.

In the depth of this, and in the next region, *d*, the calcified cartilage trabeculæ become more or less reduced in thickness, and covered with osseous substance (stained pink). This is more marked the further away from the intermediary cartilage.

Fig. VII. From a similar preparation as that of the preceding figure, only more highly magnified, to show a large trabecula of calcified cartilage taken somewhere between *c* and *d* of the preceding figure.

The upper part of the calcified cartilage, stained faintly blue, is covered with multinuclear giant cells. These being placed on cartilage which is to be absorbed are very probably the instruments of absorption, and hence deserve the name of chondroclasts. Towards the depth, that is, towards the shaft, the cartilage becomes covered with osseous substance, stained pink, and numerous osteoblasts.

Fig. VIII. From a longitudinal section through the spongy bone of shaft, but not far from the intermediary cartilage of femur of fœtal kitten, to show the formation of osseous substance on the trabeculæ of calcified cartilage represented in the preceding two figures. The section had been stained first in carmine and then in logwood.

a) A marrow cavity containing a blood-vessel (with blood corpuscles), and a few marrow cells; many of these had been accidentally removed from the preparation.

b) Calcified cartilage, stained faintly blue. It is covered either with isolated or continuous masses of osseous substance, stained pink. The isolated masses consist of a matrix of fibrils, a small cavity, and in this a nucleated cell; this latter ought to be represented more branched. Each of these isolated masses is derived from one osteoblast, of which the peripheral portion has become converted into the osseous matrix, while the part of the cell-substance immediately around the nucleus persists as the nucleated bone cell, this becoming at the same time branched, and separated from the matrix by a similarly branched lacuna. As development proceeds, these isolated masses become confluent into more or less continuous laminæ.

REESE LIBRARY
OF THE
UNIVERSITY
OF
CALIFORNIA

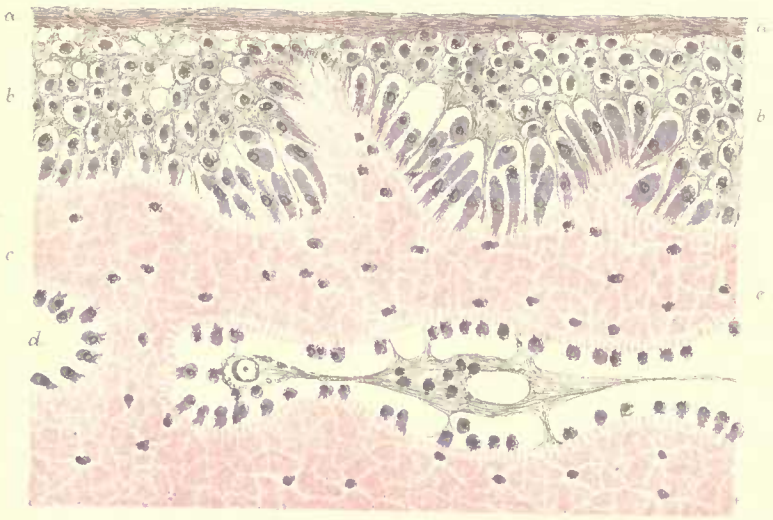

IX

X

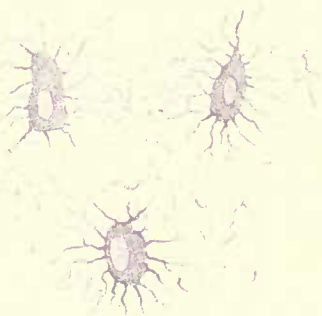

XI

XII

XIII

obble Smith fecit

Mintern Bros imp

PLATE XIV.

Figures IX. X. and XI. are drawn under a magnifying power of about 350; the other two under one of about 250.

Fig. IX. From a transverse section through part of lower jaw of human fœtus, next the external periosteum. The section had been stained first in carmine and then in hæmatoxylin. The jaw was in the stage of spongy bone.

a) Fibrous layer of periosteum.

b) Osteogenetic layer of periosteum.

c) Osseous substance, stained pink, and containing numerous bone corpuscles. Next the periosteum the trabeculæ are covered with an epitheloid layer of osteoblasts; the two pointed projections of osseous substance into the osteogenetic layer are parts just in the act of formation.

d) Haversian spaces, marrow cavities containing marrow; some of the cells are arranged as osteoblasts on the surface of the osseous substance.

Fig. X. A small isolated mass of bone next the periosteum of lower jaw of human fœtus of a similar specimen as the one mentioned in the foregoing figure.

a) Osteogenetic layer of periosteum.

b) Multinuclear giant cells; the one on the left side acting here probably like an osteoblast. The large giant cell in the middle of the upper margin of the osseous substance has an opaque lower margin vertically striated. With this margin it rests in a small Howship's absorption pit. Above *c* the osteoblasts are seen to become gradually surrounded by osseous matrix, and are thus converted into bone corpuscles.

Fig. XI. From a section through osseous substance of vertebral bone of adult mouse; the preparation had been stained in chloride of gold.

Nucleated bone cells and their processes contained in the bone-lacunæ and their canaliculi respectively.

Fig. XII. From a transverse section through part of lower jaw of fœtal kitten, next the inframaxillary canal; the section had been stained first in carmine and then in hæmatoxylin.

a) Periosteum lining the inframaxillary canal.

b) Layer of multinuclear giant cells; each of them situated in a small pit, but close to the osseous substance.

These pits correspond to the absorption pits, or Howship's lacunæ. The giant cells act here as bone-absorbers, osteoclasts. The margin of these osteoclasts resting on

the bone is opaque, and more or less distinctly vertically striated; this appearance is not represented in the figure.

c) Osseous substance.

Fig. XIII. From the spongy bone of lower jaw of fœtal kitten. The preparation had been stained in carmine only.

a) Periosteum.

b) Trabeculæ of fœtal bone, connected by smaller or larger bundles of fibres with the fibrous matrix of the periosteum. These bundles of fibres are the rudiments of the perforating fibres of Sharpey. On the surface of the osseous trabeculæ are seen nucleated osteoblasts forming osseous substance.

CHAPTER X.

UNSTRIPED MUSCLE.

The tissue of unstriped muscle has a wide distribution in man and the other vertebrates. Large masses of it are present, in the shape of bundles or continuous coats, in the œsophagus, stomach, small and large intestine, trachea, bronchi and infundibula of lung; pelvis of kidney, urethers, bladder and urethra, prostate, epididymis, vas deferens, vesiculæ seminales and ejaculatorii, and corpora cavernosa; ovary, Fallopian tube and ligamenta lata, uterus and vagina; in the arteries and many veins, in the semi-lunar valves of the heart and some lymphatic trunks; the gall-bladder, ductus hepaticus, cysticus and choledochus; the duct of the parotid, submaxillary, and pancreas glands; the capsule and trabeculæ of the spleen, and, in some mammals, also those of lymphatic glands; occasionally in the serous membranes, in the muscles of the hairs (arrector pili) in sweat glands and ceruminous glands; the sphincter and dilatator pupillæ, the tensor chorioides, and the muscle of Müller in the orbital fissure are unstriped muscle tissue.

The elements of this tissue are elongated, spindle-shaped, or bandlike cells of various lengths, each with an oblong nucleus. They are aggregated into smaller or larger bundles, and these again into groups or continuous membranes.

The muscle cells within a bundle are imbricated and held together by a semi-fluid, transparent, albuminous, interstitial or cement substance, identical with the substance uniting epithelial and endothelial cells, mentioned in a former chapter. But there are flattened connective-tissue cells to be met with in this cement-substance, and also now and then a few connective-tissue fibres. Both these tissues, viz. connective-tissue cells and fibres, represent the endomysium. The tissue surrounding or separating the individual bundles is fibrous-connective tissue of the ordinary description, and represents the perimysium. The endomysium is continuous with the perimysium.

The bundles of unstriped muscle fibres often are connected with one another in the form of a plexus, larger bundles dividing into smaller ones, and then again reuniting.

The unstriped muscle cells in a bundle are pressed against one another, appearing therefore more or less polyhedral in transverse section. The individual cells consist in the fresh state of a transparent more or less distinctly longitudinally striated substance (Arnold, Klein, Flemming, Ranvier), and their transverse section presents accordingly a finely and uniformly dotted appearance.

Each muscle cell consists of the following parts (Klein):—(*a*) of a fine sheath, probably elastic, which possesses transverse linear thickenings—these are especially distinct when the muscle cell or part of it is in a contracted state (see below); (*b*) a central bundle of fibrils representing the contractile substance or the core; (*c*) an oblong nucleus which, within a membrane, includes a fine network (Flemming, Klein). This network anastomoses at the poles of the nucleus with the bundle of fibrils of the core (Klein).

The position of the nucleus varies in different muscle cells; as a rule it is in about the middle of the long axis of the cell, but there are many instances in which the nucleus is nearer to one extremity than to the other. As a rule the nucleus is contained in the thickest part of the cell. In muscle cells treated with hardening reagents the nucleus is often shrunk, so that its outline becomes wavy and notched. At the extremities the muscle cell is drawn out either into a longer or shorter fine point pushed in between the neighbouring cells. In some instances both extremities are branched, being split into two or more longer or shorter processes. Muscle cells with branched extremities may be found in isolated examples in most instances, but in the arteries and veins they are very numerous.

Unstriped muscle tissue varies in different organs as regards the length and thickness of its cells. The longest and thickest muscle cells are found in the intestines, the shortest in the arteries, the thinnest in the sweat-gland tubes.

Unstriped muscle tissue is richly supplied with nerves. These will be specially treated in a future chapter on the termination of motor nerves. The blood-vessels, like those of other organs, consist of afferent artery, efferent vein or veins, and a network of capillary vessels. These latter are intrafascicular, they run parallel to the long axis of the bundles, and anastomose by transverse branches into a network. But the number of capillary blood-vessels is on the whole small if compared with the number present in striped muscle tissue.

CHAPTER XI.

STRIPED MUSCLE FIBRES.

ALL muscles of the skeleton, the heart, and diaphragm, the muscles of the oral cavity, pharynx and larynx, and part of œsophagus, the external muscles of the eye-ball, the muscles of the middle and outer ear, the sphincter vesicæ, part of the muscles of the prostate, &c., consist of striped muscle fibres. These are long cylindrical fibres of various thickness, showing a regular transverse striation, due to various discoid elements entering into the constitution of the individual cylinders. The fibres are aggregated into smaller groups, bundles, and these again into large fasciculi, which form part of an anatomical muscle. Ordinary fibrous-connective tissue separates or surrounds the individual bundles as perimysium ; from this pass minute bundles of connective tissue, with connective-tissue cell plates, into the muscle bundles between the individual muscle fibres as endomysium. Amongst the cells of the endomysium the plasma cells are especially noticeable. See Chapter IV. p. 27.

Each muscle fibre, when viewed in the fresh and living but resting state along its long axis, shows :—(*a*) transverse broad dim bands of a highly refractive substance, alternating with (*b*) narrow bright bands of a less refractive substance. Both are due to discs placed vertically to the long axis. As will be seen presently, the former alone represent the contractile portion of a muscle fibre, and may be therefore called the *contractile discs* : the latter, being merely interstitial substance, may be spoken of as *interstitial discs* (Rollett). During contraction, viz. the parts through which a contraction wave is just passing, the former become thinner in the long axis of the muscle fibre and transparent, the latter more opaque. But while the contractile disc becomes thinner along the long axis of the fibre, it, and consequently also the muscle fibre, becomes thicker in a transverse direction. When a muscle fibre that in the fresh and living state merely shows a differentiation into the above transverse discs, dies spontaneously or in consequence of hardening reagents, it changes its aspect, inasmuch as it becomes, in addition, longitudinally striated, owing to the appearance of longitudinal, fine, apparently linear masses of a clear bright substance, gradually increasing in amount. Hereby each dim contractile disc becomes differentiated, as it were, into thin oblong rods, the sarcous elements of Bowman, each of which is the length of the disc.

The sarcous elements represent the anatomical elements of the contractile disc.

In the fresh and living state they are prismatic corpuscles arranged side by side; those forming one disc are in immediate contact with one another, and being all of the same optical refractive power, no differentiation can be perceived, and the disc appears therefore quite homogeneous. But when, either spontaneously during life, or after death and reagents, the sarcous elements shrink (coagulate), they become separated from one another, and a transparent interstitial fluid substance, pressed out from the sarcous elements (Engelmann), is now seen occupying the crevices between them. The above clear bright lines correspond to this substance. They contain in many cases rows of granules (Henle, Kölliker). The interstitial substance corresponds in appearance and chemical respects to the interstitial transverse disc above mentioned, and both represent the albuminous substance discovered by Kühne, and called by him myosin. A longitudinal series of sarcous elements (one abreast) represents a so-called primitive fibril. A muscle fibre may therefore be regarded as composed either of transverse discs or of longitudinal fibrils, according to whether we look upon the sarcous elements as being arranged sideways or endways. Certain reagents possess the property of bringing out more prominently the one or the other arrangement. Thus muscle treated with alcohol shows generally the arrangement of the sarcous elements into fibrils more strikingly than in transverse discs, whereas the reverse is the case with hydrochloric acid.

The length of the sarcous elements, or what amounts to the same, the length of a contractile disc, or the breadth of the striation, varies considerably in different animals and also in different muscles of the same animal; it is much greater in insects than in vertebrates. Equally variable in thickness is the interstitial disc.

The thickness of the individual muscle fibres is subject to great differences in different animals and in the muscles of one and the same animal, varying between the fine fibril of the thorax muscle of hydrophylus piceus, representing almost a single row of sarcous elements, to the tremendous muscle fibre of the claw of a lobster.

When viewing a transverse section through fresh and living muscle, the muscle substance appears at first homogeneous and of a dim aspect; gradually there appear shorter or longer lines of a clear bright substance; these anastomose, and are so arranged that the muscle substance seems divided into relatively large polygonal areas. The clear lines are in some places of some muscle fibres greatly enlarged, owing to the presence in them of a nucleated cell, or muscle corpuscle (see below). The numbers of clear lines gradually increase, and consequently the size of these areas decreases, until we arrive at a permanent subdivision of the transverse section into small polygonal areas of dim substance, each corresponding to one sarcous element prism viewed endwise (Cohnheim's fields); the clear lines are the interstitial substance, mentioned above as gradually appearing between the sarcous elements. The individual sarcous elements do not,

however, present a homogeneous aspect when thus viewed endways, but appear granular, this being probably merely the expression of minute longitudinal fibrils (Kölliker). The transverse section of a muscle fibre, after hardening, shows the sarcous elements (Cohnheim's fields), or primitive fibrils, very often greatly shrunk, and therefore like small dots, the interstitial substance of course appearing greatly increased accordingly.

Besides the structural differences described hitherto, there are other minute elements entering the constitution of a muscle fibre: these can be perceived already in the fresh and living state, but better after certain reagents. These structures are: (*a*) a hyaline sheath, the sarcolemma: this is a transparent structureless elastic sheath of great resistance; it surrounds the contents of the muscle fibre like a cuticle. (*b*) In connexion with the sarcolemma are transverse fine membranous septa, stretching right across the muscle fibre at regular intervals: these septa are the membranes of Krause; they are homogeneous, elastic, but show less resistance (Engelmann) than the sarcolemma with which they are intimately connected. By these transverse septa the muscle fibre is divided into numerous equal-sized cylindrical compartments, muscle-compartments of Krause, each of which possesses the breadth of the whole muscular fibre. Each compartment contains one dim contractile disc, mentioned above. Now, the membranes of Krause are so placed that *each of them passes right across the middle of an interstitial disc* from one side of the muscle fibre to the other; hence each interstitial disc is divided into two halves, *the lateral discs*, each of these belonging to different (adjacent) compartments.

We may then summarise the structure of a striped muscle fibre thus:

1) The framework. This consists of: (*a*) *Sarcolemma*; and (*b*) *Krause's membranes*; hereby the fibre is divided into muscle compartments.

2) The muscle-substance: (*a*) each muscle compartment contains one broad dim *contractile disc*, highly refractive, composed of prismatic rods, sarcous elements; (*b*) a narrow transparent *lateral disc* placed at each end of the contractile disc, and consequently at the side of Krause's membrane. According to Hensen and Engelmann, a transparent transverse thin 'median disc' divides the contractile disc into two; but this appearance is found only under exceptional conditions (see below).

In some muscle fibres, especially in some fibres of insect muscle, we find each lateral disc containing, in the transverse diameter, a row of bright granules, so placed that each granule corresponds to the end of a sarcous element. But they are not of constant occurrence, being often absent (Krause). According to Schäfer, who regards them as constant features, they are the knoblike ends of thin rodlike elastic elements which constitute the dim disc.

These granules form the 'granular layer' of Flögel. In some muscle fibres this

granular layer is in the centre of the lateral disc; in others, it is nearer the contractile disc, and still in others nearer the Krause's membrane.

The striped muscle fibres contain numerous oblong more or less flattened nuclei, each embedded in a thin more or less branched film of protoplasm. Each nucleus contains a uniform network, intranuclear network. Both nucleus and protoplasm form the muscle cell or muscle corpuscle of Max Schultze. In the muscle fibres of higher vertebrates, except the heart, the muscle corpuscles are, as a rule, situated on the surface of the muscle substance, but underneath, not in, the sarcolemma. In the muscle fibres of amphibian animals and insects we find them sometimes only in the centre of the fibres (Weismann, Kölliker). In birds (pigeon and fowl, Rollett) both conditions are met with.

The number of muscle corpuscles varies greatly in different muscle fibres; they are always more numerous in young, developing, or growing fibres (see below).

Muscle fibres differ in colour, some being red, others pale. In mammals this is owing, in some instances, to well-defined structural differences (Ranvier). Comparing a red muscle, e.g. semitendinosus, of rabbit with a pale one, adductor magnus or vastus internus of rabbit, Ranvier finds the fibres of the red more longitudinally, those of the pale ones more transversely striated; the former possess a much greater number of muscle corpuscles than the latter; the red fibres contract slower than the pale ones, and the latter return much quicker to their state of rest. But these differences are not of a constant nature, inasmuch as, according to E. Meyer, the red muscles of other parts and in other animals (flexor digitorum com. and masseter of rabbit, red muscles of other rodents) do not show any different characters from the pale ones. In some instances (silurus) the red fibres of the red muscles are thinner than those of the pale ones (Ranvier), in others (rabbits) just the reverse is the case (E. Meyer). The more a muscle works the deeper its colour (E. Meyer).

The muscle fibres of some organs, tongue (Remak, Ripmann, Kölliker, Salter, and others), facial muscles (Huxley, Busk, and others), and especially heart, are branched, either repeatedly but without anastomosis of the branches, as in the former, or they are arranged in a network, as in the latter.

The muscle fibres of the heart show the following peculiarities: (1) they do not possess any sarcolemma; while ordinary striped muscle fibres in transverse section, either fresh or after reagents, show a well-marked and sharp limiting membrane, the sarcolemma, those of the heart are limited by their muscle substance itself. (2) A transverse section through heart muscle differs also in other respects from that of ordinary muscle; while ordinary muscle shows the transverse sections of its muscle fibres as round or oval bodies more or less pressed against one another, and differing in size within moderate limits, those of the heart, on the other hand, are of various sizes, and being

repeatedly branched, are irregular in shape and size, according to whether the transverse section is taken from a part of the fibre at the point of branching or from a part above or below it. (3) The muscle corpuscles of the fibres of the heart are invariably situated in or about the centre of the fibres (Donders); the number of the muscle corpuscles is relatively great, and the chances therefore are that in a transverse section the greater majority of fibres are cut through the muscle corpuscle. Corresponding to the individual muscle corpuscles the fibres appear, under certain conditions, subdivided into oblong cylindrical blocks (Aeby, Eberth, and others), straight at their ends, or divided according to whether they belong to an undivided or dividing portion of a fibre.

Muscle fibres have only a limited length; they terminate or originate respectively either within the bundle (Rollett) or in a tendon. In the first case, the contents of the fibre terminate abruptly in a conical shape, and the sarcolemma, having collected into a fine filamentous structure, loses itself in the connective tissue separating the muscle fibres. In the second case, a muscle fibre passes into a bundle of fine connective-tissue fibrils in either of two ways: (*a*) the contents of a fibre terminate conically, and the sarcolemma appears to pass on a tendon bundle of connective-tissue fibrils, or (*b*) the muscular contents themselves seem to be continued, apparently without interruption, into the tendon bundle.

The muscle fibres near their termination or origin respectively become gradually reduced in diameter, hence their shape is that of a spindle (Herzig, Biesiadecki, Krause, Weismann, and others). In a given transverse section through a bundle of striped muscle fibres we therefore find the muscle fibres of various diameters, some two and three times as thick as others; this is explained by the fibres being spindle-shaped, thickest in the middle parts, and tapering towards the termination.

According to Kölliker, in small muscles, as in the small muscles of the extremities of bat, muscles of frog, all individual fibres extend the whole length of the muscle; but in large muscles, according to Herzig, Krause, and others, the length of the fibres does not exceed $1\frac{1}{2}$ to 2 inches.

At an early stage of embryonal life elongated spindle-shaped cells are transformed into striped muscle fibres, each such cell giving origin to a muscle fibre (Remak, Weismann, Kölliker, and others). These spindle-shaped cells, at first thin and small, enlarge to a very great extent, and their nucleus undergoes repeated division. The cell-substance, beginning from the periphery, becomes differentiated into the striate muscle substance, viz. sarcous elements and interstitial substance (Remak, Weismann, Fredericq, and others). What remains of the original protoplasm around the nuclei—more distant from each other as development proceeds—represents a muscle corpuscle. The sarcolemma is developed from nucleated cells different from the muscle corpuscles (Calberla,

Wolff); in the adult fibres no trace of the nuclei of those cells is to be found in the sarcolemma. The younger the muscle fibre the more numerous the muscle corpuscles, and the greater the amount of protoplasm around them. When muscle fibres undergo increase in thickness and number, as during prolonged and systematic muscular exercises, we find the muscle corpuscles taking an active part therein; they enlarge and multiply, and the greater part of their substance is converted into muscle substance proper; the mode of this transformation is the same as in the embryo.

Thus we find many muscle fibres of the diaphragm of young as well as adult mammals (dog, rabbit, guinea-pig) possessing the character of growing fibres, viz. numerous and large muscle corpuscles sometimes forming on the surface of the muscle tissue proper, but underneath the sarcolemma, a more or less continuous layer of polygonal or square cells of various sizes, each with one or several nuclei. The protoplasm of these cells is gradually converted, and hence passes insensibly, into the striated muscle substance. The great number and size of the muscle corpuscles in some of the fibres of the diaphragm, as compared with those of the fibres of another muscle, e.g. quadratus lumborum, of the same animal, is not owing merely to the fact that the diaphragm being a red muscle its fibres possess many more muscle corpuscles than those of the quadratus lumb., which is a pale muscle; not all the fibres of the diaphragm possess a great abundance of muscle corpuscles, and those that possess it do so much more conspicuously than the fibres of other red muscles (semitendinosus) of the same animal.

It is probable that the character of many muscle fibres of the diaphragm, just described, indicates a constant new formation and increase of thickness. Constant work necessitates constant waste, and very likely constant reproduction.

The lymphatics and nerve-termination of striped muscle tissue will be described in the chapters on the Lymphatic and Nervous System respectively.

Striped muscle tissue is richly supplied with blood-vessels, the arteries and veins being situated in the perimysium, the network of capillaries in the endomysium, *between* the individual muscle fibres. The capillary blood-vessels are very numerous, and run parallel with the muscle fibres; they anastomose by short transverse branches, hence the meshes of the capillary network are preeminently of an elongated shape. In the red muscle of rabbit Ranvier demonstrated a peculiar condition of the minute veins and capillaries, these vessels being possessed of sinuous and spindle-shaped dilatations, owing probably to the almost permanent contraction of these muscles (E. Meyer).

Brücke was the first to show that striped muscle fibres are doubly refractive, and

REESE LIBRARY
OF THE
UNIVERSITY
OF
CALIFORNIA.

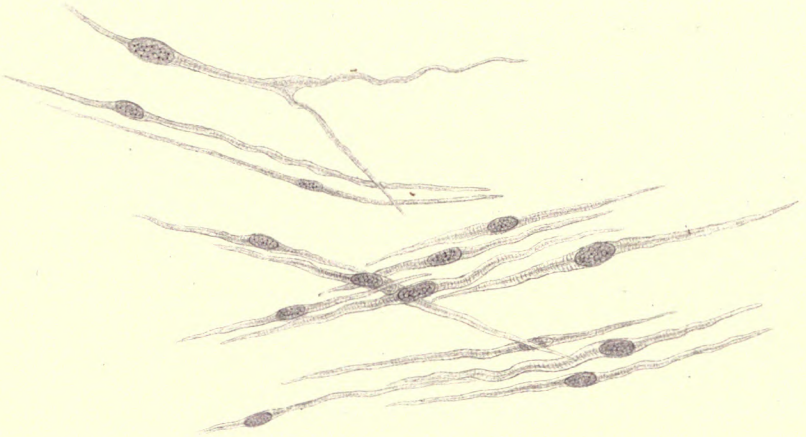

I.

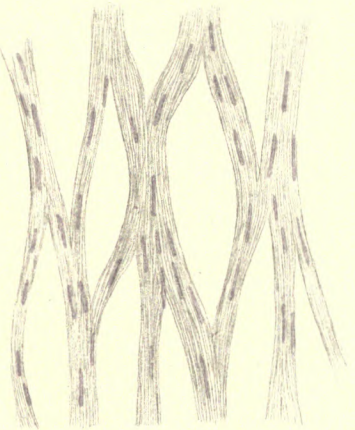

III.

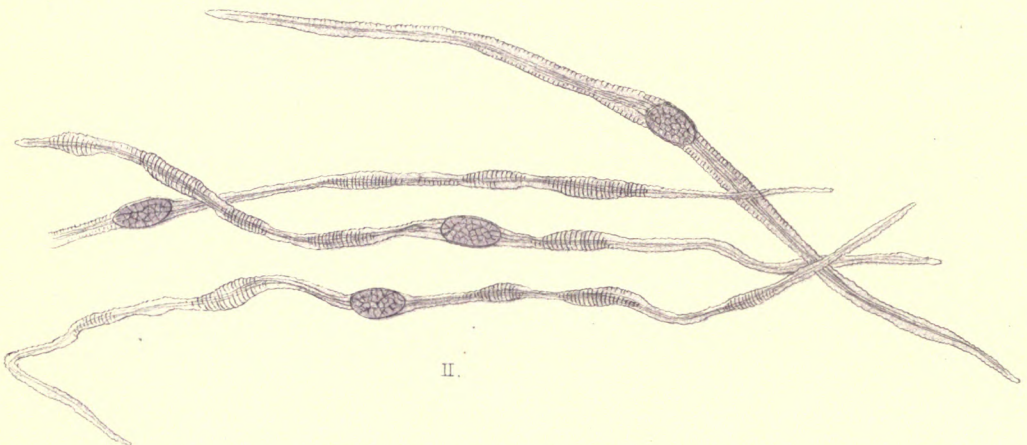

II.

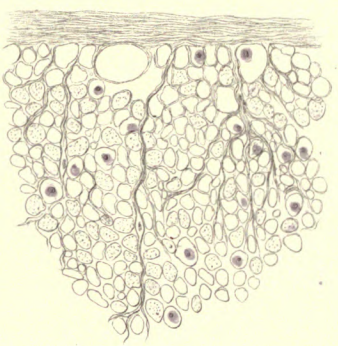

IV.

V.

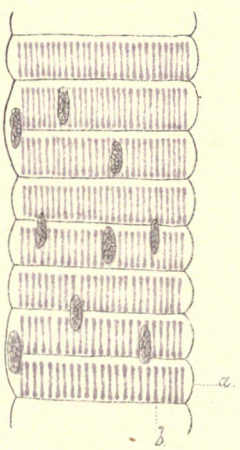

VI.



VII.

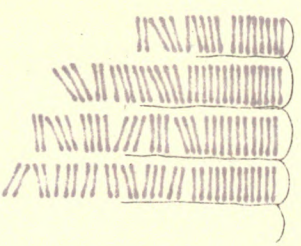

VIII.

E. Noble Smith fecit.

Mintern Bros imp.

that they comport themselves in this respect like positive uniaxial bodies (rock crystal), the optical axis being the long axis of the muscle fibres.

But not all parts of a muscle fibre are doubly refractive, the sarcous elements (Brücke) and Krause's membrane (Engelmann) being anisotropous, the lateral disc isotropous.

The sarcous elements are not the optical units, but must be considered as consisting of minute doubly refractive elements, disdiaclasts (Brücke). We have seen on a former page that also in morphological respects the sarcous elements are not of a homogeneous structure, but probably composed of minute fibrils (Kölliker).

PLATE XV.

Figures I. and III. are drawn under a magnifying power of about 180; figures II. and VIII. under one of about 450; and figures IV. V. VI. and VII. of about 300.

Fig. I. Unstriped muscle cells of mesentery of newt; the sheath with transverse markings is faintly seen.

Fig. II. From a similar preparation as fig. I., showing that each muscle cell consists of a central bundle of fibrils (contractile part) connected with the intranuclear network, and a sheath with annular thickenings. The muscle cells show varicosities, probably owing to local contractions, and on these the annular thickenings are more distinct. The mesentery had been prepared with chromate of ammonia.

Fig. III. Plexus of bundles of unstriped muscle cells of the pulmonary pleura of guinea-pig.

Fig. IV. From a vertical section through the circular muscle coat of large intestine of pig. The intestine had been hardened in chromic acid. From the connective tissue of the perimysium pass smaller and larger bundles between the individual muscle cells, shown here in transverse section. In many places the muscle cells have been removed (accidentally), and the interstitial substance is then seen as a honey-combed structure. Owing to the muscle cells being of considerable length, only few of them show a nucleus. The cells containing longitudinal fibrils (see above) appear in transverse section as if containing minute dots, these being the fibrils seen in section.

Fig. V. From a vertical section through the circular muscle coat of small intestine of dog; the intestine had been prepared with chromate of ammonia. The honey-comb interstitial substance is well shown, and in it a few nucleated connective-tissue cells. The muscle cells appear of different sizes in the transverse section, being spindle-shaped, and consequently some are cut through the thicker part, others nearer the fine extremity.

Fig. VI. Part of a striped muscle fibre of hydrophylus prepared with absolute alcohol.

a. Sarcolemma.

b. Membrane of Krause.

Owing to contraction during hardening the sarcolemma shows regular bulgings.

At the side of Krause's membrane is the transparent lateral disc. The chief mass of a 'muscular compartment' is occupied by the contractile disc, composed of sarcous elements.

The substance of the individual sarcous elements has collected more at the extremity than in the centre, hence this latter is more transparent. The optical effect of this is that the contractile disc appears to possess a 'median disc.'

Several nuclei (of muscle corpuscles) are shown, and in them a minute network.

Fig. VII. A muscle fibre of hydrophylus prepared in the same manner as in fig. VI. The sarcolemma, to a great extent detached, shows the regular bulgings as in the previous figure, but the membranes of Krause are not seen.

Fig. VIII. Portion of a broken muscle fibre of hydrophylus, showing part of sarcolemma and part of Krause's membranes; the contractile discs are being disintegrated into the constituent sarcous elements.

PLATE XVI.

Figures IX. X. XIV. A and B, and XVI. are drawn under a magnifying power of about 450; figures XI. and XIII. under one of about 300; figures XII. and XV. under one of about 150.

Fig. IX. Transverse section through muscle fibres of human tongue. The muscle fibres appear in transverse section of different sizes, owing to their being more or less spindle-shaped; each fibre is limited by a definite membrane, the sarcolemma. The muscle corpuscles are indicated by their deeply stained nuclei, situated at the inside of the sarcolemma. There are several connective-tissue corpuscles between the muscle fibres, belonging to the endomysium. Each muscle fibre shows the Cohnheim's fields, that is the sarcous elements in transverse section and separated by clear (apparently linear) interstitial substance.

Fig. X. Transverse section through muscle of heart. The fibres are irregular in shape and size, owing to their being branched; the muscle corpuscles are indicated by their nuclei, situated in about the middle of the fibres.

Fig. XI. From a section through muscle of tongue of rat; between and on the

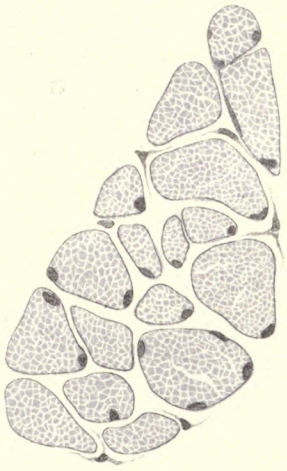

IX.

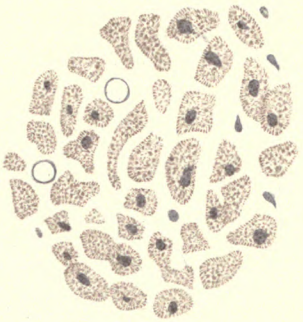

X.

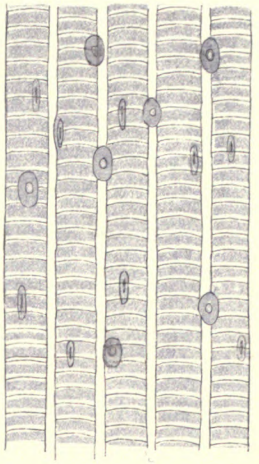

XI.

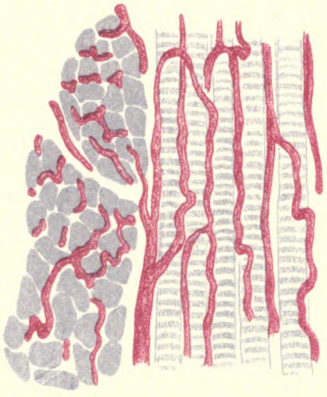

XII.

XIII.

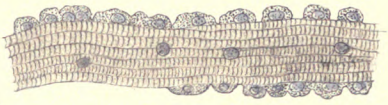

XIV A.

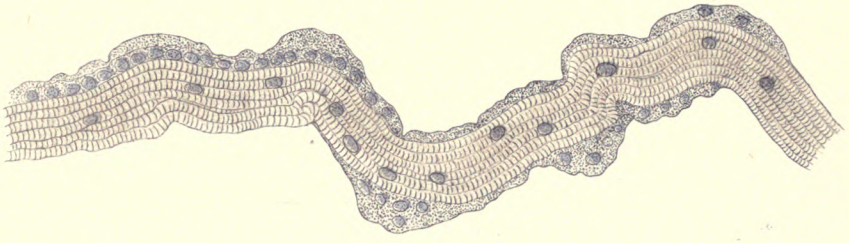

XIV B.

XV.

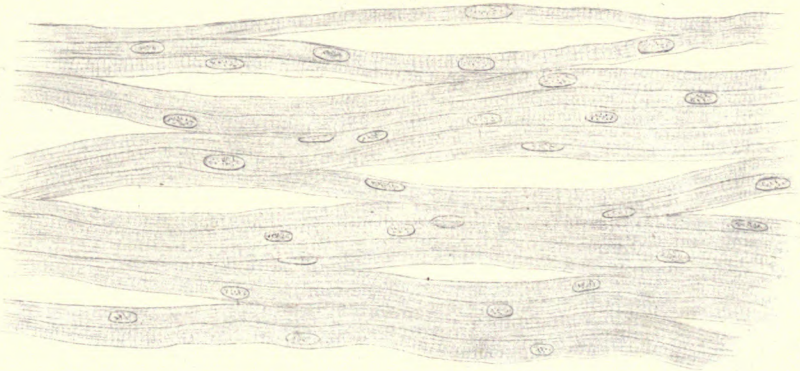

XVI.

muscle fibres are large uninuclear plasma cells. The structure of the fibres is the same as represented in figure VI. of the preceding Plate.

Fig. XII. Striped muscle fibres viewed in longitudinal and in transverse sections, showing the blood-vessels injected with carmine gelatine. The blood-vessels have chiefly a longitudinal arrangement; the left part of the figure shows both the muscle fibres and their capillary vessels more or less cut transversely.

Fig. XIII. Two muscle fibres of hydrophylus, each passing into a tendon bundle of connective-tissue fibres.

Fig. XIV. A and B, muscle fibres of diaphragm of adult guinea-pig. The muscle corpuscles are greatly enlarged and very numerous; they are probably used here for the new formation of striated muscle substance.

Fig. XV. Transverse section through several bundles of striped muscle fibres of tongue. The bundles are separated by vascular fibrous-connective tissue, perimysium; this passes in between the fibres of the individual bundles. The clefts between perimysium and muscle fibres and between the individual muscle fibres themselves belong to the lymphatic system.

Fig. XVI. Network of muscle fibres of heart of pig.

CHAPTER XII.

CEREBRO-SPINAL NERVES.

The nerve trunks of the cerebro-spinal system, with the exception of the optic nerve, consist of the following structures (Axel Key and Retzius):

a) The *epineurium*, the common framework, is composed of bundles of fibrous-connective tissue arranged as larger or smaller trabeculæ, which cross each other and thus form a more or less dense plexus. Between the bundles are the ordinary flattened more or less branched connective-tissue corpuscles, and in many places the coarsely granular plasma cells (Waldeyer), showing slight amœboid movement. Fat-tissue, a plexus of lymphatics, and the numerous blood-vessels supplying the nerve trunk are all embedded in the connective tissue of the epineurium.

b) In this common framework are embedded smaller and larger bundles of nerve fibres, *nerve bundles*. Each of these has its own special sheath of connective tissue, *perineurium*. This possesses a lamellar structure; the lamellæ consist of bundles of fibrous-connective tissue, and between them are the flattened connective-tissue cells, situated as it were in more or less continuous (interlamellary) lymph-spaces. The nerve bundle is a simple one if the nerve fibres are embedded in a uniform matrix, compound if in connexion with the perineurium thicker or thinner septa of connective tissue pass into the bundle, and thus separate the nerve fibres into two or more secondary groups.

c) The nerve fibres within a nerve-bundle are separated from each other by *endoneurium*, viz. a more or less homogeneous substance containing numerous minute connective-tissue fibre-bundles and isolated fine connective-tissue fibres and flattened nucleated connective-tissue cells. The connective-tissue fibres are twisted and coiled round the individual nerve fibres in a complex manner, in some places forming a dense sheath around them. The endoneurium contains capillary blood-vessels having chiefly a longitudinal course.

The endoneurium is accumulated occasionally on the surface of the nerve bundle, but inside the perineurium, as a special thinner or thicker peripheral layer.

Between the inner surface of the perineurium and the nerve fibres themselves there are always to be found longer or shorter lymph-spaces lined by a layer of endothelium, and these are connected with lymph-spaces of the endoneurium passing in between the individual nerve fibres. The endoneural lymph-spaces have been injected by Axel Key

and Retzius in connection with the lymph spaces of the perineurium, and they have been shown by those observers to be so numerous that each individual nerve fibre appears surrounded by them.

The microscopic branches of a nerve trunk consist of a simple or compound nerve bundle ensheathed in lamellar perineurium. The farther branches of these possess only a very delicate perineurium, which becomes the more delicate the further away from the original nerve bundle; still further microscopic branches are reached where the perineurium has dwindled down to a single layer of cells, now forming a continuous endothelial membrane. Finally these branches split up into small groups and individual nerve fibres.

Most of the nerve fibres contained in a nerve bundle are medullated; they differ, as regards thickness, in different animals, in different nerve trunks, and even in the same nerve bundle of the same nerve trunk, some being thick, others medium-sized, and still others thin fibres (Kölliker).

Each fibre possesses the following structure: (1) the axis cylinder, a solid soft pale central cylindrical structure, showing under certain conditions a longitudinal striation due to its being composed of minute longitudinal fibrils,—elementary fibrils (Max Schultze)—between these fibrils are seen minute granules, indicative of an interfibrillar granular cement-substance.

(2) The medullary sheath, a thick bright sharply outlined (doubly contoured) fatty semifluid substance, forming a thick insulating cylindrical sheath around the axis cylinder; it coagulates very soon after death, and easily separates spontaneously, after pressure water, &c., into smaller or larger simple or compound spherical or globular droplike bodies. Under certain conditions (especially perosmic acid), it has been seen (Stilling, Schmidt, Lantermann, Kuhnt, and others) to consist of *longer* or *shorter cylindrical sections* which are imbricated with their margins. They have not been demonstrated, however, on all medullated nerve fibres, and not in the whole course of the same fibre. Each of these sections contains a reticulum (Stilling, Klein), a honey-combed framework; in the meshes of this lies embedded the above-named bright fatty substance. The reticulum appears as a honey-comb only when looked at from the surface; when viewed in profile it seems to be composed of rod-like elements (Lantermann, MacCarthy); these are in reality the septa of that honey-comb seen sideways. This reticular honey-combed framework probably corresponds to the 'stroma of neurokeratin,' demonstrated by Kühne and Ewald after digesting medullated nerves in trypsin. Between axis cylinder and medullary sheath is a very narrow space, periaxial space (Klebs), containing fluid albuminous cement-substance; during life this space is in ordinary nerve fibres very minute, the axis cylinder being almost entirely in contact

with the medullary sheath, but after shrinking of the axis cylinder the space becomes more distinct. After hardening reagents the above albuminous substance becomes coagulated, and then corresponds to a thin granular membrane surrounding the axis cylinder, described by Todaro and Schmidt. With nitrate of silver this layer appears occasionally as if composed of transverse bands or rings (Axel Key and Retzius), and may thus appear as if the axis cylinder itself were composed of transversely arranged bandlike or discoid masses (Frommann, Grandry).

(3) The sheath of Schwann, a thin hyaline elastic membrane, surrounds the medullary cylinder. This outer sheath is possessed at regular intervals of annular constrictions, first discovered by Ranvier, and hence known as Ranvier's nodes. Each node is due to an annular fold of the sheath of Schwann projecting towards the axis cylinder. The part of the sheath between each two constrictions is called an 'interannular segment.' In the concavity of the constriction is a finely granular substance (Ranvier) of the nature of albuminous cement-substance. Corresponding to each constriction the medullary sheath is interrupted (Ranvier), so that the axis cylinder is here in contact with the sheath of Schwann. According to Engelmann also the axis cylinder is discontinuous at the node. The interruption of the medullary sheath at the nodes of Ranvier has probably an important bearing on the circulation of plasma to the axis cylinder (Ranvier). Owing to this state the nerve fibres present a peculiar dark cross at the node after silver staining, viz. the albuminous cement-substance around the constricting fold becomes stained by silver, and this penetrates hence gradually into the interior and stains a similar cement-substance covering the axis cylinder. According to whether the staining extends a longer or shorter distance on the surface of the axis cylinder upwards and downwards the node, the longitudinal branch of the 'cross,' appears longer or shorter (Axel Key and Retzius). The nodes of Ranvier are to be met with on all medullated nerve fibres of all vertebrates; they are more numerous on broad nerve fibres than on thin ones (Axel Key and Retzius).

(4) On the inner surface of the sheath of Schwann are elliptical nuclei surrounded by a smaller or larger film of protoplasm (Axel Key and Retzius, S. Mayer, and others). These nucleated cells do not belong to the sheath of Schwann, which, like the sarcolemma, is structureless; they are generally pressed against the medullary sheath, and are situated as it were in a small excavation of the outer surface of this latter structure. The protoplasm of these nucleated cells varies in amount in different states of development, and contains occasionally pigment granules (S. Meyer). The nuclei contain an intranuclear reticulum. Every interannular segment of the nerve fibres of higher vetebrates possesses as a rule only one such cell in about the middle of the

REGENT LIBRARY
OF THE
UNIVERSITY
OF
CALIFORNIA

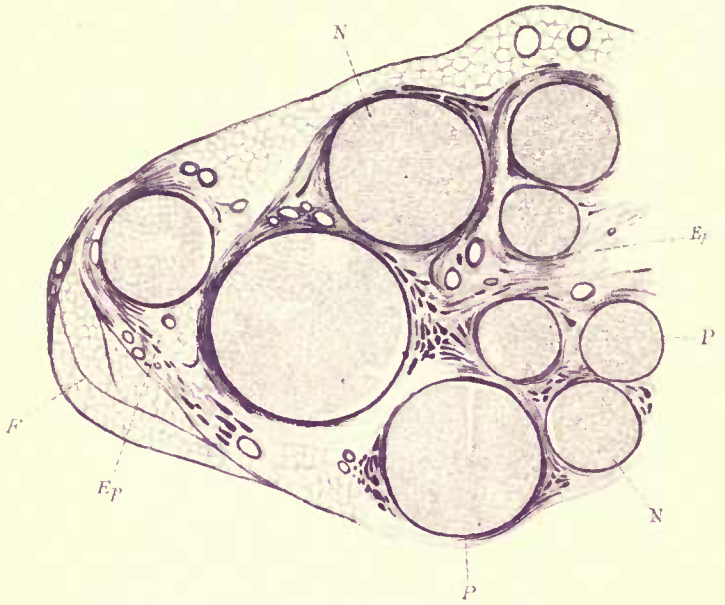

I.

II.

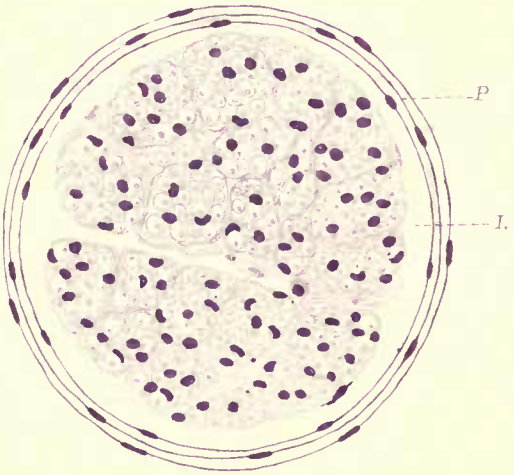

III

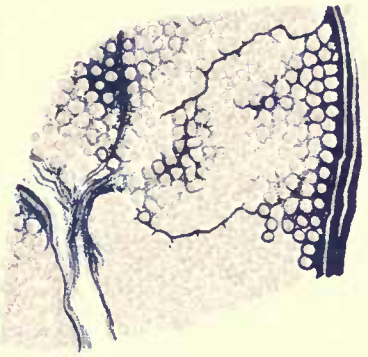

IV.

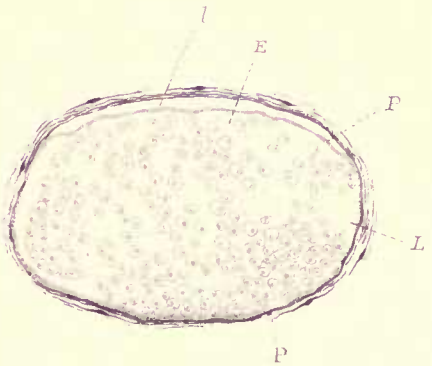

V

VI.

E. Noble Smith fecit

Mintern Bros. imp.

segment (Axel Key and Retzius), occasionally (though rarely) there are more than one (Lantermann). These cells, being analogous to the muscle corpuscles of striped muscle fibres, may be appropriately called *nerve corpuscles.*

The medullated nerve fibres contained in the nerve bundles of a cerebro-spinal nerve trunk are of various thickness, as mentioned above, fine fibres being interspersed amongst thick ones ; in some nerve trunks, as the branches derived from the sacral plexus, the fine nerve fibres are in some bundles aggregated into special smaller or larger groups.

Some medullated nerve fibres, especially motor fibres and the nerve fibres of electric organs, when approaching their terminal distribution, divide into two or more branches, the division taking place at a node of Ranvier.

Some medullated nerve fibres, especially in the opticus and the central nervous organs, possess more or less regular varicose thickenings ; these are not due to a coagulation of the medullary sheath, as formerly believed, but to local accumulations, in the periaxial space, of the albuminous cement-substance mentioned above (Axel Key and Retzius).

Medullated nerve fibres when approaching their terminal distribution lose their medullary sheath, they then consist merely of the axis cylinder and the sheath of Schwann, with the nucleated cells on its inner surface : these are the pale or non-medullated nerve fibres, to which we shall return in a future chapter.

Still nearer the termination the non-medullated fibres lose their sheath of Schwann ; and now we have the axis cylinder merely covered from place to place with an elongated nucleated cell plate (Klein), generally of considerable size, and rolled more or less around the axis cylinder. This cell plate corresponds to a nerve corpuscle and possesses in some instances fine processes passing along the axis cylinder for a shorter or longer distance. Ultimately the axis cylinder becomes quite free, and separates into the constituent elementary fibrils which become connected with each other into a network. (See a future chapter.)

The elementary fibrils within the axis cylinder, and especially after they have separated from the latter, show, in the fresh condition as well as after staining with chloride of gold, minute more or less regular varicosities (Max Schultze, Cohnheim and others).

PLATE XVII.

Figures II. IV. and VI. after Axel Key and Retzius, 'Studien in der Anat. des Nervensystems,' Part II. Plate XVII.

Fig. I. Part of a transverse section of sciatic nerve of dog, as seen under a magnifying power of about 40.

Ep. Epineurium, consisting of bundles of connective-tissue fibres cut in different ways, and containing many vascular trunks cut transversely.

F. Fat tissue contained in the epineurium.

P. Perineurium, being the sheath for the individual nerve bundles.

N. Nerve fibres, composing the nerve bundles cut transversely.

Fig. II. Part of a transverse section of sciatic nerve of man; magnifying power about 4. The lymphatics of the nerve have been injected with blue by 'puncture.' Numerous nerve bundles are shown surrounded by more or less continuous blue rings, the injected perineurium.

Fig. III. Transverse section through a microscopic nerve branch of human epiglottis; magnifying power about 120. This branch represents a compound nerve bundle surrounded by perineurium.

P. Perineurium, consisting of lamellæ of fibrous-connective tissue, alternating with flattened nucleated connective-tissue cells.

L. Lymph-space between perineurium and surface of nerve bundle.

The medullated nerve fibres are seen as circles with a central dot, viz. medullary sheath and axis cylinder, in transverse section; they are embedded in endoneurium, containing numerous nuclei, belonging to the connective-tissue cells of the latter.

Fig. IV. Part of a transverse section of a nerve bundle of lumbar plexus of man. On the right are seen the lymph-spaces of the perineurium injected with blue matter; they are in connection with similarly injected larger spaces (on the left) of the endoneurium, and with the minute spaces around the individual nerve fibres, seen in transverse sections. Magnifying power about 70.

Fig. V. Transverse section through a nerve bundle of tail of mouse. Magnifying power about 120.

P. Perineurium.

L. Lymph-space of perineurium.

E. Endoneurium.

L. Lymph-spaces of endoneurium.

Fig. VI. Part of a transverse section of sciatic nerve of man; the lymph-spaces of the epineurium have been injected by 'puncture' with blue matter. Magnifying power about 60.

REESE LIBRARY
OF THE
UNIVERSITY
OF
CALIFORNIA

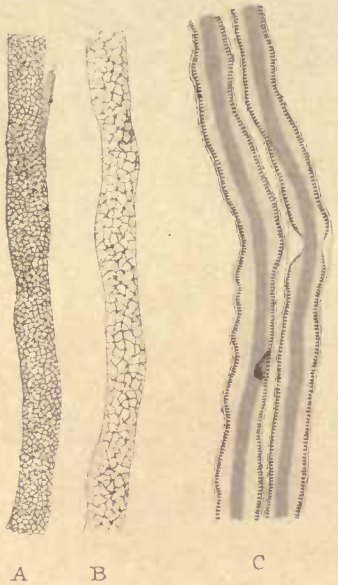

A B C

VII.

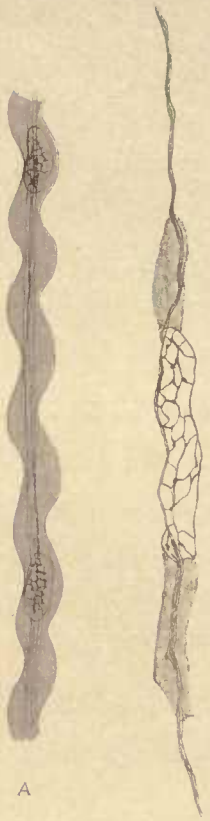

A B

VIII.

IX.



X.

XI.

XII.

XIII.

PLATE XVIII.

Figures IX. XI. and XIII. copied from Axel Key and Retzius, Part II. Plates VII. and VIII.

Figures VII. and VIII. B drawn under a magnifying power of about 400; figures IX. XI. and XIII. under one of about 750; and figures VIII. A, X. and XII. under about 300.

Fig. VII. Medullated nerve fibres of sciatic nerve of frog, acted upon by chromate of ammonia.

A. Showing in a surface view the reticular framework of the medullary sheath.

B. The meshes are here much larger, owing probably to a swelling up of the fatty matter contained in the reticulum.

C. Two nerve fibres, showing the deeply stained axis cylinder, the periaxial space, the medullary sheath, apparently composed of rods, and the fine sheath of Schwann. The left fibre shows a nucleus of the outer sheath, the right one shows a Ranvier's node; the sheath of Schwann is incorrectly drawn, it ought to be constricted at the node.

Fig. VIII. Two non-medullated nerve fibres of mesentery of newt, acted upon by chromate of ammonia. A, deeply stained with hæmatoxylin; B, unstained.

A shows an exceptionally broad wavy hyaline sheath of Schwann, surrounding the axis cylinder, which is here a small bundle of primitive fibrils. Two nuclei, showing the intranuclear network, belong to the nerve corpuscles of the sheath.

B. A non-medullated nerve fibre that has left its sheath of Schwann, but is still covered with a very elongated cell-plate, nerve corpuscle, containing a long nucleus. This latter shows a beautiful reticulum. The cell-plate is in reality folded, and the axis cylinder, here a bundle of elementary fibrils, is fixed in the fold.

Fig. IX. Part of a medullated nerve-fibre of brachial plexus of bird. The nerve had been prepared with perosmic acid; it shows the medullary sheath composed of shorter and longer imbricated sections, the hyaline sheath of Schwann, a nucleated nerve corpuscle between this and the medullary sheath, and pressed into a shallow excavation of the latter.

Fig. X. Two nerve fibres of sciatic nerve of dog, after chromic acid and spirit; showing the axis cylinder, the nodes of Ranvier, the sheath of Schwann and nuclei, apparently belonging to this latter. There are traces of medullary substance to be seen as blotches inside the sheath of Schwann.

Fig. XI. A node of Ranvier of a medullated nerve fibre, viewed from above. The medullary sheath is discontinuous at the node, whereas the axis cylinder passes from one segment into the other; at the node the sheath of Schwann appears thickened.

Fig. XII. Small dividing (sympathetic) bundle of medullated nerve fibres of mesentery, after acetic acid. The fine sheath covering the bundle and its branches, is the perineurium reduced to a single layer of nucleated endothelial plates seen in profile and at a short distance from the nerve fibres. These latter appear composed of longer or shorter sections. This appearance is entirely due to the medullary sheath of these fibres being composed of cylindrical sections, as described and figured above. The nuclei belong to the nerve corpuscles of Schwann's sheath of the individual nerve fibres.

Fig. XIII. Several fibres of a bundle of medullated nerves, acted upon by nitrate of silver, of sparrow, to show the peculiar behaviour of the nodes of Ranvier towards this reagent. The silver has penetrated through the node and has stained the surface of the axis cylinder at this place for a short distance; this forms the longitudinal branch of the 'cross' mentioned on a former page. The axis cylinder and the outline of the medullary sheath are well seen in each fibre.

CHAPTER XIII.

THE SPINAL CORD.

The spinal cord is invested in a compound connective-tissue sheath, which is richly supplied with vessels and nerves, and is continued on to the nerve roots of the cord.

This sheath is known as (*a*) Dura mater, (*b*) Arachnoidea, and (*c*) Pia mater.

a) The *dura mater* is composed of lamellæ more or less intimately connected with one another. In the outer part the lamellæ possess a more circular, in the inner a more longitudinal course (Axel Key and Retzius). The number of lamellæ varies of course according to the thickness of the dura; each lamella consists of a layer of parallel bundles of fine connective-tissue fibres; the bundles of neighbouring layers are placed under more or less acute angles.

Between the lamellæ lie flattened more or less branched connective-tissue cells arranged in a network. To these corpuscles corresponds, just as in the cornea (see p. 30), a system of lacunæ and canals, the lymph-canalicular system. In some places a network of fine elastic fibres is present underneath the cell plates.

The inner surface of the dura is covered with a thin hyaline elastic membrane, and on this is a continuous layer of nucleated endothelial plates, like that covering the serous membranes. The outer surface is also covered with a continuous layer of endothelium (Axel Key and Retzius). The dura mater is richly supplied with blood-vessels and nerves.

b) The *arachnoidea* is, according to Axel Key and Retzius, a delicate membrane composed of paralled and closely placed bundles of connective-tissue fibres; between the bundles are the connective-tissue corpuscles. The bundles of this groundwork or 'outer membrane' have pre-eminently a longitudinal direction. On the outer free surface is an endothelial membrane composed of one or two layers of endothelial plates. On the inner surface lies a fenestrated membrane composed of anastomosing thinner and thicker trabeculæ of connective-tissue fibres. The trabeculæ having chiefly a transverse direction, it follows that the meshes are stretched in a transverse diameter. This fenestrated or 'inner membrane' is covered, on the surface directed towards the subarachnoidal space, by a single layer of endothelial plates.

c) The *pia mater* consists (Axel Key and Retzius) of an external and an internal portion. The former is composed chiefly of longitudinal bundles of connective-tissue fibres, and is covered towards the subarachnoidal space with an endothelial membrane.

The latter or intima piæ is a meshwork of bundles of connective-tissue fibres; its inner surface is lined with a layer of endotheloid cells, and between this layer and the connective-tissue meshwork is a network of fine elastic fibres. The numerous blood-vessels of the pia are situated between the external and internal layer, whence they penetrate, carried by a prolongation of the latter, into the substance of the cord.

Numerous nerve fibres (medullated and non-medullated) may be traced (Axel Key and Retzius) in the external portion of the pia. They run either isolated or in small bundles, or they form a plexus.

Between the arachnoidea and pia is a spongy tissue by which the subarachnoidal space becomes subdivided into numerous minute lacunæ. This tissue is the *sub-arachnoidal tissue*, and it consists of a plexus of smaller and larger trabeculæ of fibrous-connective tissue ensheathed in endothelium and containing a few elastic fibres. We have described and figured it on a former occasion as being identical with the fenestrated membrane composing the omentum. Axel Key and Retzius have shown that the subarachnoidal tissue is a prolongation of the inner or fenestrated portion of the arachnoidea. It forms in some places on the external surface of the pia, with which it is in continuity, smaller or larger membranous condensations as epipial tissue (Axel Key and Retzius). The trabeculæ of the subarachnoidal tissue contain larger and smaller blood-vessels.

On each side of the cord, from the foramen ovale magnum down to the filum terminale, between the anterior and posterior nerve roots, is the ligamentum denticulatum stretching like a diaphragm between arachnoidea and pia; the subarachnoidal space is hereby subdivided into a spatium subarachnoidale anterius and posterius (Axel Key and Retzius).

The ligamentum denticulatum consists of trabeculæ of connective-tissue bundles, anastomosing with one another and hereby forming a spongy or fenestrated substance; the trabeculæ are covered with endothelium.

This tissue passes into the external layer of the pia mater.

There are also isolated connective-tissue trabeculæ extending between dura mater and arachnoidea; they are ensheathed in endothelium, like all other structures, blood-vessels and nerves, passing from the one membrane to the other. These trabeculæ are in some places more numerous than in others, most numerous in the posterior parts of the cord.

Between the dura mater and arachnoidea is the subdural, between archnoidea and pia mater the subarachnoidal lymph space. The subdural space does not communicate with the subarachnoidal space (Luschka, Axel Key and Retzius).

The nerve roots receive a prolongation from both the arachnoidea and dura mater as arachnoideal and dural sheath respectively (Axel Key and Retzius). And, in accordance with this, the lymph-spaces of the peripheral nerves (spinal as well as cerebral), and their ganglia, have been injected from the subdural and subarachnoidal spaces respectively (Axel Key and Retzius).

Neither the subdural nor the subarachnoidal space is one open and free cavity, there being numerous connective-tissue trabeculæ passing between the dura mater and arachnoidea as well as between the latter and the pia mater (subarachnoidal tissue), as mentioned above.

The cord itself contains a framework, and embedded in it the white and grey matter.

A) The *framework* consists of the following parts:—

1) A relatively large process of fibrous-connective tissue passes from the intima piæ into the anterior fissure up to the anterior commissure, where it loses itself amongst the connective tissue of the white substance.

Similar pial prolongations pass, at different points of the circumference, into the minute septa stretching between sections of the white matter, especially of the lateral and anterior tracts.

All these prolongations of the intima piæ carry blood-vessels into the cord.

2) The chief part of the framework is a semifluid substance (neuroglia-matrix), which under certain reagents (chromates) presents a granular aspect (Gerlach), but in the fresh state and with other reagents is quite homogeneous (Walther). This substance fills all the interstices between the nervous elements of the cord.

In this homogeneous matrix are embedded very numerous minute fibrils, neuroglia fibrils, which anastomose with one another in a network. These fibrils are in chemical respects similar to elastic fibrils (Gerlach), although they are not so resistent against acids and alkalies.

In the white matter the neuroglia fibrils have pre-eminently a *longitudinal direction*, except in the septulis, where they form networks in a transverse direction; in the grey matter they extend uniformly in all directions.

In connection with the network of neuroglia fibrils we find flattened branched nucleated connective-tissue corpuscles; the processes of these lose themselves amongst the former.

Neuroglia-matrix, neuroglia fibrils and branched cells form the 'Neuroglia.' These three substances have a definite relation to one another: the greater the amount of one, the greater is also that of the other two.

The amount of neuroglia varies in different parts of the white and grey matter. It forms definite accumulations in the following parts :—

a) On the external surface of the white matter it is present as a special peripheral crust underneath the intima piæ ; the latter easily separates from the former. The neuroglia fibrils are pre-eminently horizontal.

b) As septa passing between different sections of the white matter (posterior, lateral and anterior tracts). The so-called posterior fissure is, properly speaking, only a septum of this kind.

c) As the ground-substance of the anterior and posterior nerve roots from the point of entrance into the cord.

d) A layer of neuroglia of considerable thickness surrounds the epithelium lining the central canal, as the 'central grey nucleus' of Kölliker. The neuroglia fibrils run here chiefly in three different directions : some are arranged in a circular manner, others longitudinally, and still others have a radiating direction. The first and second are most numerous ; the third are prolongations of the epithelial cells themselves, these being conical cells drawn out into a fine fibril passing radially into the depth. The basis of the epithelial cells is on the free surface and is covered with fine cilia.

e) A peculiar accumulation of neuroglia is found in the posterior portion of the posterior horns of the grey matter as substantia gelatinosa of Rolando.

Besides these accumulations of neuroglia there is a certain difference in the distribution of this substance in the various parts of the white matter, it being always more abundant in the inner and outer parts of the white matter, i.e. near the grey matter and the peripheral crust, than in the parts between.

B) The *white matter* is composed of medullated nerve fibres. They vary in size, some being broad, others of medium size, and still others fine. Each nerve fibre possesses an axis cylinder, and around this a medullary sheath. The axis cylinder possesses the same fibrillar structure as that mentioned of the axis cylinder in general. In the broad fibres and in those of medium size the medullary sheath possesses a laminated structure. There is no definite evidence of the presence of a sheath of Swann or of nerve corpuscles, as in the medullated fibres of the cerebro-spinal nerves. The nerve fibres are embedded in, or separated by, neuroglia, as described above. The great bulk of the nerve fibres of the white matter run in a longitudinal direction, and are grouped as such, for each half of the cord, in the anterior, lateral and posterior tract. But the white matter contains also nerve fibres that have an oblique or even horizontal direction. Horizontal nerve fibres are present :—

a) In the anterior commissure, i.e. at the bottom of the anterior fissure. The anterior commissure is composed merely of medullated nerve fibres that pass from the grey matter of the anterior horns of one side into the white matter of the anterior tract of the opposite side (Gerlach).

b) Medullated nerve fibres emerge from the sides of the grey matter of the anterior horns, and after a short horizontal course enter the white matter of the lateral tracts.

c) Similarly nerve fibres emerge from the grey matter of the posterior horns, and after a longer or shorter horizontal course enter the white matter of the posterior tracts (Gerlach). It is probable that they leave the posterior tracts again as the nerve fibres of the posterior nerve roots.

d) The fibres of the posterior nerve roots pass into the grey matter of the posterior horns as horizontal fibres, either directly, as the lateral portion of the nerve roots, or indirectly, viz. by first entering the white matter of the posterior tract and running in it in a longitudinal direction upwards or downwards for a longer or shorter distance ; this is the median portion of the posterior nerve roots.

The medullated nerve fibres of the anterior nerve roots pass in an oblique direction from the grey matter of the anterior horns through the white matter.

The amount of white matter gradually increases towards the medulla oblongata.

C) The *grey matter* occupies the central part of the cord in the well-known shape of an H, of which we distinguish the lateral parts or columns from the median part containing the central canal and the 'central grey nucleus' of Kölliker surrounding it. Between this and the anterior fissure lies the anterior grey commissure, and in front of this the anterior white commissure ; behind the central grey nucleus lies the posterior commissure. The columns consist of an anterior, middle and posterior part, the former (viz. anterior) representing the anterior, the latter (viz. posterior) the posterior horn. The breadth and depth of the different parts of the grey matter vary in a definite manner in the different sections of the cord.

The substance of each column of grey matter contains, in a matrix of neuroglia very similar in character to that of the white matter, (1) ganglion cells, and (2) nerve fibres.

1) The *ganglion cells* are arranged more or less distinctly in groups. Thus they form three groups in the anterior horn : (*a*) an anterior, (*b*) a lateral, and (*c*) an inner group ; the ganglion cells of the lateral group are larger than those of the anterior, and these again larger than those of the inner group.

In the dorsal region there is a group of large ganglion cells situated in the middle part of the column near the posterior commissure ; they represent Clarke's column (Lockhart Clarke).

The lateral group extends, in the cervical portion, into the white matter, i.e. in amongst the medullated nerve fibres. In the cervical swelling of the cord of calf the lateral group appears to be subdivided into an anterior group of large, and a posterior one of small spindle-shaped ganglion cells.

In the posterior horns the ganglion cells are arranged as small groups in the anterior part, and as numerous isolated cells in the middle and lateral parts. The former are much larger than the latter, which are the smallest ganglion cells in the grey matter. A few small ganglion cells are present also around the 'central grey nucleus' (Gerlach).

The ganglion cells are relatively large, branched cells, containing in some animals small masses of yellow pigment. Numerous minute fibrils can be distinguished in the cell substance (Max Schultze); these fibrils are connected with each other in a network. Each cell possesses in about the centre a large oval nucleus composed of a well-defined membrane, and containing an intranuclear network; in about the middle of this is a large highly refractive thickening—nucleolus. Most ganglion cells, especially the large ones, are surrounded by a lymph-space, pericellular space, through which pass the processes of the cell. Their shape varies considerably, some cells being very elongated, others less so. But they are all possessed of several processes, i.e. they are multipolar. Some ganglion cells, especially those of the posterior horns, appear spindle-shaped, but each extremity is branched into several processes.

Carrière found ganglion cells in the anterior horns anatomosing with one another by means of shorter or longer processes.

The processes of the ganglion cells are of two kinds, branched and unbranched. The former are, just like the body of the ganglion cells, composed of fibrils, which run in a longitudinal direction and appear to pass in a fanlike manner from the processes into the body of the cell (Max Schultze). The branched processes ramify dichotomously into fine filaments. The unbranched processes are pale and finely striated bands, very attenuated where they join the cell-body; they represent the axis-cylinder processes discovered by Deiters. Gerlach has proved that they are present only in the ganglion cells of the anterior horns. The axis-cylinder process is generally single, occasionally there are two in one cell. After having left the cell-body the axis cylinder soon becomes ensheathed in a medullary sheath, that is, becomes converted into a medullated nerve fibre, which passes into an anterior nerve root.

2) The *nerve fibres* of the grey matter are of different kinds: (*a*) the great bulk of the grey matter is composed of a minute and dense network of fine fibrils; this has been first demonstrated by Gerlach. Deiters had already proved that the (medullated) nerve fibres which pass through the posterior nerve roots (either directly or

indirectly) into the grey matter undergo repeated division while in the latter, and Gerlach has shown that their ultimate branchlets anastomose with the above network. This network, which is known as Gerlach's nerve network, must therefore be regarded as composed of minute or primitive nerve fibrils. The nerve network surrounding the central grey nucleus of Kölliker is less dense than in other parts.

Now, the branched processes of all ganglion cells of the grey matter attach themselves to Gerlach's nerve network, and there exists therefore an essential difference between the ganglion cells of the anterior and posterior horns (Gerlach); the former are connected, on the one hand, with Gerlach's nerve network, on the other hand they pass directly into a medullated nerve fibre of the anterior nerve root; the latter are not directly connected with any nerve fibres, but anastomose with them only indirectly, viz. through Gerlach's nerve network.

b) We have mentioned above that the axis-cylinder processes of the ganglion cells of the anterior horns pass through the latter as medullated nerve fibres, and enter the anterior nerve roots. But there are other nerve fibres that pass from the anterior nerve roots into the anterior horns without however belonging to any ganglion cells, viz. nerve fibres which enter the lateral tracts of the white matter, and pursue their course in this latter towards the brain as longitudinal fibres (Kölliker).

c) Nerve fibres that originate in Gerlach's nerve network, chiefly of the outer portions of the grey matter, and having entered the lateral tracts of the white matter of the same side, pursue their course towards the brain as longitudinal nerve fibres.

d) Similar fibres originating in Gerlach's nerve network of the anterior horns pass (through the anterior white commissure) into the anterior tracts of the white matter of the opposite side.

e) Bundles of fine nerve fibres run horizontally from one column of the grey matter to the other, in front as anterior grey commissure, behind as posterior grey commissure.

f) Numerous nerve fibres pass in a horizontal direction through the anterior portion of the posterior horns; they branch very repeatedly (Gerlach).

g) A large bundle of nerve fibres runs in a longitudinal direction and occupies about the middle of the posterior horns. This bundle receives fibres from the posterior tract of the white matter as well as from the posterior nerve root.

h) In the dorsal region there exist bundles of fine nerve fibres which originate from Clarke's column of ganglion cells. These bundles, according to Gerlach, are three as a rule, viz. one running backwards, and two crossing each other, and passing in an outward direction.

i) The nerve fibres which enter the grey matter of the posterior horns as the lateral portion of the posterior nerve root have been mentioned above; they run in this latter for a shorter or longer distance upwards or downwards in a longitudinal direction, and afterwards lose themselves in Gerlach's nerve network.

The spinal cord is richly supplied with minute blood-vessels, each of which lies in a perivascular lymph-space formed by the neuroglia.

CHAPTER XIV.

THE OPTIC NERVE.

We shall consider in this chapter the optic nerve and its sheaths, up to near its passage through the cribrous membrane of the eyeball: this latter will be described in connection with the retina in a future chapter.

1) The sheaths of the optic nerve.

Through the investigations of Schwalbe, Axel Key and Retzius, H. Schmidt, Michel, Wolfring and Waldeyer, it is ascertained that the opticus possesses three distinct sheaths: (*a*) An external sheath, being a prolongation of the dura mater (dural sheath, Axel Key and Retzius); it consists of fibrous-connective tissue of the same dense arrangement as in the dura mater of the brain and spinal cord. (*b*) A middle sheath (arachnoidal sheath, Axel Key and Retzius), being a continuation of the arachnoidea; it shows the same structure as this. (*c*) An inner sheath of fibrous-connective tissue, being a continuation of the pia mater (pial sheath, Axel Key and Retzius).

Between the dural and arachnoidal sheath is a continuous lymph space (subdural space of the optic nerve, Axel Key and Retzius; subvaginal space, Schwalbe), in open communication with the subdural space of the brain. The surfaces of the dural and arachnoidal sheaths bordering on this space are covered with a single layer of endothelium. From the dural sheath pass a few connective-tissue trabeculæ through the subdural space to the arachnoidal sheath.

Between the arachnoidal and pial sheath is another lymph space, the subarachnoidal space of the optic nerve (Axel Key and Retzius). This space is permeated by a spongy mass composed of anastomosing trabeculæ of connective tissue connected with the arachnoidal sheath, and identical in structure and arrangement with the subarachnoidal tissue mentioned in connection with the arachnoidea of the spinal cord. The surfaces of these trabeculæ, just like the surface of the arachnoidal and pial sheath bordering on the subarachnoidal space, are covered with an endothelial membrane. The subdural and subarachnoidal spaces of the optic do not intercommunicate with one another (Axel Key and Retzius), and can be freely injected separately from the subdural or subarachnoidal space respectively of the brain (Schwalbe, Axel Key and Retzius).

2) The substance of the optic nerve proper.

The optic nerve is composed of a great number of bundles of nerve fibres, sepa-

rated by a framework of thicker and thinner trabeculæ of fibrous-connective tissue, with numerous connective-tissue cells, and directly continuous with the pial sheath of the optic nerve. This framework is, at the same time, the carrier of blood-vessels, large branches as well as capillary vessels. It forms a special accumulation around the arteria centralis.

The bundles are of various sizes, some being two and three times thicker than others; they are composed of medullated nerve fibres, that do not possess any sheath of Schwann. The medullary sheath appears sometimes to possess more or less regular varicosities, owing to an accumulation of fluid between axis cylinder and medullary sheath, as mentioned on a former occasion (p. 87). Under certain conditions (nitrate of silver), the nerve fibres do not show any such varicosities (Schwalbe).

The individual nerve fibres within each bundle are separated from one another by a substance that, in all its essential characters, is identical with the neuroglia described of the white substance of the cord; viz. (*a*) a hyaline, probably semifluid ground-substance; (*b*) in this lies a network of fibrils, probably elastic, forming a network, and arranged pre-eminently in a longitudinal direction; and (*c*) numerous flat nucleated cells possessed of fine processes that lose themselves amongst the fibrils of the neuroglia.

A large lymph-space may be injected (Axel Key and Retzius) on the inner surface of the pial sheath; this space does not communicate with the subarachnoidal space of the optic nerve. It is continuous with lymph spaces situated between the bundles of nerve fibres and the trabeculæ of the framework, and with smaller spaces within the trabeculæ. The perifascicular lymph spaces communicate with minute spaces separating the individual nerve fibres in a similar manner as described on p. 84, and figured on Plate XVII. fig. IV.

Besides the differences in structure between the optic nerve and spinal nerve, as described in a former chapter (XII.), there is this great distinction, that in an ordinary cerebro-spinal nerve the component bundles, nerve bundles, possess a special sheath, perineurium, as distinct from the general framework of the nerve, epineurium. But in the optic nerve this is not the case, the whole nerve being comparable to a compound nerve bundle (see p. 84, *b*), the pial sheath being the perineurium, and the connective-tissue trabeculae in connection with it being the septa by which the subdivision into smaller and larger groups of nerve fibres is effected.

PLATE XIX.

Fig. I. Transverse section through the cervical part of the spinal cord of calf, one half of the cord being represented only. Magnifying power about 40.

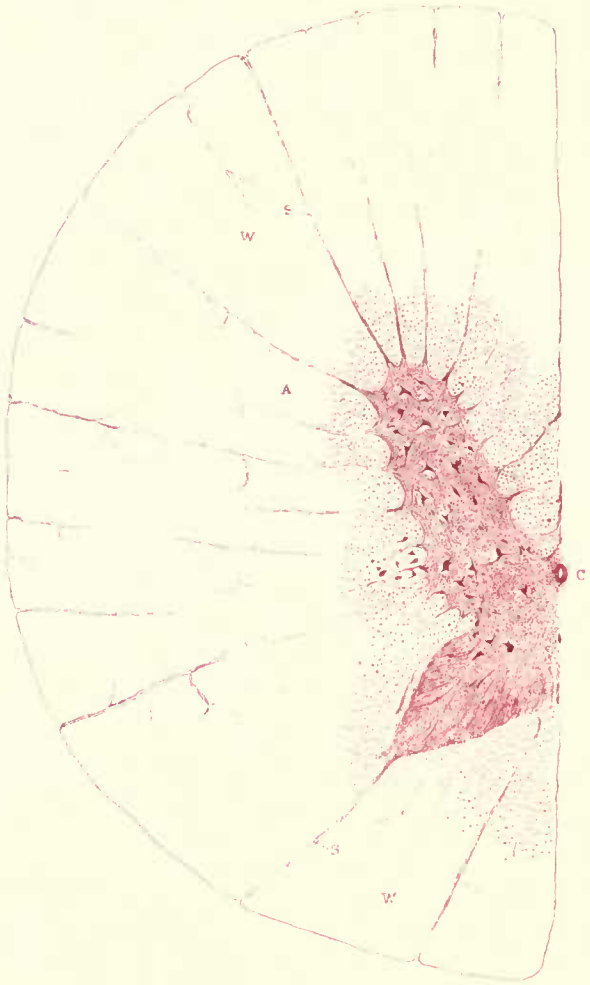

I.

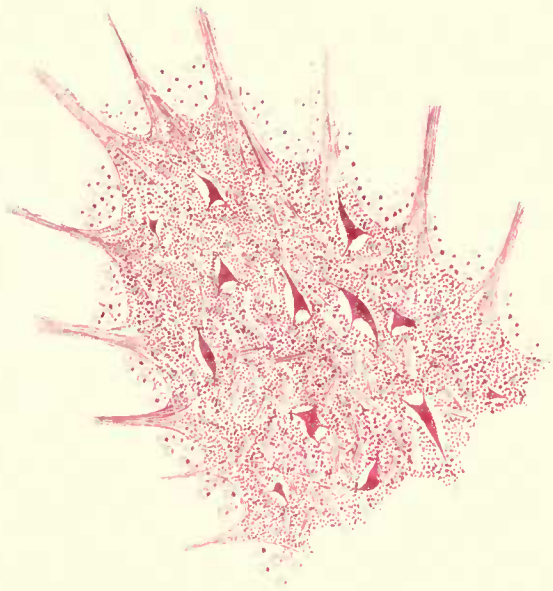

II.

III

IV

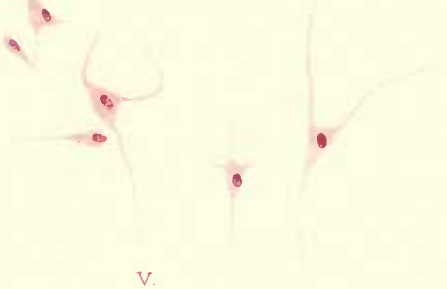

V.

VI.

VII.

VIII

REESE LIBRARY
OF THE
UNIVERSITY
OF
CALIFORNIA.

W. White matter, showing the small septa passing into it from the periphery; the nerve fibres (in transverse section) are represented only in the circumference of the grey matter.

C. Central canal of grey matter.

A. Anterior horn of grey matter.

The processes that pass from the anterior and inner portion of the anterior horn, including the upper S, correspond to the anterior nerve roots.

The process coming out from the posterior angle of the posterior horn, also marked S, corresponds to the lateral bundle of the posterior nerve root.

In the grey matter the ganglion cells are indicated as larger or smaller corpuscles, each surrounded by a pericellular lymph space. The anterior and lateral group in the anterior horn are well shown; also a few large cells in the front part of the posterior horn.

Fig. II. The front part of the anterior horn of fig. I., more highly magnified. Numerous nerve fibres pass from the grey matter into the septa of the white matter; this latter is not represented, except by a few adjacent medullated nerve fibres in transverse section.

Fig. III. From a transverse section through the spinal cord of calf, magnified about 180 diameters, showing part of the central canal, and the tissue immediately around it, viz. the 'central grey nucleus.' The canal is lined with epithelium, composed of ciliated more or less conical cells; in most instances a filamentous process passes from the cell into the tissue underneath. This tissue contains, in a hyaline matrix, a network of fibrils; most of these run horizontally, others have a longitudinal course, and appear therefore here cut transversly, i.e. as small dots. The nuclei correspond to the cells of the neuroglia, the cell substance not being shown. Both the nuclei of the neuroglia cells, as well as those of the epithelium, contain three or more large disc-shaped particles. But there is a delicate reticulum, besides, in the nucleus. This is, however, not seen on account of the relatively low magnifying power.

Fig. IV. Transverse section through the same cervical part of spinal cord of calf as represented in fig. I., seen under a lens.

A. Anterior fissure.

p. The tissue filling the so-called posterior fissure.

Fig. V. Several multipolar ganglion cells, as they appear under a power of 100, in a section through the anterior horns of a hardened spinal cord.

Fig. VI. Transverse section through the cervical swelling of the spinal cord of calf, as seen under a lens. The grey matter differs in its general outline from that of fig. IV., inasmuch as the anterior and posterior grey commissure is reduced to a thin plate.

Fig. VII. The posterior horn of grey matter shown in fig. I., under a higher magnifying power.

n. Nerve fibres, in transverse section, surrounding the grey matter.

G. Large ganglion cells in the front part of the posterior horn; there are several other small ones seen in the left part of the horn. Bundles of more or less horizontal nerve fibres are seen in the posterior and lateral portion; they are fibres that pass either directly from the posterior nerve roots into the posterior horn, or that come from, or pass respectively into the posterior and lateral tract of the white matter.

Fig. VIII. Portion of a transverse section through the grey matter (of cervical region) near the central canal. Magnifying power about 100.

A. Nerve fibres, cut transversely, of anterior tract of white matter. The horizontal nerve fibres passing amongst them are the fibres forming the anterior commissure.

B. Blood-vessels.

C. Central canal.

There are several large ganglion cells belonging to the front part of the posterior horn.

Near the anterior tract of white substance (A) are a few small ganglion cells belonging to the inner group of cells of the anterior horn.

PLATE XX.

Fig. IX. From a transverse section through the white matter of the cord of calf (hardened in bichromate of potash). Magnifying power about 300.

In the upper part are shown two isolated flattened nucleated branched cells of the neuroglia, under a somewhat higher power than the rest. In the bulk of the figure we see the nerve fibres in transverse section. They are of different sizes, and possess around the deeply stained axis cylinder a laminated medullary sheath. The nerve fibres are embedded in the neuroglia; this contains in a matrix which is here granular, but under other conditions appears homogeneous, numerous elastic fibrils seen here in transverse sections as minute dots, on account of their having a course parallel to the long axis of the cord. Amongst the neuroglia are here seen two branched connective-tissue cells—neuroglia cells.

Fig. X. Copied from Gerlach, part of fig. 223, in Strickers' 'Handbook of Histology.' A multipolar ganglion cell isolated from the grey matter of the cord, showing the numerous processes branching dichotomously, and losing themselves in the general network of fine nerve fibrils—Gerlach's nerve network. The minute dots amongst this

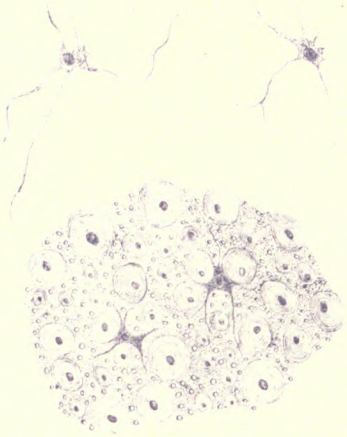

IX.

X.

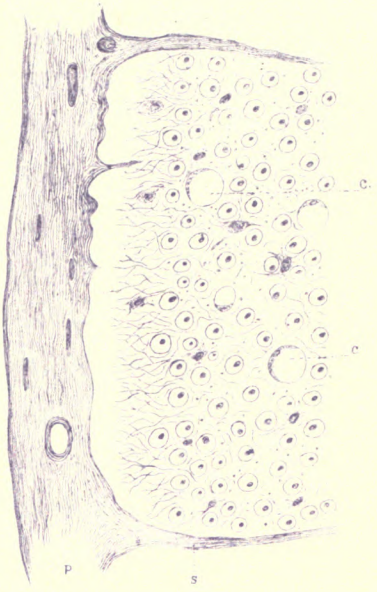

XI

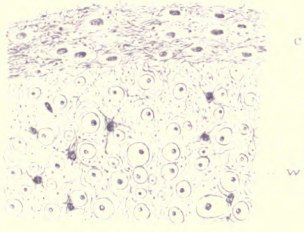

XII

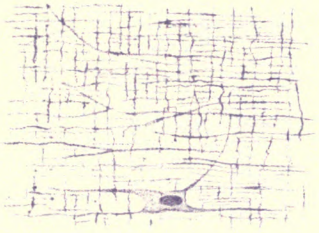

XIII

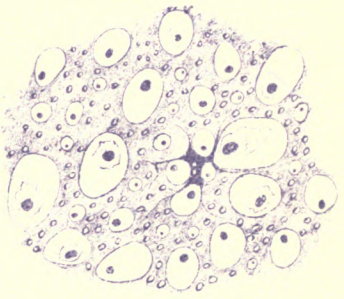

XIV

XV.

XVI.

XVII.

E. Noble Smith fecit

Mintern Bros imp

network are fibrils viewed in optical sections. In this network terminates a minute nerve, being a branch of a larger nerve that entered the grey matter.

Fig. XI. Small part of a transverse section of optic nerve. Magnifying power about 300.

P. Pial or inner sheath, a fibrous-connective tissue, showing oblong nuclei of connective-tissue corpuscles, and one or two blood-vessels in section.

S. A septum passing from the inner sheath; by such septa the nerve fibres are arranged in groups; in the present figure is shown part of a large group of nerve fibres. The nerve fibres are seen in transverse section, and each of them is indicated by a deeply stained small axis cylinder surrounded by a thin medullary sheath. The unequal size of the nerve fibres is probably due to their being possessed of varicosities, and therefore cut either through a varicosity or between.

The nerve fibres are separated from the pial sheath by a large lymph space. Between the fibres is seen neuroglia, composed like that of the cord of a general matrix, in which lies a network of elastic fibrils, and numerous branched flattened connective-tissue cells.

Fig. XII. From a transverse section through the most peripheral part of the white matter of the cord. Magnifying power about 300.

w. White matter showing the transverse sections of the nerve fibres, separated by neuroglia, viz. hyaline matrix, network of neuroglia fibrils and numerous branched nucleated connective-tissue cells.

c. Special peripheral layer of neuroglia on the surface of the white matter. The network of neuroglia fibrils has a pre-eminently horizontal direction.

Fig. XIII. From a longitudinal section through a septum of the white matter of the cord, showing neuroglia fibrils and one branched neuroglia cell. Magnifying power about 450.

Fig. XIV. From a transverse section through the white matter of a cord hardened in chromic acid. Nerve fibres of different sizes in transverse section; they show the medullary sheath greatly shrunk around the axis cylinder. The neuroglia, in its different parts, is well shown. Magnifying power about 450.

Fig. XV. Copied from Gerlach, fig. 224 in Strickers' 'Handbook.' An isolated ganglion cell of the anterior horn of the human cord. Magnifying power 150.

a. Axis-cylinder process.

b. Pigment.

The fine network in the upper part of the figure belongs to the nerve network of Gerlach, in which terminate the branched processes of the ganglion cell.

Fig. XVI. Copied from Klein, fig. 71 in 'Handbook for the Physiological Labora-

tory.' Isolated spindle-shaped ganglion cell of spinal cord of calf. Magnifying power about 450.

Fig. XVII. From a transverse section through the cervical region of spinal cord of calf, showing six ganglion cells of the lateral group of the anterior horn extending between the nerve fibres of the white matter. Magnifying power about 350.

G. Fibres of the grey matter passing into the lateral tracts.

g. Ganglion cells.

W. Medullated nerve fibres of the white matter in transverse section.

The large nerve fibres with large axis cylinder are probably derived from the ganglion cells, viz. axis-cylinder processes that have become invested in a medullary sheath.

The ganglion cells extending chiefly in a longitudinal direction appear, in a transverse section, cut obliquely or transversely.

CHAPTER XV.

THE BRAIN.

The Membranes of the Brain.

The description given of the minute structure of the membranes of the spinal cord applies also to those of the brain, with the following additions :—

a) The blood-vessels of the dura mater cerebralis present a very peculiar arrangement and appearance (Boehm, Axel Key and Retzius, Paschkewicz, Michel) ; according to Axel Key and Retzius there is one system on the outer and another system on the inner surface. The former contains more or less wavy arteries accompanied on each side by a vein. The arteries branch dichotomously and anastomose with one another ; the same is the case with the veins. The inner system is a network of capillary vessels with elongated meshes. At the nodes of this network are peculiar ampullar, spindle-shaped or saccular dilatations. Now this inner system is connected with the outer one in two ways : first, by minute arterial branches (capillary arteries) passing in an oblique direction from the latter to the former, and, secondly, by the above ampullæ being connected by capillary veins with the veins of the outer system. So that these ampullæ represent the roots of the veins.

b) The arachnoidal villi (Luschka), or glandulæ Pacchioni, are club-shaped or pear-shaped prolongations of the subarachnoidal network of trabeculæ of connective tissue (ensheathed in endothelium) ; they are covered by a thin continuation of the arachnoidea itself, including the covering endothelium (Axel Key and Retzius). These villi differ very much in size, some being single, others compound. They do not project into the subdural space, but are pushed with their stalks through minute holes of the inner laminæ of the dura mater, and thus project into the venous sinuses of the latter ; but they are not quite free in the sinus, being covered with a delicate membrane of connective tissue and endothelium derived from the dura mater (Axel Key and Retzius). By injecting the subarachnoidal spaces of the brain Axel Key and Retzius found that the injection matter passes freely from the spongy subarachnoidal tissue through the stalks into the arachnoidal villi ; these being of the same spongy structure as the subarachnoidal tissue become, through the filling of their spaces, greatly enlarged ; then the injection matter fills the space between each villus and its dural covering, and finally enters the

venous sinus itself. So that there exists a mediate connection between the subarachnoidal cavity and the venous sinuses of the brain.

c) The pia cerebralis corresponds to the intima piæ spinalis only. The numerous blood-vessels situated in the pia mater and passing to and from the brain possess a special outer sheath by means of which they are fixed on to the pia mater. When entering the brain-substance they carry with them that adventitial sheath (Kölliker, Virchow, Axel Key and Retzius, and others). This sheath is an endothelial membrane only in the capillary vessels, in the larger (arterial and venous) branches it contains in addition a variable amount of connective tissue.

The telæ choroideæ are folds of the pia mater, including a prolongation of the subarachnoidal tissue. They possess on their free surface a layer of polyhedral endothelial cells, which in the embryo are ciliated. In man these cells are pigmented.

The subdural space of the brain does not communicate with the subarachnoidal cavities nor with the ventricles (Luschka, Axel Key and Retzius).

The subarachnoidal spaces do not communicate with a space said to exist between pia mater and brain substance proper (epicerebral space of His), the pia mater being everywhere in immediate contact with the brain surface.

The Brain Substance.

A) The *framework* or neuroglia of the grey and white matter of the brain (cerebrum, cerebellum and medulla oblongata) is very similar to that described of the spinal cord. It consists of (*a*) the same homogeneous (occasionally granular) matrix in which lie (*b*) numerous minute elastic fibrils connected into a network. In the white matter these fibrils possessing a pre-eminently longitudinal direction are parallel to the nerve fibres. (*c*) Branched nucleated flattened neuroglia cells—Deiters' cells—are connected with this network by their numerous processes (Boll, Golgi).

Different from the spinal cord, the neuroglia of the white matter of the brain contains rows of small cells, each with a spherical nucleus, between bundles of nerve fibres. These small cells form special accumulations in the bulbus olfactorius and in the cerebellum. In the grey matter the numerous branched connective-tissue cells surrounding the blood-vessels (Boll) are specially to be mentioned. Lewis found them accumulated also around the ganglion cells of the cerebral hemispheres. According to Duke Charles of Bavaria, there are numerous colourless blood-corpuscles present around the blood-vessels and ganglion cells of the cerebral hemispheres, not only in disease, but also in the perfectly normal brain.

The neuroglia forms a special accumulation lining the ventricles of the brain, the ependyma. This is a direct continuation of the 'central grey nucleus' of the cord, and

possesses the same structure. The epithelium lining the ventricles is likewise a layer of columnar ciliated epithelial cells.

B) The *white matter* is distributed in the brain in the shape of large tracts of medullated nerve fibres, connecting the grey matter of different systems, or collected in the roots of the cerebral nerves. These various tracts of nerve fibres in their special significance will be briefly mentioned presently. A detailed description of the distribution of both, white and grey matter, will not be entered into here, since this is not so much a subject of Histology as of Anatomy. The reader will find in Strickers' 'Handbook' an exhaustive treatise by Meynert, the great authority on this subject.

The nerve fibres of the white matter are, like those of the spinal cord, medullated, and without any sheath of Schwann. They vary greatly in size, some being broad, others of middle size, and many others very fine. They present themselves often in the shape of varicose fibres, that is: possessed of more or less regular swellings, which, as has been pointed out previously, are not due to a corresponding thickening of the medullary sheath, but to a local accumulation of fluid between this and the axis cylinder. According to Boll there occur small multipolar ganglion cells between the nerve fibres of the white matter of the cerebral hemispheres.

The white matter of the cerebral hemispheres is composed of the following masses of nerve fibres: (*a*) nerve fibres connecting the grey matter of the hemispheres with the large cerebral ganglia; these fibres form the corona radiata, having a pre-eminently radiating direction. (*b*) There are masses of nerve fibres joining identical parts of the hemispheres of the two sides, as corpus callosum and anterior white commissure. (*c*) The association systems: these are fibres, more or less arcuate, on the inner surface of the cortex joining different parts of the hemispheres of the same side. (*d*) Special tracts of nerve fibres connecting the hemispheres with the cerebellum; they branch off from the corona radiata, pass beneath the thalamus opticus and corpus quadrigeminum into the tegmentum cruris, and after a total crossing in the processus cerebelli ad corpus quadrigeminum enter the cerebellum.

Meynert distinguishes the first section of the nervous conduction, viz. that between the grey matter of the cerebrum and the large cerebral ganglia, as the *projection system* of the *first order*.

As *projection system* of the *second order* he considers the tracts of nerve fibres passing between the cerebral ganglia and the central grey matter lining the ventricles, viz. motor fibres passing through the crus cerebri and pons into the white matter of the cord. But the crus cerebri contains also sensory fibres; these pass from the

posterior tracts of the white matter of the cord through the pyramidal crossing into the crus and through this directly into the corona radiata.

The *projection system* of the *third order* comprises the tracts of nerve fibres belonging to the roots of the cerebral nerves.

The white matter of the cerebellum, besides the above connection with the hemispheres, passes through the fasciculus cuneatus and gracilis (Burdach) into the posterior tract, through the corpus restiforme into the lateral tract of the white matter of the spinal cord. Stilling's great work on the cerebellum gives a detailed account of the course of the fibres in that organ.

C) The *grey matter* is distributed in the following four categories (Meynert): (I) as the cortex of the cerebral hemispheres; (II) as the large cerebral ganglia, viz. corpus striatum, corpora albicantia, thalamus opticus and corpus quadrigeminum; (III) as the grey substance of the medulla oblongata, rhomboidal fossa, and aqueductus Sylvii, the grey matter lining the ventricles, the tuber cinereum and infundibulum; (IV) as the cortex and central grey matter of the cerebellum.

In all parts of the grey matter we find, besides the neuroglia, a dense network of fine fibrils (Rindfleisch, Gerlach), directly connected with the terminal branches of repeatedly dividing fine medullated nerve fibres.

This fine network corresponds completely to Gerlach's nerve network of the grey matter of the spinal cord.

Embedded in the nerve network are ganglion cells, which vary as regards size, shape and arrangement in the different systems of the grey matter; they are everywhere multipolar, and their processes lose themselves in the nerve network. Most of the ganglion cells possess however an unbranched axis-cylinder process that passes into the white matter, viz. becomes sooner or later invested in a medullary sheath, thus representing a medullated nerve fibre.

I) Meynert distinguishes in the cortex of the cerebral hemispheres of man five layers:

1) The superficial layer containing only few and small multipolar ganglion cells, the great bulk being occupied by neuroglia and the nerve network.

2) The next layer possesses a large number of densely aggregated small ganglion cells of a more or less pyramidal shape.

3) Then follows the chief layer, being the broadest and containing a large number of not particularly crowded pyramidal ganglion cells of large size. The pyramidal ganglion cells of these two layers are always placed vertically to the surface of the grey

matter: they possess, (α) a process of the apex more or less branched and directed towards the surface; (β) the lateral processes of the basis, always branched; both these processes lose themselves in the nerve network; (γ) the median process of the basis, being the axis-cylinder process, remains unbranched and passes downwards into the white matter as a medullated nerve fibre.

4) This layer contains numerous small irregular ganglion cells with few branched processes; while the ganglion cells of the former layers are regarded by Meynert as motor cells, the last-named ones are considered by him as connected with sensory nerves; they represent the 'granular formation' of Meynert.

5) The last layer contains more or less spindle-shaped and branched ganglion cells of medium size; their direction is chiefly parallel to the surface.

The processes of the ganglion cells of these different layers are, like those of the spinal cord, finely striated, being composed of minute fibrils. This is especially the case with those of the ganglion cells of the third or chief layer; Meynert, Huguenin and Boll describe also the axis cylinder of these cells as distinctly fibrillar.

All these ganglion cells possess a spherical or slightly oval nucleus; under some conditions of preparation this contains a large nucleolus. The cell substance is a distinct network of fibrils, and includes sometimes small masses of yellowish brown pigment.

Each ganglion cell and its processes lie in a lymph space, pericellular space (Obersteiner).

Different from this arrangement, in five layers, is, according to Meynert:—

a) The grey matter of the posterior portion of the occipital lobe about the sulcus hippocampi, in which Meynert distinguishes eight layers. The most prominent features are here the small multipolar cells, Meynert's 'granular formation.'

b) The cortex of the cornu Ammonis, in which the small cells of the above fourth layer are wanting, but the cells of the second and especially of the third layer form the chief elements. Meynert on account of this designates the above third layer as the 'formation of the cornu Ammonis.'

c) In the walls of the fossa Sylvii, especially in the claustrum, the spindle-shaped cells of the above fourth layer are the prevalent features.

d) The bulbus olfactorius. This contains a small central cavity lined with columnar ciliated cells, and a thick cortex. In man the upper part of this is white matter, being a continuation of the tractus olfactorius; the rest is grey matter and consists, from below upwards, of:—

α) A layer of non-medullated nerve fibres possessed of a sheath of Schwann; these pass into the olfactory nerve proper, to the olfactory end-organ.

β) Stratum glomerulosum. This consists of a layer of spherical or irregular glomeruli;

each glomerulus consists in man of a convolution of an olfactory nerve fibre, containing besides, numerous small nucleated Deiters' cells.

γ) Clarke's stratum gelatinosum, containing first small loose, then larger, denser multipolar ganglion cells of a spindle or pyramidal shape. Their processes lose themselves in the fine nerve network forming the ground-substance for this layer.

According to Golgi, the nerve fibres of the glomeruli undergo repeated division, and Huguenin saw in the dog processes of the ganglion cells of the third layer in connection with nerve fibres coming from the glomeruli.

δ) This layer is very thick and contains, in a network of fibrils, numerous smaller and larger groups of nuclei, similar in structure to the nuclear layer of the cerebellum (see below).

II) In the large cerebral ganglia the cells are multipolar, and, as in the other regions, connected by their processes with the nerve network, which forms also here the matrix of the nervous part of the grey matter. In the thalamus opticus the ganglion cells are pre-eminently spindle-shaped (Meynert).

In the corpus striatum the cells contain a large amount of pigment.

III) The grey matter of this category represents chiefly the substance in which most of the cerebral nerves find their origin. The ganglion cells are multipolar and arranged in groups as the so-called 'nuclei' of the respective nerves; their processes, except the axis-cylinder process, terminate in the nerve network of the ground-substance.

The cells of the different 'nuclei' differ in size, aspect and number of processes. The cells of some regions, as some parts of the fossa rhomboidalis, or the substantia nigra Soemmeringi (between basis and tegmentum of the pedunculus cerebri), are filled with a dark brown pigment.

The ganglion cells belonging to the 'nucleus' of the optic nerve are multipolar and of different sizes. Meynert describes, in the anterior ganglion of the corpus quadrigeminum, large spindle-shaped cells belonging to a group of nerve fibres which join this ganglion with the 'nucleus' of the oculomotor and trochlear nerve.

The ganglion cells of these two nerves are situated underneath the aqueductus Sylvii; they are large multipolar spindle-shaped cells, each with an axis-cylinder process.

In the 'nuclei' of the fifth are specially conspicuous the large multipolar ganglion cells, containing pigment; they belong to its motor root situated in the anterior portion of the fossa rhomboidalis. The sensory nuclei contain small multipolar cells.

Of a similar appearance are the ganglion cells representing the nucleus of the nervus abducens, situated laterally in the anterior part of the fossa rhomboidalis.

The ganglion cells of the 'nucleus' of the facial nerve, in the depth of the fourth ventricle, are conspicuous by their size and their processes.

The ganglion cells of the different portions of the 'nucleus' of the acoustic nerve are situated in the fossa rhomboidalis, near the surface, from the middle line to the pedunculi cerebelli; they vary in size and shape; those of the outer 'nucleus' are fewer in number than those of the inner and anterior 'nucleus,' the former being at the same time pyramidal in shape.

The cells of the 'nucleus' of the glossopharyngeus and vagus, situated in the fossa rhomboidalis, are spindle-shaped.

The ganglion cells of the spinal accessory nerve belong to the grey matter of the medulla oblongata behind the central canal; they are large and multipolar.

Conspicuous by their size are the multipolar ganglion cells representing the 'nucleus' of the hypoglossal nerve, situated in front of the canal in the medulla oblongata.

The olivary bodies contain in a matrix of grey nerve network slender multipolar ganglion cells.

For a detailed account of the 'nuclei' of the cerebral nerves the reader is referred to the works of Lockhart Clarke, Stilling, and Meynert.

IV) The cortex of the cerebellum shows the following layers :—

1) A broad *cortical layer*, the so-called molecular layer, containing in a ground-substance of nerve network (besides the neuroglia of the ordinary description) numerous dichotomously branched fibrillar processes ascending from the deeper layer (ganglion cells of Purkinje) and running towards the surface. On their way from the depth to the surface, the processes become finer and lose themselves partly in the nerve network, and partly in small pear-shaped multipolar ganglion cells (Sankey, Denissenko). The nerve network in the more superficial parts of this layer possesses an arrangement more or less distinctly vertical to the surface, except at this latter, where it is more horizontal. The nerve network of the deeper part is of an uniform arrangement. This superficial layer should be called more appropriately the fibrillar layer.

2) A single layer of large spindle-shaped ganglion cells, *Purkinje's cells*. Each of them possesses one branched process extending into the former layer, and an unbranched or axis-cylinder process passing into the depth. The substance of each ganglion cell is a minute network of fibrils extending into the branched processes. The nucleus is spherical or oval. Each cell is surrounded by a pericellular space. Meynert ascribes to them a thin hyaline capsule; according to Oberseiner this capsule is a network of neuroglia fibrils.

3) Between the layer of Purkinje's cells and the white matter is a broad layer, the *nuclear layer*. This contains a network of minute fibrils (Stieda, and Denissenko) continuous with, and similar in structure to, the nerve network of the cortex, and a great number of spherical nuclei, to which various investigators ascribe a totally different nature. While some (Kölliker, Gerlach) regard them as belonging to neuroglia cells, others (Henle, Merkel) describe them as lymph corpuscles, and still others (Stilling) as minute multipolar ganglion cells. Denissenko distinguishes amongst them nuclei that belong to Deiters' or neuroglia cells, then nuclei that pertain to cells of a special nature, and nuclei indicative of small ganglion cells.

The 'nuclei dentati' of the cerebellum contain, just like the olivary bodies, a matrix of fine nerve network and slender multipolar ganglion cells. The 'nuclei' of Stilling, situated near the nuclei dentati, are distinguished from these latter by the greater size of their ganglion cells.

The substance of the brain and cerebellum is rich in blood-vessels. Those of the grey matter pass from the pia (or *vice versa*) in a more or less vertical and oblique direction and anastomose into an uniform network. Those of the white matter form a network, the meshes of which are pre-eminently longitudinal. The vessels lie invaginated in lymph channels, perivascular lymphatics of His. Between the vascular adventitia and the neuroglia boundary of the perivascular channel extend numerous neuroglia fibrils. The pericellular lymph spaces, mentioned above as surrounding the ganglion cells and their processes, anastomose with the perivascular lymph channels (Lewis).

The hypophysis cerebri and the pineal gland will be considered in a future chapter, in connection with several other organs, as the suprarenal capsule and coccygeal gland, whose structure and function are not well known.

PLATE XXI.

Fig. I. Vertical section through the grey matter of the cerebral hemisphere of dog, as seen under a low power. On the left side is the superficial layer of the cortical grey matter. Owing to the low power the small ganglion cells and the neuroglia cells in it are not visible. A blood-vessel is seen passing from the surface into this layer. Next follows a layer of small ganglion cells, then a broad layer of ganglion cells, gradually increasing in size—'formation of the cornu Ammonis,' Meynert. The 'granular formation' of small cells, viz. the fourth layer in the human cortex, and the fifth layer of spindle-shaped cells, is not visible here.

The ganglion cells in this and the next following figure are in so far of a peculiar



I.



II.

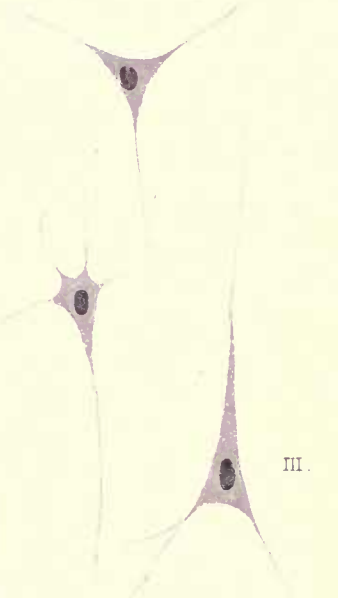

III.

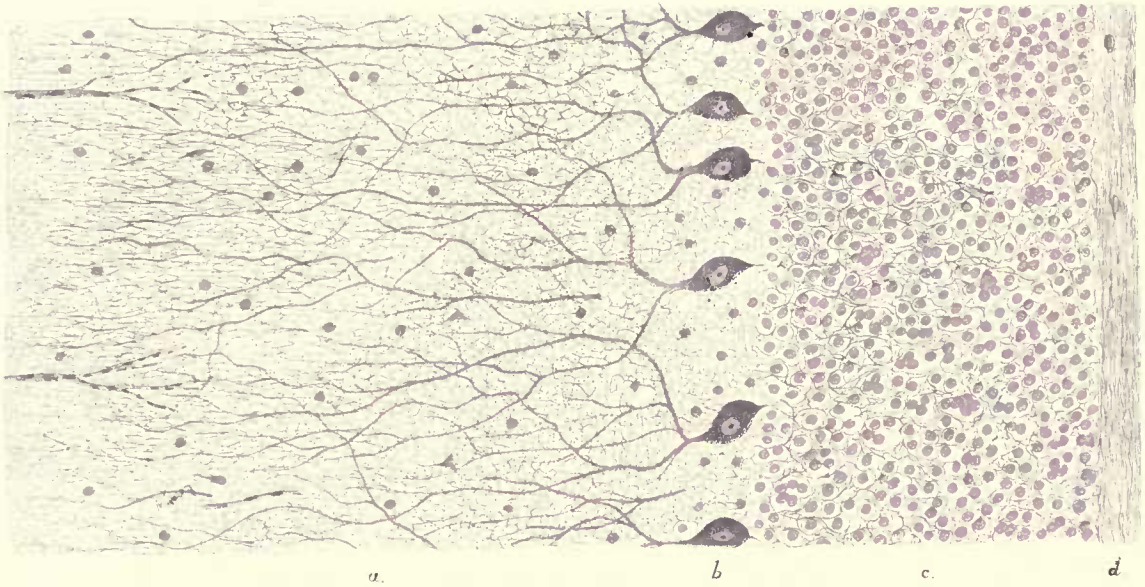

VI.

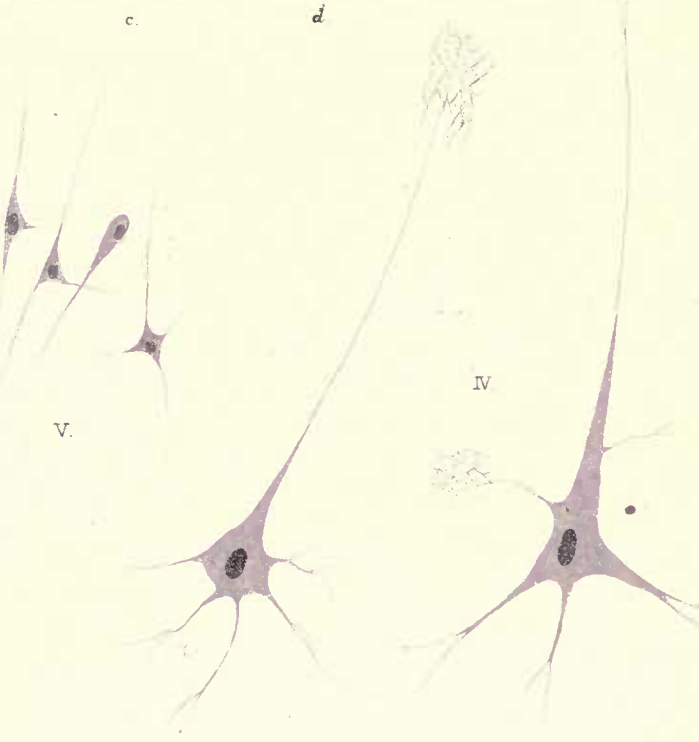

IV.

V.

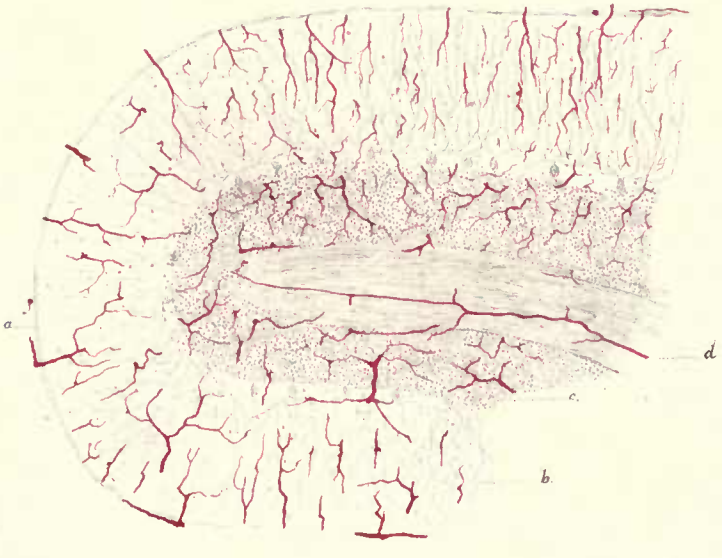

VII.

REESE LIBRARY
OF THE
UNIVERSITY
OF
CALIFORNIA.

aspect, as the space is well shown in which lie cell and processes, especially the process of the apex; the substance of the ganglion cells is not visible except the nucleus and its nucleolus.

Fig. II. From the same section as fig. I., more highly magnified. The matrix is a network of minute fibrils, possessing chiefly a direction vertical to the surface of the hemisphere.

The ganglion cells are marked by their pericellular space; of the substance of the cells only the nucleus and its nucleolus are visible. Several deeply stained nuclei belonging to the neuroglia cells, or cells of Deiters', are contained in the matrix.

A branched capillary vessel with its perivascular space is seen in the right lower part of the figure.

Figures III. IV. and V. show isolated, chiefly pyramidal, ganglion cells of various sizes, of the grey matter of the cerebral hemispheres of man. Fig. IV. shows the typical pyramidal cells of the 'formation of the cornu Ammonis;' they possess a long process of the apex, terminating in the fine nerve network of the cortex, so do also the lateral basilar processes. The median basilar process is, in most instances, the unbranched axis-cylinder process, but in this instance it appears branched.

Fig. VI. Vertical section through the grey matter of the human cerebellum Magnifying power about 100.

a. The superficial, so-called molecular, or better fibrillar layer, containing in a matrix of fine nerve networks the dichotomously branched processes of the large ganglion cells of Purkinje, that form the second layer *b.*

The nuclei of the fibrillar layer belong partly to small ganglion cells, partly to Deiters' neuroglia cells. Two (branched) capillary blood-vessels pass from the free surface, that is, from the pia mater, into the grey matter.

c. Nuclear layer, containing, in a fine nerve network, numerous groups of nucleated cells, of which only the nuclei are visible.

d. Part of white substance.

Fig. VII. Vertical section through a 'lamina' of cerebellum of rat, showing the distribution of the blood-vessels, injected with carmine gelatine, seen under a low magnifying power.

a. Pia mater of the surface.

b. Fibrillar cortex, so-called molecular layer.

c. Nuclear layer. Between this and the preceding layer are indications of Purkinje's cells.

d. White matter forming the centre of the 'lamina.' The capillary blood-vessels of the grey matter are more numerous than those of the white matter; in the cortical layer the vessels have a more or less vertical direction.

CHAPTER XVI.

CEREBRO-SPINAL GANGLIA.

It has been mentioned in a former chapter that the spinal nerves, when leaving the cord, receive from both the dura mater and arachnoidea a special investing sheath, viz. the dural and arachnoidal sheath. The pia mater does not send any prolongation on to the nerves, but is merely perforated by them. The same holds good for the cerebral nerves.

The dural sheath of the ordinary cerebro-spinal nerves becomes identified with the epineurium, the arachnoidal sheath with the perineurium described in Chapter XII. p. 84.

The cerebro-spinal ganglia possess a continuation of both the dural and arachnoidal sheath (Axel Key and Retzius), the former being placed quite peripherally, the latter more internally. The former is, like the epineurium of nerve trunks, to which it corresponds, composed of more or less dense fibrous-connective tissue, connective-tissue corpuscles, and networks of elastic fibres; the latter possesses, just like the perineurium of the nerve bundles, a lamellar structure, thin lamellæ of bundles of fibrous-connective tissue alternating with flattened endotheloid connective-tissue corpuscles.

Both the epineural and perineural connective tissue of the ganglia send into the anterior longer or shorter septa. Those of the latter (viz. perineurium) follow the larger and smaller nerve bundles that permeate each ganglion in different directions.

The endoneurium of the nerve-roots passes also into the ganglion between groups and individual ganglion cells, as the so-called interstitial tissue. Its structure is similar to that of the nerve bundles, being a homogeneous matrix containing in some places minute bundles of connective-tissue fibrils; protoplasmic nucleated cells are also present in it. These are very numerous, and in all their characters are identical with the flattened connective-tissue cells described of the endoneurium of the nerve bundles.

The endoneural connective tissue of the ganglion contains numerous capillary blood-vessels connected into a network, and nerve fibres that wind themselves through the groups of ganglion cells.

Following the nerve trunk into the ganglion, we notice that the ganglion cells form at first smaller or larger groups or rows between the peripheral nerve bundles; by-and-bye they appear also between the central ones; finally their number increases to such an extent that the nerve bundles become split up into small groups of fibres which run between the groups of ganglion cells in an oblique or longitudinal, or even transverse direction.

The nerve fibres in the cerebro-spinal ganglia of man and other vertebrates are, as a rule, medullated nerve fibres of the same structure as those described of the cerebro-spinal nerves; amongst them we meet also with a few non-medullated nerve fibres, i.e. axis cylinder with hyaline sheath of Schwann and nerve corpuscles.

The ganglion cells themselves are spherical, oval, or pear-shaped cells, occasionally slightly flattened. They vary considerably in size, some being three and four times as large as others. Their substance contains a homogeneous interstitial matrix, and a fine network of fibrils (Schwalbe), which occasionally near the periphery possess an arrangement parallel to the surface, and therefore are more or less concentric. Each ganglion cell contains about the centre a relatively large well-defined spherical or slightly oval nucleus, which under certain conditions shows an intranuclear network. In many instances it contains one large nucleolus, seldom two such nucleoli. Generally each ganglion-cell possesses a larger or smaller clump of yellowish pigment granules.

Most ganglion cells are possessed of one process, unipolar cells (Kölliker, Lieberkühn, Fraentzel, Courvoisier, Schwalbe, Stieda, and others). This process is a direct prolongation of the fibrillar network of the substance of the cell, and appears therefore finely and longitudinally striated (Max Schultze, Schwalbe, Key and Retzius). This process is directly continuous with the axis cylinder of a nerve fibre, and may therefore be called the axis-cylinder process. The smaller examples of the ganglion cells appear to be without any such process, that is, they are apolar (Kölliker, Key and Retzius); such ganglion cells are probably young or embryonal forms.

Each ganglion cell is enclosed in a special capsule. This is a homogeneous thin hyaline membrane, identical with the hyaline sheath of Schwann of nerve fibres. Inside this hyaline capsule lies a layer of small, more or less polyhedral or flattened protoplasmic cells, each with a round or slightly oval nucleus; they represent in some instances an almost complete epitheloid lining.

The capsule and its lining cells have been known through the observations of many authors (Henle, Robin, Axmann, Leydig, Kölliker, Courvoisier, Stieda, and others). The number of these lining corpuscles varies in different ganglia and in different ganglion cells of the same ganglion; they are generally most numerous near the axis-cylinder process (Arndt).

The ganglion cell in the fresh and unaltered state generally completely fills the space of its capsule, so that its surface is almost in immediate contact with the above cell-lining of the capsule (Key and Retzius, MacCarthy). After shrinking, the ganglion cell withdraws from the capsule to a greater or lesser extent; hereby the ganglion cell draws away part of the substance of the capsular cells, and appears then as if possessed of many processes (Key and Retzius). Max Schultze, Arndt, and others have misinterpreted these processes for nerve processes.

The axis-cylinder process of the ganglion cells of the cerebro-spinal ganglia of man and mammals, occasionally still within the capsule, but generally after having left the cell, becomes twisted and convoluted, sometimes in a very complex manner (glomerulus of Key and Retzius), but sooner or later it is ensheathed in a medullary sheath of the same structure as in ordinary nerves. Outside this is a hyaline sheath of Schwann, being the direct continuation of the hyaline capsule of the ganglion cell. The medullated nerve fibre is now complete even to the nodes of Ranvier, and the nerve corpuscles, viz. the isolated nucleated cells placed at intervals on the inner side of the sheath of Schwann.

The nerve corpuscles are the direct continuations of the cells lining the capsule of the ganglion cells.

In the ganglion cells of rabbit Ranvier has pointed out an interesting relation to exist, viz. that at a certain distance from the ganglion cell, the axis-cylinder process becomes thicker and converted into a medullated nerve fibre, and that this latter shows a T-shaped division, taking place generally at the first node of Ranvier. Key and Retzius confirmed this, but met it only in a limited number of nerve fibres, and are therefore disinclined to ascribe to it a character of general importance.

In a few cases the axis-cylinder process does not obtain a medullary sheath, but only the hyaline sheath of Schwann, and is therefore converted into a non-medullated nerve fibre.

The ganglion cells of the cerebro-spinal ganglia of amphibian animals and fishes differ in no essential point from those of mammals.

Next to the ganglia proper of fishes, there are in the nerve trunks isolated ganglion cells differing in many respects from the ordinary cerebro-spinal ganglion cells. These cells are bipolar, possessing at each pole an axis-cylinder process (Bidder, Volkmann, Max Schultze, and others), which is continuous with the axis cylinder of a medullated nerve fibre. On the inside of the capsule of the cell there are only a few nucleated cells.

The ganglion cells of the cerebro-spinal ganglia of petromyzon Planeri are, according to Langerhans, Stannius, Key and Retzius, bipolar; one axis-cylinder process is directed towards the periphery, and is broader than the other, which is directed towards

the brain (Stannius, Langerhans) : both become invested in a hyaline sheath of Schwann, which is a continuation of the capsule of the ganglion cell ; but they remain without a medullary sheath and represent therefore non-medullated nerve fibres. The capsule of the ganglion cell is a hyaline delicate membrane, lined with a special layer of nucleated cells, just as in the spinal ganglia of higher animals.

Key and Retzius injected from the subdural and subarachnoidal spaces of the cord the corresponding spaces of the nerve roots and of the ganglia. The lamellar septa of the ganglia, viz. those continuous with the perineurium of the nerve bundles, contain also lymph spaces which, on the one hand, are connected with the subarachnoidal spaces of the ganglion, and, on the other, pass into the very dense network of channels and spaces in the endoneural ganglionic connective tissue. The ganglion cells, just like the nerve fibres of the cerebro-spinal nerves mentioned in Chapter XII., are surrounded by these channels and spaces.

REESE LIBRARY OF THE UNIVERSITY OF CALIFORNIA.

CHAPTER XVII.

THE SYMPATHETIC SYSTEM.

A. The Sympathetic Nerve Fibres.

The sympathetic nerve trunks resemble those of the cerebro-spinal system ; they contain medullated and non-medullated nerve fibres. Unlike the cerebro-spinal system, the former are in some parts less numerous than the latter.

The medullated nerve fibres of the sympathetic vary in breadth ; they decrease in number towards the periphery. As regards structure, they in no way differ from the medullated nerve fibres of the cerebro-spinal nerves, viz. they possess : (*a*) an axis cylinder finely striated, being composed of fine fibrils, elementary nerve fibrils ; (*b*) a medullary sheath ; (*c*) a hyaline sheath of Schwann ; and on the inside of this (*d*) nucleated nerve corpuscles. They show also Ranvier's nodes. The medullated nerve fibres of medium size, and also the fine ones, show occasionally more or less regular varicosities.

The non-medullated nerve fibres, or Remak's fibres, are pale, finely fibrillar axis cylinders, many of them invested in a hyaline sheath of Schwann with nerve corpuscles (Remak, Max Schultze, Waldeyer) ; that is to say, they completely resemble the non-medullated nerve fibres of the cerebro-spinal nerves described in a former chapter. They branch very often into two or three fine fibres. There are, however, some fine axis cylinders which do not appear to possess any sheath of Schwann, but only a few nerve corpuscles. They are to be met with in numbers at the peripheral distribution of the sympathetic nerves.

The number of non-medullated nerve fibres is always considerable in the trunks and increases towards the periphery, so that the peripheral nerve branches possess many more non-medullated than medullated fibres.

The microscopic branches, bundles, of the sympathetic system are invested in a thin perineurium, which in the small examples is merely an endothelial membrane; in the larger ones it contains also a small amount of fibrous-connective tissue.

B. The Sympathetic Ganglia.

The large sympathetic ganglia are, as regards the arrangement of their connective-tissue sheaths and lymph-paths, identical with the cerebro-spinal ganglia described in the previous chapter (Key and Retzius). The sympathetic system contains, however, very numerous microscopic ganglia in connection with minute nerve branches, such as occur in the different parts of the alimentary canal, the uro-genital organs, carotic plexus, cardiac nerves, &c. These microscopic ganglia represent spherical or elliptical or irregularly shaped accumulations of ganglion cells at the point of anastomosis of two, three, or more minute nerve branches; occasionally they form a lateral budlike or spindle-shaped swelling in the course of one nerve branch. They vary very greatly in size, from one or two ganglion cells placed between the fibres of a minute nerve branch, to longer or shorter chains or clumps of ganglion cells.

The nerve branches that are connected with these microscopic ganglia possess a delicate sheath, a simple layer of endothelium, and contain in the majority of instances only non-medullated nerve fibres of various thicknesses. Where the ganglion represents a clump of cells placed at the point of anastomosis of nerve branches, we notice that the endothelial sheath of the latter is continued also over the ganglion.

The ganglion cells of the sympathetic system are of very various sizes and shapes. As a rule, they are smaller than the cells of the cerebro-spinal ganglia; they are elliptical, spherical, club-shaped or pear-shaped. They possess a hyaline capsule lined by flattened nucleated cells (Henle, Hannover, Kollmann, Arnstein, Fraentzel, Max Schultze, Stieda, and others). If the cell-substance withdraws (through shrinking or otherwise) from the capsule, it very often remains connected by fine processes with the nucleated cells lining the capsule (Key and Retzius), similar to what has been described above of the ganglion cells of the cerebro-spinal ganglia. Occasionally there are more than one cell in a common capsule (Courvoisier, S. Mayer).

The substance of the sympathetic ganglion cells is in some instances a distinct network of fibrils, in others it appears coarsely granular. It contains in some instances a clump of pigment granules. As a rule there is one excentric large, spherical or oval nucleus; occasionally (especially in the rabbit, Remak) the nucleus is double. It possesses a limiting membrane, a more or less distinct intranuclear network, and in this often a large nucleolus.

The ganglion cells are apolar, unipolar, bipolar and multipolar.

The apolar cells are generally comparatively small cells, forming groups or nests (S. Mayer, Lavdowsky); they occur especially in batrachian animals, and represent embryonal forms.

The unipolar cells are found in almost all sympathetic ganglia. They are met with especially in the microscopic ganglia of the alimentary canal and genital organs of mammals. They possess a finely striated axis-cylinder process, which, as in other instances, is a continuation of the cell substance, and carries with it a prolongation of the capsule of the cell, as sheath of Schwann, and of the nucleated cells as nerve corpuscles.

The bipolar cells are similar to the former, except that they possess two processes, one at each pole—the cell appears thus spindle-shaped—or they are both coming off from one side of the cell either close together or somewhat apart from one another.

The multipolar cells are very common in man and other mammals (Kollmann, Arnstein, Schwalbe, and others), especially in the larger sympathetic ganglia. Their processes vary from 3 to 5 or more, they are of very various thickness; some are branched, others unbranched.

In all instances, no matter whether uni- bi- or multipolar, each process is a continuation of the cell-substance, and obtains a prolongation from the hyaline capsule of the cell as the hyaline sheath of Schwann, and of the lining capsular cells, as the nerve corpuscles, that is to say it becomes converted into a non-medullated nerve fibre.

In frog the ganglion cells, especially the bipolar ones, are of a peculiar nature, inasmuch as one of their processes appears as a 'spiral fibre' twisted round the other process, 'the straight fibre.' These cells have been discovered by Beale, and are known as Beale's ganglion cells with spiral fibre. The spiral fibre is generally thinner than the straight fibre, and where it leaves the cell-substance there exists always an accumulation of small nuclei. The spiral fibre is in some instances branched, and the branches anastomose into a network (Arnold, Kölliker, Courvoisier). The spiral fibre, at first thin, becomes soon thicker and transformed into a medullated nerve fibre, whereas the straight one remains non-medullated (Hoffmann, especially Key and Retzius).

The spiral fibre is at first enclosed in a common sheath with the straight one, but sooner or later leaves this latter in its own sheath of Schwann.

Similar cells, viz. with 'spiral fibre,' but less distinct than in the frog, are met with in mammals (Courvoisier, Bidder, Klein).

The special character and distribution of the sympathetic ganglia of the alimentary canal, and uro-genital organs, will be mentioned in connection with the description of these organs in future chapters.

REESE LIBRARY
OF THE
UNIVERSITY
OF
CALIFORNIA

I.

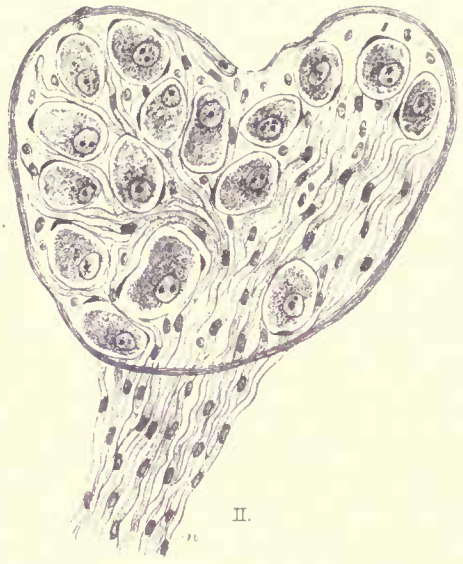

II.

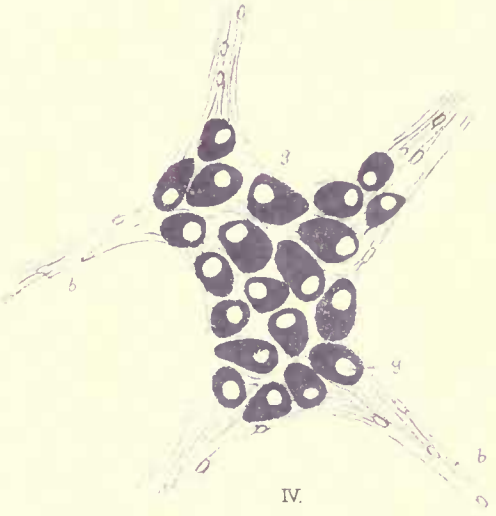

IV.

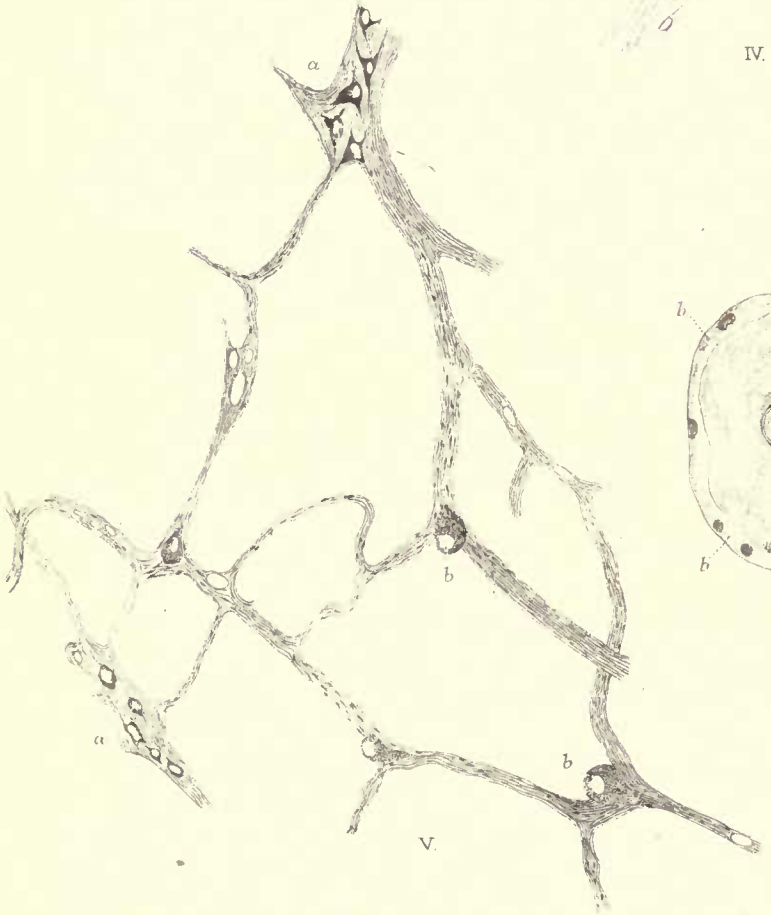

V.

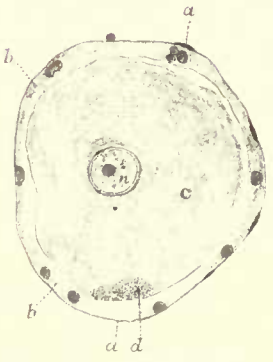

VI.

VII.

PLATE XXII.

Figs. I. and III. are copied from Key and Retzius.

Fig. I. An isolated ganglion cell of a spinal ganglion of toad. Magnifying power about 570.

The large cell with its nucleus and nucleolus, the capsule, the axis-cylinder process becoming invested in a medullary sheath, and the continuation of the sheath of Schwann with the cell capsule, are well shown.

Fig. II. From a section through a microscopic ganglion of the submaxillary gland of dog. Magnifying power about 300.

c. Capsule of the ganglion.

n. Nerve fibres passing out of the ganglion; the nerve fibres entering the ganglion are not contained in the section, they are connected with the upper right portion. The nerve fibres are ordinary medullated fibres, the details of their structure are not represented, owing to the low magnifying power. The ganglion cells are invested in a special capsule, lined by a few nuclei, here represented as if contained *in* the capsule.

Fig. III. A large and small ganglion cell of the ganglion Gasseri of rabbit. The axis cylinder immediately after leaving the cell is much convoluted, it becomes transformed into a medullated nerve fibre, which at a certain distance shows a T-shaped division of Ranvier.

The structure of the nerve fibre is the same as represented in fig. IX. of Plate XVIII. Magnifying power 850.

Fig. IV. A microscopic ganglion of the sympathetic of the bladder of rabbit. Magnifying power about 250.

b. Nerve branches, composed of non-medullated fibres, not shown in detail.

g. Ganglion cells; the ganglion is a group of ganglion cells situated at the point of anastomosis of several nerve branches.

Fig. V. From the plexus of Meissner of the small intestine, prepared with chloride of gold, of toad; it represents a plexus of broader and narrower axis cylinders composed of elementary nerve fibrils. These fibrils are beaded, and they appear such in all preparations prepared with chloride of gold. There are several small and large single ganglion cells (*b*) apparently unipolar, each with a clear nucleus, and connected with the branches of the plexus. In the enlarged parts (*a*) of the plexus are groups of multipolar ganglion cells of various sizes, each with a clear nucleus. Magnifying power about 150.

Fig. VI. Copied from MacCarthy; a ganglion cell of a spinal ganglion, to show

a. the capsule;

b. the nucleated cells lining the capsule, their outline is not well marked;

c. the substance of the ganglion cell;

n. nucleus;

d. clump of pigment granules.

The process of the ganglion cell is not represented.

Fig. VII. Copied from Klein, Plate XXXVII., 'Handbook for the Physiol. Laboratory.' Magnifying power about 350.

From a section through the tongue, stained with chloride of gold, of frog.

A. minute artery;

a. capillaries;

b. plasma cells of the intermuscular tissue;

c. non-medullated nerve fibres;

d. fine non-medullated nerve fibres forming a plexus, they possess nuclei indicative of nerve corpuscles.

PLATE XXIII.

Figs. VIII. and X. copied from Key and Retzius.

Fig. VIII. An isolated sympathetic ganglion cell of man; it shows: the capsule lined with nucleated cells; the nucleus of the ganglion cell with a large nucleolus; three unbranched and one branched process. The cell capsule is continued over all processes as the sheath of Schwann. Magnifying power 750.

Fig. IX. A small group of ganglion cells connected with a sympathetic nerve branch of bladder of dog (chloride of gold).

The ganglion cells possess each a capsule, the nuclei lining this are represented as if *in* it. In three cells the process is shown that is continuous with the axis cylinder of a non-medullated nerve fibre. On the right is a large ganglion cell as if dividing.

The detail of structure of the nerve fibres is not shown; the sheath of the nerve branch is continuous over the ganglion. Magnifying power about 350.

Fig. X. Isolated sympathetic ganglion cell of frog, showing the 'spiral fibre' of Beale. This spiral fibre is continuous with the axis cylinder of a medullated nerve fibre, while the 'straight process' remains without a medullary sheath. Magnifying power 1,100.

Figs. XI. and XII. copied from Klein, Plate XXVI., 'Handbook for the Physiol. Laboratory.'

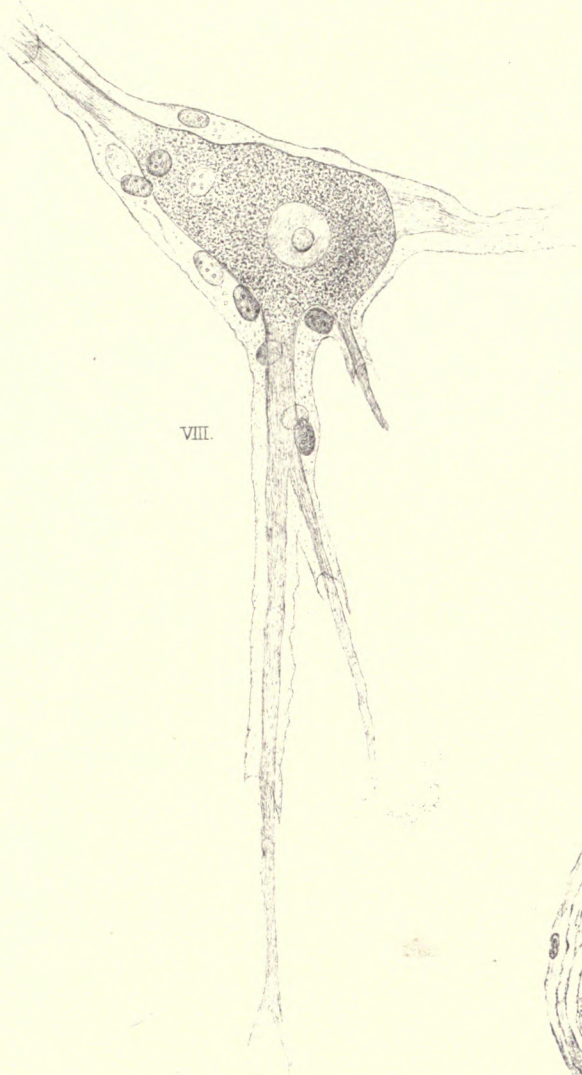

VIII.

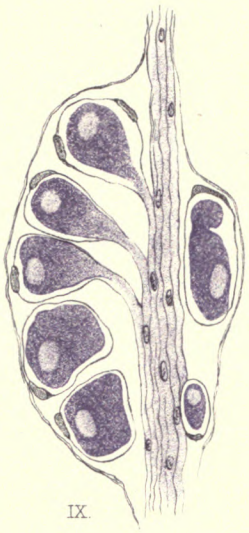

IX.

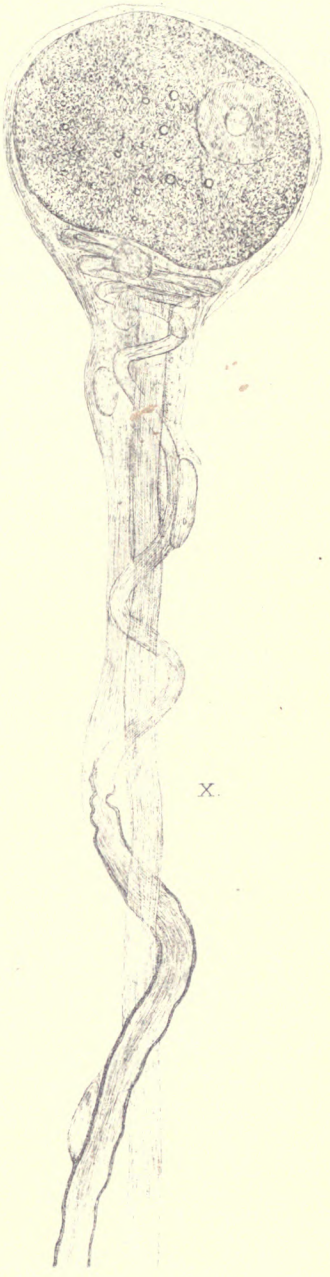

X.

XI.

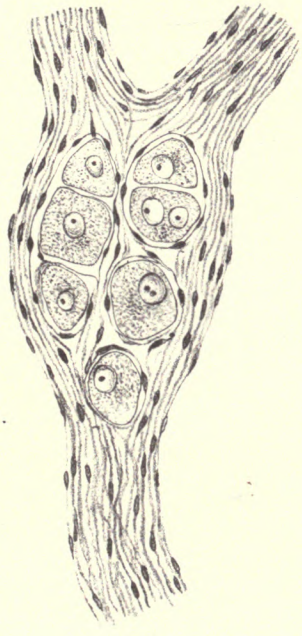

XII.

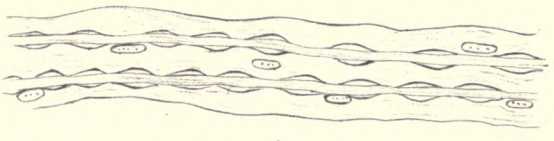

XIII.

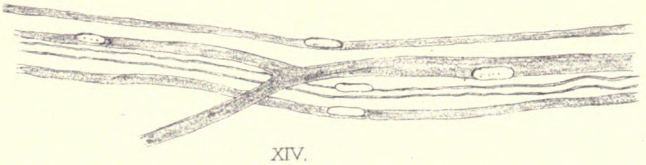

XIV.

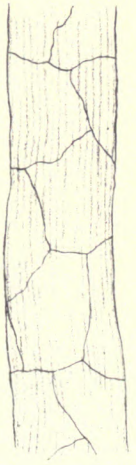

XV.

Fig. XI. Three ganglion cells with 'spiral fibre' in a sympathetic nerve branch of the muscular coat of the bladder of rabbit. Magnifying power about 500.

Only the axis cylinders coming off from the ganglion cells are drawn here; the other nerve fibres are left in outline, except the sheath with its nuclei.

Fig. XII. From a similar preparation as the preceding figure, showing seven ganglion cells embedded amongst the non-medullated nerve fibres. The upper part of the nerve branch divides into two. Magnifying power about 300.

Fig. XIII. Two sympathetic nerve fibres (man) embedded in a thick fibrous sheath of Henle.

Each nerve fibre possesses a medullary sheath only from place to place; this gives it the appearance of a varicose fibre. Magnifying power about 350.

Fig. XIV. Several nerve fibres of a sympathetic branch of rabbit.

Three are non-medullated and of various sizes; the broad fibre divides into two.

One is a fine medullated fibre.

The nuclei are indicative of the nerve corpuscles lining the sheath of Schwann. Magnifying power about 350.

Fig. XV. A sympathetic nerve branch of mesentery of cat, after nitrate of silver. Its sheath is an endothelial membrane; only the outlines of the endothelial cells are here represented. Magnifying power about 150.

CHAPTER XVIII.

PERIPHERAL DISTRIBUTION OF NERVES.

As has been mentioned on a former occasion, the nerve bundles, ensheathed in their perineurium, represent the microscopic nerve branches. By repeated division the number of nerve fibres composing a branch becomes gradually reduced. All the fine branches of a nerve bundle down to those that contain only one or two nerve fibres possess a sheath which is a continuation of the perineurium. This sheath varies in its thickness in different localities, in some places it is merely an endothelial membrane, in others it is of considerable thickness and consists then of fibrous-connective tissue and endotheloid cells. This sheath is called Henle's sheath, or also perineurial sheath (Key and Retzius).

The nerve fibres composing a fine sensory branch remain medullated until they arrive near their peripheral termination, where they lose their medullary sheath. This, however, does not take place in all nerve fibres at the same time, for we find repeatedly minute branches in which some of the nerve fibres become non-medullated much sooner than others.

In the skin and mucous membranes the minute nerve branches containing one, two or more nerve fibres when approaching the surface epithelium are connected into a plexus, which is called the *subepithelial plexus.* The branches of this plexus contain generally only non-medullated nerve fibres and vary very much in thickness. They represent broader or narrower bands composed of minute fibrils, elementary nerve fibrils, since even in the thicker examples the distinction into separate axis cylinders has been lost. Each branch possesses a sheath with nuclei from place to place. The former is a continuation of the perineurium, the latter either belong to the perineurial sheath, or are indicative of nerve corpuscles, the sheath of Schwann of the individual nerve fibres having ceased previously.

The points where several branches of the subepithelial plexus anastomose contain occasionally (cornea, skin) angular thickenings ; here the (elementary) fibrils cross each other and rearrange themselves; nuclei are generally more numerously met with in these thickenings than in other parts.

1) In the cornea.

The nerve trunks entering the cornea give off branches for two different systems

(Engelmann): a deep one and a superficial one; the former belongs to the substance proper of the cornea, the latter to the anterior epithelium. The larger branches of both are invested in an endothelial sheath (Durante, Thanhoffer, Thin), and near their peripheral distribution are composed merely of elementary nerve fibrils.

The minute branches of the deep system dissolve themselves into small bundles of elementary nerve fibrils, and ultimately into the individual fibrils; these are very characteristic by their exceedingly long and straight course, by their more or less rectangular bends, and by their anastomosing amongst themselves into a terminal network, the 'deep network.' This network lies close to the Descemetic membrane, but there are minute fibrils which pass through this latter in an oblique manner, and appear to be connected into a further network close to, or in the Descemetic endothelium (Klein). That there are fine fibrils of the deep network that terminate by being connected with the corneal corpuscles (body or processes) has been affirmed, denied, re-affirmed, and re-denied. Kühne, Lipmann, Moseley, Lavdowsky, Thanhoffer, Königstein, Izquierdo and others assume such a connection; Engelmann, Dwight, Tolotschinow, Rollett, Klein, Waldeyer and others deny it.

The branches of the superficial system form first a subepithelial plexus (Arnold, Saemisch); the nature of the parts of this plexus has been mentioned above; it may be added that within the thicker branches the elementary fibrils are much twisted and cross each other in many ways, and appear even to be connected into a network. This subepithelial plexus lies a short distance away from the epithelium. Fine branches come off from it, they pass in an oblique or vertical direction, as rami perforantes, towards the lower surface of the epithelium (Cohnheim, Kölliker), where they split up into isolated or minute groups of elementary nerve fibrils. In the periphery of the cornea these fibrils come off from the perforating branches in small brushlike bundles (Cohnheim, Klein). In preparations prepared with chloride of gold the elementary fibrils are possessed of minute varicosities, and for this reason a perforating branch with the brushlike bundle of beaded elementary fibrils bears a great resemblance to a 'cat-o'-nine-tails.'

The elementary fibrils run for a shorter or longer distance close underneath the epithelium, they are straight or slightly wavy and anastomose with one another into a network, subepithelial network (Klein, Izquierdo). After a longer or shorter course they rise perpendicularly or in a slightly oblique direction into the epithelium (Hoyer, Cohnheim, Kölliker), where they ascend towards the surface, winding their way between the epithelial cells. They give off horizontal fibrils (Kölliker, Klein). The latter anastomose into a network (deep intraepithelial network, Klein); the former also join into a

network (superficial intraepithelial network, Klein), the fibrils of which are separated from the free surface only by the superficial layer of epithelial cells.

The nerve fibrils, instead of being connected into a terminal network, are said to end in free knoblike extremities on the surface of the epithelium (Cohnheim, Lavdowsky, Krause), or in some other special way (Thanhoffer, Inzani); according to Hoyer and Izquierdo the terminal fibrils branch near, but not at the free surface of the epithelium, and end here freely.

In all instances the intraepithelial nerve fibrils run in the interstitial substance between the epithelial cells, and do not enter into any relation with the epithelial cells themselves or their nuclei.

2) In the skin.

Besides the special terminal organs to be described below, viz. the Pacinian corpuscles, genital corpuscles, Merkel's cells, tactile corpuscles of Meissner, &c., there is the general termination of the sensory nerves, which is placed in the epidermis itself.

From the subepithelial plexus, mentioned above, fine fibrils, isolated or small groups of elementary fibrils, come off, which lie close to the under-surface of the rete Malpighii, and after having formed a network with large meshes, the subepithelial network, enter the rete Malpighii (Langerhans), where they ascend towards the stratum corneum; on their way, viz. in the rete Malpighii, they give off short branches, which anastomose into a network (Podkopaew, Jantschitz). This is probably a terminal network.

As in the cornea, so also in the skin the intraepithelial nerve fibrils lie in the interstitial substance between the epithelial cells.

In the nose of the mole there are bundles of elementary fibrils ascending, in special places, into the rete Malpighii (Eimer), they run towards the surface, and each fibril terminates here, according to Mojsisovics, in a small knoblike swelling.

A similar termination has been observed by Mojsisovics in the nose of pig.

In the skin of frog Ditlevsen described special cells as the end organs of the intra-epithelial nerve fibrils.

In the skin of tadpole the non-medullated nerve fibres dissolve themselves into a very dense network of minute fibrils (Klein, Lavdowsky, Leboucq); this network lies close underneath the epithelium of the surface, its meshes are much smaller than the individual epithelial cells. Included in the network are minute flat branched nucleated cells (Klein, Lavdowsky, Leboucq).

The relation of fine nerves to the hairs in general, and especially to the tactile hairs, will be considered in the chapter on the skin.

Similar to the above is the termination of nerve fibrils in the mucous membranes

covered with stratified pavement epithelium. Here also fine (elementary) nerve fibrils enter the epithelium (Chrschtschonovitsch, Elin, Krohn), and ascend towards the superficial layers, giving off one or the other horizontal branch. It is not quite ascertained whether they terminate freely in knoblike swellings or whether they are connected into a terminal network.

Special Terminal Organs.

A. Pacinian corpuscles.

These corpuscles, more appropriately called Vater's corpuscles, are oblong more or less elliptical or pointed corpuscles, varying considerably in size. They have a wide distribution in man and other vertebrates; they are most numerously found in the subcutaneous tissue of the volar side of the hand and foot of man, near the tibia of rabbit, in the mesentery of cat, in the beak and near the tibia of birds.

Each Pacinian corpuscle is connected with a medullated nerve fibre which, with its thick sheath, represents the stalk of the corpuscle.

1. The corpuscle proper consists of a great number of capsules placed in a concentric manner around a central elongated clear mass; it shows, therefore, a concentric striation, each stria corresponding to a capsule seen in profile.

The capsules are thin at the periphery and near the central clear mass; the corpuscle appears, therefore, when seen under a low power, to be more densely striated in the parts just mentioned.

Each capsule is made up of the following parts: (*a*) a hyaline ground membrane, probably elastic; (*b*) in this ground membrane are embedded fine connective-tissue fibres. These are arranged, either regularly in one or two layers, or irregularly, but always in a transverse manner. (*c*) On the inner surface of the ground membrane is an endothelial membrane, composed of a single layer of flattened nucleated endothelial cells.

The above ground membrane corresponds to the intercapsular 'albuminous fluid mentioned by most observers; the capsules are not, at any rate not in the fresh state, separated by any fluid, but are in immediate contact with one another (Huxley).

The endothelial membrane lining the capsules shows, with nitrate of silver, the usual network of dark lines (Hoyer) indicative of the outlines of the individual endothelial cells. That the capsules contain, besides these endothelial cells, also fibrous-connective tissue has been known through Henle and Kölliker, Keferstein, Krause, Ciaccio, Key and Retzius, and others, but it is chiefly Key and Retzius who have most elaborately investigated the structure of the capsules, and various very minute differences existing in different Pacinian corpuscles.

Neighbouring capsules are often branched and connected with one another by thin fibres (Huxley, Henle and Kölliker, Keferstein, Hoyer, Ciaccio, and others).

2. The stalk of the corpuscle consists of a medullated nerve fibre of the ordinary description, with the addition of a variable amount of fibrous-connective tissue (Axel Key and Retzius); outside this is a thin limiting membrane, and further a number of lamellæ with endothelium between them. These lamellæ pass directly into the peripheral capsules of the Pacinian corpuscle (Krause, Schäfer).

3. In order to reach the central clear mass the nerve fibre has to perforate the capsules. This section of the nerve may be called the 'intermediary part,' viz. lying between the stalk and the central clear mass.

This intermediary part consists of a prolongation of the medullated nerve fibre, more or less wavy, around it a very narrow zone of a transparent substance. Its boundary is formed by the limiting membrane just mentioned; to this latter are fixed the capsules that are perforated by the intermediary part of the nerve (Ciaccio, Schäfer).

4. The central clear mass is a relatively thin cord, consisting of: (*a*) The cylindrical terminal fibre, being the axis cylinder of the nerve fibre. The medullary sheath and sheath of Schwann cease at the entrance into the central clear mass. This axis cylinder is just like other axis cylinders, finely striated in a longitudinal manner, being composed of minute primitive nerve fibrils. Generally near the distal end of the central clear mass, occasionally much sooner, the axis cylinder divides into two or more small branches of different thicknesses. As a rule, in man and mammals, these branches end in a pear-shaped, fungoid, spherical or irregular mass, terminal bud (Key and Retzius), containing the terminations of the primitive nerve fibrils of the axis cylinder (Grandry). Occasionally the terminal fibre ends in a pointed or fringed manner (Izquierdo). The terminal buds show, especially in man and cat, a more or less distinct subdivision into small bodies, but without nuclei. The substance of these buds is a dense network of minute fibrils, and may therefore be regarded as a terminal network, not to be confused with a network of coarse nerve fibres said to exist in the corpuscle proper (Paladino, Beale).

(*b*) Besides the terminal fibre and terminal buds, the central clear mass contains a transparent hyaline or slightly (longitudinally) striated matrix, and (*c*) the limiting membrane, both continued from the stalk. Rows of nucleus-like bodies may be seen occasionally in the peripheral part of the central clear mass. The transparent matrix and limiting membrane extend, in some rare instances, in the shape of a longer or shorter pointed process (Key and Retzius), beyond the terminal buds.

The Pacinian corpuscles contain between the capsules capillary blood-vessels, and occasionally a few plasma cells.

In some instances (mesentery of cat) a minute artery is seen to enter the Pacinian corpuscle opposite the nerve stalk, and having penetrated to near the distal extremity

of the central clear mass, branches into two or three capillary vessels. The capsules of the Pacinian corpuscle, including the endothelial membranes, are continued on the arterial adventitia, and the Pacinian corpuscle appears in this case to possess two stalks, one nervous and one vascular.

The intercapsular ligament, occasionally present, is merely a blood-vessel (Key and Retzius).

B. The end bulbs of the conjunctiva.

These were discovered by Krause, and are known as Krause's end-bulbs. They are found in the deeper layer of the conjunctiva of the eyeball, especially near the corneal margin.

1. In the calf they are oblong, elliptical, or cylindrical, or spindle-shaped straight or curved corpuscles, in which a medullated nerve fibre, after a longer or shorter course, terminates. This is an ordinary medullated nerve fibre, possessed of a sheath of Schwann, nerve corpuscles, and Ranvier's nodes ; it contains in addition a thicker or thinner laminated outer or Henle's sheath, with flattened nucleated cells. This latter passes on as the capsule of the end-bulb. Inside the capsule lies a transparent, or slightly longitudinally striated cylindrical or spindle-shaped mass, representing the bulk of the end-bulb (Longworth, Key and Retzius). In the centre of this lies the terminal fibre, which is a prolongation of the axis cylinder of the nerve fibre. It terminates generally in a pointed or rounded extremity, occasionally in a budlike enlargement similar to that in the Pacinian corpuscles (Key and Retzius).

2. In man they are spherical or elliptical, and, like those in the calf, possess a special capsule ; this shows the same structure as that in the bulbs of the calf, being also a continuation of the sheath surrounding the medullated nerve fibre. According to Key and Retzius, this latter on entering the bulb loses in some instances its medullary sheath, and the axis cylinder having divided into two or more branches ends in the matrix of the bulb. In many other cases the nerve fibre retains its medullary sheath, and becomes greatly convoluted, but ultimately loses the medullary sheath, and its axis cylinder having divided into thin branchlets terminates in the matrix of the bulb.

The matrix is a granular mass containing larger and smaller spherical or oval nuclei, but there are no definite cell boundaries to be perceived between the nuclei (Key and Retzius). This granular mass is in reality a dense network of fine fibrils, in which the primitive fibrils of the axis cylinder and its branches terminate.

C. The end-bulbs of the genital organs.

Fick, Kölliker, Bense, and others, and especially Krause, demonstrated peculiar end-bulbs in the penis and clitoris ; each end-bulb is connected with a medullated nerve fibre.

These end-bulbs represent simple or compound elliptical or cylindrical corpuscles, situated in the corium and mucosa, and possessed of a capsule of nucleated membranes. This capsule is either simple or composed of several membranes, but it is always a continuation of the tissue in which the nerve fibre is embedded. Generally one. occasionally two, medullated nerve fibres enter the corpuscle, and at the point of entrance lose their medullary sheath. According to Key and Retzius the axis cylinder becomes convoluted in a more or less complicated manner, and finally terminates in several small branches, each possessed of a spherical or oval granular end-swelling. The convolutions of the branches of the axis cylinder represent the bulk of the end-bulb. There are always a few nuclei present amongst these convolutions.

According to Izquierdo the genital corpuscles of the clitoris of rabbit are numerous, broad and simple, while those of the vaginal mucous membrane of the same animal are few, narrow and divided. The bulk of the corpuscle is not made up of convolutions of the axis cylinder, but either of granular nucleated cells or a fibrous matrix. The latter is derived from the former, and accordingly we find corpuscles the matrix of which is in different intermediary stages. The nerve fibre does not end in a swelling, but having become thinner, terminates in a pointed manner.

D. The end organs of the beak and tongue of birds.

These are either of large size, situated in the depth, and formed on the plan of Pacinian corpuscles, slightly modified; they are then called Herbst's corpuscles; or they are small spherical or oval budlike swellings, situated more superficially in the immediate neighbourhood of the epithelium; they have been first seen by Grandry, but fully investigated by Merkel, and are therefore appropriately called Merkel's end-bulbs. They appear as lateral enlargements at the end of a medullated nerve fibre. The enlargement is possessed of a nucleated and laminated capsule. The contents of the capsule, i.e. the matrix of the end-bulb, consist of a variable number (2–5) of transparent large cells, slightly flattened, each with a nucleus, and arranged in a vertical row.

The medullated nerve fibre loses its medullary sheath when entering the end-bulb. Those who have specially investigated the mode of the termination of the axis cylinder differ on this point: while some (Merkel, Henle) regard the above transparent cells—Merkel's 'tuch-cells'—as the true terminal organs of the axis cylinder, others (Key and Retzius, Ranvier, Hesse, Izquierdo) consider the disc, or discs, situated between the broad surfaces of two adjacent cells (disc tactil, Ranvier; Tastplatte, Hesse) as the real termination.

E. According to Merkel, there exist similar end organs, viz. 'tuch-cells,' also in the skin of man and other mammals (nose of pig, especially the small tuch hairs of the nose

of pig, Dietl). They are situated either in the tissue of the papillæ, or extend amongst the epithelium. They occur as simple or compound end organs; the former are single, large and slightly flattened transparent nucleated cells (similar to those described of the beak and tongue of birds) enclosed in a capsule, and similar to ganglion cells forming a direct continuity with a medullated nerve fibre; the latter contain within a capsule several small cells. The 'tactile' or Meissner's corpuscles, hitherto known especially in the papillæ of the skin of the fingers of man, are such multicellular end organs.

F. Termination of nerves in unstriped and striped muscle fibres.

The tissue of muscle is richly supplied with nerves. Their distribution varies considerably in striped and unstriped muscle.

1. In unstriped muscle.

The nerve branches are composed of non-medullated nerve fibres, each of them (nerve branch) possesses an endothelial sheath; they divide into individual or small groups of axis cylinders, which show very well their composition of primitive nerve fibrils. They form a plexus consisting in the exchange and rearrangement of the primitive fibrils. This plexus represents the ground plexus of Arnold. Its branches are possessed of nuclei belonging either to nerve corpuscles or to flattened nucleated cells continuous with the above endothelial sheath.

The branches of the ground plexus divide into fibres of various thicknesses, still possessed of nuclei, indicative of nerve corpuscles; these fibres form another plexus, the intermediary plexus of Arnold. This belongs to the individual bundles of the unstriped muscle fibres, whereas the ground plexus appertains to a group of muscle bundles.

The fibres of the intermediary plexus, however thin, are always compound, being a smaller or larger bundle of primitive fibrils. They give off the latter, viz. the primitive fibrils, which pass into the interstitial substance that separates the individual muscle cells; here they run for a longer or shorter distance, and anastomose with their neighbours by transverse or oblique fibrils into a real network. These fibrils represent the intermuscular fibrils of Klebs. It is not definitely settled whether they themselves are the terminal fibrils (Löwit), or whether they send off still finer branchlets that penetrate into the nucleus of the muscle cells. Frankenhäuser lets them terminate in the nucleolus, undivided if one, divided in two if there are two nucleoli. According to Arnold they terminate in the nucleolus, but so that this latter is only a nodal point in the ultimate or intramuscular network. Elischer describes the nerve fibrils as terminating on the surface of the nucleus with a small swelling.

A termination of nerve fibrils in the nucleus of the muscle cells is not improbable, although it does not take place in a nucleolus.

The intermuscular fibrils are occasionally connected with a nucleated pear-shaped, spherical, or spindle-shaped swelling similar to a ganglion cell (Klebs, Gscheidlen).

2. In striped muscle.

The nerve bundles ensheathed in their perineurium are situated in the connective tissue separating groups of bundles of muscle fibres, and are composed of medullated nerve fibres of the ordinary description. These branches form a plexus, ground plexus.

Isolated and small groups of nerve fibres come off from this plexus; they are conspicuous by their dividing into two, seldom three, medullated nerve fibres, and are also connected into a plexus, intermediary plexus, destined for the bundles of muscle fibres.

Isolated medullated nerve fibres enter the individual muscle fibres in an oblique or vertical manner, the sheath of Schwann of the nerve fibre becoming fused with the sarcolemma, while the axis cylinder, having lost its medullary sheath, passes within the sarcolemma (Rouget, Kühne).

In most animals, man included, the axis cylinder then branches into several thin fibres, forming a network with one another; these fibres remain on the surface of the muscle substance proper, but lie embedded in a granular platelike mass, the nerve end-plate of Kühne, containing numerous oval nuclei. These nuclei are of three different kinds (Ranvier); some belong to the outer or Henle's sheath of the nerve fibre; others correspond to the nerve corpuscles; and finally there are nuclei that belong to the granular matrix of the end-plate. When such an end-plate is viewed in profile, especially in a more or less contracted muscle fibre, it presents itself as an elevation, Doyère's mount.

In batrachia the medullated nerve fibre, after having lost its medullary sheath, divides into several longer or shorter thin fibres (Kölliker), which terminate apparently in a pointed or rounded extremity; oblong nuclei are attached to them. These fibres are on the surface of the muscle substance, but within the sarcolemma (Kühne, Krause, Engelmann, Waldeyer, Calberla, and others). According to Kühne the muscle fibres of batrachia do not possess a granular platelike mass in which these fibres terminate, but Krause, Waldeyer, and Axel Key have shown that there is no such distinction, the batrachian muscle fibres showing also a granular platelike matrix for the intramuscular branches of the axis cylinder. Arndt has shown that in batrachia both modes of nerve terminations occur.

There are end-plates, into which enter two nerve fibres (Krause, Arndt). The end-plates differ in size; generally more than one end-plate belongs to a muscle fibre.

According to Arndt they are always numerous in the muscle fibres of vertebrates, man and mammals included.

It is not decided whether the intramuscular nerve fibres terminate in the end-plate (Kühne, Ranvier, and others), or whether fine fibrils pass beyond this latter (Margó, Engelmann, especially Arndt, T. Gerlach); that they do not do so is maintained by the most recent investigators (Fischer, Ewald, Biedermann).

According to Arndt the end-plate and end-divisions of the motor fibres are alone intramuscular; with them are connected nerve fibres which join into a plexus, which is extramuscular, i.e. situated outside the sarcolemma of the muscle fibre, such as had been seen by Kölliker, Beale, Krause, and others. Arndt regards them as sensory nerve fibres.

According to L. Gerlach, the bundles of the muscle fibres of the heart (of frog) possess a network of fine non-medullated nerve fibres, perimuscular network. Fine fibrils come off from this and form a network between and around the individual muscle fibres, intramuscular network; but only seldom do these nerve fibrils join the substance of the muscle fibres. According to Fischer, however, the nerve fibrils terminate only in the above network, viz. between the muscle fibres, without ever joining the substance of these latter.

G. Nerve termination in tendons.

Tendons possess numerous medullated nerve fibres, which, in some instances, are distinguished by their repeated division and formation of a plexus (Sachs, Rollett, Gempt). They run generally a long and straight course in conformity with the arrangement of the tendon bundles (Golgi). The termination of the nerves is effected in special organs (Sachs, Rollett, Golgi), which are more numerous near the muscle than in other parts (Golgi). It takes place in two different ways: (*a*) the nerve fibre loses its medullary sheath, and its axis cylinder branches into several fine branches, these dissolve themselves into very short elementary fibrils, which form a dense network (Sachs); (*b*) the ultimate fine nerve fibrils are occasionally embedded in a hyaline or granular nucleated ground-substance (Rollett), and thus an end organ is produced in some respects similar to an end-plate in muscle fibres.

In some tendons there are, in addition, nerve fibres that terminate in the shape of peculiar end-bulbs (Sachs), similar in structure to the end-bulbs of the conjunctiva (Golgi).

In the tendon sheaths Rauber describes as 'synovial bulbs' peculiar end-bulbs of medullated nerve fibres, similar in structure to the Pacinian corpuscles, but much smaller.

In the aponeurosis of the cutaneo-pectoral muscle of frog Tschiriew found the nerve

fibres forming a network with large meshes; from this fine fibrils come off and terminate in small knoblike swellings.

H. Termination of nerves in blood-vessels.

The nerve fibres of the microscopic arteries and veins are derived from minute bundles belonging to the adventitia; they are non-medullated fibres possessed of a sheath of Schwann and the corresponding nerve corpuscles; they divide into smaller fibres which form a plexus, ground plexus.

The nodes of this plexus are, in many places, triangular, and contain one or more angular nuclei. From the ground plexus are derived fine fibres, which belong to the muscle coat of the vessel (Klein, Gonjaew, Gscheidlen); they form a plexus, intermediary plexus, which is denser in arteries than in veins (Klein, Gscheidlen). The fine fibrils coming off from this last plexus are elementary fibrils, and run between the individual muscle cells.

In capillary arteries and capillary veins there are a few fine nerve fibres, with nuclei from place to place (indicative of nerve corpuscles), which accompany the vessel (Beale, Klein, Tomsa), and in some places form a more or less dense network of primitive fibrils (Klein, Gonjaew, Jantschitz).

In some localities the nerve branches belonging to a vessel are provided with small ganglia (F. Darwin for the urinary bladder, Jantschitz for the dura mater).

PLATE XXIV.

All figures of this plate are drawn under a magnifying power of about 400.

Fig. I. From a preparation of frog's cornea stained with chloride of gold, showing the network of elementary (beaded) nerve fibrils situated near the Descemetic membrane, and coming off from a large branch possessed of a sheath (marked pink). This large branch represents a bundle of elementary fibrils; they appear to be connected into a network while still within that sheath.

Fig. II. From a preparation of rabbit's cornea stained with chloride of gold, showing portions of two large branches of the subepithelial plexus. They consist of elementary nerve fibrils. Short branches, perforating branches, are derived from them; they split up into brushlike groups of elementary beaded fibrils, connected into a network, *subepithelial network.*

Fig. III. From a similar preparation as the preceding figure, representing a portion of the *subepithelial plexus.* At the point of anastomosis of the branches of this plexus are triangular thickenings, and it is just here where the constituent elementary fibrils are

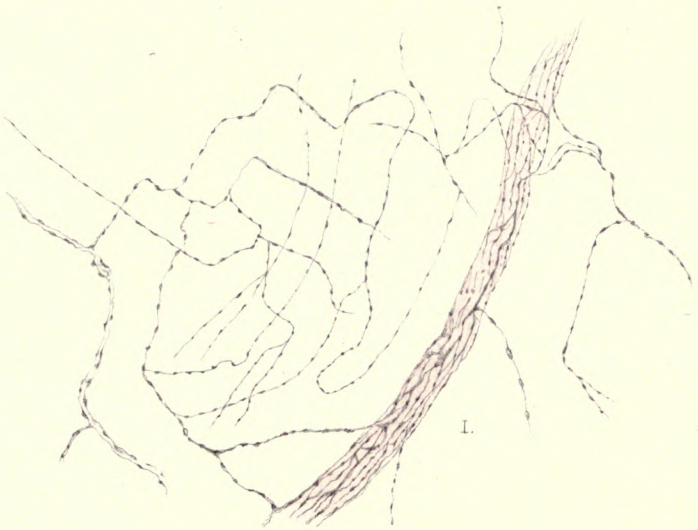

I.

II.

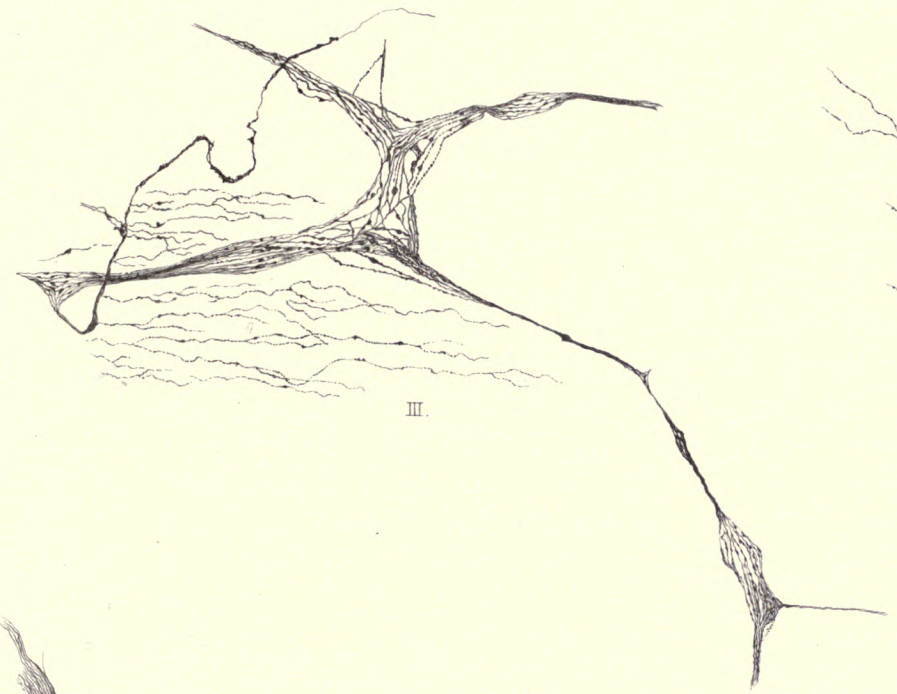

III.

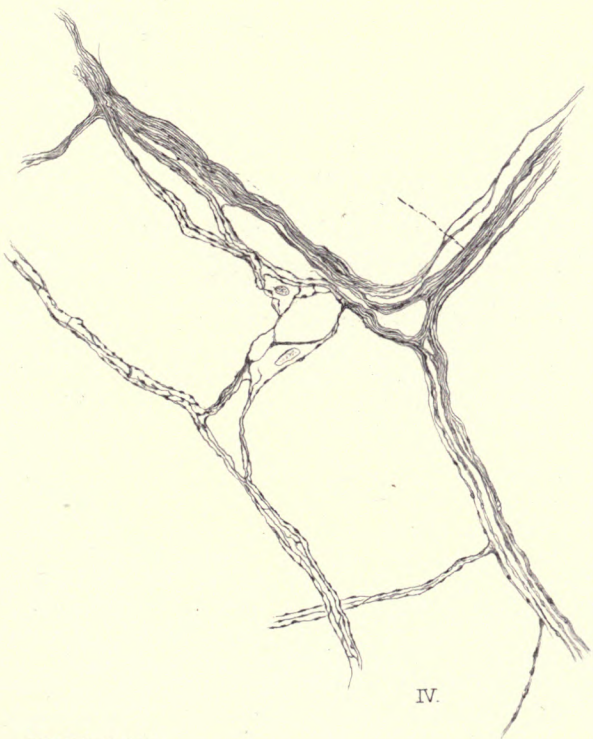

IV.

V.

E. Noble Smith fecit.

Mintern Bros imp.

REESE LIBRARY
OF THE
UNIVERSITY
OF
CALIFORNIA.

VI.

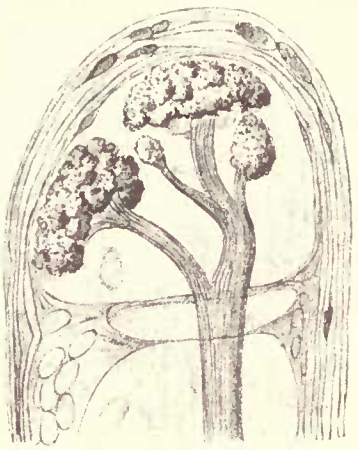

VII.

VIII.

IX.

X.

XI.

XII.

XIII

XIV.

UNIVERSITY OF CALIFORNIA

best seen. The isolated fibrils in the left portion of the figure are those that run immediately underneath the epithelium, and are connected into the *subepithelial network.*

Fig. IV. From a preparation of the submucous tissue of large intestine of toad, stained in chloride of gold; showing part of a plexus of non-medullated nerves. All branches consist of elementary fibrils. Three nuclei are shown that belong to nerve corpuscles; the sheath is not represented.

Fig. V. From a preparation of tadpole's tail, prepared with chloride of gold, showing the plexus of larger and smaller nerve fibres. The nuclei are indicative of nerve corpuscles; the sheath is marked by a slight pink tint.

PLATE XXV.

Figures VI. VII. IX.—XI. are copied from Key and Retzius.

Fig. VI. Two capsules of a Pacinian corpuscle of man; an endothelial membrane, lining a third capsule, is represented on the right as if viewed from the surface. Magnifying power 450.

Fig. VII. Termination of the axis cylinder in the central clear mass of a Pacinian corpuscle of the mesentery of cat.

The axis cylinder divides into 4 to 5 branches, each of which terminates in a globular end-bud.

The capsules next the central clear mass are represented in outline only. Magnifying power 750.

Fig. VIII. A Pacinian corpuscle of the mesentery of cat, as seen under a magnifying power of about 100.

The stalk consists of the nerve fibre with its thick outer sheath. The peripheral capsules of the Pacinian corpuscle are continuous with the outer sheath of the stalk. The intermediary part becomes much narrower near the entrance of the axis cylinder into the central clear mass. A hook-shaped termination with the end-bulb is seen in the upper part. A blood-vessel enters the Pacinian corpuscle, and approaches the end-bulb; it possesses a sheath which is a continuation of the peripheral capsules of the Pacinian corpuscle.

Fig. IX. An end-bulb of the conjunctiva of man.

The medullated nerve fibre shows a node of Ranvier, a sheath of Schwann, and a nerve corpuscle; outside these is another sheath, the sheath of Henle. The end-bulb itself possesses a capsule continuous with the sheath of Henle; the matrix of the end-bulb is a granular substance with nuclei. The nerve fibre on entering loses its

medullary sheath, while the axis cylinder divides into several branches; these are more or less convoluted and lost in the matrix. Magnifying power about 700.

Fig. X. An end-bulb of the glans clitoridis of rabbit.

The nerve fibre possesses an outer sheath of Henle, which is continuous with the capsule of the end-bulb. After having lost its medullary sheath, the axis cylinder enters the end-bulb, becomes much convoluted, and terminates in several small branchlets, possessed of knoblike swellings. Magnifying power 570.

Fig. XI. Summit of a Pacinian corpuscle of finger of man, stained with nitrate of silver, to show the endothelial membranes lining the capsules. Magnifying power about 220.

Fig. XII. Nerve termination in unstriped muscle of the muscularis mucosæ of large intestine of toad, after staining with chloride of gold.

The larger fibres belong to the *intermediary plexus*; two nuclei are shown indicative of nerve corpuscles.

The fine fibrils run between the unstriped muscle cells—only their oblong nuclei are indicated here—and terminate in a network. Magnifying power about 350.

Figures XIII. and XIV. copied from Arndt, Archiv f. mikr. Anatom. IX. Plate XX.

Fig. XIII. Two striped muscle fibres of the hyoglossus of rana temporaria. Magnifying power about 600.

a. Nerve end-plate.

b. Nerve fibres leaving the end-plate.

c. Nerve fibres terminating after dividing into several branches.

d. A nucleus in which two nerve fibres anastomose.

Fig. XIV. Nerve end-plate in a striped muscle fibre of rana temporaria. Magnifying power about 1000.

A medullated nerve fibre terminates, after dividing into several branches, in the nerve end-plate; this is a granular mass containing numerous nuclei.

CHAPTER XIX.

BLOOD-VESSELS.

1. Capillary Blood-Vessels.

The smallest and at the same time the simplest vessels are the capillaries, being minute tubes the wall of which is a thin elastic endothelial membrane, that is, a single layer of nucleated cell plates (Hoyer, Auerbach, Eberth, Aeby, and others).

Like other endothelial membranes, its individual cells are united by an albuminous interstitial cement-substance, which in silver-stained specimens appears as dark lines separating the cells. The shape of the cells is more or less elongated, with pointed extremities, and their outline smooth or sinuous. This depends, however, in a certain measure, on the state of distension or contraction of the capillary. Their substance is in the fresh state hyaline, but under certain conditions shows, just like the endothelial cells of serous membranes, a hyaline ground-plate, and in it a network of fibrils.

Each cell possesses an oval flat nucleus, situated either about the middle of the cell or near one extremity; the nucleus contains within a well-defined membrane an intranuclear network (Flemming, Klein); in adult capillaries this intranuclear network is uniform and does not contain any thickenings or nucleoli.

When capillaries are abnormally distended, as in inflammation, the interstitial cement-substance is liable to give way in many places; in consequence of this, minute openings appear (stigmata, Arnold), which become gradually enlarged into stomata. When injecting such vessels, an escape of injection matter (Winiwarter) may take place through these openings. They are likewise probably the places where, under inflammatory conditions, diapedesis of coloured (Stricker) and emigration of colourless corpuscles (Cohnheim) into the surrounding tissue occurs.

If capillary vessels, through which emigration of colourless blood-corpuscles has been going on, be stained with nitrate of silver, it is seen that the emigration is limited to the interstitial cement-substance of the endothelial wall (Purves).

Besides the endothelial wall, the (larger) capillaries in some localities possess a special outer sheath, or adventitia, which is a network of branched connective-tissue cells (hyaloidea of frog, chorioidea of mammals, Ivanoff, Eberth, and others), or a complete endothelial membrane (pia mater of brain and cord, Key and Retzius; retina,

Eberth ; serous membranes, Klein), or a network of fibres and membranes (lymphatic glands, His).

Capillaries vary in size in different localities and in different animals. Thus the capillaries of the brain and of the lung in man and mammals are smaller than those of the liver, and much more conspicuously so than those of the bone-marrow. The lumen of capillary blood-vessels varies according to whether this latter is more or less distended with fluids (blood or injection matter), or whether it is contracted or collapsed.

In young capillaries, both of normal and pathological tissues, the wall is possessed of solid threadlike shorter or longer nucleated protoplasmic processes (see below), and is capable of active contraction (Stricker). In consequence of this, the lumen may become altogether (temporarily) closed, and the vessel contracted into a thin apparently solid thread (Stricker).

The wall of all capillary vessels in the adult state forms a direct connection with the processes of the connective-tissue corpuscles of the surrounding tissue (Klein, Altmann) ; the significance of this relation will be considered in connection with the lymphatic vessels.

Capillary blood-vessels are connected into a network, the distribution and arrangement of which varies in different organs, and will be specially described with the latter.

2. Arteries.

Following a capillary vessel towards the arterial system, the following appearances, besides the increase in breadth, indicate its having changed into an arterial branch : (*a*) the presence of a permanent outer sheath, or *adventitia*, in the shape of a single layer of flattened nucleated cells, either branched and forming a network (see above), or unbranched and forming a continuous endothelial membrane. (*b*) The appearance of short unstriped muscle cells as a special layer, *media*, transversely on the long axis of the vessel ; these muscle cells occur in groups, placed on alternate sides of the vessel. The reason is probably this : the length of the uncontracted muscle cells being about equal to the circumference of the vessel, the muscle cells, when contracting, are thus able to narrow uniformly the vessel. In somewhat larger arterial branches the larger circumference requires more than this, and the muscle cells form a continuous circular layer in all parts of the vessel. (*c*) Inside the muscle layer is a delicate hyaline elastic membrane, the *intima*. (*d*) The inner boundary is formed by the *endothelium*, being a continuation of the endothelial wall of the capillary vessel.

The endothelial plates of all arterial vessels are much elongated, with more or less straight outlines.

The transition of a capillary vessel into an artery is not sudden but gradual, and it is by the muscle cell that we are able to distinguish definitely the latter from the former. The part of the vessel that shows the gradual transition from a purely capillary vessel into one with all the above attributes is called a capillary artery.

Following these minute vessels into larger arterial branches, we notice the following changes: (*a*) besides the cells representing the outer sheath, or adventitia, there is a variable amount of fibrous-connective tissue in the shape of smaller or larger bundles. The larger the vessel the larger the amount of fibrous tissue. In arterial trunks (carotis, subclavia) the adventitia is a complex connective-tissue membrane, inasmuch as the bundles are arranged into groups or trabeculæ crossing each other; between them are the interfascicular lymph spaces, containing branched connective-tissue cells, and also networks of elastic fibres arranged parallel to the long axis of the vessel. These elastic fibres are well seen in large arterial trunks (carotis, subclavia, mesenterica); they are more numerous, and at the same time thicker, in the inner portion of the adventitia, that is, nearest the media.

(*b*) The muscle cells form a continuous membrane in the media or muscle coat proper: the larger the artery the thicker this latter. Most of the muscle cells are arranged transversely, but in larger arteries there are small bundles of oblique or even longitudinal muscle cells. While in the smallest arterial branches the muscle cells are arranged in a single layer, as the vessel becomes larger, also the number of these layers increases. In a section through a hardened artery, that had been kept distended by blood or otherwise, the muscular coat will appear much thinner than if the vessel had been allowed to shrink; and it is important to bear this fact in mind when comparing the muscular coat of two arteries. In the arterial trunks the individual layers of muscle fibres are separated from each other by hyaline elastic membranes and elastic networks. In large arteries (carotid, mesenteric) these interstitial elastic membranes and elastic networks become so increased that they form a conspicuous portion of the media. The arrangement is then so that thin strata of muscle cells are separated from one another by thinner or thicker horizontal or oblique elastic lamellæ, to which are attached networks of fine elastic fibres; these latter enter also into the individual layers of muscle cells.

The elastic lamellæ are generally of the nature of fenestrated membranes of Henle; that is to say, a more or less homogeneous membrane with larger and smaller holes. This membrane is in reality a network of broad more or less confluent elastic fibres, the meshes of the network being the holes of the fenestrated membrane.

The muscle cells of the media are relatively short, and in arterial trunks are more or less branched at their extremities. In the largest arteries of man, such as aorta,

carotis, subclavia, mesenterica, &c., most muscle cells are more or less flattened, and their outline not smooth but beset with small processes.

When the muscle cells are viewed in transverse section (that is, in a longitudinal section through the vessel), they differ in so far from those of a transverse section through ordinary unstriped muscle tissue, such as of the intestine, bladder, uterus, &c., as many more muscle cells are found showing a nucleus in the former than in the latter; the reason being that the muscle cells of the arteries are much shorter than in other organs, and hence more muscle cells are cut through the nuclear portion in a given transverse section through the former than in one through the latter.

In the large arterial trunks also a certain amount of connective tissue is present in the media, in the form of small branched flattened nucleated connective-tissue cells, embedded in a hyaline albuminous interstitial substance.

The media is separated from the adventitia by a special elastic membrane (external elastic coat, Henle), conspicuous only in larger arteries, as carotis, mesenterica, renalis, hepatica, cruralis, &c.

(*c*) The intima is very distinct in all arteries; in the minute branches it is a thin bright elastic membrane, much folded when viewed in a transverse section through a contracted vessel. It is thickened on its outer surface by longitudinal elastic fibres forming a network. In the larger branches the intima is laminated, the laminæ being (longitudinal) fenestrated elastic membranes, between which pass (longitudinal) networks of elastic fibres. In the arterial trunks there are branched connective-tissue corpuscles present between the laminæ constituting the intima.

The large arteries possess on the inner surface of the intima, underneath the lining endothelium, a special connective-tissue membrane, the inner longitudinal fibrous layer of Remak, Kölliker, Gimbert, Eberth, and others. This *subendothelial connective-tissue membrane* consists chiefly of longitudinal bundles of fibrous-connective tissue, and between them are anastomosing branched connective-tissue cells. But even small arterial branches seem to possess a prolongation of this inner connective-tissue membrane, in the form of *a single layer of branched cells* separating the intima from the lining endothelium.

(*d*) The endothelial cells lining the lumen of large arterial trunks are less elongated than those of the minute branches, but this depends on the state of contraction of the vessel; for when this is contracted, the cells appear more elongated and thicker than when not contracted.

The Aorta differs only slightly, in structure, from other large arteries; the following points deserve to be mentioned:—

(*a*) The adventitia, composed of fibrous-connective tissue, is relatively very thin.

(*b*) The media contains, between thin transverse muscular strata, thick elastic membranes; these are placed horizontally or obliquely, and are laminated, being composed of several Henle's fenestrated membranes, and in addition to them there are networks of fine elastic fibres. In the ascending aorta and the arch there is a small inner section of the media that differs from the rest, in so far as the muscle cells are arranged in small groups, running either longitudinally or obliquely; they are separated by thick cylindrical longitudinal elastic fibres which are much branched, and in some places very close or even confluent. Between them are networks of fine elastic fibres running longitudinally or obliquely.

This inner portion amounts in the ascending branch and the arch to about an eighth or tenth of the whole thickness of the media, and gradually passes into the outer part, the muscle cells becoming transverse, and the thick elastic fibres becoming confluent into membranes placed horizontally or obliquely. But there are groups of longitudinal muscle cells also in the outer part of the media, especially near the adventitia.

The muscle cells of the aorta are much branched, flattened, and short, but varying considerably in their broad diameter.

A certain amount of connective tissue, chiefly accompanying small blood-vessels, is to be found in this coat.

(*c*) The intima of the aorta is similar in structure to that of other large trunks, except that it is thicker, and that it contains an appreciable amount of connective tissue added to it; also the subendothelial longitudinal connective-tissue membrane is well developed. In the ascending aorta and the arch the intima is distinctly laminated, the laminæ being composed of elastic fibres, and between them is an appreciable amount of connective tissue, chiefly in the form of branched connective-tissue corpuscles; the subendothelial membrane is here thickest.

(*d*) The endothelium does not differ from that of the arterial trunks.

Besides the aorta there are other arteries in man and mammals that possess longitudinal and oblique bundles of unstriped muscle fibres. According to Remak, Kölliker, Eberth, and others, the arteria lienalis, renalis, femoralis, mesenterica, axillaris, poplitea, &c., possess longitudinal muscle bundles in the adventitia, and, according to Remak and Eberth, the arteria hepatica, lienalis, cruralis, and mesenterica possess them also in the media. This is, however, denied by Bresgen: according to this observer there are no longitudinal muscles in the mesenterica inferior lienalis, gastro-duodenalis, brachialis, radialis, and cruralis. Bardeleben, on the other hand, maintains an inner longitudinal muscle coat for all large and middle-sized arteries.

The basilar artery has no inner longitudinal muscles, whereas the subclavia has them exceptionally well developed. The umbilical artery possesses on the inner surface of the media, of the ordinary structure, a continuous longitudinal muscle coat, and also on the outer surface of it (media) are a few longitudinal muscle bundles (Eberth).

The different coats bear a definite relation to one another: the adventitia is relatively thickest in the minute arteries, being here nearly as thick as the middle coat, it is inferior in thickness to the media in middle-sized and large arteries; in the latter it amounts only to a fraction of the media, and in the first part of the aorta it is reduced to a very delicate membrane. The media is in all arteries, in virtue of its thickness, the most conspicuous coat. The intima increases in thickness towards the aorta; in the microscopically minute arteries it is a very delicate simple membrane. The endothelium is everywhere a single layer of cell-plates.

3. Veins.

Following a capillary vessel towards the venous system, we first come upon the capillary veins: these are broader than the former, and possess, just like the capillary arteries, a delicate nucleated membrane as adventitia and a very thin membrane, composed of a network of longitudinal fine elastic fibres, as intima. The lining endothelial cells are somewhat shorter and broader than those of the capillaries, and their outlines more or less sinuous. What has been said as regards stigmata and stomata in the endothelium of capillaries holds good also for veins (Arnold). There is no muscle tissue, as a media, to be met with in these venous capillaries, and the thickness of their wall as compared with the size of their lumen is therefore greatly inferior to that in the minute arteries. And this same inferiority persists in all veins, viz. their wall is much thinner, and their lumen larger, than in the corresponding branches of the arterial system.

As the capillary veins pass into larger branches, the adventitia increases in thickness by the addition of bundles of fibrous-connective tissue, which are accompanied by the ordinary flattened connective-tissue corpuscles. The (microscopically) large branches of veins show the first traces of a muscular media, the muscle cells being placed transversely; the intima is only slightly thicker than in capillary veins.

In the venous trunks we find (*a*) a relatively thick adventitia, composed chiefly of longitudinal and oblique trabeculæ of fibrous-connective tissue, in the interfascicular spaces are the ordinary connective-tissue corpuscles; thicker and thinner elastic fibres run pre-eminently in a longitudinal direction and form a network.

(*b*) The media contains, in most instances, transverse bundles of unstriped muscle; they never form such continuous layers, and are not separated by elastic membranes, as in arteries, the bundles being separated from each other chiefly by fibrous-connective tissue.

(*c*) The intima is always a very thin elastic membrane; this is composed of networks of longitudinal fibres, more or less confluent into a fenestrated Henle's membrane.

The subendothelial (longitudinal) connective-tissue membrane, mentioned in connection with the intima of the arteries, is generally present in most venous trunks in the form of a delicate network of branched cells, but only in some it contains in addition slender longitudinal bundles of fibrous-connective tissue. It is of conspicuous thickness in the vena poplitea (Eberth).

(*d*) The endothelial lining is composed of short, broad, spindle-shaped, flat endothelial cells with sinuous outlines. In the venous sinuses of the spleen of man and some mammals the endothelial cells are sometimes almost polyhedral, that is, thick and short (Klein).

The valves in veins are folds of the endothelial lining of the whole intima and of part of the muscular media; the muscles are slender bundles that run either longitudinally or transversely (Bardeleben).

The greatest variety exists amongst the larger veins as regards the distribution of unstriped muscles in their wall. The venous vessels of bone and muscle, and of the retina, those of the membranes of the brain and spinal cord, the last portions of the venous trunks emptying themselves into the cava superior, the vena jugularis interna and externa, and vena subclavia have no muscles.

The veins of the gravid uterus possess only longitudinal (unstriped) muscles. The vena cava, azygos, hepatica, spermatica interna, renalis and axillaris possess an inner circular and an outer longitudinal muscle coat. The vena iliaca, cruralis, poplitea, mesenterica, and umbilicalis possess, between an inner and outer longitudinal, a middle circular muscle coat.

The trunk of the venæ pulmonales possesses striped muscle tissue (Arnstein, Stieda). In man they are arranged as an inner circular and an outer longitudinal coat (Stieda), and are to be regarded as a continuation of the striped muscle tissue of the left auricle, with which they are identical in structure (Stieda). The intima of the venæ pulmonales of man is a connective-tissue membrane, containing circular bundles of unstriped muscle cells (Stieda).

Hoyer showed a direct communication of minute arteries with veins, without the intervention of capillaries, to exist in various places, as in the matrix of the nail, in the tip of the nose and tail of some mammals, in the tip of the fingers and toes of man, in the margin of the earlobe of dog and cat, and especially of rabbit. According to the same observer, this anastomosis occurs either with veins that have no muscular

media, but consist only of an endothelial lining, and a connective-tissue adventitia, as in the nail matrix of man, and in the tip of the nose in mammals; or with veins that possess a distinct media of circular muscles, as in the tip of the fingers and toes of man.

The presence of contractile branched pigment cells in the adventitia of arteries and veins of lower vertebrates has been mentioned on a former occasion in Chapter VII. Also the presence of sinuous and spindle-shaped dilatations in the minute veins and capillaries of some striped muscle fibres of rabbit, as discovered by Ranvier, and the spindle-shaped and angular dilatations of the inner (capillary) network of the dura mater of the brain, described by Boehm, Key and Retzius, Michel, and others, have been mentioned in Chapters XI. (p. 80), and XV. (p. 105) respectively.

Peremeschko saw similar spindle-shaped dilatations on the vessels of the ligamentum nuchæ of dog and cat.

Beale described, many years ago, sinuous dilatations on the capillary vessels of the pharynx of frog.

In the cavernous tissue of the male and female genital organs minute veins form a dense plexus in the form of wide sinuous spaces lined by endothelium; into these lead the arterial branches. The wall of these venous spaces is formed by elastic and unstriped muscle tissue.

The adventitia and media of large vessels (arteries and veins) contain a special system of nutrient blood-vessels, vasa vasorum; the arterial and venous branches of these lie chiefly in the adventitia, occasionally also in the outer part of the media; the capillaries generally penetrate into the media and near the intima, only seldom also into the latter (Köster). In the microscopic arterial branches we meet with capillary vessels as a rule only in the adventitia.

Lymph-spaces are present as intercommunicating interfascicular spaces, containing connective-tissue cells, in all coats of arterial and venous trunks. The lymphatics attain their greatest development in the adventitia of large trunks (arteries and veins), where they form a plexus of more or less tubular vessels. In the smaller trunks they form large sinuouslike spaces lined by continuous endothelium. These spaces in the adventitia, both of arteries and veins, become occasionally fused into longer or shorter continuous lymphatic vessels, ensheathing, as it were, the vessel to a larger or smaller extent as a perivascular lymphatic, as is the case with some vessels of the omentum, mesentery, and the membranes of the brain, in the hepatic and splenic artery, and in the pulmonary vessels.

In the large trunks (venous and arterial) there are lymph channels present also in the media; they appear as clefts between the muscle bundles, and communicate with the lymphatics of the adventitia (Köster).

4. Development of Blood-Vessels.

All blood-vessels in their young state are of the nature of capillaries, that is, their wall is a simple membrane consisting of a single layer of nucleated endothelial cells. Considerable differences exist as regards the size of these young vessels, the lumen of some being many times larger than that of ordinary adult capillaries. When the wall of a young vessel exhibits a differentiation into nucleated endothelial plates, and a linear albuminous interstitial substance acting as cement of these endothelial cells, the vessel has already passed the more important stages of its development; these stages, counted backwards, are: (1) the wall of the tubular vessel is an uniform membrane, not exhibiting any differentiation yet into endothelial cells and cement-substance; this membrane is protoplasm containing a network of fibrils, the intra-cellular network, as mentioned above, and appearing therefore uniformly 'granular,' and in it, more or less regularly disposed, are oval nuclei containing the intranuclear network. (2) Previous to the above stage the vessel is irregular, being at some places much narrower than at others; while at the latter it is still tubular, at the former it will be found quite solid protoplasm with nuclei, and resembling then a nucleated protoplasmic thread or band; this latter contains a smaller or larger number of vacuoles, which in some places are more or less close together, and ready to become fused. When this happens, the vessel becomes tubular, the above solid protoplasmic band or thread being thus hollowed out. When these vacuoles appear and, still more, when they increase in number and size, the nuclei previously contained in the centre of that solid protoplasmic band are shifted by them (vacuoles) into the marginal portion. After the band is converted into a tube, this marginal portion containing the nuclei represents the wall of the vessel.

In this state of solid protoplasm with nuclei, we find not only larger or smaller sections of a network of vessels, the rest being composed of already tubular vessels, but also such single structures may be met with that are destined to become branches of an already tubular vessel. In the latter case, viz. where we have to do with the development of a branch, we find it as a longer or shorter nucleated, divided or undivided, solid protoplasmic filament, directly continuous with the wall of the tubular vessel. The portions of the thread containing nuclei are, of course, thicker than the intervening sections. This thread may be a real outgrowth, a 'sprout,' of the wall of the main vessel, and then it may continue to grow; or it may be only a nucleated

cell belonging originally to the surrounding tissue, and identical with a connective-tissue cell, connected with the wall of the vessel. In both cases the solid protoplasmic filament becomes hollowed out, either by the lumen of the main vessel gradually penetrating into it, or by several distinct vacuoles appearing in it, which, by enlarging, become confluent with one another, and also with the lumen of the main vessel. Several connective-tissue cells, connected into a network, may, by separated vacuolation, and by subsequent confluence of these, give origin to a network of capillaries.

In the embryo we meet with large sections of the vascular system, that are at first represented merely by solid nucleated protoplasmic cells, either spindle-shaped or branched, which, by the growth of their processes, become connected with one another so as to form a network. Their nuclei increase by division: at first these are irregularly distributed, but, through the growth of the cell-substance, become gradually shifted into more or less uniform distances, so that when through the appearance and confluence of vacuoles these solid protoplasmic cells and their processes are converted into hollow tubes, we find them (viz. the nuclei) more or less regularly distributed in the wall of the latter. There is also another mode of development of the first vessels in the embryo: this is in isolated cells, at first spherical, and containing one or more nuclei—some of them are large multinuclear giant cells—which through vacuolation are transformed into vesicles; these become gradually connected with one another by protoplasmic threadlike sprouts of their wall, and after these latter have become hollowed out, a network of vessels is established, which at first are very irregular, containing broad sinuous and narrow tubular parts, but in which these inequalities of diameter gradually disappear.

The development of blood-vessels is the same in the embryo and adult, in normal and pathological processes. Stricker was the first who described the formation of capillary vessels as a process of hollowing out of solid nucleated protoplasmic cells; then Afanasieff, Klein, Balfour and others described it for the embryo chick, Arnold for the development of vessels in the inflamed cornea, Klein and Ranvier for the omentum of young and adult animals, Klein for the inflamed serous membranes, and especially Leboucq, who proved it for the development of vessels in the embryo and adult, under various normal and pathological conditions.

In connection with the development of vessels in the embryo, out of solid protoplasmic cells, there is going on at the same time a formation, in their substance, of coloured and colourless blood corpuscles, so that the latter lie in the cavity of the former (Klein, Balfour, Leboucq). Blood corpuscles are also formed in the substance

of connective-tissue cells of the subcutaneous tissue of new-born animals (Schäfer), which by vacuolation are being transformed into capillary vessels.

In those young vessels that are destined to be arterial or venous branches, the original endothelial wall is gradually thickened by cells of the surrounding tissue; these give origin to the elastic, muscular, and connective-tissue elements.

5. The Heart.

(*a*) The outer covering of the heart is a serous membrane (the visceral pericardium), which, like the other serous membranes, is covered on its free surface with an endothelium. The membrane itself is a dense connective-tissue membrane, containing networks of elastic fibres arranged parallel to the surface. In the deeper or subserous part the connective tissue is looser and contains the large vascular and nervous branches, and in many instances larger or smaller groups of fat cells. This connective-tissue forms a continuity with the intermuscular connective tissue, that is, the perimysium separating the bundles of muscle fibres of the substance of the heart itself.

(*b*) The substance proper of the heart is composed of muscle-bundles, the elements of which are striated muscle fibres forming a network and possessing a peculiar structure, described and figured on a former occasion (Chapter XI. pp. 78 and 79). The bundles are separated by a vascular connective tissue of the nature of ordinary intermuscular connective tissue. In the ventricles they form more or less distinct lamellæ. The connective tissue separating these lamellæ includes oblong clefts (Henle), which possess a complete endothelial lining (Schweigger-Seidel), and are therefore to be regarded as belonging to the lymphatic system.

(*c*) The inner or lining membrane, the endocardium, is covered with a single layer of endothelium, which, as has been mentioned in Chapter III., is occasionally in young hearts, in some places, as mitral valves, chordæ tendineæ, and papillary muscles, composed of germinating cells. Next the endothelium is a delicate membrane, consisting of an inner subendothelial network of flat branched cells, and an outer dense network of elastic fibrils; next this follows the chief layer, viz. a connective-tissue membrane, composed of bundles of fibrous-connective tissue, arranged as small trabeculæ, running in different directions and crossing each other under various angles; between them lie the ordinary connective-tissue corpuscles in the interfascicular lymph spaces, and also numerous networks of elastic fibres.

The deep parts are made up of connective-tissue bundles, which further on pass as

perimysium between the muscle bundles of the heart's substance. The thickness of the endocardium varies in different localities; at the ostium of the auricles and ventricles and the summit of the papillary muscles it is greatly increased by a firm connective tissue, identical with tendinous tissue and situated underneath the proper endocardial membrane.

The same firm tendinous tissue occupies the middle layer of the auriculo-ventricular valves which represent merely folds of the endocardial membrane. The semilunar valves are also folds of the endocardium, but contain chiefly elastic tissue. Striated muscle fibres penetrate a short distance into the auriculo-ventricular valves; they are longitudinal and transverse bundles, and are continuations of the muscles of the auricle (Joseph, Gussenbauer). The endocardium of the septum ventriculorum of man contains small bundles of unstriped muscle fibres (Schweigger-Seidel).

In the subendocardial tissue are tracts of striped muscle fibres which differ in no way from those of the heart's substance; they belong to the endocardium, since they are separated from the proper substance of the heart by special layers of connective tissue (Schweigger-Seidel). Amongst the muscle fibres of the endocardium are Purkinje's fibres specially to be mentioned. They form a network. They do not occur in man, rabbit, mouse, cat, and frog (Aeby, Obermeyer), but are met with in many other mammals and birds (Purkinje, Kölliker, Aeby, Lehnert, Obermeyer and others). Each of them represents a thin muscle fibre, the central part of which is homogeneous protoplasm, containing nuclei at regular intervals, while its periphery is striated muscle substance (Schweigger-Seidel, Frisch).

The networks of blood capillaries are of course richest in the muscle substance, but they are also numerous in the pericardial and endocardial membrane, including the valves.

The lymphatic vessels form a pericardial and an endocardial network; into this latter pass the lymphatics of the mitral as well as of the semilunar valves (Eberth, Belajeff). The individual vessels are comparable to lymphatic capillaries (see a future chapter). The muscle substance proper of the heart possesses, besides the above-named lymph spaces of Schweigger-Seidel, also other tubular lymphatics (Lusckka, Eberth, Belajeff).

The nerve branches of the plexus cardiacus, those that run as subpericardial nerves towards the apex of the heart, as well as those situated in the septum ventriculorum, form plexuses; each branch represents a small bundle of ordinary non-medullated nerve fibres, held together by a perineural sheath: amongst them may be met with here and there a medullated nerve fibre.

In connection with the nerve plexus of certain places, to be mentioned presently, are

REESE LIBRARY
OF THE
UNIVERSITY
OF
CALIFORNIA.

I.

II.



III.

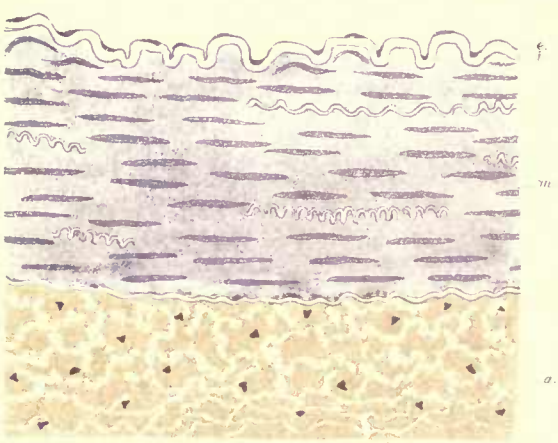

IV.

V.

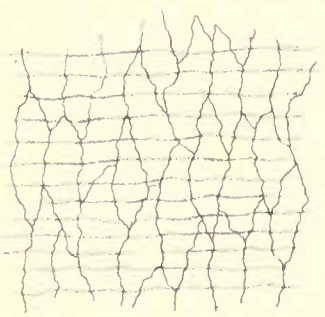

VI.

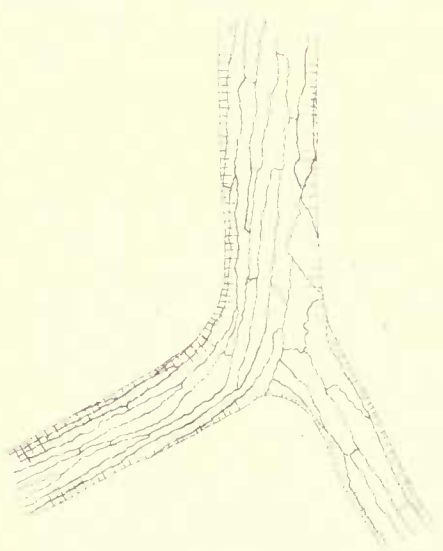

VII.

VIII.

IX

E. Noble Smith fecit.

Mintern Bros imp.

minute ganglia; they vary in size and bear the same relation to the nerve branches as the microscopic sympathetic ganglia described in Chapter XVII. *B.*, being smaller or larger spherical, spindle-shaped or irregular groups or chains of ganglion cells.

The ganglia are very conspicuous in the nerve plexus of the septum auriculorum of the heart of frog (Ludwig, Bidder, and others), also in the septum between auricle and ventricle of the same animal (Dogiel). The ganglion cells in the frog's heart are, according to Beale, possessed of a 'spiral fibre,' but this is denied by Dogiel.

In man and mammals ganglia are present in connection with the subpericardial nerve branches (Schklarevski, Dogiel). According to Dogiel they lie chiefly at the point where the large veins enter the heart, and at the boundary between the auricles and the ventricles. There are no ganglia in other parts of the heart of man and mammals, as maintained by Remak and others. The ganglion cells are of various sizes; most of them are possessed of one process only, which is an axis-cylinder process. Their structure and relation to nerve fibres is the same as that described of the sympathetic ganglion cells of man and mammals in Chapter XVII. *B.*

PLATE XXVI.

Figs. I. IV. V. VIII. and IX. are drawn under a magnifying power of about 350; the rest under one of about 250.

Fig. I. Part of a transverse section through the ascending aorta of pig. The figure represents about the inner fourth of the whole thickness of the wall.

a. Lining endothelium; the nuclei of its cells are shown only.

b. Subendothelial layer of connective tissue, showing in a homogeneous matrix oval nuclei of connective-tissue corpuscles and numerous dots, being longitudinal connective-tissue fibres viewed in transverse section.

c. and *d.* represent the inner coat proper or intima, composed of elastic tissue; at *c* most of its fibrils run circularly; at *d.* the substance is represented homogeneous, with only few elastic fibrils (dots) in transverse section, but there is in reality a dense network of such fibrils.

e. Inner portion of the middle coat or media. It contains in a matrix of very fine elastic fibrils, represented here as a homogeneous purple ground-substance, thick bright cylindrical elastic fibres, which, being arranged longitudinally, are here seen in transverse section; in some places they are more or less coalescing, so as to form membranous structures; besides the elastic fibres are unstriped muscle cells, which, being placed more or less longitudinally, are represented here transversely or obliquely.

f. Beginning with this part the thick elastic fibres of the previous layer form by

confluence elastic membranes separating the unstriped muscle cells; these have become arranged transversely.

Fig. II. Lower part of a minute artery viewed in longitudinal (optical) section; *e.* to *a.* represents the thickness of the wall seen in profile.

e. Nucleated endothelial membrane, lining the lumen of the vessel, seen in profile. In the lumen appear several faint oval nuclei; these are the nuclei of the endothelium looked at from above.

i. Very thin elastic intima.

m. Muscle coat or media; the unstriped muscle cells, being arranged circularly, are here seen as if cut transversely.

a. Nucleated membrane representing the adventitia.

Fig. III. Transverse section through the carotis of dog.

e. Lining endothelial membrane seen in profile.

i. Elastic intima. The subendothelial connective-tissue layer is too delicate to be seen in a transverse section.

m. Media, containing bright wavy elastic membranes, viewed here in profile, separating the circular bundles of unstriped muscle cells, of which only the staff-shaped nuclei are here shown. The networks of fine elastic fibrils, passing from one elastic membrane to another, are not represented here.

a. Adventitia, consisting of bundles of connective tissue indicated by a yellowish-brown tint; between the bundles are seen the deeply stained nuclei of connective-tissue corpuscles and bright cylindrical elastic fibres which, running longitudinally, are here represented in transverse section. Their number is greatest towards the media.

Between the adventitia and media is a wavy elastic membrane, Henle's elastica externa.

Fig. IV. Transverse section through a large branch of the inferior mesenteric artery of pig.

e. Endothelial membrane.

i. Elastic intima. The subendothelial connective-tissue layer being exceedingly thin, is not seen.

m. Muscular media, containing only a few of the bright wavy elastic membranes; the network of fine fibrils separating the bundles of muscle cells are not represented.

A distinct elastica externa divides the media from the connective-tissue adventitia *a.*, which has the same structure as that in the previous figure.

Fig. V. Transverse section through a small artery and vein of the mucous membrane of the epiglottis of a child.

A. Artery, showing the lining nucleated endothelium; the vessel being contracted,

the endothelial cells appear very thick. Underneath the endothelium is the wavy elastic intima. The chief part of the wall of the vessel is occupied by the circular muscle coat; the staff-shaped nuclei of the muscle cells are well seen. Outside this is—

a. Part of the adventitia; this is composed of bundles of connective-tissue fibres, shown in section, with the nuclei of the connective-tissue corpuscles. The adventitia gradually merges into the surrounding connective tissue.

v. Vein, showing a thin endothelial membrane raised (accidentally) from the intima, which, on account of its delicacy, is seen as a mere line on the media; this latter is deeply stained and composed of a few circular unstriped muscle cells.

a. The adventitia is similar in structure to that of the artery.

Fig. VI. Surface view of the endothelium lining a large vein of the frog's mesentery, stained with nitrate of silver. The outlines, i.e. the interstitial cement-substance, of the endothelial cells is shown only, not their nuclei. Underneath the endothelium are seen a few of the outlines of the circular muscle cells.

Fig. VII. Surface view of a minute artery from a silver-stained omentum of rabbit, showing the outlines of the elongated endothelial cells lining the vessel; at the margin of the vessel are seen the outlines, i.e. the interstitial cement-substance, of the circular muscle cells.

Fig. VIII. Part of a capillary artery of the omentum of dog, seen lengthwise. The lining endothelium is seen in profile at the margin, the oval nuclei seen apparently *in* the vessel are the nuclei of the endothelium viewed from the surface. The nuclei of the endothelial cells, being flattened like the cells themselves, appear broader when seen from the surface than in profile.

The media is indicated by groups of circular muscle cells arranged alternately. An outer delicate nucleated membrane represents the adventitia.

Fig. IX. Transverse section through a large branch of the mesenteric vein, accompanying the artery represented in Fig. IV.

e. The lining endothelium, its nuclei are well shown.

i. Delicate elastic intima.

m. Media, the inner part of it is a continuous circular layer of unstriped muscle cells, but the outer greater portion contains muscle cells arranged only in small bundles, and separated by a great amount of connective tissue, with a few thick elastic fibres.

a. Adventitia of connective tissue, with numerous thick cylindrical longitudinal elastic fibres, similar to those in the adventitia of the artery.

The difference in the relation of the various coats and their relative and absolute thickness in the two vessels, represented in Figs. IV. and IX., is well marked.

PLATE XXVII.

All figures, except Fig. XVI., are drawn under a magnifying power of about 350; fig. XVI. with one of about 100.

Fig. X. From an omentum, stained with nitrate of silver, of rabbit.

v. Capillary vein; the nucleated endothelial cells lining the vessel are well shown.

a. Young sprouts connected with branched connective-tissue cells;

c. Unfinished capillaries, viz. such as are in the process of being hollowed out, and whose wall has not yet become differentiated into endothelial cells.

There are other rudiments of capillaries, but they are still solid protoplasmic threads.

Fig. XI. A branched capillary vessel from the frog's bladder, stained with chloride of gold; only the nuclei of the endothelial wall are shown, the preparation, not having been stained in silver, does not show the outlines of the individual endothelial cells. A distinct intranuclear network is seen in each nucleus. There are several coloured blood corpuscles, stained by the gold, in the lumen of the vessel. In the surrounding tissue are seen the branched connective-tissue cells.

m. Migratory cells.

Figs. XII. and XIV. represent capillary vessels of the frog's mesentery, stained with nitrate of silver only; the wall of the vessel is viewed from the surface, and is seen to consist of elongated endothelial plates, marked by their outlines only; the nucleus of the individual endothelial cells is not shown.

Fig. XIII. Young capillaries of the omentum of guinea-pig.

v. Young capillary vein, showing the nuclei of the endothelial wall. The rest is a network of developing capillaries, which, in several places, are still in the stage of solid protoplasm; in all of them are transverse septa, being the remnants of the protoplasm separating the vacuoles.

Fig. XV. Developing capillaries from the tail of tadpole, stained first in chloride of gold and then in hæmatoxylin.

v. Capillary vein, clumps of pigment in its wall.

a. Solid nucleated protoplasmic sprout of the capillary wall meant to become hollowed out.

b. Thin threads of solid protoplasm connecting the wall of two capillaries. These threads are evidently the processes by which the two cells, now transformed into the right and left capillary, were originally connected with one another; when hollowed out such connecting threads represent the branches through which two vessels anastomose.

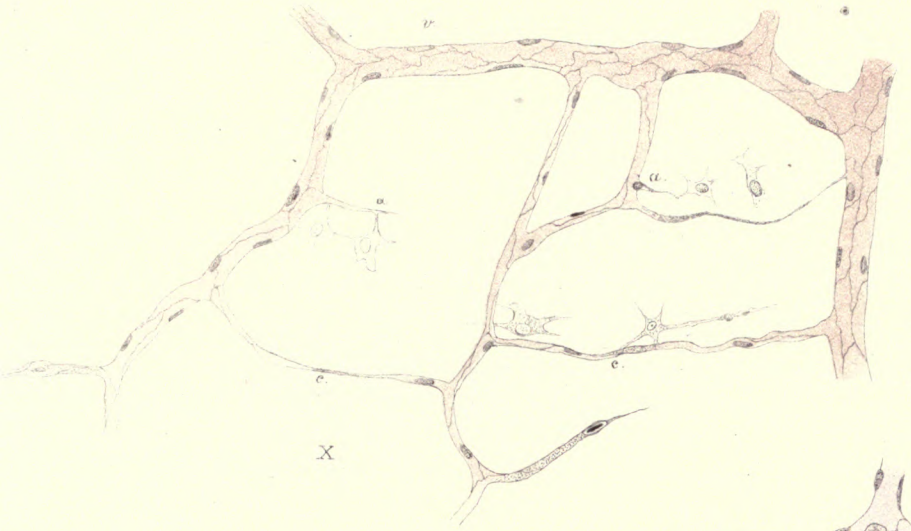

X

XI

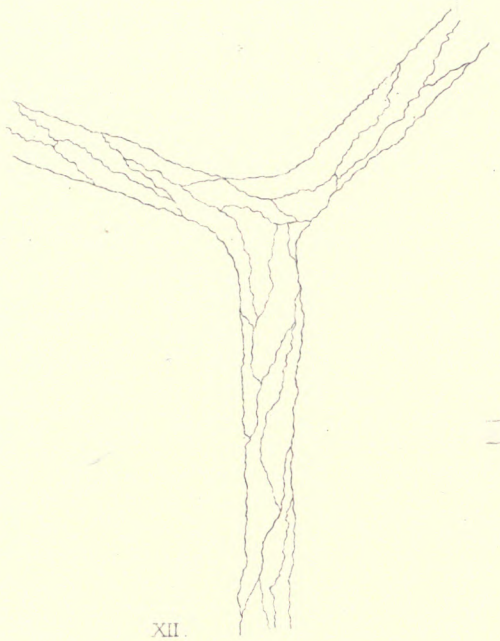

XII

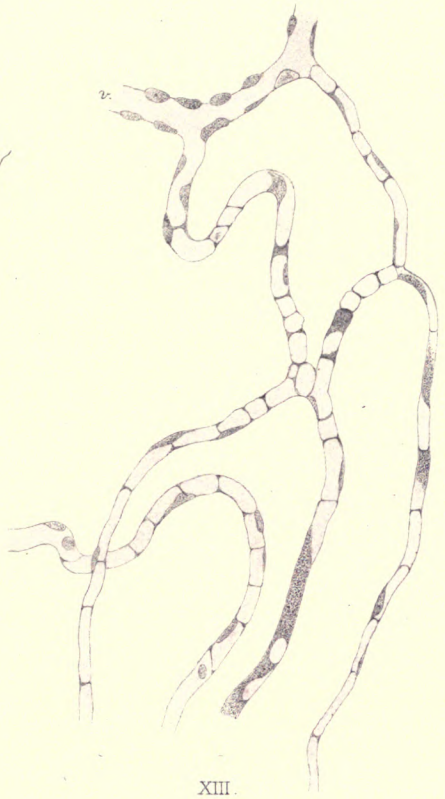

XIII

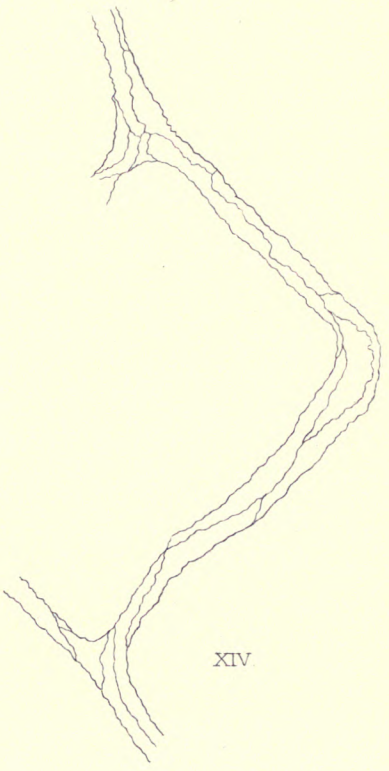

XIV

XV

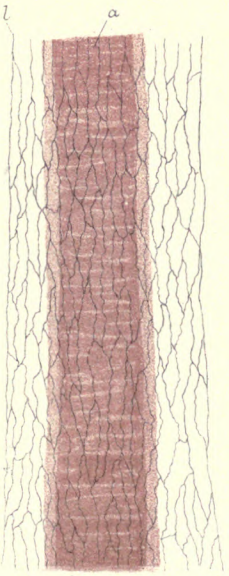

XVI

XVII

E. Noble Smith fecit

Mintern Bros imp.

REESE LIBRARY
OF THE
UNIVERSITY
OF
CALIFORNIA

The small oval nuclei belong to the wall of the vessels. There are four oval nucleated granular corpuscles in the right vessel; they are young coloured blood-corpuscles.

Fig. XVI. Surface view of an artery ensheathed in a perivascular lymphatic vessel, from the frog's mesentery, stained with nitrate of silver.

a. The artery; its deeply-stained circular muscle coat (media) is indicated by broad transverse markings; outside it is an indication of a lighter stained adventitia.

l. Lymphatic vessel; its wall is a simple endothelial membrane.

Fig. XVII. From the same preparation as Fig. XV.

a. Nucleated protoplasmic cell connected with the wall of a capillary vessel.

c. Nuclei of the wall of the capillary vessel. Two coloured blood-corpuscles in the middle part of the figure.

The vessel represented here still recalls the branched cell from which it has developed, several of its processes, like the body of the cell, having become hollowed out; two processes are still solid, and a third one is connected with a spindle-shaped looking protoplasmic corpuscle, *a*, of the surrounding tissue.

CHAPTER XX.

LYMPHATIC GLANDS.

A. Compound Lymphatic Glands.

As such are to be regarded the glands that are interposed in the course of lymphatic trunks, as the subcutaneous lymphatic glands, the cervical glands, the bronchial and mesenteric glands, the glands at the hilus of the spleen and liver, &c. The knowledge of their structure we owe chiefly to the researches of Kölliker, Frey, and Teichmann, and especially His and v. Recklinghausen. Each gland consists of: (1) a framework, (2) the gland tissue proper, (3) the lymphatics, and (4) the blood-vessels and nerves.

(1) The framework is composed of: (*a*) the *capsule*, a connective-tissue membrane arranged as an outer and inner stratum. The former is composed of bundles of fibrous-connective tissue crossing each other in different directions; between the bundles are the ordinary connective-tissue corpuscles; a limited number of elastic fibrils connected into a network may be always met with, and also occasionally groups of fat-cells. This outer stratum is connected with the surrounding loose connective tissue. The inner stratum shows a lamellar structure; the lamellæ consist of parallel bundles of fibrous connective tissue, and are separated from each other by flat connective-tissue corpuscles. Migratory cells may be occasionally met with between the lamellæ.

(*b*) In connection with this inner stratum are membranous *septa*, which penetrate into the interior of the gland in a direction vertical to the surface but more or less radiating towards the hilus, from which emerge the efferent lymphatics. These septa are of the same structure as the inner stratum of the capsule, of which they are direct prolongations.

(*c*) Having penetrated into the gland for a considerable distance, varying in different glands and even in different parts of the same gland, the septa branch into broader or narrower *trabeculæ*, which run in all different directions and anastomosing with one another form plexuses with relatively small meshes. The structure of the trabeculæ is the same as that of the septa. The part of the gland containing the septa is spoken of as the *cortex*, the rest, viz. that containing the plexuses of the trabeculæ, as the *medulla*.

The cortex is subdivided by the septa into a single stratum of longer or shorter oval compartments. Owing to the former (septa) possessing a more or less radiating direction, most of the latter (compartments) are broader at their capsular surface than towards the medulla.

The septa between two neighbouring compartments not being complete, these latter communicate with one another laterally. Towards the medulla the compartments are in open communication with the spaces pertaining to the medulla, viz. those contained in the plexuses of the trabeculæ. In many mammals (Heyfelder), especially pig and calf, the septa and trabeculæ contain unstriped muscle-cells, some of the trabeculæ being almost entirely muscular.

Besides the flat connective-tissue corpuscles, the septa and the trabeculæ contain in some instances (pig, guinea-pig, occasionally also man) numerous plasma-cells of Waldeyer.

It is essential for the understanding of the structure of the compound lymphatic glands to have a clear conception of the arrangement of the framework. In examining sections through these glands it is necessary to be aware that only those sections that pass through the gland in the direction of the septa, show the exact relations of the cortex and medulla, and the shape and size of the above compartments.

(2) The gland tissue proper or *adenoid tissue* (His) occupies the above compartments of the cortex and the spaces between the trabeculæ of the medulla. From the peculiar arrangement of the framework as above described it follows that the adenoid tissue forms in the cortex a stratum of oval or egg-shaped masses, *follicles*; these masses pass in the shape of more or less cylindrical tracts, *medullary cylinders*, into the medulla, where they anastomose into a network. The cortical follicles are everywhere separated from the capsule and septa by a distinct and almost uniform space, *lymph-sinus* (His); the same relation exists also in the medulla, the medullary cylinders being separated from the trabeculæ by uniform lymph-sinuses.

The lymph-sinuses of the cortex represent therefore the peripheral portion of the above compartments, and their boundaries are consequently the outer surface of the follicles on the one hand, and the inner surface of the capsule and septa on the other; the lymph-sinuses of the medulla are the spaces between the surface of the medullary cylinders and the trabeculæ. From what has been said above, on the occasion of the framework, the cortical sinuses intercommunicate with one another; so do, of course, the medullary sinuses; and also the former are in open communication with the latter.

The structure of the adenoid tissue both in the follicles of the cortex and in the cylinders of the medulla is precisely the same; it is this: (*a*) the ground substance or matrix is a dense reticulum, *adenoid reticulum*, of fine homogeneous fibrils and mem-

branes joined into a honeycomb. This honeycomb contains all gradations between fibrils and plate-like expansions. Its chemical nature is not definitely ascertained; it is neither identical with elastic tissue nor with common fibrous tissue.

(*b*) Applied to this adenoid reticulum are from place to place transparent flattened (connective-tissue) *endotheloid cells*, each with an oval but flattened nucleus. The large clear nuclei, which in an ordinary section are situated *apparently in* the nodes of the reticulum, are in reality the nuclei of these endotheloid cells fixed on the reticulum. By prolonged shaking or pencilling of a section of the gland all the endotheloid cells can be removed from the reticulum, and this latter is then seen to be barren of any nuclei, at any rate in the adult state (Bizzozero, Klein). In embryonal life and during early periods of development the reticulum, being derived from branched cells, possesses nuclei, but these disappear as the development advances.

(*c*) The meshes of the adenoid reticulum contain, according to their size, two, three or more *lymph-corpuscles*; they are completely filled by the latter. These lymph-corpuscles are small cells, each with a conspicuous spherical nucleus, staining deeply in ordinary dyes. In most corpuscles the amount of cell-protoplasm surrounding the nucleus is very small and escapes superficial observation. An ordinary section through adenoid tissue reveals at first sight only these nuclei, densely crowded; of the delicate cell-substance surrounding each of them, and of the adenoid reticulum containing them, very little is to be noticed. The nucleus of the lymph-corpuscles is smaller than that of the endotheloid plates, spherical, whereas the nucleus of the latter is oval and flattened, and stains more deeply and appears therefore less transparent than the latter. The intranuclear network is always more distinct in the latter than in the former. When carefully examining the lymph-corpuscles it will be seen that some of them are larger than others, possessing a larger amount of cell-protoplasm; they contain one or two nuclei, and are considered in a more advanced state of development; under suitable conditions they show amœboid movement. They differ from ordinary colourless blood-corpuscles chiefly in the fact that the nuclei are larger in the former than in the latter.

(*d*) The adenoid tissue is richly supplied with blood-vessels; like all glandular tissues, it contains a dense network of capillaries. These differ from ordinary capillaries in so far as they obtain from the adenoid reticulum a special sheath, the capillary adventitia (His).

The adenoid tissue occurs also in the simple lymphatic glands and other kindred organs; it possesses everywhere the same structure, and we shall, therefore, not detail its structure again, when describing the latter.

(3) The lymphatics; the afferent lymphatics enter the capsule and branch here into

numerous vessels which are connected into a dense network; the vessels of this network are situated in the outer stratum and between this and the inner stratum. They are lymphatic tubes with valves and corresponding saccular dilatations. From this network vessels pass into the depth and open into the cortical sinuses. As has been mentioned above, these are freely connected with the medullary sinuses forming an intercommunicating system. At the hilus tubular lymphatics are developed from the medullary sinuses. Some of these vessels may be traced, embedded in a trabecula, for a considerable distance into the medulla of the gland. They are possessed of valves and corresponding saccular dilatations; at and near the hilus they are connected into a network. From this network are developed the efferent lymphatic trunks.

The stream of lymph or injection fluid passing through the gland is therefore from the afferent vessels into the capsular network; from here into the cortical, then into the medullary, sinuses; from these into the network of lymphatics of the hilus, and finally into the efferent lymphatic trunks.

Neither the cortical nor medullary sinuses are, however, free passages like the other lymphatics, for they are filled with a spongy substance, a peculiar reticulum, by which their cavity is subdivided into minute spaces.

This reticulum, although in some respects similar to the adenoid reticulum, differs from the latter by being thicker and coarser, and its meshes larger. Like the adenoid reticulum it is also of a homogeneous nature. We have, then, a sponge-like reticulum occupying the sinuses that separate, in the cortex, the surface of the follicles from the inner stratum of the capsule and septa, and in the medulla, the surface of the lymphatic cylinders from that of the trabeculæ.

The afferent lymphatics, those of the capsular network, as well as the lymphatics of the hilus and the efferent trunks, are lined with a single layer of endothelium like other lymphatics to be specially described in one of the next chapters, so are also the sinuses of the cortex and medulla: both the surface of the follicles and of the medullary cylinders, on the one hand, and that of the septa and trabeculæ, on the other, being covered with a layer of endothelial cells.

This endothelium is continuous on to the aforesaid spongy reticulum, stretching through the sinuses; the flattened endothelial cells do not, however, cover the spaces of the reticulum, but keep close to its fibres and membranes.

In some animals (bovine) the endothelial cells of the sinuses of the medulla, both those covering the medullary cylinders and trabeculæ as well as those belonging to the spongy reticulum, are filled with yellowish-brown pigment granules; hence the medulla presents already in the fresh state a dark brown colour.

The meshes of the reticulum of the cortical and medullary sinuses generally contain

numerous lymph-corpuscles; the greater majority of these possess a well-marked cell-protoplasm surrounding the relatively large nucleus, and are therefore to be considered as in a ripe state. Passing a current of fluid through the afferent lymphatics of the gland, it will be found that these lymph-corpuscles are readily removed from the cortical and medullary sinuses into the efferent lymphatics, and there is no reason why the similar thing should not happen already during life. It is supposed that these lymph-corpuscles are produced in the follicles and medullary cylinders, whence they are floated into the lymph-sinuses by the natural current of plasma passing from the capillary blood-vessels towards the lymphatics (Recklinghausen), similar to what is the case in all other tissues (see a future chapter). In this the lymph-corpuscles are very probably aided by their amœboid movements. After having been discharged by the lymphatics into the venous system they represent colourless blood-corpuscles.

(4) The blood-vessels and nerves. The arterial and venous branches are embedded in the trabeculæ and septa, the networks of capillaries, including capillary arteries and veins, belong entirely to the adenoid tissue. The distribution of fine nerves is not known.

B. Simple Lymphatic Glands.

As such are to be considered the masses of adenoid tissue occurring in the shape of spherical or oval lymph-follicles, singly or in groups, or as nodular and cord-like, or irregularly defined accumulations.

The tonsils are folds of the oral mucous membrane containing a collection of lymph-follicles. The surface, like that of other parts of the mucous membrane of the oral cavity, is covered with stratified pavement epithelium; underneath this is a connective-tissue mucosa, which contains closely aggregated spherical or oval lymph-follicles. In adults the number of them is very great and the mucosa is so much folded, that hereby numerous pit- or cleft-like depressions become apparent on its surface. Towards the epithelium of the surface the adenoid tissue of the follicles is more or less diffuse, penetrating in many places into the epithelium itself; here the epithelial cells give way before the adenoid reticulum and the lymph-corpuscles.

At the root of the tongue (Kölliker, Huxley) and in the upper part of the pharynx (Kölliker, Luschka) a similar accumulation of lymph-follicles is met with.

The thymus gland is an aggregation of well-defined more or less cylindrical masses of adenoid tissue anastomosing into a network; these masses are separated from each

other by fibrous connective tissue, which together with the capsule form the framework of the gland. This will be described more minutely in the next chapter.

Similar lymph-follicles, singly or in groups, or as diffuse masses of adenoid tissue, occur in the mucous membrane covering the posterior surface of the epiglottis, in the walls of the ventriculus Morgagni of the larynx, and in the conjunctiva. The mucosa of the pyloric end of the stomach possesses lymph-follicles, either singly or in groups, as the so-called glandulæ lenticulares.

The small intestine contains lymph-follicles, either singly as solitary, or in smaller or larger groups, as agminated glands. In both cases they are situated with their chief portion, viz. the body of the follicles, in the submucous tissue; with the rest they are pushed through the muscularis mucosæ into the mucosa. In the agminated glands each individual follicle reaches the inner free surface of the intestine, and like this is covered with columnar epithelium. This end represents the summit, the opposite the basis of the follicle. The epithelium, covering the summit of the follicles, is in many parts altered by the growth of the subjacent adenoid tissue into it, the individual epithelial cells giving way before the growing reticulum and lymph-corpuscles (Watney). In consequence of the above arrangement of the follicles of the agminated glands, the mucosa, containing Lieberkühn's crypts, and covered with villi, is reduced to minute folds between the summits of the follicles. The mucous membrane appears at the same time much thicker than the surrounding parts, and is conspicuous as a patch somewhat projecting over the general surface. Such a patch is called a Peyer's patch. In the Peyer's patches the follicles are arranged in a single stratum, and are confluent with their middle portion, but separate at the summit and basis. The number of follicles contained in a Peyer's patch varies greatly, and hence also the size of the latter. Their numbers and sizes increase towards the ileo-cæcal valve; in carnivorous animals the mucous membrane of the lower part of the ileum is one single large Peyer's patch.

In the large intestine we meet with single lymph-follicles which are considerably larger than the solitary glands of the small intestine; they are also situated with their body in the submucous tissue; occasionally they are pushed through the muscularis mucosæ and penetrate into the mucosa. In the rabbit the mucous membrane of the cæcum is filled with lymph-follicles, which possess the same relation to one another and to the mucosa as those in the Peyer's patches: in fact, the mucous membrane is a Peyer's patch with the difference that there are no villi.

The adenoid tissue of the lymph-follicles of the small and large intestine passes at the sides below their (follicles) summits, directly into the tissue of the mucosa, both being in all respects similar in structure.

The mucous membrane of the small bronchi contain isolated lymph-follicles, and also diffuse masses of adenoid tissue.

The spleen contains cylindrical masses of adenoid tissue ensheathing the arterial branches; these cord-like masses are possessed of oval or spherical enlargements, either uniform or one-sided. The Malpighian corpuscles of the spleen, generally incorrectly represented as spherical or oval bodies placed laterally on an arterial branch, are, in the majority of instances, transverse sections through such a cord-like mass of adenoid tissue ensheathing an artery; this vessel is generally situated excentrically, being surrounded by a greater amount of the adenoid tissue on one side than on the other.

The serous membranes (omentum, pleura mediastini) contain smaller or larger nodular, patch-like, or cord-like masses of adenoid tissue, covered on one or both surfaces with germinating endothelium, as has been mentioned in Chapter III. (p. 21). These masses have either a well-defined outline, or they are more or less diffuse; their growth and relation to fat-tissue has been referred to in Chapter VI. (pp. 42 and 43).

Smaller or larger diffuse masses of adenoid tissue occur occasionally in the mucous membrane of the false vocal cords and trachea, in the mucosa of the soft palate and uvula, in the œsophagus, in the tissue in which the tubes of the epididymis are embedded, and in the interlobular tissue of the pancreas.

The adenoid tissue contains in its adult state a special system of blood-vessels. This is especially the case in the follicles, both single and in groups; each follicle contains an afferent arterial branch, one or more venous branches, and an intermediary network of capillaries. In the follicles of the root of the tongue, in those constituting the tonsils, in those of the upper part of the pharynx, in the solitary follicles of the small and large intestine, and in those of the Peyer's patches, the veins form a plexus around the follicles, while the capillaries are arranged more or less radiating towards the centre of each follicle. The number of capillaries in a follicle is generally considerable, but there are differences in this respect in different organs: thus, the follicles of the intestine are much richer in capillary vessels than the follicles of the tonsils, or the Malpighian corpuscles of the spleen.

The follicles of the root of the tongue, tonsils, pharynx, intestine, bronchi, &c., are surrounded, over a larger or smaller portion of their circumference, by a lymph-sinus (His, Frey, and others), which is in open connection with a lymphatic vessel of the surrounding tissue. Both the visceral surface, i.e. that belonging to the follicle, as well as the parietal surface, i.e. that separating the sinus from the surrounding connective tissue, is covered with a layer of endothelial plates with more or less sinuous outlines.

REESE LIBRARY
OF THE
UNIVERSITY
OF
CALIFORNIA.

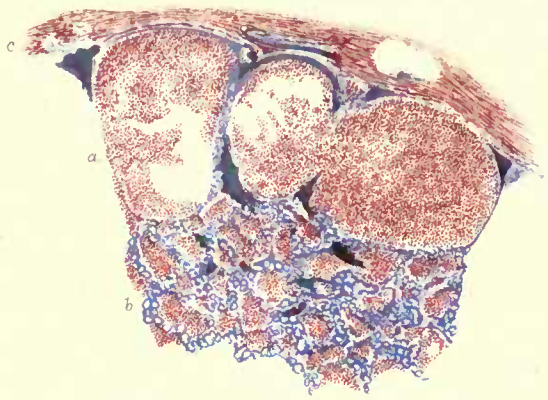

I.

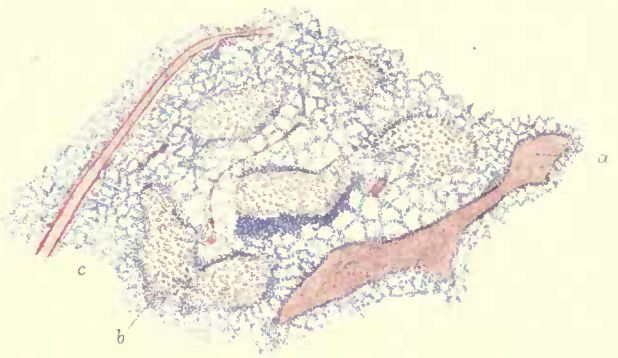

II.

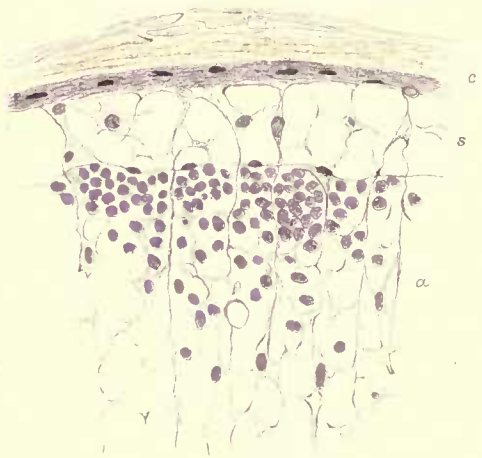

III.

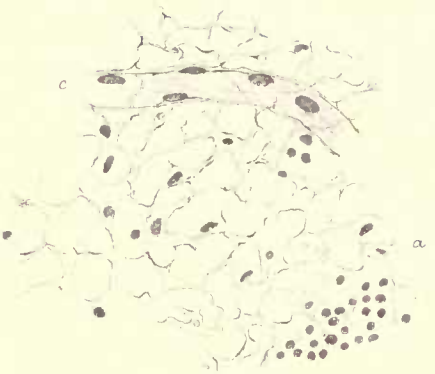

IV A

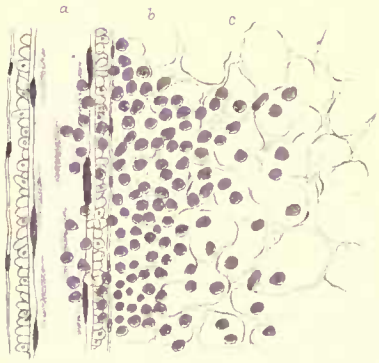

IV B

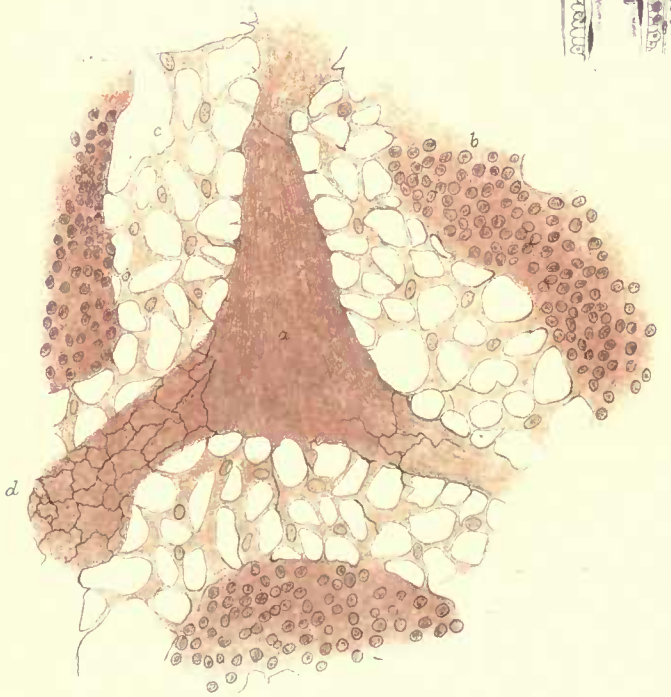

V.



VI.

The lymph-follicles develop as masses of adenoid tissue around the wall of a lymphatic, generally unilaterally (Klein). So that they are from the outset surrounded on one side by a lymph-sinus, this being part of the lymphatic vessel. In many instances the first appearance of the adenoid tissue is in the wall of a small arterial branch between this and a neighbouring lymphatic.

Also the compound lymphatics have a similar history, inasmuch as Sertoli has shown that they are developed as masses of adenoid tissue in the wall of lymphatics connected into a network.

Sometimes even in adults (subcutaneous tissue of guinea-pigs and rabbits), small compound lymphatic glands may be seen developing as masses of adenoid tissue with its capillary blood-vessels in the sheath of a minute artery; these masses form cylinders and are connected into a network, surrounded by, and embedded in, *a network of lymphatics*. These cylinders become very much enlarged at the periphery as cortical follicles. In the cavity of the lymphatics, viz. the future sinuses, a young reticulum makes its appearance later on.

PLATE XXVIII.

Fig. I. From a vertical section through a compound lymphatic gland of dog, the afferent lymphatics of which had been injected with Berlin blue. The section had been stained in picrocarmine. Magnifying power about 25.

c. Capsule, containing a few lymphatics cut transversely, these open into the cortical sinuses.

a. Lymph-follicles of the cortex, surrounded by lymph-sinuses.

b. Medulla, showing the network of (pink) cylinders of adenoid tissue, and the lymph-sinuses injected blue; the injection-matter appears in the form of a network owing to its being deposited on the reticulum contained in these sinuses. The trabeculæ are not visible under this low power.

Fig. II. A portion of the medulla of the same gland as represented in the previous figure, somewhat more magnified, about 90. The section had been stained, first in picrocarmine, and then in hæmatoxylin.

a. Trabeculæ of various sizes.

b. Medullary cylinders, cut in different ways; their minute structure is not shown.

c. Lymph-sinuses, showing the injection-matter deposited as a network.

Fig. III. From a vertical section through the capsule, cortical sinus, and peripheral portion of follicle of a human compound lymphatic gland. The section had been shaken, so as to get rid of most lymph corpuscles. Magnifying power about 350.

c. Capsule composed of an outer and inner stratum. The former consists of bundles of fibrous connective tissue cut in various ways, because running in different directions; the latter possesses lamellæ of connective tissue with flattened connective-tissue corpuscles between; only the nuclei of the latter are shown.

s. Lymph-sinus, containing a reticulum and on it nucleated flattened endothelial cells.

a. Adenoid tissue of lymph-follicle, shaken. The surface of the follicle is covered with a distinct nucleated membrane, endothelium. Numerous nuclei, indicative of lymph-corpuscles, are left in the adenoid reticulum.

Fig. IVA. Shaken adenoid tissue of cortical follicle of a mesenteric gland of calf. The adenoid reticulum, *a*, is well seen; only few nuclei of lymph-corpuscles are left in its meshes. The oval nuclei are indicative of the hyaline flattened endothelial cells; *c* is a capillary blood-vessel ensheathed in the adenoid reticulum. Magnifying power about 300.

Fig. IVB. Part of a Malpighian corpuscle of spleen of man. Magnifying power about 350.

a. Arterial branch in longitudinal section.

b. Adenoid tissue, still containing the lymph-corpuscles; only their nuclei are shown.

c. Adenoid reticulum; the lymph-corpuscles had been removed accidentally.

Fig. V. From a section through the medulla of a rabbit's mesenteric gland, the lymphatics of which had been injected with nitrate of silver. Magnifying power about 350.

a. Trabecula; at *d* it is seen from the surface, and therefore it appears covered with an endothelium; the rest of the trabecula, being cut longitudinally, shows only at the margin the endothelium in the form of a thin dark line.

This endothelium is seen in many places, especially towards the lower part of the figure, to extend on the reticulum occupying the lymph sinuses, *c*; the nuclei on the reticulum correspond to these endothelial plates.

b. Medullary cylinders; except the nuclei of the lymph-corpuscles, their structure is not shown.

Fig. VI. From a section through the medulla of a mesenteric gland of ox. Magnifying power about 300.

a. Trabeculæ.

b. Medullary cylinders; their minute structure, except the nuclei of the lymph-corpuscles, is not represented.

c. The reticulum occupying the lymph-sinuses; this reticulum is covered with nucleated flat endothelial cells containing brown pigment granules. Both the surface of the trabeculæ and medullary cylinders are seen to be covered with the same endothelial cells shown in profile.

LIBRARY
OF THE
UNIVERSITY
OF
CALIFORNIA

VII.

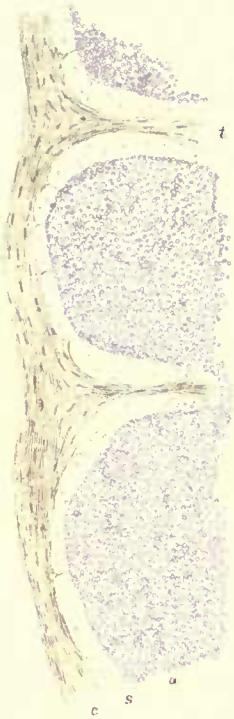

VIII.

IX.

X.

XI.

XII.

PLATE XXIX.

Fig. VII. From a vertical section through the skin of pig's ear-lobe, to show the distribution of the lymphatics. This figure is illustrative of a point to be considered in the chapter on lymphatic vessels.

b. Distended blood-vessels in transverse section.

l. Lymphatic vessels, their wall a single layer of endothelial plates; these vessels are in open communication with the lymph-canalicular system, the intercommunicating interfascicular spaces; they contain the nucleated connective-tissue corpuscles, seen here in profile.

The skin had been œdematous, and hence all the interfascicular spaces are abnormally distended, as shown at *c.*

The blood-vessels are also surrounded by these lymph spaces.

The connective-tissue bundles cross each other in different ways and are therefore cut in various directions, most of them transversely and obliquely.

Fig. VIII. From a vertical section through a mesenteric gland of rabbit. Magnifying power about 100.

a. Peripheral portion of cortical lymph-follicles; under this power they appear as a dense accumulation of nuclei.

s. Lymph-sinus; the lymph-corpuscles have been removed.

c. Inner stratum of capsule.

t. Septa coming off from the capsule, and passing in between the follicles.

Fig. IX. From the same preparation as in the preceding figure, but illustrating the portion of the medulla adjoining the cortex.

a. Transition of the cortical follicles into the medullary cylinders.

b. Lymph-sinuses; the lymph-corpuscles, with which they are ordinarily filled, have been removed by shaking.

c. Trabeculæ.

d. Medullary cylinders of adenoid tissue; their minute structure is not to be made out under this low power, and they appear merely as a collection of nuclei.

Fig. X. Vertical section through a Peyer's patch of cæcum of rabbit, showing two lymph-follicles and their relation to the other parts of the wall of the intestine. Magnifying power about 100.

a. Middle part of lymph-follicles, i.e. the part where they are fused.

s. Summit of follicles covered by the epithelium of the surface; the adenoid tissue

of the follicle penetrates, as a rule, in many places into this epithelium; but this point is not represented in the figure.

m. Mucosa pressed into folds, and containing the crypts of Lieberkühn, most of them being cut transversely.

L. The basis of the follicles is surrounded by lymph-sinuses separated from each other by the connective tissue of the submucosa, containing the large blood-vessels and lymphatics.

c. External circular muscular coat.

b. External longitudinal muscular coat, cut transversely.

p. Peritoneal covering, separated from the muscular coat by the subserous lymphatics.

Fig. XI. A portion of dog's pleura mediastini, stained with nitrate of silver. Magnifying power about 100.

a. Fenestrated membrane, its trabeculæ are covered with flattened endothelium.

b. Large trabeculæ, more or less freely projecting over the general surface.

c. Nodular masses composed of adenoid tissue and covered with germinating endothelium.

b and *c* contain numerous amorphous black particles, which are carbon particles. The lymphatics of both lungs and the bronchial glands of the same animal were also filled with carbon. This will be referred to in the chapter on the lymphatic vessels.

Fig. XII. From a transverse section through a portion of the tonsil of dog. Magnifying power about 100.

E. Stratified pavement epithelium.

L. Diffuse adenoid tissue, filling the mucosa and penetrating at the depth of the fold, represented in the middle of the figure, into the epithelium of the surface.

F. More or less well-defined lymph-follicles.

m. Part of a mucous gland situated in the submucous tissue.

CHAPTER XXI.

THE THYMUS.

A. The Framework.

A capsule of fibrous tissue surrounds the gland; into the interior of the latter pass septa connected with the former and carrying the arterial and venous branches and the efferent lymphatics. The large septa branch into smaller ones; by the former the gland is subdivided into lobes, by the latter into lobules. Lamellæ of connective tissue, derived from the interlobular septa, pass into the individual lobules, and subdivide them into follicles. The connective tissue of all these parts is composed of bundles of fibrous-connective tissue, more or less arranged as lamellæ, separated by the ordinary flattened connective-tissue corpuscles, and great numbers of small lymph-corpuscles. In the capsule and the larger septa we meet with a small amount of elastic tissue in the form of networks of fine elastic fibres.

The capsule is surrounded by a continuation of the pleura, a delicate connective-tissue membrane with networks of elastic fibrils and numerous capillary blood-vessels, a plexus of nerve fibres and a few lymphatic vessels; towards the pleural cavity it is covered with a single layer of endothelium.

B. The Gland Substance.

The follicles are very irregular in shape, most of them being oblong or cylindrical. Near the capsule they are well defined from one another, and present a polygonal outline, often very regular; towards the interior of the gland the follicles become more or less fused.

Each follicle consists of a cortical or peripheral and a medullary or more or less central portion (Watney); the relation between the two, as regards amount, is not everywhere constant, but in most instances the cortical portion is greater in extent than the medullary. The medulla of neighbouring follicles is occasionally continuous (Watney).

The matrix of the follicles is a *fine reticulum*, differing from the adenoid reticulum, described in the preceding chapter, chiefly in the fact that in the thymus the

reticulum still presents its embryonal aspect, being composed of nucleated branched cells. These cells consist of a flattened body with broad platelike sections (Afanassiew); numerous delicate filamentous and membranous processes are joined together so as to form the reticulum.

The reticulum of the medulla contains coarse and short fibres; those of the cortex are finer and longer (Watney).

In the meshes of this reticulum lie the ordinary lymph-corpuscles, as described in connection with the adenoid tissue of the other lymphatic glands; each lymph-corpuscle consists of a spherical nucleus, deeply staining in the different dyes, and of a very delicate zone of protoplasm. In the cortex of the follicles these lymph-corpuscles more or less completely fill the meshes of the reticulum; in the medulla they are by far not so numerous. To the meshes of the reticulum appertain also endotheloid cells, transparent large cells, each with a transparent large oval nucleus. In the medulla these cells are very numerous, and regularly distributed, in such a manner that each of them fills the greater part of a mesh of the reticulum. Hence the lymph-corpuscles are here reduced to a narrow zone between the branches of the reticulum and the endotheloid cells. The effect of this arrangement is that the medulla is at once very conspicuous by its transparency and by the few lymph-corpuscles limited chiefly to the sides of the meshes of the reticulum.

These endotheloid cells are also present in the cortex, but being smaller, a greater section of each mesh of the reticulum is filled with the lymph-corpuscles. In many places the endotheloid cells of the medulla, occasionally also of the cortex, are less transparent, being more granular, and include one, two, or three nuclei (large granular cells of Watney). From these to multinuclear giant cells all transitional forms may be met with.

The so-called concentric corpuscles are protoplasmic masses of various sizes; they occur in the medulla, and each consists of a central nucleated granular part, around which are placed, more or less concentrically, flattened nucleated endotheloid cells (Watney).

According to Afanassiew the concentric corpuscles are developed in blood-vessels by a multiplication of the lining endothelium; hereby the vessel becomes gradually obliterated, and the involution of the gland is thus initiated. According to Watney they are, on the contrary, concerned in the formation of blood-vessels and connective-tissue trabeculæ.

Each follicle possesses a network of capillaries, chiefly belonging to the cortex, and radiating from the periphery towards the centre; the medulla possesses larger vessels than the cortex (Watney). In the dog the larger vascular branches penetrate

into the centre of the follicle before giving off the capillaries for the cortex (Kölliker, Afanassiew).

As in the adenoid tissue of other lymphatic glands, so also here the blood-vessels obtain from the reticulum a special adventitious sheath.

Lymph-sinuses may be seen occasionally surrounding a greater or smaller portion of the periphery of the follicles (Klein).

CHAPTER XXII.

LYMPHATIC VESSELS.

1. The large lymphatic trunks, as ductus thoracicus and tributaries, have a structure in some respects similar to veins, but differing from these in the extreme thinness of their wall as compared with the large lumen. (*a*) A delicate adventitia of fibrous-connective tissue forms the outer boundary; (*b*) next comes the media, a circular layer of unstriped muscle cells; (*c*) on the inner surface of this is a fine elastic membrane, the intima, composed chiefly of a network of longitudinal elastic fibrils; the inner boundary is formed by (*d*) a single layer of elongated nucleated endothelial plates with more or less sinuous outlines.

The semilunar valves are folds of the intima and the endothelium.

2. The microscopic lymphatic vessels, such as are present in great numbers in most tissues and organs, are tubular structures; many of them possess valves and corresponding saccular dilatations; their wall is simple, being, like that of capillary blood-vessels, a single layer of endothelial plates. The endothelial cells are more or less elongated and possess each an oval excentric flat nucleus: their structural characters have been described and illustrated in Chapter III., and they have been illustrated on Plate VI. The lumen of the lymphatics bears no relation to their wall, for lymphatics that are not broader than blood capillaries, as well as such that are many times larger, have an equally delicate endothelial membrane for their wall. Hence it follows that, unlike blood-vessels, they cannot rely on the firmness of their own wall for keeping their lumen free, but must be supported in this by the surrounding connective tissue. And indeed, these vessels will be found invariably collapsed and lost to view, as soon as the tissue in which they are embedded is allowed to shrink or does otherwise contract.

The lymphatics in all tissues and organs are connected into a plexus, the density and arrangement of which varies in different localities; all the vessels of such a plexus that possess valves and corresponding saccular dilatations are considered as trunks, whereas those parts of the plexus that have no valves are lymphatic capillaries. The trunks are, as a rule, more tubular in character than the capillaries, which are often irregular, saccular, or cleft like cavities; besides, the endothelial cells forming the wall of a trunk are generally elongated, whereas those of a capillary are shorter and their

outlines more sinuous (see Plate VI. fig. XIII.). It is to be borne in mind, however, that this latter condition may be met with also in the trunks, whose wall has become much shrunk. The size of the vessel is no distinguishing character, for in many organs we find capillaries of greater calibre than the trunks.

In some localities we find one or the other blood-vessel completely ensheathed in a lymphatic capillary, perivascular lymphatic (Robin, His, Stricker, MacGellavry and others).

3. In all instances the lymphatic capillaries bear a definite relation to the tissue to which they belong, having their rootlets in this latter. It is this: the capillaries open into a system of lacunæ connected with each other by finer or broader canals or clefts: this system, which is the lymph-canalicular system of v. Recklinghausen, is moulded, as it were, in an albuminous, semifluid interstitial substance, and represents, as has been mentioned on former occasions (Chapter IV.), the spaces containing the connective-tissue corpuscles, these forming, as it were, an endotheloid lining for it. While, therefore, the cavity of the capillary lymphatic is in a free communication with the lymph-canalicular system, its endothelial wall is continuous with the connective-tissue corpuscles contained in the former (Kölliker, v. Recklinghausen, Klein). Such we find the relation of the lymphatic capillaries to the surrounding tissue in the lung, serous and synovial membranes and membranes of the brain and cord. In some places, such as cornea, cartilage, white and grey matter of the brain and cord, the lymph-canalicular system is the chief and to a great extent the sole representative of the lymphatics.

The nature of the lymph-canalicular system differs, however, considerably in different organs, being dependent on the nature and arrangement of the matrix. The most typical and regular form of it we meet with in the cornea, lung, serous membranes and bone, being uniformly branched and anastomosing lacunæ, lined by the corresponding corneal corpuscles, branched connective-tissue cells, or bone corpuscles respectively. In tendon, fascia and aponeurosis, owing to the peculiar arrangement of the connective-tissue bundles (see Chapter IV.), it consists of straight and continuous clefts and channels situated between groups of connective-tissue bundles; in striped and unstriped muscle, and nerves, there are likewise long and straight clefts and spaces extending between the individual fibres.

In the skin and mucous membranes and similar masses of ordinary fibrous-connective tissue the lymph-rootlets are of a very irregular nature, viz. spaces left between groups or trabeculæ of bundles crossing each other in a complex manner, interfascicular spaces. As has been mentioned on a former occasion, the connective-tissue corpuscles are applied to the surface of the trabeculæ so as to be at the same time the lining cells of those spaces. In the loose subcutaneous and submucous tissue there are all gradations

between interfascicular spaces or sinuses lined by a complete endothelium, and consequently representing a lymphatic capillary, and small irregular lacunæ lined only on one side by a branched connective-tissue cell.

4. As has been mentioned in a former chapter, the wall of capillary blood-vessels does not present any obstacle to the passage of formed particles (blood-corpuscles or pigment). This takes place through the interstitial substance (stigmata) acting as cement between the endothelial plates constituting the wall of the capillary. It has also been mentioned that the connective-tissue corpuscles of the surrounding tissue are connected with the wall of the capillaries : this connection consists in a continuity of the interstitial albuminous cement-substance of the endothelial wall with the same albuminous substance in which is embedded, as above stated, the lymph canalicular system or the connective-tissue corpuscles respectively. Thus fluid or formed matter escaping from the blood-vessel (through the interstitial substance) passes into the lymph-canalicular system (Arnold, Foà), lined by the connective-tissue corpuscles, and from here freely into the capillary lymphatics. And this passage of plasma from the capillary blood-vessels through the lymph-rootlets into the lymphatic capillaries represents the normal stream that uniformly percolates the tissues. This stream is caused, in the first place, by the difference of pressure that exists in the capillary blood-vessels and in the lymphatics, in the former being positive, in the latter negative; and in the second place, by the peculiar distribution of the blood and lymph-capillaries, the former holding, as it were, the centre of a definite area, while the latter belong to its periphery (v. Recklinghausen), and hence the tendency of the plasma to uniformly percolate the tissue intervening between the two systems of vessels. The passage of formed matter, such as colourless and coloured blood-corpuscles or pigment matter, from the blood-vessels, into the lymph-canalicular system, and hence into the lymphatics, is well illustrated in inflammation (Cohnheim, Hering, Arnold, Klein, and others), and in the experiments of Klein, Arnold, Küttner, and others, where pigment matter (Berlin blue or indigo sulphate of sodium) introduced into the organism of the living guinea-pig, rabbit, or frog can be easily traced through the lymph-canalicular system into the lymphatics.

5. The lymphatics of the serous membranes.

The endothelium covering the free surface of the serous membranes has been minutely described in all its details in Chapter III.; and likewise the connective-tissue matrix and its cells in Chapter IV. Bizzozero showed in the serous membranes of man a thick membrana propria, 'limiting membrane,' separating the endothelium from the ground substance. Networks of blood capillaries occur in all parts of the serous membranes, especially in those parts that contain patches, nodules, or cords of adenoid tissue or fat tissue. The sympathetic nerves mentioned in a former chapter split up into minute

branches which are connected into a plexus ; from this come off fine non-medullated fibres which are characterised by their relatively long course; according to Cyon they terminate in free endings in the tissue, but according to Klein and Gempt they are connected into a network; most of the nerves belong however to the blood-vessels. The nerve branches contain occasionally small groups of ganglion cells.

The lymphatics are numerous in all serous membranes; the tubular trunks possess valves, and some of the larger vessels also a layer of circular muscle cells : they form plexuses chiefly in the neighbourhood and around the larger bood-vessels ; some of these latter are occasionally ensheathed in a continuous perivascular lymphatic tube (omentum of rabbit, mesentery of frog) or in an intercommunicating system of lymph-sinuses lined with endothelium (mesentery of toad). The parts of the serous membrane situated between the large vascular trunks contain the lymphatic capillaries which are everywhere connected with the lymph-canalicular system, as described above.

The lymphatics of the central tendon of the diaphragm and the intercostal pleura possess special characters.

a) The central tendon of the diaphragm of rodents. The matrix of this is a double layer of tendon bundles ; one layer, nearest to the peritoneum, is composed of bundles more or less radiating from the centre towards the periphery, while the other, nearest to the pleura, contains more or less circular bundles, crossing the former under a right angle. Between groups of these bundles are lymphatic channels (Ludwig and Schweigger-Seidel); they are lymphatic capillaries, the wall of which is a single layer of endothelial plates with sinuous outlines : they are the straight lymphatic capillaries (Klein). Those of them that belong to the radiating layer of tendon bundles possess naturally a radiating direction, and represent the superficial, while those of the circular layer are arranged circularly, crossing the former under a right angle and represent the deep straight lymph-capillaries. But the vessels of both layers form an intercommunicating and therefore single system, being connected with each other by small openings, chiefly at the point of crossing.

This matrix of tendon bundles is covered on the pleural surface with a delicate but dense connective-tissue membrane, the pleura, which on its free surface is covered with a layer of ordinary flattened endothelial plates. There is always a more or less continuous subendothelial membrana propria, a single layer of flattened cell. These are either unbranched, and touch each other in straight lines like an endothelium, or they are branched and form a network. The peritoneal surface of the tendon bundles is also covered with a delicate connective-tissue membrane, the peritoneum ; but this membrane is complete only where it stretches over the tendon bundles themselves, while that portion of it that covers the radiating or superficial straight lymph-capillaries is a

fenestrated membrane (Ludwig and Schweigger-Seidel), viz. a plexus of anastomosing trabeculæ with smaller or larger oval or spherical meshes. The endothelium covering this fenestrated part, that is above the straight lymph-channels, is composed of small more or less germinating endothelial cells, while that above the tendon bundles consists of the ordinary large endothelial plates, as mentioned in Chapter III.

Between the pleural serosa and the circular layer of tendon bundles lies a dense plexus of lymphatic vessels with valves, their wall is a single layer of elongated endothelial cells (see fig. XII. Plate VI.). In connection with this plexus, which represents the 'plexus of pleural lymphatics of the central tendon,' are (*a*) capillaries that have their roots in the lymph-canalicular system of the pleural serosa itself, and (*b*) the circular or deep straight lymphatics, which, as we mentioned above, form, with the radiating or superficial straight lymphatics, an intercommunicating system.

The plexus of pleural lymphatics is arranged as an anterior and posterior system (Klein); the former is symmetrically distributed over the two anterior quadrants, and the same is the case with the latter, viz. one for each of the two posterior quadrants. The pleural lymphatics of both sides of the anterior system, as well as those of both sides of the posterior system, communicate with each other by intermediary branches.

The efferent trunks of the anterior system run near the margin of the central tendon towards the xyphoid cartilage, where the branches of the two sides anastomose with one another and, freely intercommunicating, ascend on the posterior surface of the sternum towards the jugular incision of the manubrium sterni, and finally enter a lymphatic gland, one for each side. The efferent trunks of the posterior system are fewer and larger, and finally collect into one or two short large vessels for each side, which freely empty themselves into the thoracic duct.

Bizzozero and Salvioli have shown that the arrangement of the lymphatics in the muscular portion (pars costalis) of the diaphragm is similar to that of the central tendon.

In connection with the radiating straight lymphatic capillaries in rodents there are smaller and larger sinuous or saccular lymphatic capillaries (Klein), they are chiefly near the middle line of both the anterior and posterior quadrants. Bizzozero and Salvioli showed them to exist also in the human diaphragm, especially in the 'zona peritendinea.'

According to Rajewsky the arrangement of the lymphatic system of the central tendon in man is the same as in rodents.

The membrana propria or limiting membrane described by Bizzozero and Salvioli of the peritoneal surface of the human diaphragm is perforated, above the radiating straight lymphatics, and also above the aforesaid lymph-sinuses, by minute holes.

The superficial or radiating straight lymphatic capillaries are in open communication with the peritoneal cavity through stomata (Oedmanson, v. Recklinghausen) ; the meshes of the fenestrated portion (Ludwig and Schweigger-Seidel) of the peritoneum mentioned above as bridging over those capillaries, and in man the holes of the subendothelial limiting membrane (Bizzozero and Salvioli), together with discontinuities in the endothelium of the surface and of the straight lymphatic capillaries, contribute to form those stomata. I have shown that the endothelial cells surrounding or rather lining them (stomata vera) are germinating cells.

The deep or circular straight lymphatic capillaries, which, as has been mentioned above, are in open communication with the superficial or radiating ones, empty themselves into the pleural lymphatics (Ludwig and Schweigger-Seidel), both the anterior and posterior system, so that they are able to discharge their contents in two directions at the same time (Klein), viz. towards the lymphatics constituting the anterior as well as towards those constituting the posterior system.

The current passing through the lymphatics of the diaphragm is then : from the free peritoneal surface of the diaphragm, that is the peritoneal cavity, through the stomata vera into the superficial or radiating straight lymphatic capillaries, hence into the deep or circular straight ones : hence the current may pass in two directions, viz. (*a*) into the plexus of lymphatic vessels forming the anterior system, and (*b*) into that of the posterior system ; through the efferent trunks of the former the current passes a long and circuitous way (along the sternum) into a lymphatic gland, whereas through the efferent trunks of the latter it reaches in a short and unimpeded manner directly the thoracic duct. Hence the pleural lymphatics of the posterior system are easier filled and easier emptied than those of the anterior system (Ludwig and Schweigger-Seidel, Klein).

The respiratory action of the diaphragm is the principal moving cause of the circulation in the lymphatics of the latter (Ludwig and Schweigger-Seidel) thus : during inspiration the straight lymphatics (both the superficial and deep ones) become distended owing to the descent of the central tendon and consequently the greater separation of its bundles from one another, while at the same time the pleural lymphatics become compressed ; in this distended state of the superficial straight lymphatic capillaries the above stomata necessarily are wide open, and there exists therefore a tendency on the part of the straight lymphatic capillaries to absorb plasma, cells, or other formed matter that happens to be present on the peritoneal surface of the diaphragm. But at the same time, owing to the compression of the pleural lymphatics, these will discharge their contents into the efferent trunks. During expiration the straight lymphatics become compressed owing to the tendon bundles becoming again closer, the pleural lymphatics being

at the same time distended, for during the ascent of the central tendon the area of its pleural surface becomes enlarged. Hence the effect of the movement of the diaphragm on its lymphatics in inspiration is the reverse from that in expiration, since during the latter the straight lymphatic capillaries become compressed and therefore discharge their contents; these are readily received by the pleural lymphatics, distended during this period.

The action of the respiratory movements of the diaphragm is, therefore, that of a pump (Ludwig and Schweigger-Seidel), but of one with two cylinders (Klein), owing to the straight lymphatics emptying themselves in two directions, viz. into the anterior and posterior systems, as mentioned above.

The direct absorption of formed matter, milk, blood, &c., placed on the peritoneal surface of the central tendon of rabbit by the lymphatics of this organ has been first shown by v. Recklinghausen, and Rajewski proved the same also for the human diaphragm. Ludwig and Schweigger-Seidel then proved this to be dependent chiefly on the respiratory movements; Klein demonstrated the lymphatics in their different relations to one another by injecting Berlin blue into the peritoneal cavity of the living rabbit and examining the diaphragm after several hours.

b) In the intercostal pleura the lymphatics are arranged as a plexus of superficial and one of deep lymphatics (Dybkovski); the vessels of the former correspond to straight lymphatic capillaries which open freely by stomata vera on the free surface, that is into the pleural cavity; on the other hand they empty themselves into the plexus of deep lymphatics, which possess valves and the efferent trunks of which pass through the subserous tissue outwards.

As in the zona peritendinea of the diaphragm, so also in the pleura costalis and intercostalis of man, Bizzozero and Salvioli showed the existence of small holes in the subendothelial membrana propria or limitans; these holes, together with the holes between the endothelial cells of the surface, form the stomata. The relation of the pulmonary pleura with the pleural cavity will be considered in the chapter on the Lung.

Dybkovski proved the passage of pigment matter from the pleural cavity through the stomata into the lymphatic system of the intercostal pleura, and likewise that, as in the case of the diaphragm, the respiratory movement has a direct influence on the absorption, viz. acting as a pump.

6. The synovial membrane possesses, according to Tillmanns, a rich network of lymphatics, of which there is a plexus immediately underneath the endothelium of the surface; the deeper vessels mostly accompany the large blood-vessels. In the tendinous parts Tillmanns finds a network of lymphatic clefts situated chiefly between the bundles of connective tissue, similar as in tendinous tissue of other localities.

In certain places of the knee-joint of rabbit Nicoladoni described numerous nerve branches, from which fine nerve fibres come off; some of them terminate in a network, others belong to

blood-vessels, and a third group enter Pacinian corpuscles. Krause observed in the synovial membranes of the joints of the human fingers medullated nerve fibres terminating in peculiar tactile corpuscles, 'articulation-nerve corpuscles.'

7. Besides the true stomata mentioned above as occurring on the peritoneum of the diaphragm and on the intercostal pleura, there are also true stomata in other membranes, as in the mesentery, omentum, pleura mediastini; they are mostly marked by two or three or more germinating cells surrounding them. These cells, when ripe, become detached and may be at once absorbed as lymph-corpuscles (Klein). The best stomata are seen on the mesogastrium and mesentery of frog and the septum cisternæ lymphaticæ magnæ of the same animal. In the latter membrane the stomata are short canals by which a direct communication is established between the peritoneal cavity and the large cistern behind; in the former membranes the stomata open into a superficial lymphatic. In female individuals, especially during the spawning season, both on the mesogastrium and mesentery (Klein), as well as on the peritoneal surface of the septum cist. lymph. magn. (Dogiel and Schweigger-Seidel, Klein), the endothelial cells lining the stomata are ciliated and often germinate (Klein). (See also Chapter III., Plate V.)

8. The epithelium lining mucous membranes and secreting glands and the endothelium covering serous and synovial membranes or lining blood-vessels and lymphatics bear a definite relation to the lymph-canalicular system of the tissue underneath or outside respectively. This relation may be shortly described by saying that the hyalin albuminous interstitial or cement-substance, i.e. the substance separating the individual epithelial or endothelial cells, is directly continuous with the albuminous interstitial substance in which the lymph-canalicular system is embedded (see above), so that fluid and formed matter can pass freely from the intra-epithelial cement-substance into the lymph-canalicular system underneath, or *vice versa*. And also the connective-tissue corpuscles contained in the lymph-canalicular system are continuous with branched nucleated cells which extend into the epithelium, and whose processes are lost in the cement-substance of the epithelium. These intra-epithelial connective-tissue corpuscles (pigmented or unpigmented) have been mentioned before on more than one occasion. The absorption through the epithelium and endothelium is therefore carried out by means of the interstitial cement-substance, hence the current passes into the subjacent lymph-canalicular system, and finally into the lymphatic vessels. The absorption of fluid and formed matter is carried out in the same manner in every epithelium (including that of the villi of small intestine, bronchi, and alveoli of lung, glands, &c.) and endothelium, viz. through the interstitial substance and not through the substance of the epithelial or endothelial cells themselves; this mode of absorption may be described as taking place through pseudo-stomata, as different from that through true stomata (stomata vera).

By the experiments of Thoma, Arnold, and others it has been proved that indigo sulphate of sodium injected into the circulating system of frog is eliminated from the blood-vessels through the paths just mentioned, only, of course, in a reversed order, viz. from the capillary blood-vessels (through the stigmata) into the lymph-canalicular system, hence into the cement-substance of epithelium or endothelium.

9. The lymph-channels of connective tissue have been described above, and it remains here to mention a few special points :

a) The lymph-clefts between groups of bundles in tendons, fasciæ and ligaments, mentioned above, are not the ultimate rootlets of the lymphatic system in these organs, for injection-matter may pass from the lymph-clefts into the albuminous cement-substance between the individual bundles forming these groups (Key and Retzius, Herzog).

b) Genersich, Ludwig, and Schweigger-Seidel demonstrated on the inner surface of fasciæ and aponeuroses a plexus of lymphatic capillaries, the greater number of which run parallel with the connective-tissue bundles; they are connected by a few short cross-branches. On the outer surface, however, the lymphatic capillaries form a plexus with polygonal meshes. From these proceed the efferent trunks possessed of valves. Genersich also showed that the first-named capillaries, viz. the straight vessels on the inner surface, bear the same relation to the lymphatics on the outer surface, as the straight lymphatic capillaries of the central tendon to the plexus of pleural lymphatics of this same organ.

Injection matter, introduced into the lymph-clefts situated between striped muscle fibres, passes into the straight lymphatics of the inner surface of the corresponding fascia or aponeurosis, and from here through oblique vessels into the plexus of lymphatics of the outer surface (Genersich, Ludwig, and Schweigger-Seidel).

The lymph-clefts between the individual muscle fibres are just like those between the nerve fibres, spaces, whose boundary is formed on one side by the muscle fibre or nerve fibre respectively, and on the other by the connective tissue described and figured in former chapters as endomysium or endoneurium respectively; they pass into lymphatic capillaries situated in the perimysium.

In the ligamentum nuchæ of ruminants Schwalbe proved the existence of lymphatic vessels, running longitudinally and connected into a network by fine transverse branches. They are situated in the connective tissue separating the bundles of elastic fibres (see the chapter on elastic tissue). In connection with them are lymph-channels and clefts of the connective-tissue between the elastic fibres.

10. The lymphatics of cartilage.

The perichondrium of all cartilages possesses a plexus of lymphatic vessels. The lacunæ in which the cartilage cells of hyaline and elastic cartilage lie are connected with

one another by fine canals, and also with the lacunæ of the cells of the perichondrium; so that also in these cartilages we meet with a lymph-canalicular system similar to that of the cornea. This lymph-canalicular system is in direct communication with the lymphatic vessels of the perichondrium. Budge injected it in the articular cartilage (of calf) from the lymphatic vessels of the periosteum, and Nykamp saw it indicated in hyaline cartilage of rabbit by granules of indigo carmine, this substance having been injected into the peritoneal cavity several hours previously. Arnold saw the indigo sulphate of sodium, which had been previously injected into the circulating blood, deposited in fine lines passing in a radiating manner through the capsules of the cartilage cells.

Consequently the canaliculi by which neighbouring lacunæ anastomose and which permeate the hyaline matrix, increase greatly in numbers as they pass through the capsule immediately surrounding the lacuna of the cartilage cell.

11. The lymphatics of bone.

The periosteum possesses a network of lymphatic vessels which are in connection with the lymph-clefts (lymph-canalicular system) of the fibrous-connective tissue of that organ. According to Budge the lymphatics of the periosteum of the metatarsus of calf are arranged in several layers, and in most instances accompany the blood-vessels. Schwalbe found in the human femur and tibia lymphatic vessels only in the superficial layers of the periosteum, but saw numerous clefts, especially between the inner and outer layer, anastomosing with those vessels.

The periosteal lymphatics are in communication with the lymphatics of the Haversian canals (Budge, Schwalbe); these are either perivascular lymphatics totally invaginating the blood-vessel of the Haversian canal (Rauber, Budge, Schwalbe) or, as in the large Haversian canals, they are separate lymphatics accompanying the blood-vessels. In both cases the wall of the lymphatics is represented by a single layer of endothelium. The lymphatics of the Haversian canals are in open connection with the lacunæ and canaliculi of the bone corpuscles (Budge), and these represent therefore a similar lymph-canalicular system as that of the cornea (see also chapter on Bone). The marrow also contains lymphatic vessels, which generally accompany or invaginate the veins and capillaries (Budge).

Schwalbe demonstrated a continuous endothelium on the surface of the yellow marrow and on that of the cord of vessels lying in the canalis nutritius.

Arnold recognised the course of the lymphatic system, as just described, by a deposit of indigo sulphate of sodium taking place in the lymphatic system of bone of frog, that substance having been previously (24 to 48 hours) injected into the circulating system.

12. The lymphatics of the nervous system have been described and figured in previous chapters in connection with these tissues.

13. The lymphatics of the alimentary, respiratory, urinary and genital organs, those of the skin and sense organs, will be described in connection with these various tissues.

14. Development of lymphatic vessels. The lymphatic vessels develop, both under normal and pathological conditions, after the same plan as blood-vessels, viz. by a process of vacuolation of branched cells (Klein); from the wall of a lymphatic vessel solid protoplasmic filamentous processes grow out, and these, gradually becoming hollowed out, form lateral branches. In some cases we find a series of vacuolated cells, vesicles, which having been brought into contact are gradually fused so as to form one continuous vessel. In other instances a single cell grows into a nucleated cylindrical, single or branched band or filament, which by vacuolation becomes converted into a vessel, in the same manner as described of blood-vessels in Chapter XIX. The differentiation of the protoplasmic wall of the young lymphatic into endothelial cells occurs at a later stage.

PLATE XXX.

Fig. XIII. Copied from Klein's 'Anatomy of the Lymphatic System,' I.

From the central tendon of rabbit after staining with nitrate of silver, showing the connection of a lymphatic capillary, indicated on the left and upper part of the figure by its endothelial wall, with the lymph-canalicular system of the pleural serosa; the lacunæ are represented as more or less branched clear spaces in the dark ground-substance. In some lacunæ a nucleus is seen belonging to the connective-tissue corpuscle.

t. Transition of the endothelial cells of the lymphatic capillary into the connective-tissue corpuscles contained in the lymph-canalicular system. Magnifying power about 300.

Fig. XIV. From a preparation of the gall-bladder of guinea-pig.

l. Lymphatic vessels underneath the serous covering of the gall-bladder, forming a plexus. The wall of the lymphatics is marked blue, owing to a precipitate on the inner side of their wall of Berlin blue injected by the method of 'puncture.'

v. Semilunar valves seen in profile and indicated by an accumulation of injection matter.

b. Ramifications of blood-vessels, arteries, capillaries, and veins, belonging to the mucous membrane of the gall-bladder, and accidentally injected at the same time.

Magnifying power about 25.

Fig. XV. Copied from Klein's 'Anatomy of the Lymphatic System,' I.

Part of the peritoneal surface of a silver-stained preparation of the central tendon of diaphragm of rabbit.

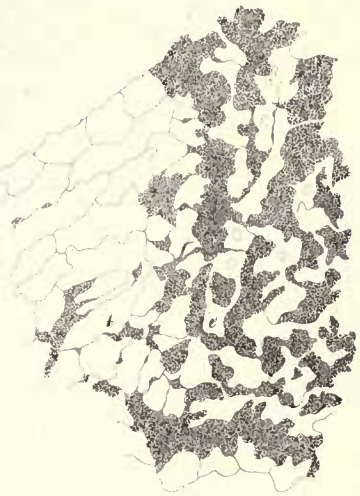

XIII.

XIV.

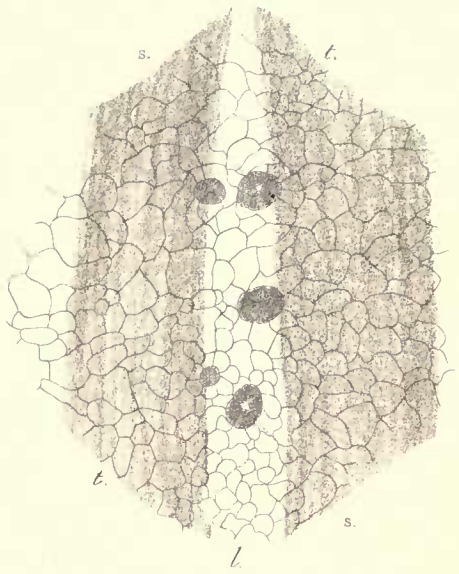

XV

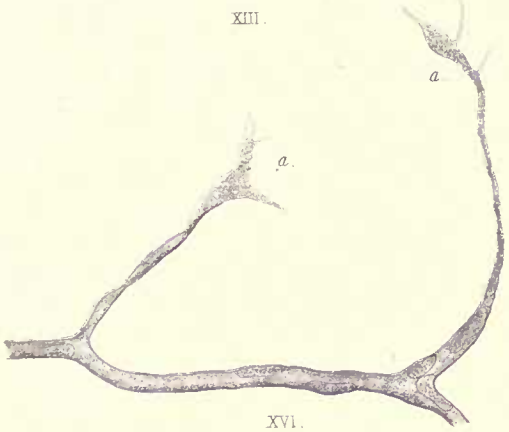

XVI.

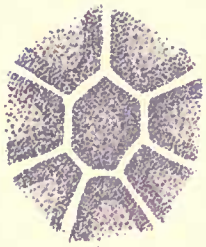

XVII.

XVIII.

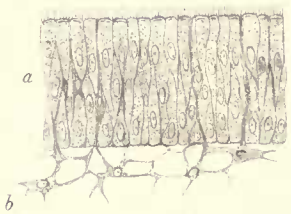

XIX.

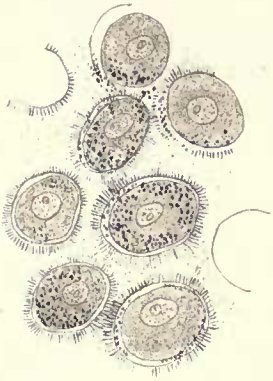

XX.

XXI.

XXII

REESE LIBRARY
OF THE
UNIVERSITY
OF
CALIFORNIA.

l. Superficial straight lymphatic capillary, contained between the radiating tendon bundles.

s. Stomata surrounded by germinating endothelium and leading from the free surface into the straight lymphatic; some of the stomata are open, others collapsed.

t. Part that corresponds to tendon bundles; the endothelial cells covering this part are larger than those over the lymphatic capillary (see Chapter III.).

Figs. XVI. and XVIII. represent developing lymphatic vessels of the tadpole's tail; magnif. power about 350. These vessels develop from branched corpuscles in the same manner as the blood-capillaries described and figured in a previous chapter, viz. by a process of vacuolation. The minute spikes and filaments of the wall of the young lymphatics are very numerous and quite characteristic. In some parts of the tadpole's tail it is not easy to distinguish a developing blood-vessel from a young lymphatic, but as a rule this distinction is facilitated by noticing that the wall of the former is coarser than that of the latter, that it possesses few of the above processes, and that it can be traced to a vessel that contains blood-corpuscles.

a. Parts that are still composed of solid protoplasm.

Fig. XVII. From a horizontal section through the superficial part of a thymus of calf, viewed under a lens; showing in the centre a follicle of polygonal shape and similarly shaped follicles around it. This polygonal shape does not, however, indicate that the follicles are polyhedral, but only that the part of the follicle next to the capsule is so shaped. The clear lines between the follicles indicate the interstitial connective tissue separating them. The distinction into a transparent medullary and deeper stained cortical portion is well shown.

Fig. XIX. Copied from Klein's 'Anatomy of the Lymphatic System,' II.

a. The ciliated columnar epithelium lining a bronchus.

b. The branched connective-tissue corpuscles of the mucosa; they are connected with similar branched corpuscles in the epithelium, whose processes reach up to the free surface and are embedded and lost in the interstitial cement-substance—the pseudo-stomata.

The connective-tissue corpuscles are contained in the lymph-canalicular system (see a previous page), and it may be therefore said that the interstitial substance of the epithelium acts as rootlets of the lymph-canalicular system of the mucosa.

Fig. XX. Copied from Arnold, 'Virchow's Archiv,' vol. lxxiii. Showing the excretion of indigo sulphate of sodium in fine lines passing radially through the capsule of the cartilage cells. When seen from above these lines appear of course as fine dots.

Fig. XXI. Copied from Klein's 'Anatomy of the Lymphatic System,' I. Showing the lymphatics of part of the central tendon of rabbit injected with Berlin blue, that had

been introduced into the peritoneal cavity of the living animal several hours previously. Magn. power about 90.

a. Pleural lymphatics, i.e. vessels that belong to the pleural section of the diaphragm; the vessels are possessed of valves and corresponding saccular dilatations.

b. Superficial straight lymphatic capillaries situated between the radiating tendon bundles; they are connected with the deep straight lymphatics which cross them, and, as has been mentioned on a former page, are situated between the circular tendon bundles; the deep straight lymphatics lead into the above pleural vessels.

Fig. XXII. Copied from Nykamp, 'Archiv f. mikrosk. Anat.' XIV. Showing the excretion of granules of indigo carmine into the lacunæ and canaliculi of the cartilage cells, *c*, as well as into those of the periosteum, *p*.

CHAPTER XXIII.

TEETH.

THE hard parts of a human tooth are: (*a*) the enamel, substantia adamantina; (*b*) the dentin or ivory; (*c*) the cement, or substantia osteoidea. The soft parts are: (1) the dental pulp; (2) the periosteum; and (3) the gums.

a) The *enamel* covers the crown of the tooth. It consists of closely placed solid thin prisms, enamel prisms, extending, in a direction vertical to the surface, from this latter to the subjacent dentin: they appear hexagonal when viewed in transverse section. The prisms are arranged in bundles. These cross each other, so that on a longitudinal section of tooth alternate layers of longitudinally and transversely cut prisms are visible. Hereby the appearance of alternate light and dark stripes is produced. Besides this inequality in appearance, there are the 'brown parallel stripes of Retzius,' consisting of horizontal curved lines running more or less parallel with one another, often very closely placed. Their significance is not definitely ascertained, inasmuch as deposit of pigment (Hertz) or successive formation of enamel (Kölliker) is given as its cause. Each enamel prism when isolated by dilute HCl shows regular transverse markings and varicosities, owing probably to a successive formation of its parts (Hannover, Hertz). By continued maceration in HCl they disintegrate into short cubical pieces (Waldeyer).

The enamel consists chiefly of lime salts, phosphate and carbonate of lime, a trace of fluoride of calcium, and very little phosphate of magnesia; a small percentage (1–3·5) of organic matter is also contained in it.

The enamel prisms, although closely placed side by side, are nevertheless separated from one another by a very thin layer of hyaline interstitial substance. In the parts of the enamel bordering on the dentin are often found shorter or longer canals and lacunæ between layers of prisms, and leading into the *interglobular spaces* of Czermak, situated on the surface of the dentin. A delicate cuticle (Kölliker, persistent capsule of Nasmyth) covers the outer surface of the enamel of young teeth: it is composed of a layer of non-nucleated horny scales.

b) The *dentin* or ivory (osteodentin, Tomes) consists of the following parts: (*α*) a homogeneous hard *ground substance*; this contains, embedded in a dense reticular matrix of organic substance, lime salts similar to the ground substance of bone; (*β*) long fine canals, *dentinal canals*, passing through the whole thickness of the dentin in a spiral

manner and in a direction vertical to the surface of this substance. These canals commence at the pulp cavity, and become gradually finer as they approach the enamel. Numerous fine lateral branches unite them amongst each other. The wall of each canal is formed by an elastic membrane, *dentinal sheath* of Neumann; this withstands acids and alcalies. (γ) The cavity of each dentinal canal contains the *dentinal fibre* of Tomes: this is a solid branched fibre, very elastic, and of a homogeneous structure. These fibres are regarded as the processes of nucleated cells lining the inner surface of the dentin or covering the outer surface of the pulp-tissue, generally called the layer of *odontoblasts* (Waldeyer).

The dentinal canals pass, on the outer surface of the dentin, into the *interglobular spaces* of Czermak, or the *granular layer* of Purkinje. They are larger or smaller branched spaces intercommunicating with one another, and into them terminate the dentinal canals. Where the dentin is covered with enamel, viz. at the crown, the interglobular spaces extend as blind canals a certain short distance between bundles of enamel prisms, as mentioned above; on the neck and fang, viz. where the dentin is in contact with the cement, the interglobular spaces are in direct communication with the bone lacunæ and their canaliculi. Just as these latter contain nucleated branched cells, so do also the interglobular spaces include nucleated branched protoplasmic corpuscles: these are especially distinct in young teeth (Waldeyer). The dentinal fibres are directly continuous with these cells, so that an anatomical connection is established between the odontoblasts and the cells of the interglobular spaces. According to Kölliker, Tomes, Wenzel, and others, the dentinal fibres penetrate also into the enamel. The *interglobular substance* of Czermak is imperfectly calcified dentin; it is present in distinct and separate layers, more or less parallel to the surface of the tooth: these layers are the incremental lines of Salter. Owing to the curved indentations of the interglobular substance, the adjoining dentin matrix assumes the form of globular masses, dentin spheroids. 'The lines of Schreger' are parallel to the surface, and are the optical effect of simultaneous curvatures of the dentinal fibres.

c) The *cement* is osseous substance of the nature of ordinary osseous tissue, viz. a more or less lamellated bone matrix containing the bone corpuscles: lacunæ and canaliculi, and in these the nucleated bone cells (see Chapter IX.). The bone corpuscles are here exceptionally large, and their canaliculi very numerous. The cement is covered by the alveolar periost, to which it stands in the same relation as other bone substance to the osteogenetic layer of the periosteum (see Chapter IX.). The cement is generally thickest near the apex of the root. In very thick parts of cement Haversian canals with blood-vessels may be occasionally met with (Salter). Sharpey's fibres exist also in the cement; they are well shown in cement of tooth of dog (Waldeyer).

The tissue of the periosteum surrounding the cement differs in no respect from the osteogenetic layer of the periosteum, such as that covering the outer surface of the alveolus of the jaw. The mucous membrane of the gums will be described in connection with the mucous membrane of the oral cavity; but its tendinous nature, its firm connection with the fibrous layer of the periosteum, the regular and beautiful papillæ, and the fine prickle cells of the middle layers of the stratified epithelium, may be here mentioned.

The *pulp* is a continuation of the alveolar periosteum. It consists of a great number of cells, these are chiefly branched cells, each with an oval or spherical nucleus; the cell substance surrounding the nucleus is very small in amount, and is drawn out in two or three homogeneous long processes which at their extremities are richly branched; by their anastomosis with one another they form a dense reticulum of homogeneous fine fibres, the matrix of the pulp tissue. A few spherical lymphoid corpuscles are to be met with in it.

At the periphery the cells of the dental pulp form two distinct strata of different cells. The outer stratum, that next to the inner surface of the dentin, is a layer of beautiful columnar cells; their substance is a dense reticulum; each cell contains an oval nucleus in the inner section. This layer is the layer of odontoblasts (Waldeyer, Boll). The cells are possessed of fine processes directed towards the pulp and connected with the cells of this latter. According to Waldeyer, Boll and others, the odontoblasts send processes into the dentinal canals as the dentinal fibres, and are also possessed of lateral processes by which they (odontoblasts) are connected with one another.

The deeper stratum is composed of spindle-shaped or pyramidal cells wedging themselves in between the odontoblasts; they are identical with the branched cells of the pulp, mentioned above, of which they are merely a dense superficial row. They are accordingly in connection with the reticulum of the pulp matrix, and also amongst each other. Each of them sends two or more filamentous processes towards the dentin, whose canals they enter as the dentinal fibres.

[However great the authorities who maintain that the cells of the outer stratum, above referred to as the odontoblasts proper, send processes into the dentinal canals as the dentinal fibres, I must question the accuracy of this assertion, for I cannot find convincing evidence of those odontoblasts doing more than producing the dentin matrix, as will be described below. The dentinal fibres appear to me derived solely from the deep layer of cells which, as has been mentioned just now, are wedged in between the former.—E. K.]

Boll first pointed out the great number of non-medullated nerves in the superficial part of the pulp-tissue. The fibrils ascend from here between the odontoblast; it is probable, although not proved, that they ascend into the dentinal canals.

The capillaries form a dense network in the periphery of the pulp tissue. The blood-vessels are ensheathed in endothelial membranes, which form the wall of lymphatics.

Development of Tooth.

The first rudiment of the tooth appears at a time when the mucous membrane covering the lower jaw is vascular embryonal, or gelatinous tissue, i.e. a network of branched embryonal cells; it is a solid prolongation of the stratified epithelium of the surface into the depth of the mucous membrane; this prolongation, somewhat thickened at its lower end, is the *primary enamel organ.* The enamel organ at its deep end becomes invaginated by a papillary mass of vascular gelatinous tissue, the *embryonal tooth papilla,* which is entirely derived from the mucous membrane. The primary enamel organ is thus gradually converted into the *secondary enamel organ,* or the *enamel cap,* a caplike covering of the embryonal tooth papilla.

The part of the gelatinous mucous membrane that immediately surrounds the rudiment of the tooth (the secondary enamel organ and the tooth papilla) represents the tooth sack. This is a vascular membrane consisting at first of a network of embryonal cells, but soon very numerous fine fibrils arranged in bundles appear in it. The bundles are grouped into lamellæ, and these, by anastomosis of neighbouring trabeculæ, form a sort of meshwork with one another. At this period the tissue of the tooth sack is well defined from the mucosa covering it.

The connection between the enamel organ and the surface epithelium, owing to the growth of the tissue of the mucous membrane over the former, is severed at a much later stage.

The tissue of the papilla, as mentioned above, is very vascular, and is composed of a network of nucleated cells; it gives origin to the pulp, and by its odontoblasts produces the dentin. The odontoblasts make their appearance very early as an epithelial-like peripheral stratum of large more or less columnar cells. The odontoblasts elongate at their outer or distal extremity, and this is directly converted into the matrix of dentin (Waldeyer, Boll, and others).

Kölliker, Hertz, and others regard the dentin matrix as an excretion of the odontoblasts.

Previous to its calcification it shows, just like the substance of the odontoblasts, the fine network of its matrix.

The outer extremity of the odontoblasts continues to elongate, and the increment is again changed into dentin; and this process continues as long as the dentin increases in thickness. The most recently formed dentin remains for a certain time uncalcified, and is easily distinguished as such by a well-marked boundary line from the earlier layers of dentin, viz. those that have already become calcified. As mentioned above, I cannot

convince myself of the correctness of the now (since Waldeyer) generally accepted theory according to which the peripheral part of the cell-substance of the odontoblasts is transformed into the matrix of the dentin, while the central part persists as the dentinal fibre; from my observations I am on the contrary led to assume that the superficial layer of cells, or odontoblasts proper, yields only the dentinal matrix, while the dentinal fibres are derived from the processes of the cells of the deeper layer, that is, of the cells wedged in between the odontoblasts just referred to.

Thus, while the continued growth of the outer extremity of the odontoblasts yields new layers of dentinal matrix, that of the processes of the deeper layer of cells causes the elongation of the dentinal fibres, and enables these to keep pace with the growth of the matrix.

Owing to the growth of the tooth sack over the enamel cap, the connection of the latter with the surface epithelium becomes gradually severed. The enamel cap being a duplicature of stratified epithelium, its innermost cells, viz. those next to the tooth papillæ, as well as the outermost cells, viz. those next to the tooth sack, are columnar cells, corresponding to the deepest cells of the surface epithelium. Next to the inner and outer cells are polyhedral cells, and towards the middle of the enamel cap we find more or less flattened epithelial cells. The tooth sack, where it is in contact with the upper greater half of the enamel cap, extends as very regular small papillæ into the outer stratum of the epithelium of the latter.

The enamel cap is limited both on its inner and outer surface by a membrana propria (Huxley, Kölliker).

The next change that takes place in this enamel cap is a separation into an *inner* and *outer membrane*, owing to the transformation of the aforesaid middle strata of flattened epithelial cells into a transparent tissue, *middle membrane*; the matrix of this is a honeycomb of membranous structures containing oval flattened nuclei, its meshes are relatively larger—much larger than those of the gelatinous tissue of the tooth papilla—and contain a hyaline interstitial substance. No vessels are present in this middle membrane.

This change in the middle membrane is due to an accumulation of fluid in the interstitial substance between the epithelial cells; hereby these latter are gradually separated from one another and compressed into membranous structures, which are connected into a honeycomb. It is, therefore, not quite correct to compare this middle membrane of honeycombed tissue with the gelatinous connective tissue of the tooth sack or the tooth papilla. The *inner membrane* is composed (*a*) of a layer of beautiful columnar epithelial cells in contact with the dentin, or, if this is not formed yet, with the tooth

papilla. These cells are called the *enamel cells* (inner epithelium of Kölliker). Each is a hexagonal long prism; their nucleus is situated in the inner part of the cell substance: this is a dense reticulum. (*b*) Outside the layer of enamel cells are one, two, or three layers of small polyhedral cells, each with a spherical nucleus: they form the stratum intermedium of Hannover. The *outer membrane* (outer epithelium of Kölliker) of the enamel cap is composed of several layers of epithelial cells; but as development proceeds, the middle membrane increasing in thickness at the expense of the stratum intermedium of Hannover as well as the cells of the outer membrane, the layers of this latter become greatly reduced. Still later, the middle membrane having disappeared, the inner and outer membrane are again brought into contact.

The enamel is formed by the enamel cells of the inner membrane, in the same manner as the dentin from the odontoblasts, viz. the distal extremity of the cells, that is, the one next the dentin elongates, and this increment is directly converted into enamel (Waldeyer, Tomes, Wenzel, and others). Kölliker, Kollman, and others, on the other hand, regard the enamel as an excretion of the enamel cells. The enamel cells being prismatic, the enamel matrix is accordingly also composed of prismatic elements, the above enamel prisms. The increment of the enamel cells and the conversion into enamel probably occur successively, and hence the aforesaid transverse markings of the enamel prisms receive their ready explanation. The enamel cells, like all epithelial cells, being separated from one another by a homogeneous interstitial substance, it is clear that the remains of this substance must occur also between the enamel prisms; in the enamel of a developing tooth this interstitial substance is larger in amount than in the fully formed organ. It is improbable that nucleated protoplasmic masses are contained in the interstitial substance of the enamel of a fully formed tooth, as is maintained quite recently by Bödecker.

In the parts adjoining those that are breaking down through caries, the spaces, containing this interstitial substance, between the enamel prisms increase, and become filled with granular *debris*.

A similar relation exists also in caries of dentin, for here also the dentinal canals are enlarged, and their contents, dentinal fibres and sheaths, thickened.

When the most recently formed layer of enamel, the membrane of Huxley (membrana preformativa of Raschkow), is viewed from the surface, it appears of course to consist of closely placed hexagonal sections, these being the enamel prisms seen endwise; each of these sections shows an opaque peripheral and a clear central part. This is due to the petrifaction of the prisms taking place first in the periphery, the centre remaining for some time transparent. In conformity with this the centre of the distal end of the enamel cells retains its soft structure much longer than the periphery, and when isolated, these cells present accordingly at that end a shorter or longer process (Tomes).

The cells of the stratum intermedium of Hannover, besides being used for the formation of part of the above middle membrane of the enamel cap, are also utilised for the regeneration of enamel cells (Waldeyer).

By the time the middle membrane disappears, also the stratum intermedium is used up, and the enamel cells are in contact with the outer membrane or the outer epithelium of Kölliker, but separated from it by what appears to be a delicate homogeneous membrane. The cells of the outer epithelium give origin to the cuticle of the surface of the enamel, as mentioned on a preceding page.

The membrana propria above referred to on the inner surface of the enamel cap of the earliest stages, can be still recognised as a sharp boundary line *between the young enamel and dentin.* Later on it entirely disappears.

The tissue of the tooth sack represents the matrix from which the cement is formed ; its structure and function are that of the osteogenetic layer of the periosteum ; the formation of the cement out of that tissue is identical with the subperiostal bone development described in Chapter IX.

Already during the stage of the primary enamel organ of a temporary or milk tooth, there is growing out of it a lateral process of epithelial cells ; this represents the rudiment of the enamel organ of the permanent tooth (Kölliker). The formation of this latter takes place on precisely the same plan as that of the temporary tooth.

The knowledge of the structure and development of teeth, as described in the foregoing pages, we owe to a great extent to the observations of Purkinje, Schwann, Henle, Nasmyth, Kölliker, Tomes, Huxley, Owen, Retzius, Hannover, E. Neumann, Waldeyer, Hertz, Wenzel, Lieberkühn, Kollmann, and others, and especially to Charles Tomes by his numerous researches in the field of comparative anatomy of the teeth.

CHAPTER XXIV.

SALIVARY GLANDS.

THE salivary glands, according to their structure and secretion, are of three different kinds: (*a*) true salivary glands, as parotid gland of man and mammals, the orbitalis and submaxillaris of rabbit; (*b*) mixed salivary or muco-salivary glands, as submaxillary gland of man and guinea pig; and (*c*) true mucous glands, as submaxillary gland of dog and cat, sublingual gland of man, orbital gland of cat and dog (Lavdowsky). In all instances, however, we find a framework consisting of a capsule of fibrous-connective tissue, and in connection with this, thinner and thicker septa, which subdivide the gland substance into lobes and lobules. This connective tissue is composed of bundles of fibrous-connective tissue arranged more or less in lamellæ, and between these are the flattened more or less branched connective-tissue cells. Into the interior of the lobule penetrate only small bundles of fibrous-connective tissue, but chiefly the connective-tissue cells. The small ducts within the lobules are always surrounded by a conspicuous amount of fibrous-connective tissue; the large or lobar ducts run within the connective tissue forming the interlobar septa. There are found in all parts of the connective tissue, both inter- and intralobular, isolated or small groups of migratory cells (Boll, Lavdowsky). The connective-tissue framework is at the same time the support of the blood-vessels, lymphatics, nerves and ganglia.

The salivary glands of all categories have the same kind of ducts: beginning with the chief duct down to the lobar, and intralobular duct and its finest ramifications, we find in all corresponding sections the same structure. The lobar ducts, as the largest microscopical ducts, possess a relatively large lumen, lined by a single layer of beautiful columnar epithelial cells. Each of these consists of a finely striated protoplasm, owing to its containing an intracellular network of a pre-eminently longitudinal arrangement (Klein); the outer part of the cell contains the oval nucleus with its intranuclear network. Then follows a delicate membrane, on which the epithelium rests, and this is strengthened by fibrous-connective tissue, varying in amount according to the size of the duct. In the largest ducts, including the chief duct, there are unstriped muscle cells included in the wall.

The intralobular ducts (salivary tubes of Pflüger) differ from the former, not merely in their size and position, and in the thickness of their wall, but chiefly by their structure. Each of them possesses a relatively small lumen, this is lined by a single layer

of columnar epithelial cells, the substance of which appears to consist of closely placed relatively thick longitudinal rods (Kölliker). When examined more carefully, it can be ascertained, however, that these rods anastomose with one another by few short lateral branchlets, so as to form a network (Klein). Each cell has an oval or spherical nucleus situated about the middle or a little beside the latter. The striation is generally more distinct in the inner part of the cell substance than in the outer, owing to the above network being closer and more uniform in the latter than in the former. The epithelium is situated on a thin membrane containing oval flattened nuclei at more or less regular intervals, probably an endothelial membrane. The outline of the intralobular ducts is never smooth, but irregular and wavy, owing to the irregularity in size (height) of the epithelium at different places.

The large intralobular ducts branch into the smaller ones, and these are ultimately connected with, and pass into, the proper gland substance or alveoli. But before doing so, they undergo a change in their structure, and assume special characters by which they are easily distinguished, the terminal or intermediary part (v. Ebner). This latter varies in length in different salivary glands, being longer in the human submaxillary gland than in that of dog. It is much narrower than the intralobular duct, its lumen is smaller, and its epithelium either a single layer of polyhedral transparent cells, each with a spherical nucleus, as in dog's submaxillary gland, or it is a layer of flattened cells, each with a flattened nucleus, as in the submaxillary gland of man. The intermediary part is often branched before it passes into the alveoli (Grot).

The proper gland substance is in all salivary glands made up of branched tubes of varying lengths, much convoluted, and of a wavy appearance (Grot). This type of gland is called compound tubular. The tubes are closely placed against one another, and extending with their branches and convolutions in all different directions, it is natural that, in any section through the gland, we should find them cut under very different angles: transversely, obliquely, and longitudinally. Between the individual tubes or alveoli are capillary blood-vessels, lymphatic spaces, and the connective tissue mentioned above. This latter varies, however, in different glands, and determines the closeness of the position of the alveoli; thus in the submaxillary gland of man there is considerably more interalveolar connective tissue than in the dog, and therefore the alveoli in the former instance are less closely placed than in the latter.

The membrana propria of the alveoli appears as a delicate homogeneous membrane containing from place to place flattened nuclei, being in reality made up of richly branched flattened cells connected with each other (Henle, Heidenhain, Boll and others). Their processes are either fine and threadlike or broad and membranous, and the

network, adapting itself to the curvature of the alveoli, possesses in a given portion of the latter a basket-shaped arrangement.

In connection with these cells are minute membranous or filamentous septa, passing inwards between the epithelial cells lining the alveoli (Boll); they are lost in the cement substance between the epithelial cells.

This cement substance corresponds to the capillary ducts described by some writers in the salivary and other glands (Saviotti, Langhans, Schwalbe, Ewald, Boll, Grot, and others). According to v. Ebner they are merely clefts, without any special wall, between the epithelial cells. Hering also denies their existence as special canals. Latschenberger takes the same view with reference to the pancreas.

The nature of the lumen and the epithelium lining it determines the character of the gland. It is this:

a) In the true salivary gland: the lumen of the alveoli is small, the epithelial cells form a single layer of columnar or short columnar cells, each with a spherical nucleus situated in the peripheral part of the cell. The substance of this latter appears 'granular,' but is in reality a very dense network. Also the nucleus contains an intranuclear network. During secretion the lumen of the alveoli becomes still smaller, while the lining cells become broader than during rest.

In the parotid gland, in the greater portion of the lobules of the submaxillary gland of man and guinea pig, in the submaxillary and orbital glands of rabbit, the alveoli show the structure just described.

R. Heidenhain observed that the alveoli of the parotis of rabbit alter considerably their aspect after the stimulation of their sympathetic nerve. While after the stimulation of the cerebral nerve the cells lining the alveoli do not show any change from the resting state, after the stimulation of the sympathetic the cells become very much diminished in size and their contents very opaque. A similar change is observed also in the parotis of dog.

b) In the true mucous glands: the alveoli are considerably larger than in the former case, not only on account of the greater length of the lining epithelium but chiefly owing to the much greater lumen. The cells are of two kinds:

1) The *mucous cells* (Heidenhain) or central cells line the lumen, and are transparent columnar cells in all respects resembling goblet cells, as mentioned in Chapter II.; with their pointed extremity they are applied to the membrana propria, but so as to be imbricated with each other (Kölliker). The nucleus is much compressed and next to the membrana propria. The cell substance, as is generally the case in goblet cells, is a delicate network, the meshes of which contain in the resting state a transparent substance: this is the mucigen of Heidenhain. When secreting this substance is transformed into

mucin, and as such stains deeply blue in hæmatoxylin ; on account of its imbibition with water, it greatly increases in bulk, and hence produces an increase in the size of the cells (Heidenhain). The meshes of the intracellular network are hereby much enlarged, and the cell therefore looks more transparent. In the first state the reticulum in the inner portion of the cell possesses a longitudinal arrangement (Klein), and hence the cell substance appears as if longitudinally striated.

2) The crescents of Gianuzzi represent semilunar groups of parietal 'granular' cells applied from place to place to the outer surface of the mucous cells but inside the membrana propria (Heidenhain). The parietal cells are small polyhedral cells, each with a spherical nucleus (Heidenhain, Asp). The substance of these cells appears granular owing to its being composed of a very dense reticulum with very little interstitial substance in its meshes.

During secretion also the crescents become enlarged (Lavdowsky, Klein), and the alveolus as a whole is larger, although its lumen is somewhat reduced in size. In an exhausted gland (by electric stimulation or chemical action), the transparent mucous cells disappear as such, the alveoli are much smaller, being now lined only with polyhedral or short columnar 'granular' cells similar to the parietal cells. Heidenhain, Boll, and Lavdowski conclude from this that the mucous cells have become destroyed, and that the parietal cells have taken their place, probably in consequence of a process of new formation. Ewald, however, explains the same appearance by assuming that the mucous cells, in consequence of the exhaustion, have lost all their mucous contents, and have shrunk into small 'granular' cells. Ranvier, v. Eberth, and others also question the accuracy of Heidenhain's interpretation. Under ordinary conditions of secretion, however, the mucous cells do not become destroyed nor ever alter their appearances more than is indicated above (Klein), viz. a reticulum with transparent mucigen in its meshes, is found in the resting state, while during secretion its meshes become enlarged owing to the contents having swollen up and transformed into mucin.

Judging by analogy (see below) the mucous cells when exhausted very probably become much smaller, their network being closer and containing in its meshes much less interstitial substance, and hence the cells present a 'granular' aspect.

This is borne out also by experiment, for through Heidenhain, Pflüger, Lavdowsky, Ewald, and others it is known that the saliva secreted by the exhausted gland is watery, while in a previous stage it is mucus. The explanation of this would then seem to be this: when the mucous cells have discharged all their mucin, that is, when their substance has become 'granular,' like that of the cells of true salivary gland, also their secretion becomes similar to that of the latter, viz. watery.

In the submaxillary gland of young animals all transitional stages are met with between small alveoli with small lumen lined only with small 'granular' cells, and

alveoli somewhat larger and lined either partly with mucous cells, partly with granular cells, or altogether with mucous cells to which are applied from place to place groups of 'granular' cells.

Such is the nature of the alveoli in the submaxillary and orbital gland of dog, and in the sublingual gland of man.

c) In the mixed or muco-salivary glands, as in the human submaxillary gland and in that of the guinea pig, we find amongst lobules of true salivary gland smaller lobules of mucous gland, the structure of the alveoli of which is similar to that of the submaxillary gland of the dog, viz. a large lumen, lined with mucous cells, and outside these from place to place crescents of parietal cells. But even in one and the same lobule we may find the larger part composed of true salivary gland structure, while a small part is represented by mucous gland. More than that, in the submaxillary gland of man and guinea pig, we meet with alveoli of the structure of mucous gland described just now, *directly continuous with alveoli that are smaller, have a smaller lumen, and are lined only with 'granular' cells*, that is, alveoli identical with true salivary gland-structure (Boll, Klein).

Nussbaum maintained that by the aid of osmic acid it is possible to show that in the submaxillary gland of rabbit the cells lining the alveoli immediately adjoining the intermediary part of the duct, above described, possess a different character from the cells of other parts of the alveoli, and that the former are concerned in the secretion of the salivary 'ferment.' Langley denies the correctness of both the morphological as well as the physiological part of this assertion.

Bermann describes in the submaxillary gland of man, rabbit, dog, bat, &c., in connection with a large branch of the ductus Whartonianius, a compound tubular mucous gland whose structure is altogether different from the rest of the gland.

The alveoli of all salivary glands, like those of other glands, are surrounded by a dense network of capillary blood-vessels, and between them and the alveoli we find also lymph spaces and clefts surrounding the greater part of the circumference of the alveoli (Boll). The lymphatic vessels taking up these spaces lie in the interlobular septa, where they form a plexus.

The nerve branches are composed of medullated nerve fibres, and form a plexus in the interlobular connective tissue. In connection with this plexus are larger or smaller ganglia; in some places they form spherical or oval enlargements, in others they are

represented by smaller or larger chains of ganglion cells within a nerve branch. Their structure has been described and figured in a former chapter (see figure II. Plate XXII.). Most of these ganglion cells are unipolar, and ensheathed in a special capsule.

According to Pflüger, the nerve fibres coming off from this plexus remain medullated until their termination is reached, viz. just before they enter the intralobular ducts (Pflüger's salivary tubes) and alveoli. Then each nerve fibre loses its medullary sheath, and its axis-cylinder, composed of minute fibrils, becomes directly connected with the cell substance of the epithelium of those ducts. The nerve fibres for the alveoli remain medullated until the membrana propria is reached, they are also in direct continuity with the lining cells. Thus all the epithelial cells are real terminations of nerve fibres; and during regeneration they are direct outgrowths of the nervous elements.

Pflüger also mentions isolated multipolar ganglion cells (Krause) between alveoli, by their intervention a connection is occasionally established between nerve fibres and epithelial cells.

These assertions of Pflüger have received a certain amount of support in the observations of Kupffer on the termination of nerves in the salivary gland of periplaneta orientalis. Kupffer saw here a plexus of fine nerve fibres surrounding the alveoli of the gland; from it pass minute fibres which enter the epithelial cells themselves, in whose reticular substance they terminate.

But, on the other hand, with regard to the nerve distribution in the salivary glands of man and the other mammals, the correctness of Pflüger's assertions has been questioned or altogether denied by all who have investigated this subject.

REESE LIBRARY OF THE UNIVERSITY OF CALIFORNIA

CHAPTER XXV.

ORAL CAVITY, PHARYNX, ŒSOPHAGUS, AND STOMACH.

1. The mucous membrane lining the mouth and palate is, in man and mammals, covered with a thick stratified pavement epithelium. The arrangement of this, its minute structure, and the occurrence of prickle cells have been described in Chapter II. The deepest layer of the epithelium is composed of more or less columnar epithelial cells, each with an oval nucleus; then follow several layers of polyhedral cells with a spherical nucleus; nearer to the surface the cells and their nucleus become more flattened, and on the surface itself the cells are transformed into scales, each with a flattened circular nucleus.

In the mucous membrane of mouth of man the flattened cells of the most superficial layers possess each a flattened nucleus, except in the transitional part of the lip, that is, the red part seen even when the lips are touching; here many of the superficial cells are horny scales without a distinct nucleus, more or less closely packed together. In mammals we find in many instances the superficial cells with only traces of nuclei in them, and more or less fused into a bright horny stratum.

Underneath the epithelium is a basement membrane, a delicate endothelial membrane. Then follows the mucosa, a dense connective-tissue membrane, chiefly composed of bundles of fibrous-connective tissue, arranged as smaller or larger trabeculæ crossing each other in various directions. The interfascicular lymph spaces, containing the connective-tissue corpuscles and the networks of elastic fibrils attached to the surface of the trabeculæ, have been mentioned on several previous occasions. The thickness and firmness of the mucosa varies in different parts; thus, for instance, the mucosa is much thicker on the lips, angle of mouth, and buccal region than at the bottom of the mouth, soft palate, and palatine arches, and it is much firmer on the gums and hard palate than anywhere else, owing to the tendinous nature of its connective tissue, and its intimate fusion with the fibrous tissue of the subjacent periosteum. In all instances, however, the surface of the mucosa is raised as conical or cylindrical papillæ, extending into the epithelium The tissue of the papillæ is rich in connective-tissue cells. The epithelium and sub-epithelial basement membrane adapt themselves to the unevenness thus produced; the masses of epithelium filling the grooves and pits between the papillæ have been mentioned (Chapter II.) as interpapillary processes.

About the entrance of the mouth are found occasionally, in new-born children, papillæ that pro-

ject freely above the general surface of the epithelium, and are covered with a continuation of the general epithelium similar to the papillæ filiformes of the tongue (Klein).

The deeper parts of the tissue of the mucosa pass insensibly into the loose connective tissue which constitutes the submucosa or the submucous tissue. In this the trabeculæ or groups of bundles do not cross so repeatedly, but possess a more or less distinct lamellar arrangement, and are separated by large interfascicular lymph spaces.

The submucous tissue contains masses of fat cells, the large branches of vessels and nerves, the glands and striped muscle, and extending outwards, forms a continuity with the connective tissue of the surrounding organs, as muscle, periosteum, skin, &c.

As has been mentioned in a former chapter, the mucosa of the tonsils and soft palate contains masses of adenoid tissue, which in the former assumes the shape of lymph follicles. In some places the adenoid tissue with its lymph corpuscles by active growth encroaches on the epithelium.

The glands of the mucous membrane are mucous glands, and very conspicuous by their large size. The largest are found in the lower lip and soft palate. Each gland consists of the duct and the secreting part proper. The former is a tube passing in a vertical or, more usually, oblique direction from the submucous tissue (the gland proper) through the mucosa, and opens on the free surface of the epithelium with a funnel-shaped 'mouth.' The duct is limited by a membrana propria, containing oval flattened nuclei from place to place, being probably in all instances an endothelial membrane. It is a direct continuation of the subepithelial basement membrane. The duct possesses a large lumen, and this is in man lined with a single layer of beautiful columnar epithelial cells, each with an oval nucleus. The substance of these cells is longitudinally striated, containing an intracellular network of fibrils of a pre-eminently longitudinal direction. The nucleus contains also a reticulum. At the mouth the stratified epithelium of the surface passes, in an attenuated form, a short distance into the duct, but is soon replaced by the above columnar epithelium. In mammals the epithelium remains, however, stratified, being composed of two or three layers of flattened cells, until the deep part of the duct is reached, where it is composed of a single layer of polyhedral cells.

The oral cavity, the pharynx and œsophagus of batrachiæ, are lined with ciliated columnar epithelium. The posterior surface of the soft palate and uvula are in the human embryo covered with laminated columnar epithelium, of which the most superficial cells are ciliated, but in the adult the epithelium is stratified pavement epithelium (Klein), as in other parts of the oral mucous membrane. The epithelium lining the ducts and indeed of the whole gland is developed as a continuation of the epithelium of the free surface; this explains how sometimes also in the adult the epithelium lining the first part of the duct is ciliated (Klein).

In the submucous tissue the duct branches in several branches, each of which having become slightly narrower, and its epithelium flattened, generally becomes again somewhat enlarged, as *infundibulum*, where it passes into the secreting part. This consists

of tubes much convoluted, and possessed of shorter or longer lateral branches; each of these possesses a relatively large lumen; so that the secreting part of the gland is a compound tubular gland (Puky Akos). The mucous glands of all parts of the cavity of the mouth and pharynx are compound tubular glands, identical in structure (v. Ebner, Teraszkievicz, Podwisotzky, and others). They vary in size according to the number and length of the tubes.

The wall of both the infundibulum and gland tubes is a membrana propria, composed of a network of branched, flattened cells, each with a flattened nucleus. From these cells and their processes come off thin membranous and filamentous septa, which pass in between the epithelial cells of the gland. And this structure, viz. *a membrana propria composed of branched, flattened cells, and membranous or filamentous septa coming off from the former and passing into the cement substance of the epithelium lining the gland, repeats itself in all glands, no matter what their function, arrangement, or structure* (Boll, Schwalbe, v. Ebner, Watney, and others). The epithelium lining the lumen is a single layer of thin columnar epithelial cells. These are similar in structure to the mucous cells lining the alveoli of the submaxillary gland of dog, viz. transparent cells composed of an intracellular network, with relatively wide meshes. The nucleus is more or less flattened and pressed against the membrana propria. During rest the meshes of the intracellular network contain a transparent mucigen, which during secretion changes into mucin. When exhausted the network is closer, there being less interstitial substance in its meshes, and the cells appear therefore shorter and more 'granular;' in this period we find their nucleus nearly spherical. Similar are the epithelial cells lining the alveoli when not yet fully developed, viz. short and 'granular;' the nucleus is at the same time not flattened and pressed against the membrana propria, but spherical and at a little distance from the latter; the lumen of the alveoli is very minute, and hence their diameter is much smaller than when fully developed.

In some localities there is outside the lining cells of the alveoli an indication of crescents similar to those described of the submaxillary gland of dog, viz. a semi-lunar group of small 'granular' cells, each with a spherical nucleus. In the case of the mucous glands the crescents are very thin and scarce.

The transition of the epithelium of the duct into the mucous cells of the infundibulum is more or less sudden, the flat or polyhedral cells at the end of the duct, which may be conveniently called the intermediary part, become sooner or later longer and more transparent. This change does not occur simultaneously at all points of the circumference, for we see occasionally that while on one side the epithelium has already undergone the above alteration, it remains unchanged for some distance longer on the other side of the lumen of the gland tube.

THE BLOOD-VESSELS; the *arterial trunks* give off branches which pass in an oblique direction through the mucosa, in the superficial parts of which they dissolve into a network of capillaries extending in a horizontal direction. Single or double loops of capillaries of this network occupy the papillæ. The veins proceeding from the superficial capillary network form a plexus the efferent branches of which pass into the submucous tissue, where they join the large venous trunks. Lymph follicles, striped muscle, fat tissue, and mucous glands possess their own system of blood-vessels, consisting of afferent arterioles, a dense network of capillaries, and efferent veins. The nature of the capillary network differs in these different tissues; its characters in lymph follicles, in striped muscle and fat, have been described in previous chapters; as for the mucous glands the capillaries form a uniform network surrounding the alveoli similar to what is the case in the salivary glands.

The lymphatics; these are arranged, according to Teichmann, as a superficial network of tubular capillary vessels belonging to the surface of the mucosa; from it ascend blind or looplike branches for the papillæ. Lymphatic vessels with valves pass from this network, and penetrate into the depths and join the deep network of large trunks belonging to the submucous tissue. The relation between the lymphatic capillaries and the lymph-canalicular system of the mucosa, as well as that of the interfascicular spaces and sinuses of the submucous tissue to the lymphatics of the latter, has been mentioned on a previous occasion.

The nerves; they are distributed as a subepithelial plexus of fine bundles of nerve fibres, as a subepithelial network of fine elementary fibrils, and finally as intraepithelial fibrils, which probably terminate as a network (Elin), described in Chapter XVIII. It remains to be added here, that Krause observed end bulbs in the papillæ of the lips of the mouth of many mammals; Kölliker and Gerlach found in the same places, viz. papillæ of lips, tactile corpuscles similar to Meissner's corpuscles in the skin.

2. The *tongue.*—The mucous membrane of the tongue differs in structure in several respects from that of other parts; on the dorsum of the tongue it is very thin and firmly connected with the muscular tissue, but at the root it is much thicker, looser, and placed in numerous complex permanent folds. The epithelium covering the surface of the tongue is everywhere a stratified pavement epithelium, it is much thinner at the lower surface than in the other parts. The freely projecting papillæ filiformes and fungiformes, including the papillæ circumvallatæ, are covered with the same stratified pavement epithelium as other parts, with the difference that, owing to the erect position of the papillæ and to the epithelium following the surface of these

latter, the direction of the epithelial cells of the different layers over the papillæ themselves is nearly at right angles with that of the parts between.

The papillæ filiformes are single or compound, in the latter instance two, three, or more papillæ project from a common large papilla; but each papilla, whether single or compound, includes, as a rule, minute papillary projections of the mucosa, forming the matrix of the papilla, into the epithelium covering it, similar to what is the case in other parts of the mucous membrane of the oral cavity. The epithelial cells of the apex of the papillæ are much flattened, and in the adult we meet with small groups of them forming filamentous horny prolongations. In the papillæ filiformes of mammals the superficial strata of the epithelium are often composed of horny scales closely packed together.

The papillæ fungiformes are covered with beautiful stratified pavement epithelium, into which project larger or smaller secondary papillæ.

The mucosa forming the matrix of the papillæ is of the same connective-tissue nature as that of other regions of the oral cavity, except in the fungiform papillæ, especially in the large ones forming the centre of a circumvallate papilla, it contains numerous nerve branches composed of medullated nerve fibres.

The distribution of blood-vessels and lymphatics does not differ from that of other parts, except that the papillæ have each a single or multiple loop of capillaries, according as they are single or compound. In the fungiform papillæ the blood capillaries form a very beautiful network.

In the root of the tongue the mucous membrane is loose and contains numerous secreting glands, lymphatic follicles, and diffuse adenoid tissue.

The former, viz. secreting glands, are buried between bundles of striped muscle fibres, their ducts pass through the mucosa and open generally in the grooves, pits or crypts between or in the folds or knoblike prominences, with which the surface is beset; the lymphatic follicles are closely aggregated in the mucosa and extend into the epithelium of the surface as diffuse adenoid tissue. Their relation to the mucosa and the epithelium is the same as that described of the tonsils in a former chapter, viz. the folds or larger and smaller knoblike papillæ and crypts of the mucous membrane are chiefly caused by the presence in their wall of the above lymph-follicles and diffuse adenoid tissue (Kölliker, Huxley). As in the tonsils, so also at the root of the tongue, the adenoid tissue of the mucosa gradually encroaches on the epithelium, this latter becoming filled with lymph-corpuscles and reticulum. The lymph-corpuscles may be traced in many places up to the free surface. There is little doubt that the so-called salivary or mucous corpuscles, found in the mucus and saliva taken from the cavity of the mouth, are lymph-corpuscles that have originally belonged to the adenoid tissue

of the tonsils, root of tongue, or soft palate, and have made their escape through the epithelium of these organs. Like other lymph corpuscles they exhibit the power of amœboid movement. Under the influence of water they swell up into spherical corpuscles, containing numerous granules that show very lively Brownian molecular movement. In this latter aspect they generally present themselves in the saliva and mucus taken from the oral cavity.

Taste organs.—The circumvallate papillæ, many fungiform papillæ, and certain permanent folds at the side of the root of the tongue of man and mammals are distinguished by the presence of taste goblets, discovered by Schwalbe and Lovén.

The description of their structure, as given by Schwalbe, is in its chief points still generally accepted.

Each taste goblet is a goblet-shaped or elliptical organ, embedded vertically in the stratified epithelium in such a manner that one end of it is on the free surface, the other touches the tissue of the mucosa, and the sides are bordered by the epithelium. This latter forms a special covering for the taste goblet by a layer of flattened epithelial cells, imbricated one with the other, and each possessed of a flattened circular nucleus. The goblet itself contains: (*a*) the peripheral or tegmental cells (Schwalbe, Lovén), which by their peculiar arrangement determine the shape of the goblet. They are elongated, spindle-shaped, slightly flattened cells, each with a flattened circular or oval nucleus; they are occasionally branched (Schwalbe). (*b*) The central cells, or taste cells (Engelmann): these are slender, spindle-shaped or staff-shaped cells, each with a spherical nucleus in about the middle of the cell. Both extremities are filamentous; the outer extremity projects as a fine hairlike process a short distance beyond the free opening of the goblet, while the inner extremity is directed towards the mucosa, and is in some instances branched in two fine processes (Engelmann). Great numbers of nerves are found in the mucosa near the taste goblets, and, according to Engelmann, and especially Hönigschmied, fine nerve fibrils are directly connected with the taste cells.

The taste goblets have a wide distribution in man and mammals. They are found in rows, at the base of the circumvallate papillæ, at the base of many fungiform papillæ, in the permanent folds known under the name of papillæ foliatæ (Weber), and occurring at the side of the human tongue and the tongue of many mammals, especially in rabbit, where they form on each side a very conspicuous organ. In the papilla foliata the taste goblets occur in three or four closely placed rows at the base of the fold. v. Wyss and Engelmann minutely described them in the papilla foliata of rabbit, v. Ajtai in the papilla foliata of man, Hönigschmied showed their distribution in the papillæ circumvallatæ and foliatæ of many mammals, Krause and Hoffmann observed them in the fungiform papillæ of man, and the latter author described

taste goblets also in some papillæ of the soft palate. Isolated taste goblets occur, according to the same observer, also on the summit of some fungiform and circumvallate papillæ of man.

The parts of tongue that contain taste goblets, especially the circumvallate papillæ and the papillæ foliatæ, are also distinguished by large saccular lymphatic capillaries embedded in the mucosa; each fold of the papillæ foliatæ contains in the centre a large lymphatic sinus, the wall of which is a single layer of endothelium, and which is connected with the superficial plexus of the lymphatics of the mucosa.

The secreting glands of the root of the tongue are of two kinds, serous glands and mucous glands (v. Ebner). The latter differ in no way from the mucous glands of other parts of the oral cavity, as described on a previous page. Their ducts are occasionally (in man) lined with ciliated epithelium (v. Ebner). The mucous glands occur only at some distance from the parts that contain taste goblets. The glands present in the apex and marginal parts of the tongue (Blandin, Nuhn, Wardt) are mucous glands.

The serous glands differ in position and structure from the mucous glands; they occur always in the parts that contain taste goblets (v. Ebner), and their ducts open with a funnel-shaped mouth in the grooves or pits lined by the taste goblets (papillæ circumvallatæ and papillæ foliatæ).

The thick stratified pavement epithelium of the surface is continued into the mouth of the duct, but soon becomes thinner, being composed of a limited number of layers of polygonal cells; in the deeper parts of the duct the epithelium is a single layer of columnar cells.

The duct branches in several minute ducts, each of which is, just as in the case of the mucous glands, connected with a wavy and convoluted branched tube, alveolus; the branches are all closely pressed together, and hence in any section through the gland we meet with tubes cut under different angles: transversely, obliquely, and longitudinally. The lumen of the alveoli is very small, in many cases not at all distinct, or only just indicated as a fine canal. Their epithelium is a single layer of more or less columnar cells, each with a spherical nucleus, similar to the cells lining the alveoli of true salivary glands. The cell substance looks like granular protoplasm, but is in reality a dense network, as described of the cells of the true salivary glands. The membrana propria of the alveoli is formed, as in other glands, by a network of flattened and branched nucleated cells (v. Ebner). It is very probable that the secretion of the serous glands is, like saliva, of a watery nature, and owing to the above-mentioned distribution of the glands and their ducts, it (the secretion) is poured out directly over the parts containing the taste goblets. This naturally greatly assists the rapid and efficient distribution of the substances, to be tasted, over the taste area, an effect that

could not be easily achieved if the secretion were viscid, viz. if it were that of a mucous gland (v. Ebner).

According to Krause and Kölliker, the nerves of the papillæ of the tongue contain end bulbs, and according to Geber also tactile corpuscles of Meissner. This latter can be fully confirmed.

In connection with the nerve trunks situated in the intermuscular connective tissue, especially in the parts containing secreting glands, we meet with smaller or larger ganglia (Remak). They possess the same structure as those of the submaxillary gland, and it is quite probable from their distribution that also in the tongue they bear an intimate relation to the glands.

3. The *pharynx.*—The mucous membrane lining the lower greater section of the pharynx is similar to that of the oral cavity as regards the epithelium, the structure of the papillæ, of the mucosa and submucosa, the mucous glands in the latter, and the distribution of blood-vessels and lymphatics.

In the upper section the epithelium is like that of the respiratory organs, viz. stratified columnar epithelium, the most superficial cells being ciliated. The mucosa is possessed of numerous folds and crypts, the wall of which contains lymphatic follicles and diffuse adenoid tissue similar to what is the case at the root of the tongue and the tonsils, and hence the designation of pharyngeal tonsil (Luschka). The pits and crypts are lined by beautiful ciliated columnar epithelium (Luschka). According to Ganghofner the epithelium lining the mucous membrane of the bursa pharyngis of children, especially the part that he designates as recessus pharyngis medius, is in some places composed of ciliated columnar cells, in others, as on the folds of the mucosa, of stratified pavement epithelium. This latter epithelium occurs also as small islands amongst large continents of cylindrical ciliated epithelium.

4. The *œsophagus.*—The œsophagus of man and mammals is lined with stratified pavement epithelium of the same nature as that of the oral cavity and pharynx; its (epithelium) thickness is much greater in man than in mammals. The mucosa is a dense connective-tissue membrane projecting into the epithelium as longer or shorter conical or cylindrical papillæ. These are largest in the human œsophagus. The mucosa is separated from the loose submucous tissue by unstriped muscle cells, running in a longitudinal direction, and arranged in larger or smaller bundles—muscularis mucosæ. In the beginning of the œsophagus, the bundles are small and separated by a great amount of connective tissue, further down they become closer, until they form a continuous layer, whose thickness increases towards the lower parts. The thickness of the mucosa, and

that of the muscularis mucosæ, vary in different animals, it is inferior in man to that in carnivorous animals. In the dog the muscularis mucosæ is very thick, and its bundles are connected with one another in a plexus.

The submucous tissue contains the mucous glands; they and their ducts are of the same nature as those of the oral cavity. The glands are scarce in the œsophagus of man, in carnivorous animals they are well developed, forming in the lower half of the organ a continuous stratum. In carnivorous animals the cells lining the gland tubes are mucous cells, showing the same structure and changes during rest, secretion and exhaustion, as described of those of the mucous glands of the mouth. The reticulated nature of the cell substance of the gland tubes is shown with great distinctness in the dog. The epithelial cells of the glands in man are beautifully columnar, and show the same changes during rest, secretion, and exhaustion, as mentioned previously. The ducts pass through the muscularis mucosæ and the mucosa in a vertical or oblique direction, and open with a narrow mouth on the free surface. The epithelium of the ducts shows the same difference in man and mammals as in the glands of the oral cavity.

Outside the submucous tissue is the external muscle coat, consisting in man of an inner circular and an outer longitudinal coat. The former is thicker than the latter in all parts, except the upper fourth. Outside this is a longitudinal thin membrane of fibrous-connective tissue. The trabeculæ of the submucous tissue are continuous with the connective tissue separating the muscle bundles of the muscle coats. In man the external muscle coat consists of striped fibres in the upper half of the first fourth, in the second half small bundles of unstriped muscle cells appear gradually amongst the former, their number increases rapidly, so that in about the middle of the œsophagus the striped fibres are altogether replaced by the unstriped ones.

In mammals the striped muscle fibres, more or less separated by bundles of unstriped cells, remain to the cardia. In carnivorous animals, the external muscle coat is in many places composed of more than two layers, the muscle bundles having mostly a course more or less spiral around the long axis of the œsophagus.

The blood-vessels have a similar distribution as in the pharynx, viz. from the arterial trunks situated in the submucous tissue proceed branches which in the upper part of the mucosa form a network of capillaries, these give off loops for the papillæ. The venous branches pass the reverse way, viz. from the superficial network of capillaries through the tissue of the mucosa, into the venous trunks of the submucosa. The glands of the latter tissue, the muscularis mucosæ, and the external muscle coat, possess their own vascular system.

The lymphatics form a plexus of capillaries belonging to the surface of the mucosa (Teichmann); from them proceed the lymphatics of the papillæ, each of these possessing

a single cæcal vessel or a loop. The plexus of lymphatics of the mucosa is in communication with a plexus of large tubular vessels belonging to the submucosa (Teichmann). In connection with the submucous lymphatics, in the œsophagus as well as in the pharynx, are special lymphatic vessels and sinuses belonging to the mucous glands (Kidd).

The plexus of large nerve trunks surrounding the œsophagus includes larger and smaller ganglia (Remak). The nerve-branches that enter the œsophagus form a dense plexus of smaller or larger bundles between the circular and longitudinal layer of the external muscle coat. In these nerve branches we meet with isolated or chains of ganglion cells (Klein). Each of these is enclosed in a capsule. The submucous tissue contains another plexus of nerves, connected with the former plexus, and also in this may be met with occasionally isolated ganglion cells (Klein).

5. The *Stomach.*—The epithelium covering the free surface of the gastric mucous membrane is a single layer of columnar epithelial cells; in many places the cells are mucus-secreting goblet cells (Stricker, F. E. Schultze, Klein, Watney, and others); this is especially the case during digestion, when all cells are secreting mucus. The nature of the intracellular network in the ordinary epithelial cells, and in the goblet cells, and the relation of the ordinary epithelial cells to the goblet cells, have been fully described in Chapter II. The lower or inner portion of the epithelial cells, containing the oval nucleus, remains always the same, viz. composed of a dense network, even while the upper part becomes changed into the mucus-secreting goblet. The epithelium of the surface is continued into the ducts of the gastric glands, these being closely placed tubes vertically sunk into the mucous membrane. The epithelium lining the ducts is identical in appearance and nature with that of the free surface. Amongst the epithelium of both the surface and the gland ducts is a reticulum of connective-tissue cells and their processes (Watney), losing themselves in the cement substance between the epithelial cells. Watney showed that the epithelial cells, both of the free surface and of the ducts, undergo division; this is indicated by the presence of smaller or larger epithelial buds, being groups of broad, clear epithelial cells. Underneath the epithelium is a basement membrane, which consists of nucleated flattened transparent endotheloid cells (Watney).

The inner greater section of the mucous membrane belongs to the mucosa; this contains in a scanty connective tissue, chiefly composed of thin fibre bundles, numerous flattened endotheloid cells (Watney), a few lymph corpuscles, and gland tubes, the gastric glands, placed closely and vertically to the surface. Owing to the close position of the gland-ducts, opening on the surface, the mucosa of this latter appears

reduced to narrower or broader foldlike or villous projections. The glands of the pyloric end of the stomach, viz. the pyloric glands, possess a different structure from those of the rest of the stomach, the peptic glands. The latter are arranged in groups of four, five, and more. The amount of tissue of the mucosa separating these groups varies in different depths of the mucosa; it is much greater near the surface, that is between the ducts, than in the depth.

a) The *Peptic Glands.*—Into each of the above minute *ducts*, lined with the columnar mucus-secreting epithelium, open two or three tubes, the gland tubes proper. These are straight or slightly wavy, they are generally more or less curved like a hook at their blind extremity, that is, near the muscularis mucosæ. The duct amounts to about a third or a sixth of the whole length of the tube; near the cardia, the tubes being shorter, this relation is altered in favour of the ducts.

The first section of the gland tube, amounting to about the third or fourth part of the whole tube, is the *neck*, the rest the *body*. The neck is much thinner than the body, and this latter increases in breadth towards the blind extremity, the *fundus* of the tube. At the point where the neck opens into the duct, the broad lumen of this latter becomes suddenly narrower and extends into the former as a very fine canal. The epithelium of the neck is a continuation of that of the duct; its cells are, however, very much shorter, their substance is more opaque, and their nucleus small and oval. Outside this epithelium lining the canal of the neck but inside the membrana propria of the gland tube we meet with other cells; they are more or less angular, oval, or spherical cells slightly compressed in vertical diameter, of an opaque or 'granular' aspect, and containing a clear oval or spherical compressed nucleus; they often bulge out the membrana propria, hence the outline of the tube becomes very irregular. These cells, which were formerly always described as the 'peptic cells,' were shown by Rollett and Heidenhain, who first recognised their true relation, to be always situated outside the epithelium lining the canal of the gland tube. Heidenhain called them parietal cells (Rollett's delomorphous cells), in contradistinction to the chief cells (Rollett's adelomorphous cells), that immediately line the canal. They do not form a continuous layer but are isolated. In the neck they are tolerably near one another.

The body of the gland tube also possesses only a fine canal lined by columnar cells or chief cells, these being a direct continuation of the chief cells of the neck, but much longer, more columnar, and more transparent than the former. They increase in length in proportion as the gland tube increases in breadth from the neck towards the fundus. The substance of these chief cells is a delicate reticulum with a small amount of a hyaline interstitial substance in its meshes (Klein). The nucleus is spherical or slightly oval, and situated in the outer third of the cell, it contains also an intranuclear network,

and stains readily in dyes. During digestion the chief cells of the body of the gland are thicker, hence the whole tube is slightly broader (Heidenhain); in this state the network forming the substance of the chief cells is more open, its meshes being larger. The parietal cells are fewer than in the neck, but of the same position and structure; their substance is opaque and the nucleus clear; their number decreases towards the fundus (Rollett, Heidenhain).

Owing to the different nature of the chief cells in the neck and the body of the gland, and to the difference in the number of parietal cells in the two sections, it is always possible to recognise, in a horizontal section through the gastric mucous membrane, the peptic glands being then cut transversely, whether a particular tube is cut across the neck or the body. More than this, owing to the difference in breadth of the body of the tube at the fundus, and further away from it, and owing to the parietal cells diminishing in numbers towards the fundus, it is possible to recognise whether a particular transverse section of a tube corresponds to the fundus or to another part of the gland.

Approaching the pyloric end, the peptic glands alter slightly, inasmuch as the duct becomes longer and the tube relatively shorter; the glands in some instances become branched at their fundus. Between the pylorus, containing the pyloric glands, to be described presently, and the rest of the stomach, there is, in carnivorous animals (dog), a zone (intermediary zone, Ebstein), in which the two kinds of glands, viz. the peptic glands and pyloric glands, not only intermix, but the first change into the latter (Klein, Bentkowski). This change consists in the following: (α) the ducts become very much longer: twice and three times as long as in other parts of the stomach; the rest of the gland is accordingly shortened in proportion; (β) the neck of the gland becomes shorter; (γ) the body of the gland becomes branched, while the diameter of its lumen is very much enlarged; (δ) the parietal cells diminish gradually in number, first in the body, then also in the neck of the gland. The chief cells retain their reticulated structure, both those of the neck and those of the rest of the gland.

Careful observations have shown the existence of the two kinds of cells in the peptic glands of most mammals. Besides Rollett and Heidenhain, we owe these results to Friedinger, Jukes, Bentkowsky, Schäfer and Williams, and others. Rabe does not find the two kinds of cells in the peptic glands of the horse.

b) The *Pyloric Glands.*—From the description, just given, the nature of these glands is probably already clear. It is this: the duct is proportionately very long, it amounts to half or more of the whole length of the gland; two or three tubes open into the duct by a very short neck, which represents the narrowest part of the gland; the body of the gland is branched into two or three tubes, which are wavy and convoluted;

the lumen of the neck, but especially that of the body of the gland, is much larger than in the corresponding parts of the peptic gland: the lumen in the body of the former glands being many times larger than that of the latter.

The epithelium covering the surface of the mucosa and lining the ducts in the pyloric region is exactly the same as in the rest of the stomach. The epithelium lining the neck and body of these glands is a continuation of that of the duct; but, as in the case of the peptic gland, so also here the cells are shorter and more opaque in the neck than in the body. In this latter the cells are fine, more or less transparent columnar cells: in no part are there parietal cells. Their substance is a beautiful reticulum, which during rest and exhaustion is closer and more elongated than during secretion; in the latter state there is an appreciable amount of interstitial substance contained in its meshes. Hence the epithelial cells are shorter, more 'granular' and opaque during rest than during secretion; in the former state the nucleus is spherical, during secretion it is compressed and close to the membrana propria (Ebstein, Klein).

Ebstein regards the pyloric glands as simple peptic glands, but this is denied by several observers (v. Wittich and others); at any rate, they are not mucous glands, as formerly believed.

Towards the duodenum the pyloric glands become larger, owing to the greater length of their tubes; these are at the same time more branched. They pass without interruption into the Brunner's glands, with which they are identical in structure. We shall return to these when describing the duodenum.

The membrana propria of the glands of the stomach is of the same structure as that of other glands mentioned on former pages: viz. a network of flattened branched cells, from which come off filamentous and membranous processes that penetrate between the epithelial cells lining the gland tubes (Watney). The branched cells of the membrana propria of the peptic glands have been first seen by Henle; Heidenhain described them more accurately.

Outside the cæcal extremity of the gland tubes is a thin layer of connective tissue, and then follows a muscular coat, the muscularis mucosæ, which in some places consists of a single longitudinal layer, but in many places shows an inner circular and an outer longitudinal layer of unstriped muscle cells; in some places there is an additional inner longitudinal or oblique layer. The thickness of the muscularis mucosæ varies in different places; as a rule it is thickest at the summits of the folds of the mucous membrane. Numerous bundles branch off from the muscularis mucosæ and penetrate into the mucosa, where they ascend between the gland tubes; near the surface some of them assume a horizontal course, others terminate at the basement membrane (Watney). Outside the muscularis mucosæ is the submucous tissue, consisting of trabeculæ of fibrous-connective tissue arranged as a loose meshwork. This tissue is here, as in

other parts, supporting the large blood-vessels and lymphatics, the nerve trunks and their ganglia.

On the outer surface of the mucosa and the inner surface of the muscularis mucosæ of cat's stomach is found a very characteristic elastic membrane (Zeissl), mentioned already in Chapter V.

The mucous membrane composed of the preceding layers is fixed to a thick muscle coat, the external muscle coat, which in many places consists of an inner thicker circular and an outer thinner longitudinal stratum of unstriped muscle cells; but masses of oblique bundles (fibræ obliquæ) are found on the inner surface of the circular stratum (Gillenskoeld). The outer boundary of the stomach is formed by the peritoneum, whose deeper bundles of connective tissue are connected with the perimysium of the longitudinal muscle stratum in the same way as those of the submucosa with the perimysium of the inner layer of the muscle coat.

The mucous membrane of the first part of the alimentary canal, viz. mouth, palate, and pharynx, does not contain any muscularis mucosæ, and the tissue of the mucosa passes therefore insensibly into that of the submucosa. Both these tissues, and especially the intermuscular connective tissue, contain fat-cells.

In the second part, viz. the œsophagus, stomach, small and large intestine, the mucosa is separated from the submucosa by a muscularis mucosæ, in the œsophagus, as mentioned above, it is a single longitudinal stratum, in the stomach it is composed of an inner circular and outer longitudinal stratum, and occasionally an additional inner longitudinal stratum. Fat-cells occur chiefly in the submucous tissue and in the subserous part of the peritoneal covering.

In the mucous membrane of the mouth, palate, pharynx, and œsophagus, the secreting glands are situated in the submucous tissue; in the stomach, small and large intestine, they belong to the mucosa, except the Brunner's glands at the beginning of the duodenum, these are situated in the submucous tissue.

The secreting glands of the alimentary canal, until the cardia is reached, are compound or branched tubular glands; in the stomach, small and large intestine, they are single tubes with the exception of the pyloric glands and the Brunner's glands, both of which are also compound tubular.

The distribution of blood-vessels does not differ materially from that of the œsophagus, except in the mucosa. The arterial branches having penetrated through the muscularis mucosæ ascend into the mucosa, where they dissolve themselves into capillaries, which form networks around the gland tubes, with more or less elongated meshes. Near the surface the network is very dense, and forms a special horizontal superficial layer underneath the epithelium. Out of this develop the venous branches.

The lymphatics of the mucous membrane are very numerous, they form a deep plexus of larger vessels in the submucous tissue (Teichmann). Into this plexus lead lymphatics which belong to the mucosa: here they form, according to Teichmann and Lovén, a network of vessels near the fundus of the gland tubes. According to Lovén numerous lymphatics lead into that plexus; these are larger than the former, and run a more or less longitudinal course between the gland tubes; they anastomose with one

another very freely, and extend nearly to the surface, where they form loops or terminate in saccular cæcal extremities. In many places the lymphatics almost invaginate the gland tubes for a longer or shorter distance. In the mucosa, especially between the fundus of the peptic glands, are found occasionally smaller or larger masses of adenoid tissue. They form in some instances distinct lymph follicles, arranged either singly or in groups. At the point of union of the pyloric end of the stomach with the duodenum of man and other mammals occur numerous lymph follicles (Watney).

The nerve trunks derived from both the pneumo-gastric and sympathetic include minute ganglia (Remak). The nerve branches, having entered the external muscle coat, form a plexus, extending in a horizontal direction between the longitudinal and circular stratum, the plexus of Auerbach. In this plexus are included spindle-shaped, angular or nodular ganglia. The ganglion cells are apolar, unipolar or multipolar. Nerve branches pass from the plexus of Auerbach into the submucous tissue, where they are again connected into a plexus, the plexus of Meissner; this also includes minute ganglia, whose cells appear unipolar and bipolar. The structure of both these plexuses and their ganglia will be considered more minutely in connection with the small intestine.

Rabe describes a rich plexus of nerve fibres surrounding the peptic glands of horse; some of them terminate in peculiar spindle-shaped cells, each with two small nuclei.

PLATE XXXI.

Fig. I. From a vertical section through embryonal tooth of dog; the tooth is still surrounded on all sides by the tooth sac. Magnifying power about 45.

The preparation had been stained first in carmine and then in hæmatoxylin.

a. Tooth papilla; its cells and its blood-vessels are only indicated owing to the very low magnifying power.

b. The layer of odontoblasts, the most peripheral stratum of the tissue of the papilla, is well shown.

c. Dentin; numerous fine lines pass through it, they agree with the outlines of the odontoblasts from which the dentinal matrix is derived, and correspond to the places for the future dentinal canals. There is a distinction between an inner thin layer of dentin next to the odontoblasts and an outer broader layer, the first is the most recently formed and not yet calcified. Next to this layer is the rudiment of enamel, marked by a thin layer of a substance stained deeply in hæmatoxylin.

d. Inner membrane of the enamel cap, the columnar enamel cells are well shown.

e. Middle membrane of the enamel cap, being a honey-combed structure.

I

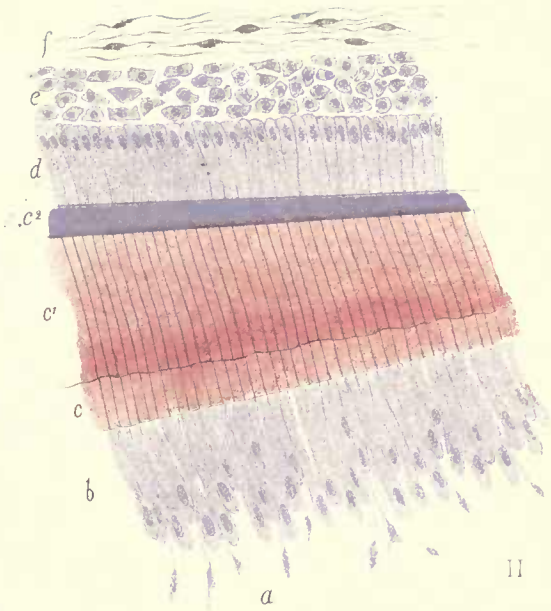

II

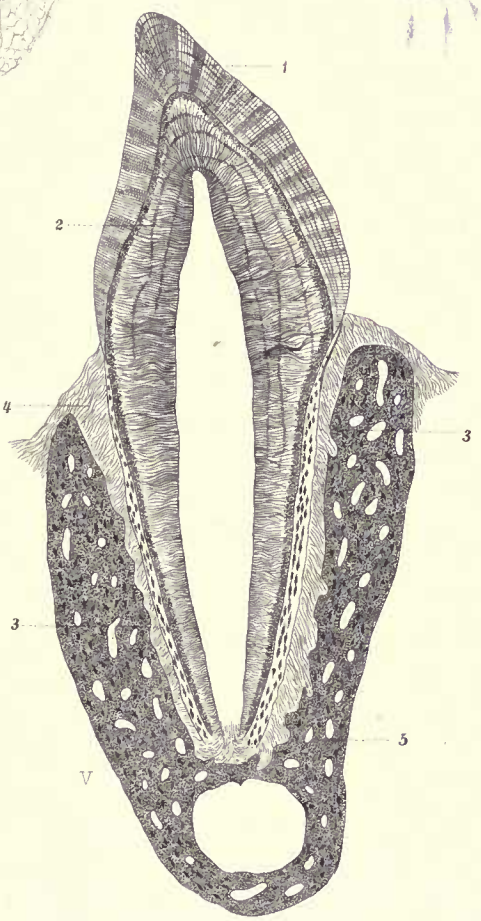

V

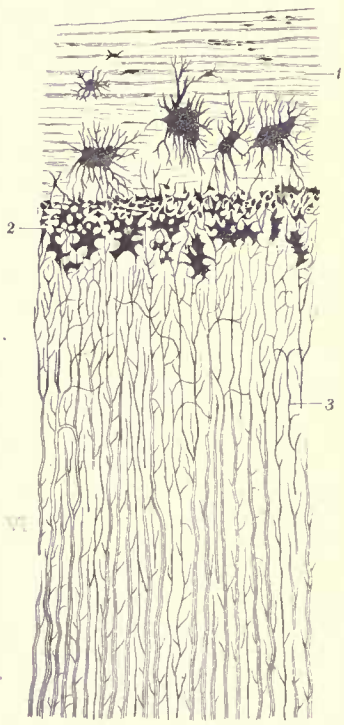

VI

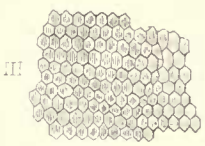

III

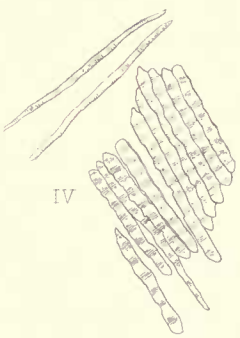

IV

VIII

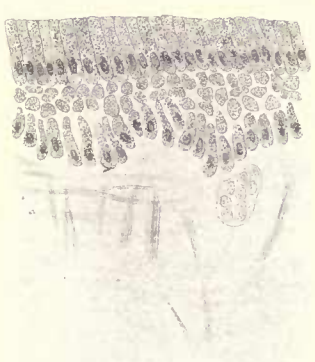

VII

REESE LIBRARY
OF THE
UNIVERSITY
OF
CALIFORNIA

Outside this is the outer membrane or outer epithelium of the enamel cap, marked by a purple line.

f. Tissue of the tooth sac with vessels; these latter do not extend further than the outer membrane of the enamel cap.

Fig. II. From a similar embryonal tooth as in figure I., but of a stage when no middle membrane of the enamel cap is visible. Magnifying power about 400.

a. Special layer of spindle-shaped and branched cells of the periphery of the tissue of the papilla penetrating with their long filamentous processes between the odontoblasts proper. These processes are much more numerous than represented here.

b. The odontoblasts proper.

c. Most recently formed layer of dentin.

c_1. Older dentin.

c_2. Enamel.

d. Enamel cells; between this layer and the following is a distinct membrane, omitted in the drawing.

e. Outer epithelium of enamel organ; its cells are separated from each other, probably in course of preparation.

f. Tissue of tooth sac, a lamellated structure; the details of its structure have been omitted.

Figs. III. and IV. Copied from Kölliker's 'Handbook.'

In Fig. III. enamel prisms are seen in transverse section; in fig. IV. portions of enamel prisms seen lengthwise.

Figs. V. and VI. Copied from Waldeyer (figs. 97 and 98) in Stricker's 'Handbook.'

Fig. V. Frontal section through præmolar tooth of cat. Magnifying power 15.

1. Enamel, showing a radial striation due to the crossing of bundles of enamel prisms, and numbers of parallel stripes of Retzius.

2. Dentin with the dentinal canals and Schreger's lines.

The most peripheral dotted zone of the dentin corresponds to the interglobular substance.

The central cavity corresponds to the pulp cavity.

3. Cement; in its transparent ground-substance are seen the large bone corpuscles.

4. Periosteum of alveolus.

5. Inframaxillary bone with the inframaxillary canal.

Fig. VI. Part of dentin and cement from a transverse section of human canine tooth. Magnifying power 300.

1. Cement with the large bone corpuscles.

2. Interglobular substance.

3. Dentinal canals.

Fig. VII. Vertical section through part of enamel organ of a bicuspid tooth of puppy. Magnifying power about 300.

a. Enamel cells; the upper part of the cells is here represented as of the same granular shade as the lower part containing the nucleus, in reality it is more transparent and homogeneous.

b. Small epithelial cells, the deepest layer of which is composed of cells more or less columnar. The interstitial substance is represented as uniformly transparent, but this is in so far incorrect, as the cells are distinct 'prickle cells,' being connected by fine processes.

c. The surrounding mucous membrane, projecting into the enamel organ as small papillæ.

A clump of small cells is seen in the neighbourhood of the epithelium. It is an outgrowth of the epithelium.

Fig. VIII. From a section through submaxillary gland of a child. Magnifying power about 45 ; representing a lobule surrounded by fibrous-connective tissue.

a. Chief duct, lined by columnar epithelium.

b. Fibrous-connective tissue surrounding this and its lobule.

c. Intralobular ducts.

d. Its terminal parts.

e. Alveoli, being tubes cut in different directions.

Fig. IX. From a section through submaxillary gland of a child ; magnifying power about 350 ; showing part of a mucus-secreting alveolus and its several branches.

a. Lumen of alveolus, the cells lining it are mucous cells. Outside these are polyhedral granular-looking cells each with a spherical nucleus. These cells form crescentic masses around the mucous cells.

c. Alveoli cut in different directions, they are not mucus-secreting and correspond to true salivary gland substance. They are much smaller and have only a small lumen, the lining cells are columnar, each with a spherical nucleus. The cell substance appears granular because its intracellular network is exceedingly dense.

PLATE XXXII.

Fig. X. Part of a lobule of a serous gland of root of tongue of rabbit. Magnifying power about 450.

d. Duct.

a. Alveolus or gland tube cut obliquely.

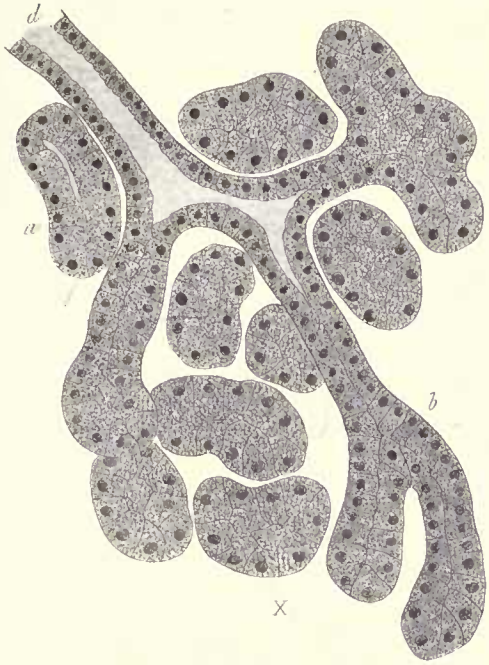

X

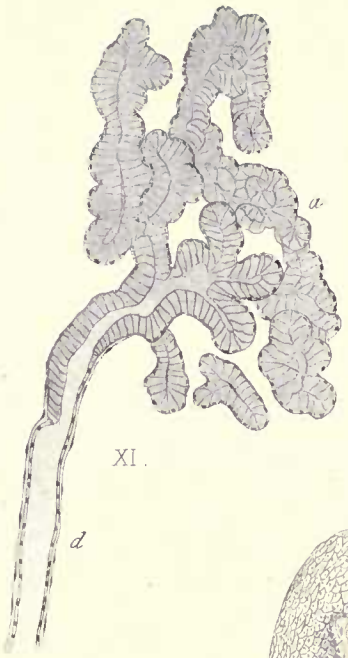

XI.

XII.

XIII.

XIV

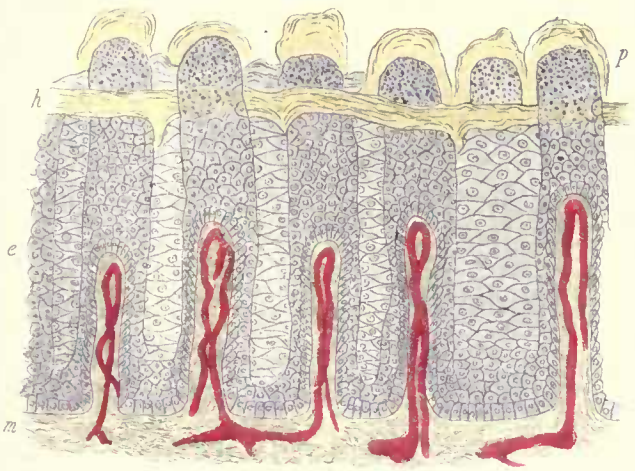

XV.

XVI.

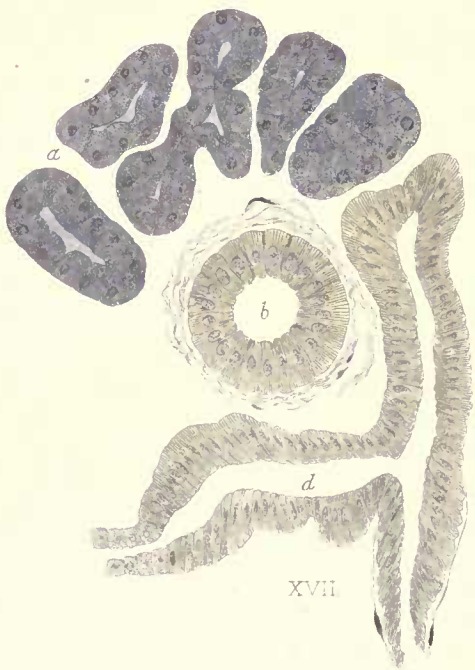

XVII.

b. Gland tube cut longitudinally.

The epithelial cells lining the alveoli are columnar, their substance is a dense network, much denser than here represented, and their nucleus is spherical.

Fig. XI. Part of a lobule of a mucous gland of the root of tongue of dog. Magnifying power about 90.

a. Gland tubes cut in different directions.

d. Duct.

Fig. XII. Part of a lobule of submaxillary gland of dog; showing (*a*) the alveoli cut in different directions; each alveolus shows a relatively large lumen lined by transparent mucous cells, outside these the more opaque crescents of Gianuzzi.

d. The intralobular ducts.

The details in structure of the epithelium lining the duct and alveoli are not shown on account of the low magnifying power.

Fig. XIII. From the same gland as represented in the preceding figure. Magnifying power about 400.

a. Alveoli or gland tubes (branched) cut in different directions; the lumen is very conspicuous; the lining cells are mucous cells. Outside these are the crescents, groups of 'granular' polyhedral cells.

d. Minute duct in transverse section; its epithelium shows a very beautiful longitudinal striation.

i. Intermediary part of duct. The epithelium is here made up of short columnar cells, each with a spherical nucleus.

Fig. XIV. From a vertical section through the dorsal part of the tongue of a child. Magnifying power about 90.

m. Connective tissue of mucosa.

a. Small papilla filiformis.

p. A papilla fungiformis.

Both kinds of papillæ are covered with thick stratified pavement epithelium, and both, especially the fungiform papilla, possess minute secondary papillæ, extending from the connective-tissue matrix into the covering epithelium.

Fig. XV. From a vertical section through dorsum of tongue of rabbit; the blood-vessels had been injected with carmine and gelatin. Magnifying power about 100.

m. Mucosa; from it rise papillæ filiformes, each with a single or double loop of capillary vessels.

e. Thick stratified epithelium, covering the papillæ.

p. The summit of the papillæ; the epithelium on them (summits), as well as on the surface between them—*h*—is transformed into a homogeneous horny stratum.

Fig. XVI. The duct and adjoining part of the mucous gland of fig. XI., but more highly magnified, about 450.

d. Duct lined by a single layer of transparent polyhedral cells; these pass into the mucous cells—*g*—of the infundibulum, but sooner on one side than on the other.

The membrana propria with small flattened nuclei is well seen.

Fig. XVII. From a section through true salivary gland structure of human submaxillary gland. Magnifying power about 350.

a. Alveoli cut in different directions.

b. Minute intralobular duct cut transversely; its striated epithelium is well shown; it is surrounded by fibrous-connective tissue.

d. Similar duct cut longitudinally.

PLATE XXXIII.

Fig. XVIII. From a vertical section through the papilla foliata of rabbit. Magnifying power about 90.

f. Folds in transverse section, covered with stratified pavement epithelium; at the basis of each fold are seen the taste goblets.

g. Furrows between the folds; into them open:

d. The ducts of the serous glands.

l. Lymphatic vessel in the centre of the folds.

Fig. XIX. Three taste goblets more highly magnified, about 300.

e. Epithelium around the taste goblets.

g. Basis of the goblets next to the mucosa.

h. Openings of the goblets with fine hairs.

The distinction of the cells of the goblet in taste cells and tegmental cells is not shown here.

Fig. XX. From a vertical section through a papilla circumvallata of a child. Magnifying power about 50.

a. Fold of mucous membrane surrounding the papilla itself.

p. The fungiform papilla, showing minute secondary papillæ.

Of the stratified epithelium only the nuclei of the cells are shown.

At the basis of the papilla are seen the taste goblets.

s. Serous gland; its duct opens at the base of the papilla.

m. A small section of a lobule of mucous gland between the lobules of serous gland.

b. The vascular mucosa; the holes are capillary vessels cut in different directions.

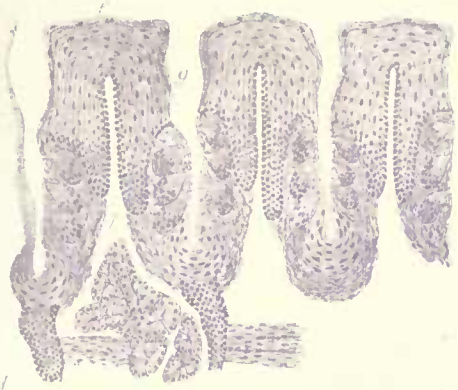

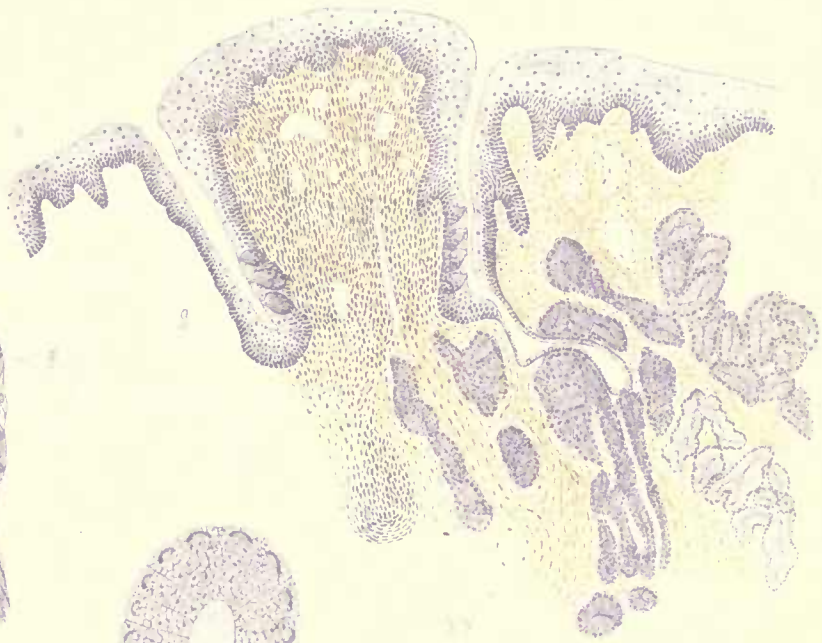

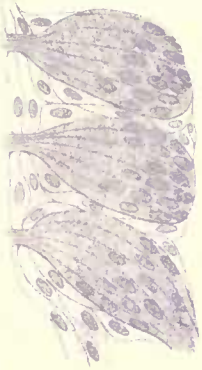

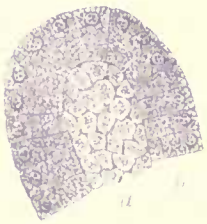

XXVIII.

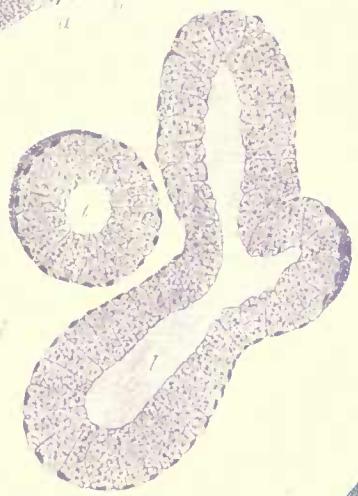

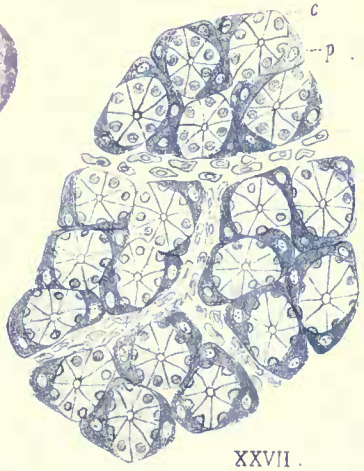



XXVII.

XXIX.

d

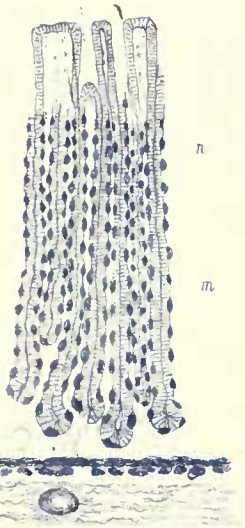

XXV.

REESE LIBRARY
OF THE
UNIVERSITY
OF
CALIFORNIA

Fig. XXI. From a vertical section through the pyloric end of the stomach of dog. Magnifying power about 150.

s. Folds of mucosa covered with columnar epithelium.

d. The glandular ducts lined with the same epithelium.

n. Region of the neck of the gland.

m. Body of the gland tubes cut in different directions.

mm. Muscularis mucosæ, here composed of three layers.

The tissue of the mucosa is here represented much denser than in reality.

Figs. XXII. and XXIII. each represent a portion of a tube of pyloric gland, the former after prolonged secretion, the latter in ordinary secretion. Magnifying power about 500.

In Fig. XXII. the intracellular network is much closer and the cell appears, therefore, more 'granular,' the nucleus is spherical.

a. The epithelial cells as seen from the surface.

b. The same as seen sideways.

In Fig. XXIII. the cells are more elongated, the meshes of the intracellular network wider, and the nucleus flattened.

Fig. XXIV. Gland tubes of a mucous gland of œsophagus of dog. Magnifying power about 400.

t. One gland tube cut transversely.

l. Another as seen in longitudinal section.

The epithelial cells lining the lumen are mucous cells. The 'crescents,' composed of nucleated opaque cells, are seen in two places.

Fig. XXV. From a vertical section through the mucous membrane of fundus of stomach (stained in aniline blue). Magnifying power about 50.

d. Ducts of peptic glands, each taking up two thin gland tubes.

The epithelium of the surface is of the same nature as in fig. XXI.

n. Region of the neck of peptic gland.

m. Body of the gland tube.

The minute lumen of the gland tube is lined with columnar 'chief cells,' outside these are the deeply stained parietal cells.

mm. Muscularis mucosæ, composed here of two layers.

s. Submucous tissue with a large vessel; between the fundus of the peptic glands and the muscularis mucosæ is a small amount of connective tissue.

Fig. XXVI. From a vertical section through the mucous membrane of œsophagus of dog. Magnifying power about 50.

e. Stratified pavement epithelium.

m. Connective tissue mucosa, possessed of numerous minute papillæ.

mm. Muscularis mucosæ, a single layer of longitudinal bundles of unstriped muscle cells.

Outside this is the submucous tissue containing mucous gland tubes *g*, cut in different directions; the wide infundibula of these pass into the ducts.

d. Ducts which after penetrating through the mucosa open with a narrow funnel-shaped mouth on the free surface.

Fig. XXVII. From a horizontal section through the mucosa of fundus of stomach of dog; the section had been stained in aniline blue Magnifying power about 400.

The peptic glands are cut transversely, they are arranged in groups separated by connective tissue including numerous unstriped muscle cells.

c. Chief cells lining the small lumen of the gland.

p. Parietal cells.

Owing to the relatively great number of the latter, this section corresponds to a part nearer to the neck than to the fundus of the gland tubes.

Fig. XXVIII. From a similar preparation to that represented in fig. XXV., but under a higher magnifying power: about 350.

d. Duct; the epithelium is the same on the free surface as in the duct, but the cells become shorter towards the neck.

n. Neck of the gland tubes, the chief cells lining the lumen are short columnar cells directly continuous with those lining the duct; the parietal cells are here very numerous.

In the body of the gland the chief cells are longer and more transparent than in the neck, and the parietal cells are less numerous.

b. Fundus of gland tubes, its cæcal extremity is slightly curved.

Fig. XXIX. From a similar preparation as the preceding figure, representing the fundus of a gland tube under a magnifying power of about 450.

c. Chief cells; their substance is a distinct reticulum.

p. Parietal cells; the cell-substance is here a much denser reticulum. The nucleus of the parietal cells is always more transparent than that of the chief cells.

CHAPTER XXVI.

THE SMALL AND LARGE INTESTINE.

The wall of the small and large intestine consists, like that of the stomach, of the mucous membrane and the external muscle coat. The former is composed of: (1) the epithelium covering the free or internal surface; (2) the mucosa, which in the small intestine projects above the general surface as the villi; in both the small and large intestine the mucosa contains simple vertical gland tubes with blind extremities in the depth and openings on the free surface, the crypts of Lieberkühn; (3) the muscularis mucosæ; and (4) the submucosa. The latter or external muscle coat includes: (*a*) an inner or circular layer of unstriped muscle cells; (*b*) a middle or nervous layer, being a dense plexus of nerve branches and ganglia, the plexus myentericus of Auerbach; (*c*) an outer or longitudinal layer of unstriped muscle cells; and (*d*) the peritoneum or serous covering.

The connective tissue of the submucosa is united with the connective tissue separating the muscle bundles of the muscle coat next to it, and the same relation exists between the connective tissue of the serous covering and that of the longitudinal muscle layer.

A. The Small Intestine.

1) The *epithelium.* This is a single layer of beautiful columnar epithelial cells. The nature of the longitudinal striation of the cell substance, and the structure of the nucleus, the change the cells undergo during mucous secretion, and the nature of the striation of the free or basilar border, have been fully described and illustrated in Chapter II. It remains here to be added, that into the hyaline interstitial cement substance between the individual epithelial cells project filamentous or membranous structures, sometimes with nuclei, a sort of reticulum, continued from the tissue of the mucosa underneath. This relation has been referred to on a former occasion (Chapter XXII.). Lymph corpuscles are also occasionally met with between the epithelial cells (Watney). Where lymph follicles (see below) extend to the free surface, the epithelium of the surface becomes invaded both by the adenoid reticulum and the lymph corpuscles of the former; under these circumstances the epithelial cells become altered, being greatly reduced in size, and changed into small irregularly shaped corpuscles in which the nucleus forms the chief part.

In Chapter XXII. it has been mentioned that absorption by the epithelium in general takes place through the interstitial cement substance, whence the fluid or formed matter passes into the lymph-canalicular system of the tissue underneath, and from there enters the lymphatic vessels. The same holds good for the epithelium covering the villi of the small intestine with reference to the absorption of chyle: for the chyle globules travel, not through the substance of the epithelial cells themselves, but through the interstitial substance, and hence through the reticulum of the matrix of the villus, and finally into the chyle vessels.

These statements are based on observations of Dr. Watney, made under my direction. Dr. Watney's paper is published in the 'Philosophical Transactions,' 1876.—E. K.

According to a generally received doctrine, the chyle globules are absorbed by the epithelial cells themselves, whence they pass into the tissue of the villus, and hence into the chyle vessel or vessels situated in the centre of the villus. This doctrine assumes that the substance of the epithelial cells becomes filled with the chyle globules, and further that it (the cell substance) is in direct continuity with the tissue underneath; and, indeed, the literature on this subject is rich in assertions maintaining these two points, although there are equally numerous observers who deny them both. As mentioned above, the substance of the epithelial cells is concerned in the mucous secretion, not in absorption, which is performed by the interstitial substance, and this latter (interstitial substance) and not the former (epithelial cells) is connected with the tissue underneath.

Amongst those who in more recent times asserted the absorption of chyle globules by the epithelial cells themselves and the passage from here into the tissue underneath may be cited Thanhoffer, who asserts that the chyle globules are taken up by the epithelial cells (of frog's small intestine) in virtue of active movement, dependent solely on the nervous system. This observer says the epithelial cells push out from their free surface minute processes, on and between which the chyle globules are caught, and then withdrawing the former also the latter are brought into the interior of the cell. By a repetition of this process the cells become gradually filled with chyle granules. In an equally splendid manner the cells are said to discharge the chyle globules into the tissue underneath, for each epithelial cell is possessed of two processes: one is in connection with the part of the tissue of the villus through which the chyle globules have to travel, and the other with a nerve fibril; and thus the control by the nervous system of the whole proceeding finds a ready explanation. As regards mammalian animals Thanhoffer's view is, no doubt, erroneous. With reference to the special influence of the nervous system on the absorption of chyle, this is an assumption which for its support requires more evidence by facts than is at present available; but this much must be said, that the whole process can be easily explained on the same simple principles as ab-

sorption in general (see Chapter XII.); viz. owing to the centripetal direction of the current in the lymphatic vessels, there is an *a priori* tendency of matter to pass from outside the lymphatic into the interior of this latter, and as both the wall of the lymphatic and the tissue surrounding it are permeable for formed matter, this latter will find its way into the lymphatic.

2) Underneath the epithelium is a *basement membrane*, which is composed of a single layer of flattened transparent endothelial plates, each with an oval nucleus, sub-epithelial endothelium (Debove, Watney).

The tissue of the *mucosa* is similar to adenoid tissue, viz. a reticulum of fibrils and membranes, to which are applied from place to place transparent endotheloid plates, each with an oval, clear nucleus; in the meshes of the reticulum are lymph corpuscles. A few coarsely granular large plasma cells may be occasionally seen amongst them. Each villus is a projection of the mucosa. Villi vary in the intestines of different animals and in different parts of the same intestine. This difference consists in their length and shape: in some cases they are much flattened, leaf-like (hedgehog); in others less flattened (man, dog, cat); in the majority of cases they are conical if short (mouse), cylindrical if long (cat, dog).

The tissue of the villi is similar to, but not identical with, that of the rest of the mucosa. It possesses in the centre one or two relatively large chyle vessels; these are in all respects identical with lymphatic capillaries, their wall being made up of a single layer of endothelial plates (v. Recklinghausen). They terminate with a blind extremity near but not quite at the summit of the villus. Along this chyle vessel or vessels run thin bundles of unstriped muscle cells (Brücke). They extend from the base to near the summit of the villus; in many places they may be traced from the tissue of the mucosa, in others this does not seem to be so. The individual cells are relatively long, like the muscle cells of the alimentary canal generally.

In a transverse section through a villus the muscle bundles appear arranged around the chyle vessel, without, however, always forming a continuous layer (Basch).

Thanhoffer mentions also circular muscle cells situated in a transverse direction on the surface of the villus immediately underneath the epithelium.

On their way towards the summit the bundles of muscle cells become much attenuated by giving off laterally individual muscle cells that terminate at the basement membrane of the sides of the villus. Those muscle cells that reach the summit terminate also on the basement membrane (Watney).

The matrix of the villus consists of a homogeneous delicate reticulum, in the meshes of which lie flattened cells of various sizes, each with an oval clear nucleus, and arranged like an endothelium (Watney). There are all gradations between these

endothelial cells and the lymph corpuscles as present in the mucosa. In some places there may be noticed a branched cell with a small nucleus included in the reticulum.

The reticulum just mentioned represents at the same time the interstitial substance for all other elements in the villus; viz. muscle cells, blood-vessels, and endothelium of the chyle vessels (Watney). It extends through the basement membrane (as the interstitial substance between its individual endothelial plates), and becomes identified with the interstitial cement substance between the epithelial cells covering the free surface of the villus.

The paths for the chyle globules are, then, these: the interstitial substance of the epithelium, the interstitial substance of the basement membrane, further the reticulum forming the matrix of the villus, and finally the interstitial substance between the individual endothelial cells forming the wall of the chyle vessel. All these substances are soft, probably semifluid in the living state, and do not present any obstacle to the passage of formed matter.

Since there exists the same anatomical continuity between the reticulum on the one hand and the interstitial substance of the endothelial cells forming the wall of a venous capillary on the other (Watney), there is no reason why the chyle globules or other matter, to be absorbed, should not pass with the same facility into the venous rootlets as into the lymphatics, since the current is in both centripetal.

At the base of the villi open the crypts of Lieberkühn. They are vertically arranged, and so closely placed side by side that only a small amount of tissue of the mucosa is found separating them. The length of the crypts varies in different parts of the intestine, the longest being found in the duodenum, owing to the greater thickness of the mucosa in this latter place. The crypts are about as long as the mucosa is thick, that is their blind extremity is almost in contact with the muscularis mucosæ.

Each crypt consists of a membrana propria, which, being a continuation of the basement membrane, is in reality an endothelial membrane (Watney). In connection with this latter, probably with its interstitial substance, are filamentous and membranous structures penetrating towards the lumen of the crypt; they form a reticulum, including a nucleus in some places, and become identified with the interstitial substance separating the columnar epithelial cells lining the crypt. These epithelial cells are identical in structure and function with those covering the free surfaces of the villi, as has been described and figured in detail in Chapter II., except that they are somewhat shorter.

3) The *muscularis mucosæ* is in many parts composed of an inner thin circular and an outer equally delicate longitudinal layer of unstriped muscle cells, but in some parts of the small intestine only a single longitudinal layer can be detected.

4) The *submucosa* is composed of trabeculæ of fibrous-connective tissue, forming

a loose meshwork; it is the carrier of the blood-vessels, nerves, lymphatic vessels and fat tissue. The structure and arrangement of the lymph follicles, which, as mentioned in a former chapter, occur as solitary or agminated glands, and in the latter instance produce the Preyer's patches, have been fully described on page 159. With their body and fundus they are situated in the submucous tissue; with their summit they are pushed through the muscularis mucosæ and reach the free surface of the mucosa, and are covered with columnar epithelium more or less altered by the ingrowth of the adenoid tissue. In the mucosa the adenoid tissue of the lymph follicles merges into the tissue of the former.

The submucous tissue of the first part of the duodenum contains the glands of Brunner. These are closely placed, and form a special layer in the submucosa next to the muscularis mucosæ. Each gland is a branched and convoluted tube (Schlemmer, Schwalbe, Heidenhain), with large lumen lined by columnar cells of exactly the same structure as those of the pyloric glands (Schwalbe, Watney and others). They undergo the same changes in their structure during rest and secretion as the cells of the pyloric glands (Hirt, Klein). The lumen of the gland tube is continued into minute *capillary channels* between the epithelial cells lining the lumen (Schwalbe, Klein). The duct emerges from the gland next to the muscularis mucosæ, passes through this and ascends in a vertical direction between the crypts of Lieberkühn of the mucosa, and opens on the free surface of this latter. The duct is narrowest at its beginning—neck of the gland—and is lined by simple columnar epithelium. The difference between a gland of Brunner and one of the pyloric end of the stomach consists chiefly in the much greater length of the duct and in the greater length and number of the tubes belonging to one gland.

The glands of Brunner are separated by thin trabeculæ of fibrous-connective tissue; bundles of unstriped muscle cells, derived from the muscularis mucosæ, pass between and outside them (Verson).

Where the pyloric end of the stomach is in contact with the duodenum the pyloric glands can be directly traced into the Brunner's glands (Cobelli, Watney), the tubes becoming larger, more numerous, and being gradually pushed from the mucosa into the submucous tissue. At the point of transition the muscularis mucosæ is generally more or less interrupted. In the dog there is a zone of appreciable dimensions that does not possess any continuous muscularis mucosæ, and in this zone the transformation of the pyloric glands into the glands of Brunner is very well shown.

With regard to the *external muscle coat* there is little to be added to what has been already mentioned; the circular layer is generally thicker than the longitudinal. The *plexus myentericus of Auerbach*, situated between the two muscle layers, is

composed of finer and thicker flat bandlike nerve branches; each of these is ensheathed in a delicate endothelial membrane, being a continuation of the perineurium of the nerve trunks entering the intestine, and is composed of a number of fine elementary nerve fibrils. A grouping of these into separate axis cylinders is nowhere distinguishable.

The plexus contains many triangular or irregularly shaped placoid enlargements, in which groups of ganglion cells are embedded. These are either closely grouped together and separated only by a few fibrils, or they are arranged in clusters or nests, or form chains and rows. These latter may be seen extending specially from the placoid enlargements into the afferent or efferent branches.

The ganglion cells vary very greatly in size, some being many times larger than others. The smallest consist of a nucleus surrounded by just a trace of cell substance; the largest ones are like ordinary full-grown sympathetic ganglion cells, from which they do not differ in structure of their cell substance and nucleus. As regards the shape of the ganglion cells, they are spherical, elliptical, or branched (unipolar, bipolar, and multipolar); only the larger ones are possessed of a capsule and processes.

From this plexus come off minute branches, which, having split into fine fibres, form secondary plexuses for the different strata of the circular and the longitudinal muscle coat. These represent the plexuses for the muscle bundles, and correspond therefore to the intermediary nerve plexuses of unstriped muscle tissue (see p. 131).

From the plexus of Auerbach pass nerve branches through the circular muscle layer into the submucous tissue, where they are connected into the plexus of Meissner. The branches of this are more cylindrical, and at the points of anastomosis they form nodular or spindle-shaped enlargements. Here are groups or chains of ganglion cells much more uniform in size and appearance than in the plexus of Auerbach; many of the ganglion cells are enclosed in a capsule, and are unipolar, bipolar, and multipolar.

From the *plexus of Meissner* originate other minute secondary plexuses of nerve fibres, most of which are destined for the bundles of the muscularis mucosæ, but there are minute networks belonging to the connective tissue and blood-vessels of the submucosa.

The *blood-vessels* are arranged in various systems according to the very different tissues forming the wall of the small intestine. The first system is that of the peritoneal covering; then the external muscle coat contains the second system; the fat tissue when that occurs in larger masses in the submucosa; the lymph follicles and the Brunner's glands (in the duodenum) contain each their own system; the muscularis mucosæ has again its own vessels, the mucosa including the villi possesses the final and most important system. In all these cases the afferent arteries or efferent veins are branches of the respective trunks, entering the intestine at the mesenteric margin.

The arterial and venous trunks found in the submucosa give off or take up respectively the vessels for all the above systems present between the epithelium of the inner surface and the external muscle coat.

The distribution of the capillaries in the peritoneal covering is the same as in the mesentery, viz. uniform networks with rather large meshes ; those of the external muscle coat and the muscularis mucosæ are arranged as in other unstriped muscle tissue, viz. networks with elongated meshes. The capillary network of the fat tissue is the same as in fat tissue of other parts (see Chapter VI.).

In the solitary and agminated lymph follicles the capillaries form a network with elongated meshes and radiating towards the centre, where they generally form loops. Around the individual follicles minute veins are found arranged as a special network.

The arterioles passing through the muscularis mucosæ into the mucosa give off numerous capillaries, forming a network around the crypts of Lieberkühn ; their meshes are elongated and vertical to the surface ; the arteriole passing into the villus ascends generally to near the apex, except in man, where it does not as a rule pass beyond the lower half (Heller). It dissolves itself into a dense network of capillaries, spreading over the apex and base of the villus ; in the former the network is much denser than in the latter.

The capillaries of the villus are always situated in the periphery next to the epithelium. The network of capillaries of the villus forms a continuity with that of the rest of the mucosa (Toldt).

There are generally one or two veins developed from the capillaries of the villus. According to Heller, the vein generally commences near the apex of the villus in man and rabbit, while in dog, cat, pig and hedgehog it originates near the base.

The *lymphatics* of the small intestine are very numerous. They are :

a) The lymphatics of the villi. As has been mentioned above, each villus has a central single chyle vessel, or two such vessels, anastomosing with one another. They correspond to large lymphatic capillaries, beginning with a blind extremity near the apex of the villus ; the reticulum of the surrounding tissue is connected with the interstitial substance of the endothelial wall and represents the rootlets for the chyle vessel. At the basis of the villus the chyle vessel is generally much narrower and anastomoses with the network of lymphatic capillaries and sinuses between the Lieberkühn's crypts (Frey and others).

Absorption by the chyle vessels is in a great measure supported by the peculiar relation existing between the blood-vessels of the villus and its chyle vessel, for during digestion the former are in a state of great turgescence, and owing to their peripheral disposition will necessarily keep the villus erect : the central chyle vessel is hereby, of course, kept distended.

b) The lymphatics of the rest of the mucosa appear as a network of finer and broader capillaries and sinuses; these latter surround in many places the crypts of Lieberkühn to a greater or smaller extent. Just below the fundus of the crypts of Lieberkühn this network of lymphatics is denser and more easily visible.

c) These lymphatics send their efferent branches into the submucosa, where they join larger lymphatic tubes with valves : they are connected into a network. When there are lymph follicles, they (tubes) take up the lymph sinuses surrounding a greater or smaller section of the surface of the basis of the follicles (His, Frey, and others), (see p. 164).

d) While the efferent trunks of the submucous lymphatics penetrate through the external muscle coat, in order to reach the mesenteric margin, they take up the lymphatic system of the former. This system is a network of lymph capillaries situated between the circular and longitudinal layer ; they take up straight channels and clefts between bundles of unstriped muscle fibres, chiefly of the circular layer. These channels are lined with endothelium, possess no valves, and their arrangement is, of course, parallel with the direction of the bundles.

e) The peritoneal covering possesses its own network of lymphatics, the efferent trunks of which join the large lymphatics in the mesenteric margin. The subserous lymphatics take up many lymphatic channels and clefts of the adjoining longitudinal muscle layer.

The blood-vessels of the muscle coat are occasionally seen invaginated in a perivascular lymphatic, representing one of the above-named lymph channels or clefts between muscle bundles.

B. The Large Intestine.

The structure of the large intestine is in many respects identical with that of the small intestine, only slight differences existing between the two.

The epithelium covering the inner surface, the mucosa and the crypts of Lieberkühn, possess the same nature in both organs ; there are no villi, but in some instances, as in the colon of rabbit, the mucosa is raised in the form of minute permanent papillæ, but these are altogether different from villi of the small intestine, for they (papillæ) contain crypts of Lieberkühn like other parts of the mucosa. Of interest are the bundles of unstriped muscle cells, ascending into these papillæ and terminating at the basement membrane (Watney).

The muscularis mucosæ consists in most places of an inner circular and an outer longitudinal layer. Minute bundles may be occasionally seen branching off from the inner layer and ascending between the crypts of Lieberkühn.

The submucosa contains, as a rule, more fat-cell tissue than the small intestine, but otherwise shows the same structure. The lymph follicles occur usually as solitary follicles; they are much larger than in the small intestine, and are either pushed through the muscularis mucosæ with their summit, or, what is in some large intestines (pig) more commonly the case, the mucosa with its crypts of Lieberkühn is, to a greater or smaller extent, drawn down into the lymph follicle through a discontinuity of the muscularis mucosæ. In these instances there is, consequently, to be found a pit lined with crypts of Lieberkühn, and leading into the depth to the lymph follicle. In man and carniverous animals a relation resembling this is occasionally met with. The abundance of lymph follicles and their arrangement (as Peyer's patches) in the cæcum of rabbit have been described and figured on p. 169.

The processus vermiformis of man contains numerous lymph follicles, closely placed and arranged like those of the Peyer's patches of the small intestine.

The external muscle coat of the cæcum and colon differs in so far from that of the small intestine that in some parts the circular and longitudinal layer is very thin or altogether wanting; in the septa of the well-known sacculi the circular bundles form groups, and similarly the so-called ligaments represent accumulations of longitudinal bundles. In the rectum, whose mucosa is of conspicuous thickness, the external muscle coat is well developed, the circular layer being of great thickness.

The nervous apparatus is the same as in the small intestine, except that the submucous plexus of Meissner contains larger ganglia than that of the small intestine, and that the ganglion cells appear smaller in the former than in the latter.

The plexus of Auerbach of the large is more developed than that of the small intestine, the nerve branches being more numerous, the plexus denser, and the ganglionic enlargements greater. In the toad I have observed large isolated multipolar ganglion cells situated in the meshes of the general plexus; some of their processes are connected with the branches of this, while others pass as fine fibrils directly amongst the muscle bundles, forming on these a more or less distinct transparent plate-like expansion.

The distribution of blood-vessels and lymphatics is very similar to that of the small intestine.

CHAPTER XXVII.

THE PANCREAS.

THE structure of the pancreas differs to a considerable extent from that of the salivary glands. The two are, however, similar as regards the framework, the blood-vessels and lymphatics. A thin *capsule* of fibrous tissue gives off lamellæ of the same tissue; these penetrate as *septa* between the lobes and lobules into which the gland substance is divided. The amount of this connective tissue varies in different animals; in man it is greatest and therefore the arrangement of the gland into lobes and lobules can be easily followed. From the interlobular connective tissue proceed very delicate bundles of fibrous tissue, but especially the flattened branched connective-tissue corpuscles; these are continued into the interior, where they may be traced, in company with the capillary blood-vessels, between the gland alveoli.

The interlobar and interlobular connective tissue gives also support to the larger branches of the arteries and veins, and it contains nerve branches and large lymphatics with valves. These latter take up lymphatic clefts and sinuses lined with endothelium and situated between the lamellæ of connective tissue passing in between sections of a lobule. In man these lymphatic clefts are easily demonstrated and also the sinuses which surround parts of the circumference of the alveoli.

As regards the distribution of blood-vessels the same relations prevail as in the salivary and other glands, viz. the arterioles dissolve themselves into a uniform network of capillaries closely surrounding the alveoli.

The *gland tissue* consists of the large or lobar ducts, which take up the small or intralobular ducts; these are much branched and take up longer or shorter branched thin canals which correspond to the intermediary parts of the ducts; these lead directly into the alveoli.

The lobar ducts are tubes with large lumen, their wall is a membrana propria lined with short columnar epithelial cells, each with an oval nucleus near the membrana propria. The cells are shorter than in the ducts of the salivary glands, and their substance is very finely and longitudinally striated. Outside is a smaller or larger amount of fibrous-connective tissue; the pancreatic duct and its larger branches possess in their wall unstriped muscle cells.

The intralobular ducts are similar to the former, except that they are much smaller:

their epithelium being shorter and the lumen smaller, and the fibrous tissue around them much less in amount. The substance of the epithelial cells is transparent, and does not show, like that of the cells lining the intralobular ducts of the salivary glands, thick rodlike fibres. The nucleus of the cells is more or less spherical.

The intermediary parts are branched canals of various lengths with a small, but distinct lumen; each consists of a membrana propria, a continuation of the same membrane of the intralobular duct, lined with a single layer of flattened clear cells more or less elongated, and each with a flattened oval nucleus (Langerhans, Teraszkievicz). The intranuclear network is very well seen.

These cells are continuous with the lining cells of the intralobular ducts.

The length of the intermediary canals varies in different parts: while in some lobules they and their branches may be traced for a considerable distance, in others they are extremely short, the branches of the intralobular ducts appearing to pass almost immediately into the alveoli. The intermediary tubes in the pancreas of rabbit are very long (Langerhans).

The alveoli are branched tubes, very wavy and much convoluted. They are limited by a membrana propria of the same structure as that of the salivary glands (see the chapter on salivary glands), lined with a single layer of beautiful columnar cells; these are either cylindrical or blunt conical with their narrow end in the centre of the alveolus. Their substance shows a marked distinction into an inner and outer part (Langerhans, Heidenhain); the outer part (that is the one next the membrana propria) is homogeneous in aspect and stains better with dyes; the inner appears more granular and does not stain readily (Heidenhain). The nucleus is spherical and is placed in the outer part where this is in contact with the inner part. These two zones of the epithelial cells differ in structure in this manner: while the outer zone is composed of very fine longitudinal fibrils (Pflüger, Heidenhain), the inner, viz. the one that appears coarsely granular and is described as such by Langerhans and Heidenhain, is in reality a network of thick short rods (Klein). When viewing this part of the cell substance in an oblique manner the rods are very clearly seen; viewed from the top they appear as closely placed coarse granules of uniform size. The nucleus contains a distinct network.

According to Heidenhain the cells alter their appearance and size in different stages of digestion in this way: in the first stage of digestion the cells as a whole become smaller owing to a diminution (exhaustion) of the inner or granular zone, but the outer zone appears at the same time slightly larger; in the second stage a regeneration takes place of the granular inner zone at the expense of the homogeneous outer one; this latter considerably decreases, but the cell as a whole increases greatly in size.

Kühne and Lea, observing the pancreas of rabbit during life, noticed that during

hunger the outline of the gland tubes is quite smooth, while during digestion it becomes irregular, being notched-in, corresponding to the outlines of the lining epithelial cells. This condition can be easily confirmed in hardened specimens. They also noticed that the striation of the outer zone of the cells is more distinct during digestion.

The cells are separated from one another by a thin layer of a homogeneous interstitial substance, which corresponds to the ultimate or capillary secreting canals (Latchenberger and others; see the reference to the various assertions as regards the pancreas and salivary glands in Chapter XXIII.).

The centre of the alveoli is occupied by the same interstitial substance, there being visible, as a rule, no distinct lumen or only a trace of such an one. In all parts of the gland tubes the place of the lumen is occupied by spindle-shaped or branched cells, each with an oval nucleus, the centroacinar cells of Langerhans. It is difficult to definitely ascertain whether these centroacinar cells are continuations of the cells of the intermediary parts of the ducts (Langerhans, Teraszkievicz) or not; if the former be the case, the epithelial cells lining the alveoli would be altogether independent of those lining the intermediary part, and the latter would, then, be continuous with the alveoli only by means of the membrana propria and the centroacinar cells.

CHAPTER XXVIII.

THE LIVER.

THE *framework* of the liver is composed of the capsule, the inter- and intralobular connective tissue.

The capsule is fibrous-connective tissue, covered with endothelium on its free surface; like that of other serous membranes, it consists of trabeculæ of connective-tissue bundles crossing each other in various directions, and between them are the flattened branched connective-tissue corpuscles. In man the connective tissue of the capsule forms two distinct strata (Theile), an outer, containing in the matrix of fibrous-connective tissue networks of elastic fibrils, and an inner stratum, more lamellar in its structure and continuous with similar masses of connective tissue separating the lobules.

The latter, viz. the interlobular tissue, or the tissue of the portal canals (Glisson's capsule), is also more or less lamellar, the bundles of the individual lamellæ running in various directions; between the lamellæ are the flattened branched connective-tissue corpuscles in their respective interfascicular lymph spaces, and in very young livers in addition a few migratory cells.

The interlobular connective tissue forms the supporting tissue for the blood-vessels, lymphatics, nerves, and bile ducts.

The arrangement of the interlobular tissue determines the size and shape of the lobules or acini. According to whether this tissue forms complete septa between the lobules or not, these latter appear well defined from one another (pig), or more or less confluent (man and many other mammals). In the former case the lobules are polygonal, more or less oblong or cubical, in the latter their outline is very irregular.

The intralobular connective tissue is very delicate and scarce, it consists of:

a) Flattened branched connective-tissue cells (Fleischel, Kupffer) situated between liver cells and blood capillaries. These corpuscles are continuous with each other in a network, and at the margin of the lobules also with those of the interlobular tissue.

b) There is a small amount of fibrous-connective tissue around the intralobular or central vein; this (connective tissue) is a continuation of the fibrous tissue surrounding or supporting the hepatic vein.

c) Minute bundles of fibrous tissue extend between the interlobular connective

tissue and the tissue surrounding the central vein of each lobule (Fleischel, Ewald and Kühne).

Asp, and especially Peszke, mention also the existence of a network of fine fibrils, probably of the nature of elastic fibrils.

The *blood-vessels.* The interlobular branches of the portal vein, at the margin of the lobules, give off the exceedingly numerous capillaries for the latter; these are extending in a direction radiating towards the central vein into which they open. These radiating or longitudinal capillaries are connected by transverse or horizontal branches into a network. The transverse branches are in some livers more numerous (man, especially dog) than in others (rabbit); in the former instances the meshes of the capillary network are more uniform, in the latter they are oblong, of course in a radiating direction.

The branches of the hepatic artery are interlobular and accompany the branches of the portal vein, which latter in some places are surrounded by them (arteries) as by a plexus; they anastomose with one another in many places, and finally give off capillaries for the connective tissue of the portal canals and all the structures embedded in it, especially the bile ducts (Kowalewsky). They lead into special veins (Ferrein), which accompany in couples (Beale) the arteries and join the interlobular branches of the portal vein. According to many observers the capillaries and veins derived from the hepatic artery join the capillaries of the lobules directly; and according to Kowalewsky this takes place by the anastomosis of the blood capillaries of the bile ducts, or of the venous branches proceeding from them, with the capillaries of the lobules at the margin of the latter. But according to Cohnheim and Litten the number of capillaries, derived from the hepatic artery, and anastomosing with the capillaries of the lobules, is but a small one.

The capsule of the liver possesses its own branches of the hepatic artery, viz. the rami capsulares: these dissolve themselves into a dense network of capillaries, possessing in some places a stellate arrangement.

The *gland substance proper* is arranged as the tissue of the lobules or acini, and as the bile ducts. Each lobule consists of small polygonal epithelial cells, the liver cells, permeated by the above-named capillary blood-vessels. These two structures, viz. liver cells and capillary blood-vessels, represent the chief parts of the lobule; the branched connective-tissue corpuscles and the very few fine bundles of fibrous tissue, especially around the central vein, form only a small addition. There is no membrana propria separating the liver cells from the capillary vessels. The liver cells in man and mammals are arranged neither as a network of 'cylinders' or 'trabeculæ' radiating towards the central vein and separated by the capillary vessels, nor as a compound tubular gland in

the ordinary sense, but they form within each lobule *one continuous mass of cells permeated only by the capillary blood-vessels* (Hering); owing to the peculiar arrangement of the latter a vertical section through the lobule shows a network of longer radiating and short transverse masses of liver cells. The latter are about of the same size throughout the liver, but there are some, especially near the margin of the lobules, that are smaller than the rest. Their shape is polyhedral (in section pentagonal or hexagonal) or sometimes slightly elongated, their surface smooth and separated by a hyaline interstitial substance. Kolatschewsky isolated liver cells that were possessed of processes.

The substance of the cells appears uniformly granular, but is in reality a beautiful honeycombed network (Kupffer, Klein). It is probable that during activity the meshes of the intracellular network are larger, and hence also the cell as a whole becomes enlarged. Each cell possesses one spherical or slightly oval nucleus; in the liver of rabbit it is common to find cells with two nuclei; in some livers there are liver cells without any nucleus (Asp, Peszke). The nucleus is limited by a thin membrane, and includes an intranuclear network, in which occasionally one or two thickenings, nucleoli, are seen. The intranuclear network forms a continuity with the intracellular one; the network of contiguous cells is likewise in connection with one another (Klein).

Besides the liver cells and capillary blood-vessels there are in each lobule numerous minute cylindrical canals, the *bile capillaries*, which form a network closed in itself (Hering). These bile capillaries run between the contiguous liver cells, so that the meshes of their network are of the size and shape of the cells (Hering, Eberth, Kölliker). The bile capillaries when viewed in section are found in the angle where three or more liver cells meet (Eberth, Peszke). They are never present between liver cells and capillary blood-vessels (Hering, Peszke). Owing to the radiating arrangement of the whole mass of the liver cells, we meet in many places with bile capillaries extending for a considerable distance, in a similar, i.e. radiating, manner, and giving off short lateral branchlets; this gives rise to the appearance, as it were, of long chief bile capillaries and short lateral secondary branchlets.

Some observers assume a special delicate membrana propria forming the wall of the bile capillaries (MacGillavry, Chrzonszewski, Asp, Peszke, Davis and others), while Hering, Eberth, Kölliker and others deny the existence of a definite membrane, as that, for instance, forming the membrana propria of other gland ducts, and assume that the liver cells themselves form the immediate boundary of the bile capillaries.

The *bile ducts* are situated in the interlobular connective tissue; they are the efferent ducts: tubes with a relatively large lumen, a lining columnar epithelium and a limiting membrana propria with regularly disposed oblong nuclei in it, most probably owing to its being an endothelial membrane. The largest ducts are surrounded

by unstriped muscle cells (Heidenhain). The epithelium lining the small ducts is made up of short columnar cells, that of the large ducts is distinctly columnar. The bile ducts form a network amongst themselves (Beale). At the margin of the lobule the small ducts are much branched; their branches are narrow tubes with a very small lumen, and are lined with a single layer of small more or less flattened epithelial cells; a distinct membrana propria forms the outer boundary. These so constructed tubes correspond to the *intermediary portion* of the ducts of other glands (see previous chapters).

Now, the intermediary portion of the bile ducts joins the substance of the lobule in this manner: the lumen of the former passes directly into the network of bile capillaries, while the flattened epithelium, changing of course suddenly its appearance and nature, forms a direct continuity with the mass of the liver cells. At the point of the union of these two the difference between the respective cells is sufficiently striking: the cell-body and nucleus of the liver cells are much larger than the corresponding parts of the cells of the intermediary duct; the nucleus of the latter forms the most conspicuous part of the cell, it stains deeply in dyes and is surrounded by very little cell substance; the breadth of the whole intermediary tube is greatly inferior to the diameter of two liver cells. The membrana propria is not continued into the lobule on to the surface of the liver cells, as is maintained by Beale, Pflüger and others.

The interlobular connective tissue, as well as the capsule of the liver, possesses networks of *lymphatics*; those of the latter, viz. the superficial lymphatics, form an exceedingly dense network of fine vessels, denser even than the blood capillaries of the branches of the hepatic artery (Hering). With this network communicates the network of the deep lymphatics, viz. those situated in the connective tissue of the portal canals; the vessels of this system are fine and large vessels; the latter have valves. Networks of these interlobular lymphatics surround the branches of the portal vein as well as those of the hepatic vein (Kölliker, v. Wittich), and also the branches of the hepatic duct (v. Wittich). According to Budge and Kowalewsky branches of the hepatic vein are completely ensheathed in lymphatic vessels; a fact easily confirmed. The fine interlobular lymphatic vessels are, at the margin of the lobules, in communication with minute spaces extending between the liver cells and the capillary blood vessels (MacGillavry, Frey and others), and containing the branched connective-tissue corpuscles mentioned above. Under normal conditions these intralobular lymph spaces are very insignificant, but may become much distended and conspicuous under abnormal conditions through accumulation of fluid or formed matter. According to Kisselew and Chrzonszewsky small lymph follicles may be present in the interlobular connective tissue.

The wall of the large branches of the *hepatic duct* consists of a mucous membrane

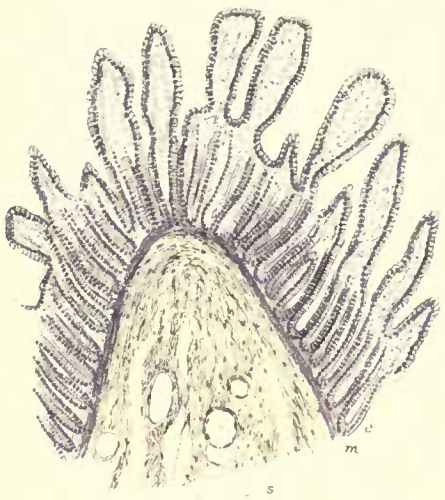

I

II

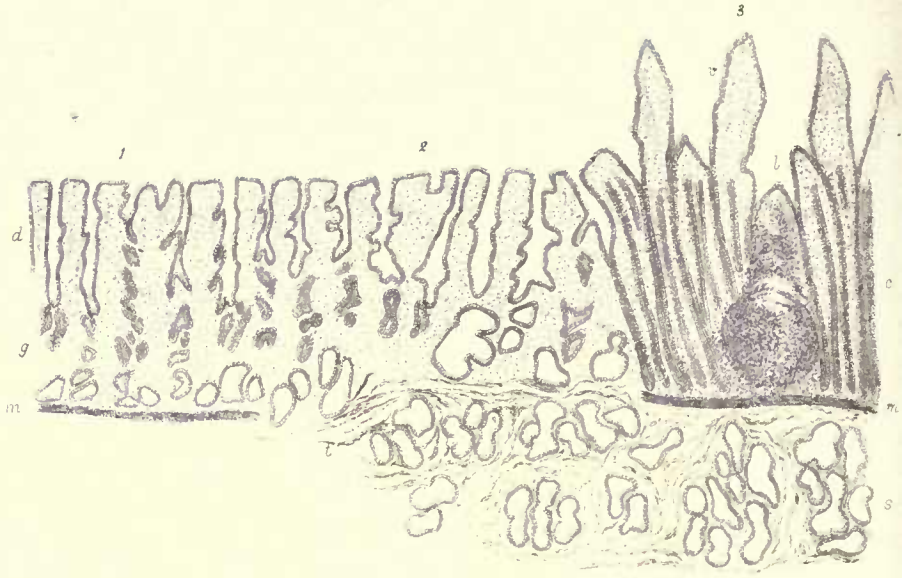

III

IV

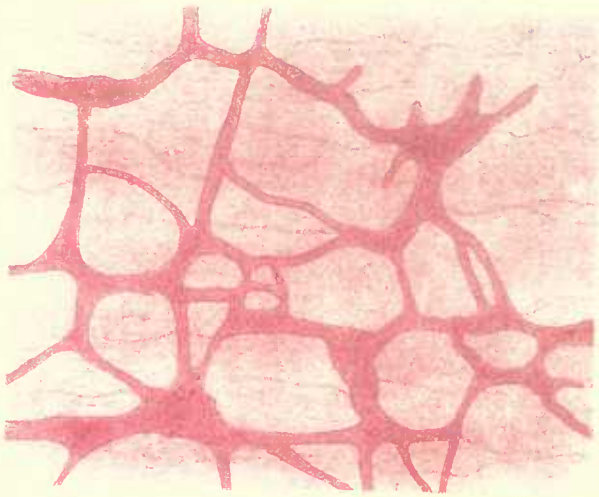

V

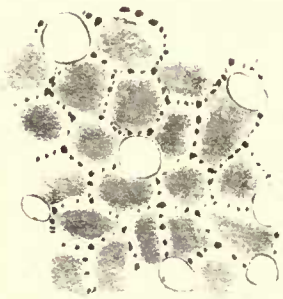

VI

VII

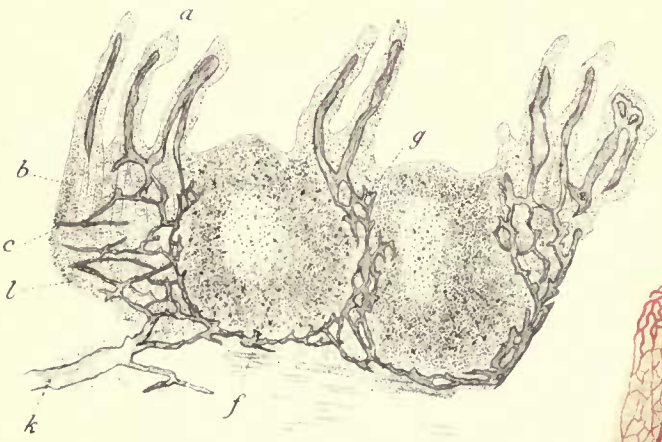

VIII

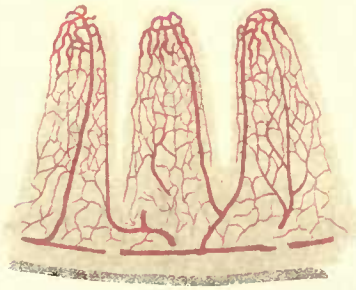

IX

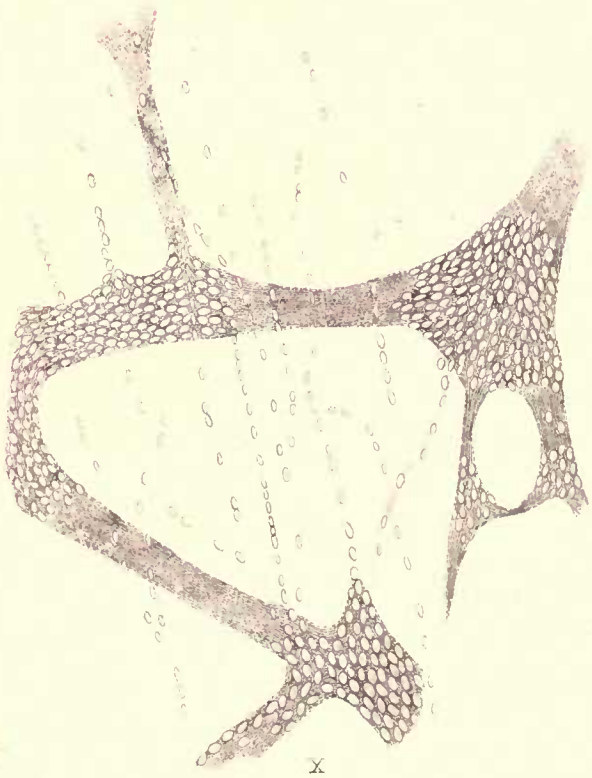

X

of loose connective tissue with numerous capillary blood-vessels and lined with a single layer of beautiful columnar epithelium; in the mucous membrane are shorter or longer tubular mucous glands (Riess, Kölliker). The larger the duct the longer these glands. Outside the mucous membrane are unstriped muscle cells (Henle), chiefly arranged as circular bundles.

The *gall bladder* is similar in structure to the large hepatic ducts, except that the mucous membrane is much thicker and possessed of folds and villous projections; the muscle coat is thick and surrounded by a considerable amount of connective tissue which is continuous with the most external layer, viz. the peritoneum. The vascular supply to the wall of the gall bladder is very rich, the capillary blood-vessels forming a very dense network underneath the single layer of fine columnar epithelial cells lining the inner cavity.

The inner portion of the mucous membrane contains an irregular network of fine lymphatic vessels (Deutsch). These vessels lead into a network of lymphatic trunks possessed of valves and belonging to the outer part of the wall of the gall bladder, viz. to the serous covering.

PLATE XXXIV.

Fig. I. From a vertical section through a fold of the mucous membrane of jejunum of dog. Magnifying power about 45.

c. Mucosa containing the crypts of Lieberkühn; the structure of the villi is only indicated.

m. Muscularis mucosæ; here a single (longitudinal) layer.

s. Submucous tissue containing the large vessels.

Fig. II. Part of a crypt of Lieberkühn, showing the septa extending from the membrana propria between the lining epithelial cells; these latter are only just indicated. The lower part of the crypt is cut longitudinally, the upper obliquely. Magnifying power about 350.

Fig. III. Vertical section through the end of stomach and commencement of duodenum of dog. Magnifying power about 45.

1 and 2. End of the stomach.

3. The commencement of the duodenum.

1. Shows the ordinary structure of the pyloric end, as illustrated in Plate XXXIII., fig. XXI.

2. The transition is shown of the pyloric glands into Brunner's glands; the muscularis mucosæ is here interrupted. This section (2) is somewhat longer in reality than here shown. Its length has been reduced on account of want of space.

d. Ducts of the pyloric glands.

g. The gland tubes cut in different directions.

m. Muscularis mucosæ.

v. Villi.

c. Crypts of Lieberkühn.

l. A solitary lymph follicle.

s. Submucosa, containing the glands of Brunner.

Figs. IV. VI. and VII. copied from Watney, 'Philosophical Transactions,' 1876. II.

Fig. IV. Part of a villus of a hedgehog killed during absorption of fat. The intestine was hardened in osmic acid. Magnifying power about 450.

l. Chyle vessel filled with chyle globules.

The matrix of the surrounding tissue shows the minute (black) chyle granules in the reticulum or interstitial substance.

Fig. V. Part of the plexus myentericus of Auerbach, from the small intestine of a new-born child. Magnifying power about 45.

The details of structure are shown in fig. X.

Fig. VI. From the same intestine as figure V., representing a surface view of the epithelium covering a villus; the section had been treated (after osmic acid staining) with caustic potash. The chyle granules (black) are contained, not in the epithelial cells themselves—seen here endwise as dark shaded polygonal zones—but in the interstitial or cement substance between these cells. The clear spaces are the openings of goblet cells. Magnifying power about 850.

Fig. VII. From a section through a villus of duodenum of dog. Magnifying power about 550. The figure represents a small portion of the tissue of a villus near the summit, which is supposed to lie on the right.

l. Central chyle vessel; the nucleated endothelial plates of its lower wall are indicated.

m. Unstriped muscle cells running alongside of the chyle vessel towards the apex of the villus.

v. Blood capillary in transverse section. The nucleated endotheloid cells around the blood and chyle vessel belong to the stroma of the villus, and together with the fine reticulum or interstitial substance between them form its principal constituents.

Fig. VIII. Copied from Fry's 'Histology,' fig. 109, showing the distribution of the lymphatic vessels in the villi, mucous and submucous tissue. Vertical section through part of a human Peyer's patch.

a. Intestinal villi with their central chyle vessel or vessels.

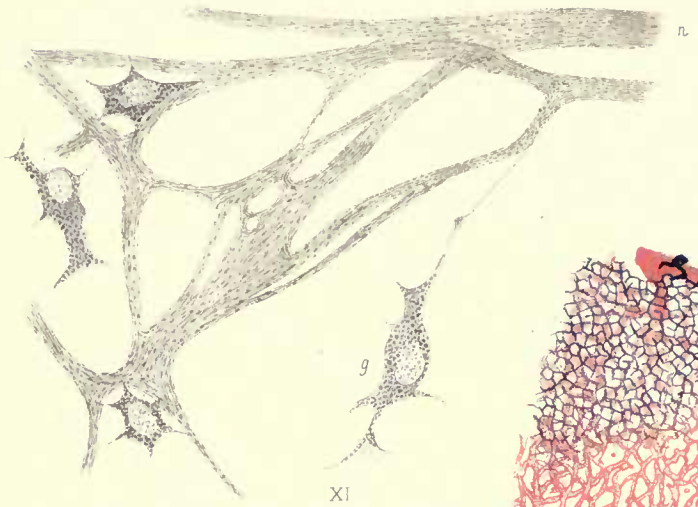

XI

XII

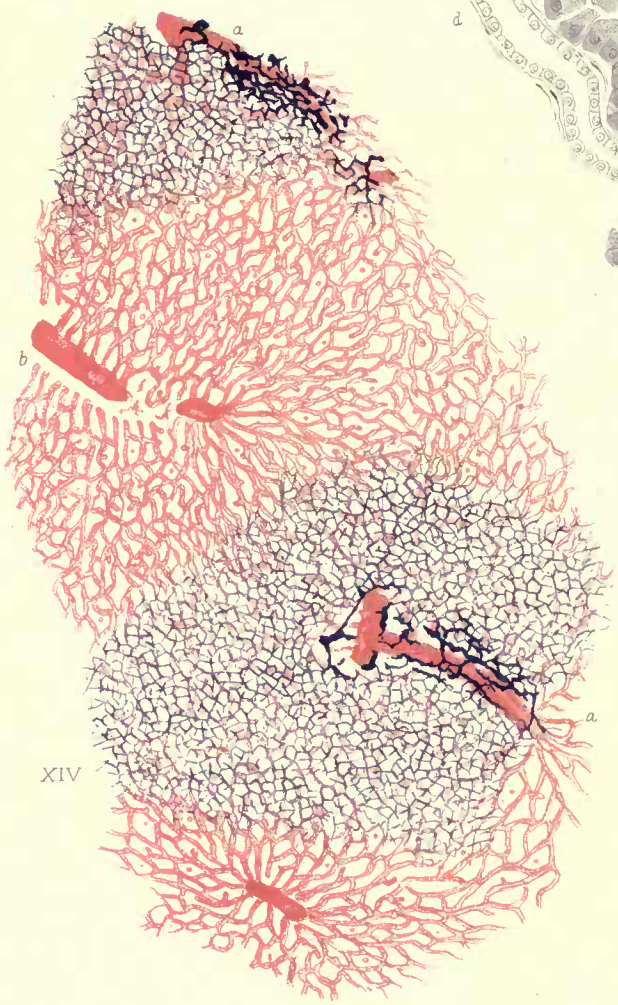

XIV

XV

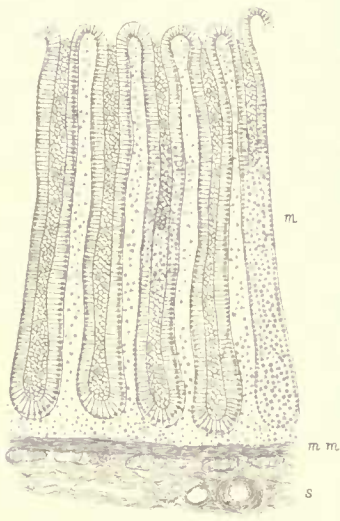

XIII

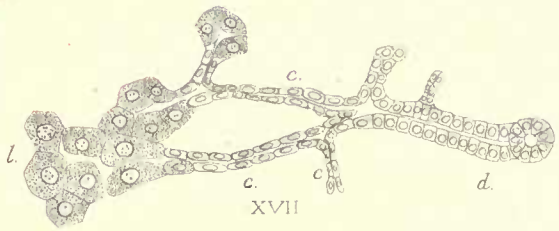

XVII

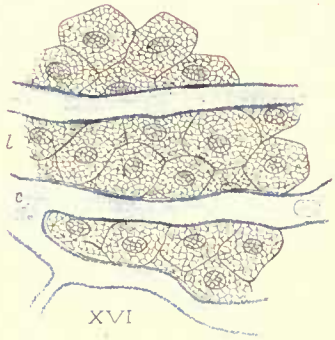

XVI

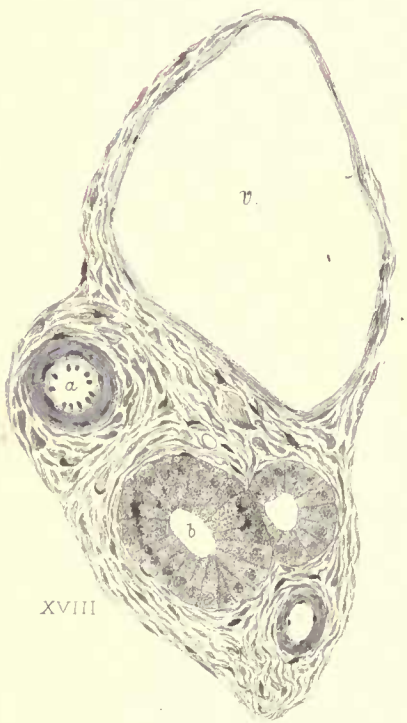

XVIII

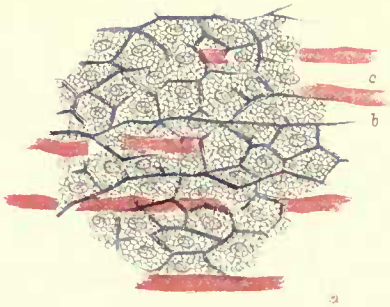

XIX

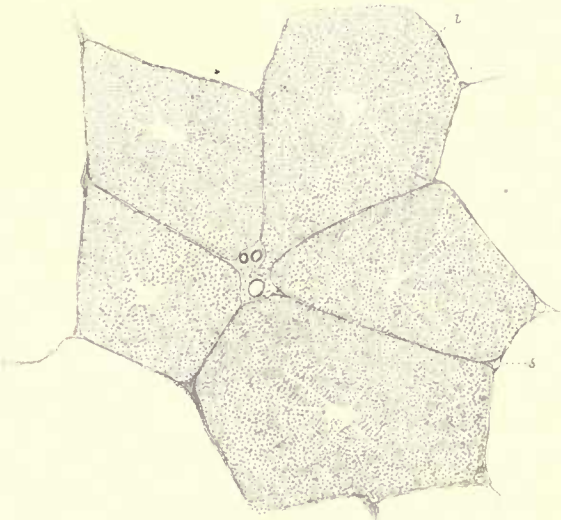

XX

b. Lieberkühn's crypts.

c. Muscularis mucosæ.

f. Lymph follicle.

g. Lymph passages around the follicle.

l. Lymphatic network of the submucosa.

k. An efferent lymphatic trunk.

Fig. IX. From a vertical section through small intestine of mouse; the blood-vessels are injected with carmine gelatin. Magnifying power about 45. The arterial trunks of the submucosa give off the arteries for the villi; from the dense network of capillaries of each villus a vein is seen to emerge near the apex and to pass down into the submucosa.

Fig. X. From the same preparation as fig. V., but more highly magnified, about 350.

The placoid enlargements of the nerve branches, filled with very minute ganglion cells, are well shown; the ganglion cells are so closely placed that only their relatively large clear nuclei are here seen. The nerve branches give off minute fibres with nuclei connected into secondary plexuses.

PLATE XXXV.

Fig. XI. Plexus of Auerbach in rectum of toad. From a preparation stained first in cloride of gold and afterwards in hæmatoxylin. Magnifying power about 350.

n. Nerve branches composed of elementary fibrils.

g. Large multipolar isolated ganglion cells.

Fig. XII. Part of a lobule of the pancreas of dog during digestion. Magnifying power about 350.

The gland substance is composed of branched, wavy tubes; many of them passing in an upward or downward direction are cut away transversely or obliquely.

d. Terminal part of duct or the intermediary part, lined by polyhedral transparent epithelial cells. In many instances, however, this epithelium is made up of cells more flattened than is here the case.

a. The alveoli or gland tubes.

Each epithelial cell of the latter shows very well the distinction into an inner 'granular' and outer homogeneous part containing the nucleus, and staining deeply in hæmatoxylin.

The cells are separated by a considerable amount of transparent interstitial substance. There is hardly any distinct lumen visible in the alveoli, but several nuclei

indicating the centroacinar cells ; these are transparent and spindle-shaped, but are not shown here.

The transition of the epithelium of the intermediary part of the duct into that of the alveoli is represented here as a direct one, but in the preparation it does not appear quite so clear; see the text.

Fig. XIII. From a vertical section through the mucous membrane of the large intestine of dog. Magnifying power about 100.

m. Mucosa containing the crypts of Lieberkühn ; these are separated by the adenoid tissue of the mucosa.

mm. Muscularis mucosæ, consisting of an inner circular (cut longitudinally) and an outer longitudinal layer (cut transversely).

s. Submucous tissue with large vessels.

Fig. XIV. From a vertical section through the liver of rabbit, after an injection of the bile vessels with Berlin blue and of the portal vein and its capillaries with carmine gelatin; showing the greater part of two adjoining lobules. Magnifying power about 90.

a. Interlobular veins.

b. Central vein.

The interlobular branches of the portal vein are surrounded by a network of (interlobular) small bile ducts. These take up the intralobular or bile capillaries forming a network, the meshes of which are polyhedral, and correspond to the outlines of the liver cells.

The blue injection did not penetrate farther than about the middle of the lobules, that is, midway between the interlobular and central vein. The bile capillaries of the tissue surrounding the latter are therefore not injected. The blood capillaries form a dense network, more or less radiating from the interlobular to the central vein. The liver cells are not represented.

Fig. XV. A part of a lobule of a similar liver as in the preceding figure, but more magnified, about 250. The section is, however, not vertical, but horizontal. In consequence of this many blood capillaries appear cut transversely.

b. Bile capillaries.

c. Blood capillaries, cut longitudinally.

n. The same in transverse section.

The liver cells are not shown here, but fill up all the space between bile capillaries and blood capillaries.

Fig. XVI. From a section through a lobule of liver of guinea pig. Magnifying power about 450.

l. Liver cells; the intracellular and intranuclear networks are very distinct.

c. blood capillaries injected with Berlin blue.

Fig. XVII. From a section through liver of guinea pig, showing the transition of the interlobular bile duct *d* through the intermediary part *c* into the liver cells *l* at the margin of the lobule.

The canal of the intermediary part passes into the bile capillaries while its flattened cells become continuous with the liver cells.

Fig. XVIII. From a vertical section through liver of dog, showing the tissue of a portal canal in transverse section. Magnifying power about 350.

a. Artery.

b. Bile duct lined with columnar epithelium.

v. Interlobular vein.

The matrix is formed by bundles of fibrous-connective tissue cut in various directions, because running under different angles.

Fig. XIX. From a lobule of the same liver as fig. XIV. Magnifying power about 350.

b. Bile capillaries between the liver cells.

c. Capillary blood-vessels.

Fig. XX. From a vertical section through the liver of pig. Magnifying power about 25.

Five lobules are shown well separated from one another.

i. Intralobular or central vein.

s. Interlobular connective tissue or the tissue of the portal canals.

CHAPTER XXIX.

LARYNX AND TRACHEA, BRONCHI AND LUNG.

1. The Larynx.

The support of the epiglottis is formed by the reticular or elastic cartilage with its fibrous perichondrium, described and figured in Chapter VIII.

The anterior surface is covered with stratified pavement epithelium; this in no way differs from that found in the neighbourhood of the epiglottis, viz. root of tongue or pharynx; the mucous membrane underneath the epithelium is fibrous tissue of loose texture, containing a network of numerous and wide lymphatics. The part next the epithelium, the mucosa, is densest and projects in the form of numerous small papillæ into the epithelium. The network of capillary blood-vessels is distributed in this superficial portion of the mucous membrane. In the deep or submucous portion, that is the one close to the perichondrium, are imbedded (in man) small branched tubular mucous glands, whose ducts pass in an oblique direction to the free surface, and open here with a wide mouth. In carnivorous animals the glands are very rare. The structure of these glands and their duct is similar to that of the glands of the pharynx and œsophagus.

The large lumen of the gland tubes of the epiglottis and other parts of the larynx are lined with epithelial cells, which are either: columnar transparent 'mucous' cells, each with a flattened nucleus, like those of the gland tubes in the oral cavity (see p. 196), or: they are columnar cells the substance of which is apparently granular and longitudinally striated, the intracellular network being dense and pre-eminently longitudinal; the nucleus is spherical and lies in the outer third; or: the two kinds of cells are side by side in the same tube. There are also tubes in which, outside the lining 'mucous' cells, are 'crescents' of granular polyhedral cells (Heidenhain, Tarchetti, Klein). The difference between the two kinds of cells has been described on a former occasion, and it has been stated to consist in the fact that the former are in a state of secretion (the intracellular network distended by mucigen or mucin) while the latter are in a state of rest or exhaustion. The duct is lined with a layer of beautiful columnar cells, and outside this is generally a layer of small polyhedral cells.

The mucous membrane covering the posterior surface, although similar to that of the anterior surface, differs from it in certain essential points, and hence the two may be readily distinguished. The differences are as follows: (*a*) the stratified pavement epithelium is distinctly thinner than on the anterior surface; (*b*) the mucous membrane extends into the epithelium as small papillæ, which are shorter and fewer than on the anterior surface; the texture of the mucous membrane is much denser on the posterior

surface, and in its superficial parts contains vascular adenoid tissue either diffuse or as distinct lymph follicles (Klein, Haidar Kiamil); (*c*) the deep or submucous part is less dense in texture and contains many groups of fat cells and small mucous glands. (In carnivorous animals these latter are few and almost single tubes, wavy and convoluted). They are more numerous than in the anterior membrane and form almost a continuous layer. Their ducts penetrate through the mucous membrane and open on the posterior surface. The mucous glands are placed closely against the cartilage and in some places actually in a depression of this latter. As has been stated on a former occasion (p. 52), the cartilage is reticulated, and through its holes the mucous glands of one surface are continuous with those of the other; in some parts we find a mucous gland situated in the submucous tissue of the anterior membrane sending its duct through a hole of the cartilage to the posterior surface.

According to Verson the posterior surface of the epiglottis of the new-born child is covered with columnar ciliated epithelium; in the adult there are found, according to Davis, islands of stratified pavement epithelium amongst the ciliated columnar epithelium of the general surface.

I have examined the epiglottis of eight children varying in age from two years to twelve, and in no single instance have I found the epithelium of the posterior surface other than stratified pavement epithelium, as described above. Also in carnivorous animals I do not find on the posterior surface any other than stratified pavement epithelium, the superficial layers being composed of very flattened squamous cells.—E. K.

Passing from the epiglottis into the larynx the epithelium sooner or later changes from stratified pavement epithelium into stratified columnar epithelium, whose superficial cells are conical in shape and possessed of cilia (see Chapter II.).

This change never occurs suddenly, but gradually and in this way: amongst the stratified pavement epithelium there appear smaller or larger islands of stratified columnar cells, of which the superficial cells are short conical, and in most, but by no means in all, instances possessed of cilia. Further away from the epiglottis these islands increase in number and size, so that we find the general surface covered with stratified columnar (ciliated) epithelium with a few islands of stratified pavement epithelium amongst them. Ultimately these disappear and stratified columnar (ciliated) epithelium only is present. There exist great differences with regard to whether the stratified pavement epithelium of the posterior surface of the epiglottis is changed into stratified columnar (ciliated) epithelium nearer to or further from the base of the epiglottis. The margin of the false vocal cord is covered with stratified pavement epithelium (Klein, Davis), so is also the inner surface of the arytenoid cartilage (Davis), while in other cases close to the base of the epiglottis the epithelium is an uniform columnar ciliated epithelium.

Over the thyroid and cricoid cartilages the mucous membrane is covered only by

stratified columnar ciliated epithelium of the same nature as that described and figured in Chapter II. figs. I. and II. of Plate III. (See also the occurrence of goblet cells in connection with mucous secretion.)

The superficial part of the mucous membrane, or the mucosa, is of a tolerably dense texture; it is a meshwork of delicate bundles of fibrous tissue, which in many places contains more or less dense adenoid tissue; this latter tissue occurs chiefly underneath the epithelium (Luschka, Verson, Heitler), and contains the ultimate ramifications of the blood-vessels, that is a network of capillaries. It occurs either as diffuse adenoid tissue or as lymph follicles (Verson, Boldyrew, Coyne).

Between the epithelium and the mucosa is a distinct basement membrane (see below); this is always thickest in the deeper parts of the larynx, e.g. over the thyroid and cricoid cartilages.

In these same parts, viz. over the thyroid and cricoid cartilage, the mucosa is separated from the next layer or the submucous tissue by a special layer containing networks of longitudinal thick elastic fibres.

The deeper or submucous part, like the epiglottis, contains numerous mucous glands, and groups of fat cells, besides larger vessels and nerve branches. The mucous glands are, comparatively speaking, large, compound tubular, and form in many places a continuous layer. Their ducts open with wide mouths on the free surface and are occasionally lined with ciliated epithelium (Verson).

The largest mucous glands are found in those parts where the mucous membrane is loose and easily folded, e.g. in the false vocal cords.

The epithelium lining the lower part of the false vocal cord and the ventriculus Morgagni, except the part next the margin of the true vocal cord, is stratified columnar (ciliated), the mucous membrane is loose in texture and easily folded; it contains numerous mucous glands, and around and between them adenoid tissue either as diffuse masses or in the shape of definite lymph follicles (Luschka, Verson, Boldyrew, Heitler).

Passing from the ventricle on to the true vocal cord the columnar epithelium becomes changed into stratified pavement epithelium; this is thinnest just at the very margin; immediately below this the epithelium becomes again a little thicker, and remains stratified pavement epithelium for some distance below. This varies in different cases. The mucosa is without glands and is a dense tissue chiefly containing networks of elastic fibrils and projecting into the epithelium in the form of beautiful regular papillæ.

Between the epithelium and mucosa is a conspicuous basement membrane.

A short distance below the margin of the vocal cord the mucous glands reappear in a loose submucous tissue; at first they are small and isolated, but soon become larger and closer.

With the appearance of the mucous glands, or soon after, the epithelium and the mucosa resume again their former characters.

The distribution of the blood-vessels in the larynx does not differ from the general plan of their distribution in other mucous membranes, viz. the larger branches of arteries and veins belong to the submucous tissue, while the mucosa contains their ultimate ramifications, viz. the network of capillaries. These extend horizontally underneath the surface epithelium, except where this latter is stratified pavement epithelium (epiglottis, vocal cords); in this case the mucosa is possessed of papillæ, into each of which extends a loop of the capillaries. The mucous glands and lymphatic follicles possess of course their own afferent and efferent blood-vessels and capillary networks.

The lymphatics are very numerous. Generally we find a network of minute lymphatic tubes in the mucosa, leading into a network of larger tubes with valves, and situated in the submucous tissue. The most numerous and dense, and at the same time largest, lymphatics are found in the anterior membrane of the epiglottis, in the false vocal cords, in the ary-epiglottic folds, and in the ventriculus Morgagni.

The nerve branches found in the submucous tissue are large bundles of medullated fibres; isolated medullated and non-medullated fibres may be met with in the mucosa, where they are connected in a fine plexus.

These fibres possess a thick laminated nucleated sheath (Boldyrew).

According to Luschka, and also Boldyrew, the nerve fibres terminate in the mucosa in the form of end-bulbs.

On the posterior surface of the epiglottis we meet with taste goblets amongst the stratified epithelium (Verson, Schofield, Davis); their number increases towards the basis, and they are in some instances (dog, Schofield) arranged in rows, and may be met with also occasionally on the ary-epiglottic folds and the mucous membrane of the inner surface of the arytenoid cartilage, as well as on the true vocal cord (Davis).

2. The Trachea.

The structure of the mucous membrane of the trachea is very similar to that of the larynx. The different layers described of the latter are continued into the former.

a) The epithelium is stratified columnar, the superficial cells being ciliated; its minute structure is identical with that of the larynx.

b) Underneath the epithelium is a homogeneous-looking basement membrane; this membrane is very conspicuous in the human trachea on account of its thickness.

It is permeated by thicker and thinner canals connecting the lymph-canalicular system of the mucosa with the intercellular substance of the epithelium. Occasionally

we find even a greater or smaller part of a lacuna of this lymph-canalicular system extending into the membrane.

c) Underneath the basement membrane is the mucosa; this consists of a superficial and deep section. The former is a reticulated structure, being composed of a meshwork of thin fibre bundles, and between them lymphoid cells and flattened connective-tissue cells, each with an oval flattened nucleus. In some places, the just-named meshwork is like adenoid reticulum, and the mucosa appears then similar to diffuse adenoid tissue. The small lacunæ of the meshwork are connected with one another by narrower or broader channels, and contain both the flattened connective-tissue corpuscles and the lymphoid cells; that is to say, they completely resemble the lymph-canalicular system of other connective tissues.

The deep section of the mucosa is a thin stratum of a network of longitudinal elastic fibres, between which lie connective-tissue corpuscles and capillary blood-vessels.

d) The submucous tissue is loose connective tissue containing the glands, fat tissue and the larger blood-vessels and lymphatics, and the nerve trunks.

The glands are mucus-secreting glands, forming a more or less continuous layer. Their structure is in all respects similar to that of the glands of the larynx; the contrast between the two conditions under which the epithelial cells lining the alveoli appear is very easily ascertained. In the human trachea we meet with many alveoli, belonging to the same gland, which are either lined with 'mucous' cells or with 'granular' epithelial cells. As in the larynx, so also here we meet occasionally (especially in cat and dog) a gland tube lined with mucous cells, and outside these are 'crescents' of granular cells similar to those of the submaxillary gland of dog (see Chapter XXIV.).

The duct, and also part of the gland, is in some places embedded in, or surrounded by, a lymph follicle.

The trabeculæ of connective tissue of the submucosa are continuous both with the perichondrium of the cartilage rings and with the tissue between the free ends of these latter—that is, the membranous part of the trachea. Here we find also groups of bundles of unstriped muscle tissue extending in a transverse (circular) direction between the extremities of the cartilage rings. Occasionally we find outside these in addition longitudinal muscle bundles; they are not so numerous in man as in some (carnivorous) animals (Verson).

The mucous glands above mentioned extend not only in amongst the muscle coat, but some are placed even outside the latter.

The outer boundary of the trachea is formed by a layer of fibrous-connective tissue.

As regards the distribution of blood-vessels, lymphatics, and nerves, the same relations exist as in the larynx.

3. The Bronchi.

In the bronchi we meet with precisely the same structure as in the trachea.

The epithelium, as a whole, becomes thinner towards the smaller branches, in which it is composed only of one layer of ciliated columnar cells. In the smallest bronchi these cells become very short columnar, but retain their cilia to the end—that is, to near the alveolar ducts. As in the trachea, so also in the bronchi the epithelial cells are capable of being converted into goblet cells.

The epithelium lining the mucous membrane of two bronchi belonging to the same order, but one of which is distended, the other contracted *ad maximum*, presents itself in a totally different aspect (Klein); while in a large bronchus which is contracted the epithelium appears stratified, it is but a single layer of cells in a similar bronchus that is much distended. And similarly in the smallest bronchi the epithelium may appear composed of shorter or longer columnar cells, according to whether the bronchus is distended or contracted *ad maximum*.

Underneath the epithelium is a basement membrane, which is a single layer of large flattened nucleated endothelial cells (Debove).

The mucosa appears as smaller or larger folds, and contains a delicate meshwork of minute connective-tissue bundles, between which are seen the connective-tissue corpuscles; numerous longitudinal elastic fibres, connected into a network, belong to this layer.

In the bronchi of some animals (pig) these elastic fibres attain a very great development, forming a thick stratum of their own.

Outside this is a more or less continuous circular layer of unstriped muscle cells. This layer is very conspicuous, and its thickness varies, of course, whether a bronchus is in a distended or contracted state. The depth (or height) of the folds of the mucosa entirely depends on the state of contraction of the muscle coat.

The next layer is the submucous tissue containing small mucous glands. In the larger bronchi the connective-tissue trabeculæ of this layer pass directly into the perichondrium of the cartilage plates, and into the fibrous coat outside these, viz. the bronchial adventitia. The mucous glands generally extend between the cartilage plates into the adventitia. Groups of fat cells occur in the submucous tissue as well as in the adventitia.

Towards the smaller bronchi the glands of the submucous tissue decrease, both in size and number, just like the cartilage plates, and in the smallest bronchi the fibrous tissue outside the muscle coat contains neither glands nor cartilage.

In the smaller bronchi the adventitia is very rich in elastic fibrils connected into a network. The adventitia of the larger bronchi is connected with the tissue between the lobules of the lung—that is, the interlobular septa—while the adventitia of the smaller bronchi passes insensibly into the wall of the adjacent alveoli.

The vascular supply of the bronchi is obtained from the bronchial arteries, whose ultimate branches supply the mucosa, the muscular coat, the mucous glands and fat tissue with special networks of capillaries. In the smallest bronchi, the capillaries of the bronchial wall are directly connected with the capillaries of the adjacent alveoli; but in the larger bronchi the capillaries empty themselves into the bronchial veins only.

Lymphatic vessels are present as a network of fine capillaries in the mucosa; they are connected with larger tubes with valves situated in the submucous and adventitious tissue, the peribronchial lymphatics. In the submucous tissue of the larger as well as smaller bronchi are occasionally present smaller or larger lymph follicles (Burdon-Sanderson, Klein); they extend sometimes as diffuse adenoid tissue into the mucosa, and are generally surrounded by a dilatation or a lymph sinus of a peribronchial lymphatic (Klein). Small collections of adenoid tissue may be met with in the wall of even the smallest bronchi.

In connection with the nerve branches of the adventitia are small ganglia (Remak, Klein, Stirling).

4. The Lung.

Like other glands, the lung also possesses a connective-tissue *framework* in which is embedded the *parenchyma.*

The *framework* consists of a capsule, the pulmonary pleura, and in connection with it are the septa dividing the parenchyma into lobes and subdividing these again into lobules.

The capsule consists (in man and the large mammals) of an outer denser layer, pleura proper, and an inner looser tissue, subpleural tissue, which passes into the depth as the aforesaid septa.

The pleura is covered on its free surface with an endothelium, whose cells are transparent, large, flat, and hyaline when the lung is expanded *ad maximum,* but become smaller, thicker (polyhedral) and granular-looking when the lung collapses (Klein). The ground substance is a dense fibrous-connective tissue and in it are networks of elastic fibres. Like that of other serous membranes, it contains a lymph-canalicular system, and in it branched connective-tissue corpuscles. There exists the same continuity of the interstitial substance of the surface endothelium with the lymph-canalicular system, as well as of this with the numerous lymphatic vessels (subpleural lymphatics), to be described below (Küttner, Klein), as that occurring in other membranes (see p. 175). In some animals (guinea pig) the pulmonary pleura contains a meshwork of broader or narrower bands of unstriped muscle cells (Klein); the meshes are lymph sinuses, communicating with the free surface of the pleura by means of true stomata.

The subpleural tissue and that constituting the interlobar and interlobular septa con-

tain lamellæ of fibrous-connective tissue, and between them the connective-tissue corpuscles. Numerous lymphatic vessels and lymphatic spaces are here to be met with (see below).

The fibrous-connective tissue surrounding, or rather supporting, the bronchi and large vascular trunks (the adventitia) forms a continuity with that of the interlobular septa, as already mentioned.

The *parenchyma*, consisting of the bronchi, alveolar ducts and alveoli, is divided into lobules.

The small or intralobular bronchi are cylindrical tubes. They divide dichotomously into smaller tubes, and ultimately pass into the alveolar ducts (F. E. Schulze, Stieda) which take up on all sides of their circumference the lateral alveoli; the ultimate parts of the alveolar ducts are the infundibula (F. E. Schulze), which take up the terminal alveoli. The alveoli are spherical or polyhedral in shape, and those belonging to the same alveolar duct or infundibulum are separated by much less tissue than the alveoli of adjacent lobules.

Passing from a terminal bronchus of man or mammals into an alveolar duct and infundibulum, we find that the epithelium becomes reduced to low polyhedral cells without any cilia: each cell possesses a spherical nucleus. In the alveolar duct and infundibulum itself we find these polyhedral cells continued as smaller or larger groups, while the rest of the lining epithelium is made up of very large flattened transparent cell plates of exactly the same appearance as those of an ordinary endothelial membrane.

From the alveolar ducts and infundibula we trace, into the alveoli, both the small polyhedral cells as well as the large flattened cell plates; the latter predominate greatly over the former, there being left only isolated or small groups (two or three) of the small polyhedral cells between the transparent placoids lining the alveoli (Elenz, F. E. Schulze and others). In the lung of cat the number of such polyhedral cells is greater than in the lung of other mammals. They are easily perceived both in the fresh state as well as after reagents, especially after staining with nitrate of silver, being conspicuous by their 'granular' appearance, and by being smaller and much thicker than the others, viz. the placoids.

Except in size and appearance the two kinds of cells are identical, both being epithelial cells derived from the hypoblast of the embryo. At first sight it seems as if the two kinds of cells were essentially different, the one being a continuation of the polyhedral epithelial cells lining the terminal parts of the bronchi, the other of the subepithelial endothelial membrane mentioned above. And this has indeed been asserted to be the case (Debove); but there can be no doubt that in the embryo this distinction

does not exist, and in the lung of the fœtus that has not breathed yet, the alveoli are lined only by one kind of cells, viz. by small polyhedral granular-looking cells; only after respiration has begun and the alveoli have become expanded and remain so, we find the two kinds of cells (Küttner). But also in the adult a transition of the one kind of cells into the other can be observed, for during a maximum expansion of the alveoli most of the small polyhedral granular cells become flattened transparent placoids, which resume again their previous nature when the alveoli collapse.

In the alveolar ducts, infundibula, and alveoli there appear larger or smaller circular or angular openings (Buhl and others) between the lining cell plates, similar to stomata (pseudo-stomata) in serous membranes. They are conspicuous only in the distended alveoli; when the latter are collapsed they are reduced into the smallest points or stigmata. As has been mentioned on a previous page in connection with the serous membranes, these pseudo-stomata correspond to the interstitial substance between the placoids lining the lumen of the alveoli. They lead into the lymph-canalicular system of the alveolar wall.

The wall of the alveolar ducts and infundibula is made up chiefly of unstriped muscle cells, running in a circular manner; there is present a very small amount of fibrous tissue, and in it branched connective-tissue cells in their respective lymph-canalicular system. An uniform network of elastic fibres increases the thickness of the wall. It is barely necessary to add that the connective tissue, the elastic fibres, and the branched cells are continuations of the same elements of the ultimate bronchi. In the wall of the alveoli we meet chiefly with a network of broader and finer elastic fibres and a dense network of capillary blood-vessels, the latter being in close contact with the epithelium lining the alveolar cavity. Between and outside the capillaries we find a network of branched cells in their respective lymph-canalicular system, embedded in a homogeneous ground-substance; the branched cells with their processes—or the lymph-canalicular system respectively—penetrate between the alveolar epithelium, where they identify themselves with the interstitial substance (Klein, Küttner).

Bands of unstriped muscle cells are absent from the greater part of the alveolar wall; they are seen to pass from the alveolar ducts and infundibula a short distance into the alveolar wall.

As mentioned above, the tissue separating the alveoli of adjacent lobules is greater in amount than that between alveoli belonging to the same alveolar duct or infundibulum, and in the former case we see besides elastic networks also a certain amount of fibrous-connective tissue, belonging to the interlobular septa.

The most important part of the alveolar septa are the capillary vessels. They are connected into an exceedingly dense network, which is intermediary between the

branches of the pulmonary artery and pulmonary vein. Not each alveolus belonging to one and the same lobule has its own afferent arteriole, efferent vein, and capillary network, but a number of neighbouring alveoli possess a common vascular supply; the afferent arteriole and efferent vein or veins join the capillary network generally at opposite sides; the network of capillaries, according to the peculiar globular nature of the alveoli, possesses, as it were, a honey-combed arrangement. The individual capillaries are either straight or more or less wavy; in the contracted lung they are of course very wavy, and quite close. The capillaries belonging to the septa between adjacent alveoli are in many instances more or less twisted, so as to approach now the cavity of the one, now again that of the other alveolus. The structure of the capillary blood-vessels in no way differs from that of other organs. The branched connective-tissue cells with their processes, mentioned above, are seen entwining and crossing the capillaries.

Near a bronchus, and near the pleura, the alveolar capillaries anastomose with the capillaries of these organs: that is to say, with the capillaries of the bronchial artery. This is, however, denied by Cohnheim and Litten, but reaffirmed by Hoyer, Köster, and others.

The large arterial and venous branches are situated in the interlobular connective tissue, which is continuous with their adventitia. Of interest is the arrangement of the muscle coat in the branches of the pulmonary artery, the (circular) muscle coat not being a continuous one, but interrupted from place to place (Klein), so that at these points the adventitia is in immediate contact with the intima. This state is very well shown in the lung of guinea pig.

The lymphatics are very numerous (Wywodzoff, Sykorski, Klein, Küttner, and others). They are arranged in the following three systems: (*a*) the subpleural lymphatics (superficial lymphatics, Wywodzoff) forming a dense plexus of lymphatic vessels, many of which contain valves. Their wall is, as usual, a single endothelial membrane. These subpleural vessels take their rootlets in the pleura itself, but especially in the lymph-canalicular system of the walls of the alveoli next the pleura. The meshes of this plexus correspond, on the whole, to the outlines of the alveoli, but there are many places where the vessels are much closer.

In the lung of cattle the vessels of the subpleural plexus form more or less separate sections, according to the individual lobules, and the vessels of each such section have a stellate arrangement (Roy).

In man and many mammals this plexus of subpleural vessels sends efferent trunks, through the ligamenta pulmonum, directly to the bronchial glands, but there are always numerous vessels that pass from the subpleural plexus through the interlobular connective tissue to join (*b*) the perivascular lymphatics. These have their rootlets

in the lymph-canalicular system of the wall of the alveoli. These vessels accompany the branches of the pulmonary artery and vein, and the larger trunks possess valves. In some places the perivascular lymphatics more or less completely invaginate the arterial or venous branches, in others the lymphatics form a dense network of intercommunicating sinuses in the sheath of the large branches of the pulmonary artery (Klein).

(*c*) The peribronchial lymphatics, which have been mentioned previously as the deep lymphatics of the bronchi, to whose adventitia they belong, anastomose freely with the perivascular lymphatics and run with them, in the form of a plexus of lymphatic trunks with valves, through the interlobular and interlobar connective tissue towards the bronchial glands.

The rootlets of the subpleural and the perivascular lymphatics, as mentioned already, lie in the alveolar walls, that is in the lymph-canalicular system described on a former page. The lacunæ of this (lymph-canalicular) system are situated between the capillary blood-vessels, and their canaliculi cross these latter in many directions. During the expansion of the lung (inspiration), the lymph-canalicular system, as well as the lymphatic vessels, become distended, and there is caused hereby, naturally, a certain suction, in consequence of which formed or fluid matter, that happens to be present in the alveolar cavities, will readily penetrate from the latter into the lymphatic vessels. The above-described direct connection of the lymph-canalicular system with the interstitial substance between the epithelial cells lining the alveolar cavity is of great importance in this process. Sykorski, and afterwards Küttner, demonstrated very beautifully the passage of pigment matter that had been inspired into the bronchi and alveoli during life (dog, cat, rabbit) through the interstitial substance of the lining epithelium into the lymph-canalicular system, and hence into the lymphatic vessels, all parts being very well injected. Inflammatory products present in the alveolar cavities readily find their way into the efferent lymphatics. The migratory lymph cells (pus-corpuscles) of inflammation are supported in this by their amœboid movement.

A more or less similar success was achieved by Ruppert, Schottelius, and v. Ins. Schestopal injected the lymphatic system of the frog's lung by introducing pigment matter into its cavity. The result is the same as in the experiments of Küttner on mammals, viz. the pigment matter is contained in the interstitial substance of the lining epithelium, in the lymph-canalicular system, and, finally, in the lymphatic vessels.

Coal particles of a smoky atmosphere, when inhaled for some time, penetrate into the lymph-canalicular system of the alveolar walls, as well as into the lymphatics of many parts of the lung. They are especially distinct in the subpleural lymphatics and the

REESE LIBRARY
OF THE
UNIVERSITY
OF
CALIFORNIA

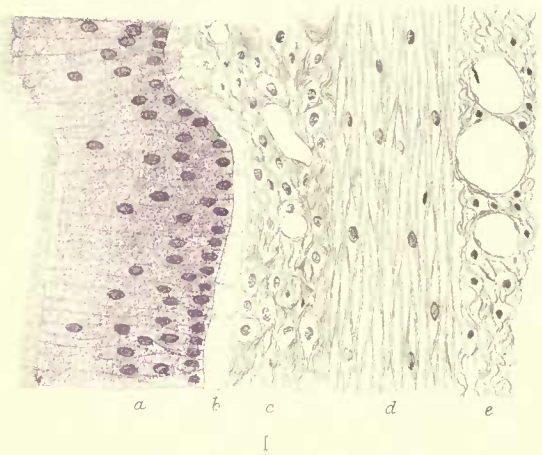

I



II

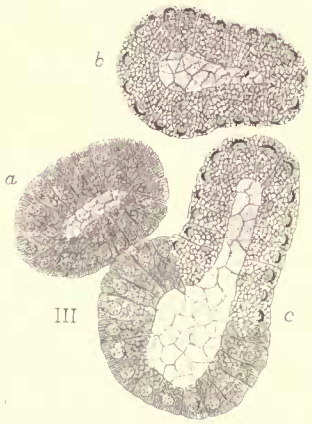

III

IV

V

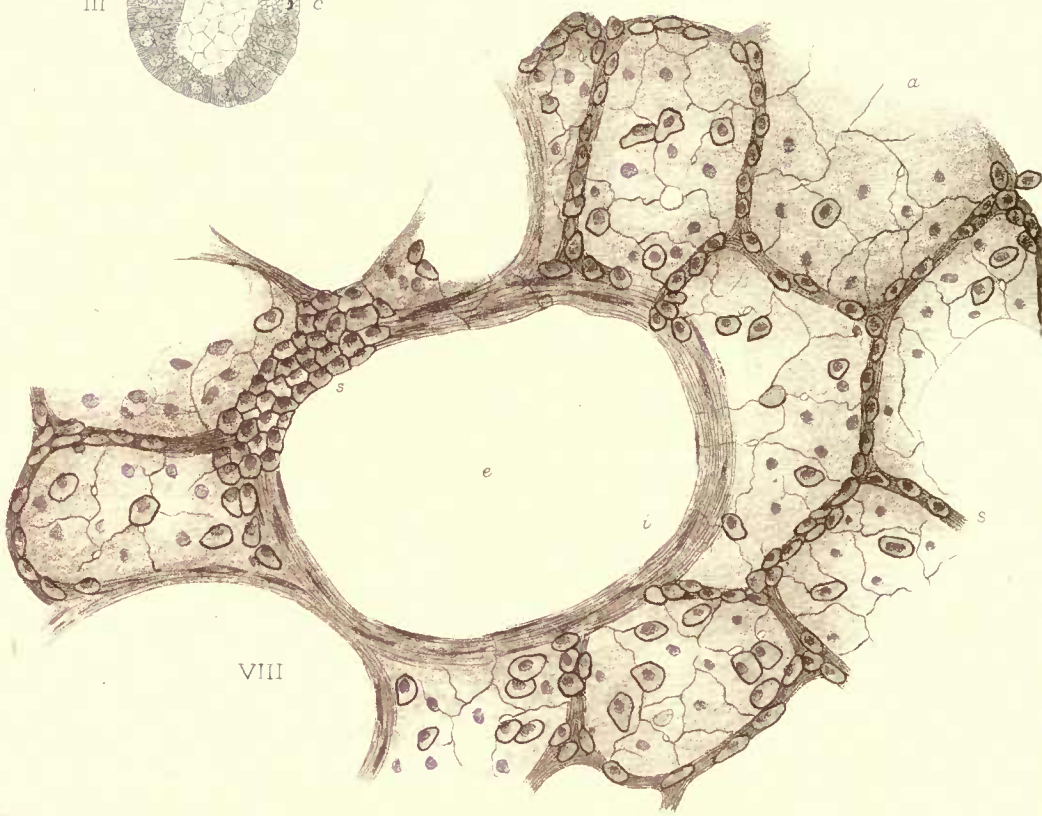

VIII

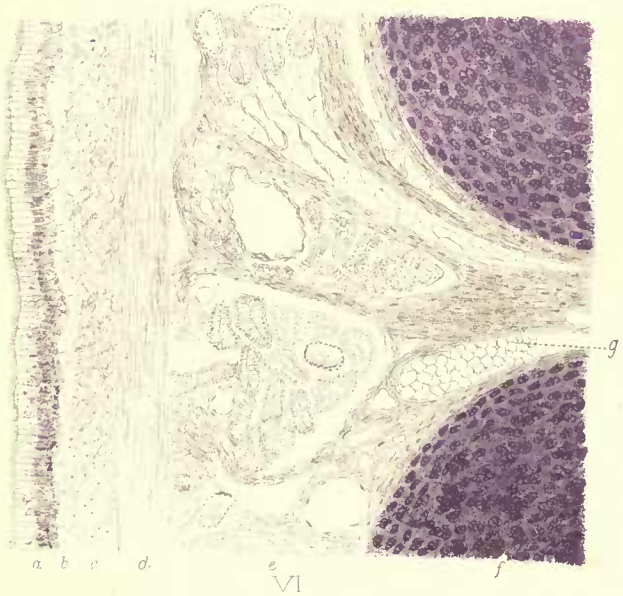

VI

VII

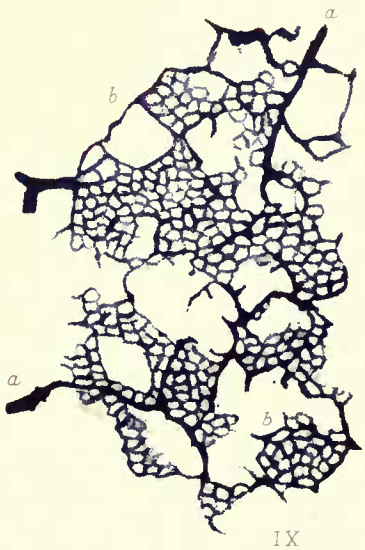

IX

lymphatics of the interlobular connective tissue (Knauff, Wittich, Buhl, Rindfleisch, and others).

Also other particles (dust of every description, septic matter, contagious particles, etc.) may penetrate into the lymph-canalicular system, either as such—viz. merely in consequence of the above suction—or they are carried there by lymphoid cells (inflammatory products), which had taken them up previously (see Chapter I.).

Just as much as the inspiratory movement of the lung aids absorption, so the expiratory movement produces a contraction of the lymphatics, and therefore a progression of the contents of the latter towards the bronchial glands.

PLATE XXXVI.

Fig. I. From a longitudinal section through the innermost part of the mucous membrane of the trachea of a child. Magnifying power about 300.

a. Stratified columnar epithelium; the superficial conical cells are ciliated.

b. Basement membrane, perforated by fine vertical canals of the lymph-canalicular system underneath.

c. The inner section of the mucosa, containing capillary blood-vessels.

d. The layer of longitudinal elastic fibres connected into a network.

e. First section of the submucous tissue with large vessels.

Fig. II. From a vertical section through the stratified pavement epithelium covering the mucous membrane of the posterior surface of the epiglottis of a child. Magnifying power about 300.

s. Free surface.

d. Inner surface attached to the mucosa.

Fig. III. From a section through a mucous gland of epiglottis of child, showing gland tubes cut in various directions. Magnifying power about 450.

a. A gland tube cut transversely; the epithelium lining it is in a state of rest.

b. A similar tube, whose epithelium is in a state of secretion.

c. A tube cut obliquely; in the lower part the epithelium is in a state of rest, in the upper in a state of secretion.

Fig. IV. From a transverse section through the epiglottis of a child. Magnifying power about 45.

a. The stratified pavement epithelium of the posterior surface.

b. The mucous membrane containing mucous glands.

c. The elastic cartilage.

d. The mucous glands of the anterior surface. In this instance a duct is seen to pass through the posterior mucous membrane.

e. The mucous membrane of the anterior surface contains numerous lymphatics, cut here in various directions.

f. The stratified pavement epithelium of the anterior surface.

l. Lymph follicle.

Fig V. From a longitudinal section through the ventriculus Morgagni of a child. Magnifying power about 45. In order to correspond to the natural position the drawing should be reversed.

a. The true vocal cord, covered with stratified pavement epithelium. The mucosa contains dense elastic tissue.

b. The false vocal cord ; its margin is covered with stratified pavement epithelium, towards the epiglottis the epithelium is stratified columnar (ciliated), intermixed with islands of stratified pavement cells. These minute details are not shown here on account of the low power under which the drawing is made. The mucous membrane contains numerous mucous glands.

c. A nodule of elastic cartilage in the true vocal cord.

d. Ventricle lined with ciliated columnar epithelium.

l. The mucous membrane next the epithelium, being one continuous mass of adenoid tissue. The outer section of the mucous membrane containing mucous glands and striped muscle (upper portion of thyro-arytenoid muscle) is not represented.

m. Striped muscle fibres in transverse sections, the lower portion of the thyro-arytenoid muscle.

Fig. VI. From a longitudinal section through the same trachea as fig. I., but under a low power, so as to show the whole thickness of the mucous membrane. Magnifying power about 45.

a. The stratified columnar (ciliated) epithelium.

b. The basement membrane.

c. The inner section of the mucosa.

d. The network of longitudinal elastic fibres.

e. The submucous tissue, containing mucous glands and large vessels.

f. Portions of the (hyaline) cartilage rings in transverse section.

g. Fat cells.

Fig. VII. From an oblique section through the trachea of fœtus. Owing to the obliquity of the section, several cartilage rings (stained deep purple) are included in the section. The trachea is much shrunk and placed in folds. Magnifying power about 25.

e. The ciliated columnar epithelium.

m. The unstriped muscle tissue of the posterior membranous part.

REESE LIBRARY
OF THE
UNIVERSITY
OF
CALIFORNIA.

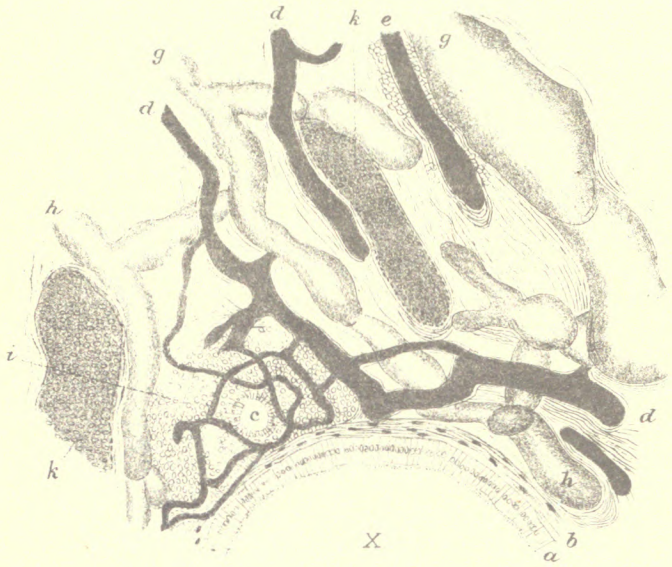

X

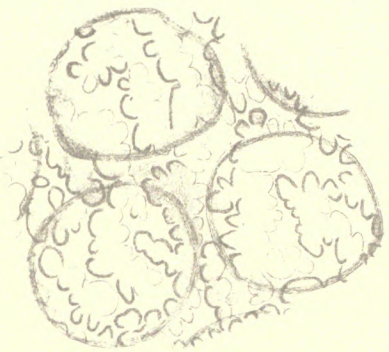

XII

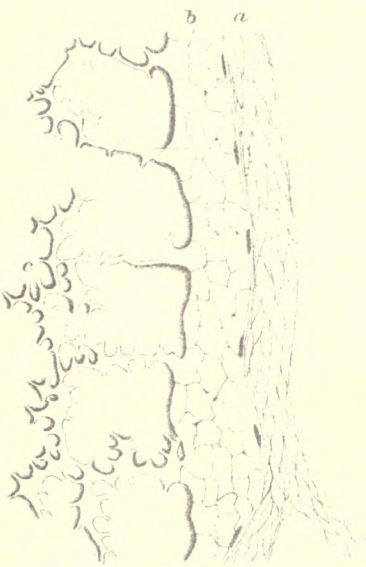

XI

XIII

The mucosa contains mucous gland tubes.

Fig. VIII. From a section through the lung of cat, stained first with nitrate of silver and then with hæmatoxylin.

a. Alveoli lined with large flat transparent nucleated epithelial cells; amongst them are small polyhedral nucleated cells more deeply stained; they are especially well shown where the alveolar wall is seen in profile. Between the large flat cells are smaller or larger clear spaces corresponding to pseudo-stomata.

s. Alveolar septa.

s. A group of small polyhedral epithelial cells continued from the bronchus.

e. Alveolar duct in section.

i. The circular muscle coat.

Fig. IX. From a section through lung of a child whose pulmonary artery had been injected with Berlin blue, Magnifying power about 25.

a. The afferent and efferent vessels; on account of the low power it is not possible to recognise which is the branch of the pulmonary artery and which of the vein; but under a high power it can be ascertained that the upper corresponds to the artery.

b. The arrangement of the network of capillaries according to the individual alveoli is easily recognised.

PLATE XXXVII.

(*Copied from Klein's 'Anatomy of the Lymphatic System.' II.*)

Fig. X. Section through a large bronchus of the lung of guinea pig; the blood-vessels had been injected from the pulmonary artery. The injection had escaped through the lymphatics, which are here distended. The section is oblique, and therefore in the upper part of the figure the bronchial wall is viewed more or less from its external surface.

a. Ciliated epithelium lining the inner surface.

b. Muscular coat.

c. A duct of a mucous gland.

d. Veins.

e. A branch of pulmonary artery.

g. Perivascular lymphatics.

h. Peribronchial lymphatics, anastomosing with the former.

i. A lymphatic follicle.

k. Cartilage. Magnifying power about 50.

Fig. XI. From a section through a guinea pig's lung that had been injected with nitrate of silver.

a. Branch of pulmonary artery.

b. A lymphatic vessel, in connection with

c. Interalveolar lymph spaces, i.e. the lymph-canalicular system. Magnifying power about 150.

Fig. XII. From the same lung as the preceding figure, showing the lymph-canalicular system of the alveolar wall as viewed from the surface.

Fig. XIII. Surface view of distended subpleural lymphatics (injected) of guinea pig.

a. Large trunks with valves.

b. Branches emerging from the depth, i.e. from the interalveolar tissue. Magnifying power about 90.

CHAPTER XXX.

THE URINARY ORGANS.

The Kidney.

The *framework* of the kidney of man and mammals consists of (*a*) the outer capsule; (*b*) the membrane lining the pelvis and calices; (*c*) the tissue passing from the calices into the parenchyma of the kidney as the carrier of the large blood-vessels; (*d*) the connective tissue of the parenchyma itself.

a) The capsule is composed of fibrous-connective tissue more or less of a lamellar arrangement, with the corresponding flattened endotheloid connective-tissue corpuscles between the lamellæ. A thin deep portion of the capsular tissue is much looser and more delicate than the rest; its bundles penetrate between the tubes of the peripheral part of the cortex, chiefly in connection with the vascular branches running between the latter (cortex) and the capsule. According to Eberth there exists a plexus of unstriped muscle cells underneath the capsule of the human kidney.

b) The membrane lining the pelvis and calices is, like the one forming the wall of the ureter, covered on its internal free surface with stratified transitional epithelium (see below). Underneath this epithelium is a dense feltwork of connective tissue with the corresponding connective-tissue corpuscles. This stratum is the mucosa, and it passes insensibly into the loose outer coat or submucosa, composed chiefly of trabeculæ of connective tissue and a few elastic fibres; its outer section contains a greater or smaller amount of fat-cell tissue, while its inner section includes numerous bundles of unstriped muscle cells, arranged in a longitudinal and circular layer and continuous with the muscular coat of the ureter. On the papillæ only circular muscular fibres are met with (Henle).

Paladino, Sertoli, and especially Egli, described in the pelvis of the kidney of the horse small, simple or branched gland tubes lined with a single layer of columnar epithelial cells; also in the pelvis of the human kidney Egli observed, but not constantly, gland tubes similar to sebaceous follicles.

c) The connective tissue of the submucosa above mentioned penetrates, together with the large vascular trunks, into the parenchyma, at the boundary of the cortex and medulla. It also carries with it longitudinal muscular bundles; they retain the same direction while accompanying the vascular trunks, viz. more or less parallel to the surface of the kidney.

d) The connective tissue of the parenchyma differs very greatly in the different parts

of the latter. Around each Malpighian corpuscle there is always present an appreciable amount of fibrous-connective tissue (Ludwig and Zawarykin) with the corresponding connective-tissue cells; it is more abundant in the young kidney than in the adult. This connective tissue forms a continuity with the connective tissue around the afferent arteriole, further with that around the interlobular artery, and finally with the connective tissue surrounding the large arterial trunks situated at the boundary between the cortex and medulla.

A small amount of fibrous-connective tissue may be traced from the last-mentioned trunks on the arteriolæ rectæ into the boundary layer of the medulla (see below).

The papillary part of the medulla (see below) contains a great amount of fibrous-connective tissue (Henle) separating the urinary tubules; it increases in amount towards the apex of the papilla, and becomes continuous with the fibrous tissue of the surface of the papilla.

The boundary layer between the medulla and the cortex possesses only a scanty intertubular connective tissue: this tissue consists of hyaline honey-combed membranous structures—the supporting tissue of the urinary tubules and the capillary blood-vessels—to which are applied from place to place flattened branched or spindle-shaped connective-tissue cells, each with an oval nucleus generally placed transversely to the long axis of the urinary tubules (Schweigger-Seidel).

The constituents of the *parenchyma* are the urinary tubules. They commence with a cæcal extremity in the Malpighian corpuscles and terminate with an opening on the free surface of the papilla.

Owing to the peculiar arrangement of the tubules, a vertical section through the kidney exhibits three distinct regions: the *cortex*, the *boundary layer* (Grenzschichte) of Ludwig, and the *papillary portion*, the two last forming the medulla.

Each papilla, with the section of boundary layer belonging to it, forms a pyramid of Malpighi.

The papillary portion is uniformly vertically striated, the striæ being due to urinary tubules and blood-vessels, all of them running parallel, straight and vertically to the apex of the papilla. The boundary layer is also uniformly striated, the striæ having a parallel and longitudinal course, but they are grouped in columns, alternately opaque and light, the former being composed of more or less straight urinary tubules, the latter of straight blood-vessels (vasa recta). The cortex shows, in a uniform *labyrinth* of convoluted tubules, regularly disposed vertical, straight columns radiating towards the boundary layer; being the direct continuations of the opaque columns (urinary tubules) of this latter, they are called the *medullary rays*.

At the commencement of the cortex (next the boundary layer) the medullary rays are of about the same thickness as the aforesaid opaque columns of the boundary layer, but they diminish gradually towards the periphery of the cortex and cease altogether at some distance from the outer capsule; hence each of these medullary rays is conical in shape, its apex lying in the periphery of the cortex and its base merging into the base of the medulla: they represent what are called the pyramids of Ferrein.

Taking the vertical diameter of both cortex and medulla together as 10, the relative proportions of the above three sections, viz. cortex, boundary layer, and papillary portion, are about 3·5 : 2·5 : 4.

In the human kidney and in that of other mammals Malpighian corpuscles are present only in the parts of the cortex containing convoluted tubules, i.e. in the labyrinth between the medullary rays, except the most external and most internal layer of the cortex, that is near the capsule and near the boundary layer. In both places, but especially in the former, there is a layer of appreciable thickness without any Malpighian corpuscles.

Taking the vertical diameter of the cortex as 7, we find a layer of the thickness of 1 next the capsule, and one of 0·8 next the boundary layer, without any Malpighian corpuscles, as shown in the diagram 1 of Plate XXXVIIA. as a and a_1.

Every urinary tubule, from its beginning in the Malpighian corpuscle to its opening on the surface of the papilla, can be divided into several distinct sections; these differ from one another very markedly in *location* and *structure.*

In diagram 1 of Plate XXXVIIA. these different sections are well marked:

1. The Malpighian corpuscle, being a spherical cæcal commencement of the urinary tubule.

2. The neck, a short narrow constriction, through which the Malpighian corpuscle passes into:

3. The proximal convoluted tubule. This is of considerable length and finally passes into:

4. The spiral tubule (Schachowa). This is not situated any more in the labyrinth, but forms part of the medullary ray.

These four sections belong to the cortex A. Passing from the cortex into the boundary layer B, the spiral tubule becomes suddenly very fine and straight as:

5. The descending limb of Henle's loop. This is continued into the beginning of the papillary section C, where it forms:

6. The loop itself. When entering the boundary layer again, it becomes suddenly enlarged and slightly wavy, forming thus:

7. The first thick portion of the ascending limb of Henle's loop.

8. About midway in the boundary layer this tubule becomes again narrower and

assumes a spiral course, thus forming a distinct section as the spiral part of the ascending limb.

9. Now the tubule enters again the cortex, and becoming narrower and more or less straight, or slightly wavy, ascends in the medullary ray. After a longer or shorter course, during which it may undergo a slight variation in thickness, it leaves the medullary ray and enters the labyrinth, winding its way amongst the convoluted tubules as:

10. The irregular tubule, which is very irregular in outline, breadth and course. It passes into:

11. The intercalated segment (Schaltstück) of Schweigger-Seidel, this being the distal convoluted tubule of exactly the same nature as the above-named third section, viz. the proximal convoluted tubule. After a longer or shorter course it passes into:

12. The curved part of the collecting tube, a narrow tube of a wavy, curved course having to find its way through the labyrinth. It joins other similar tubes and forms:

13. The straight part of the collecting tube of the cortex: this tube forms part of the medullary ray.

14. Now the collecting tube enters the boundary layer, and while passing through it increases in breadth but remains straight. It enters finally the papillary portion as:

15. The large collecting tube, or tube of Bellini, a large straight tube joining other collecting tubes.

16. Having by anastomosis with similar tubes become greatly enlarged, it opens as one of the 'ducts' with its 'mouth' on the free surface of the papilla.

From the foregoing description and the diagram 1 of Plate XXXVIIA., it will be seen that the Malpighian corpuscle, with its neck (1 and 2), the proximal convoluted tubule (3), the spiral tubule (4), the straight narrow part of the cortical ascending limb of Henle's loop (9), the irregular tubule (10), the intercalated segment of Schweigger-Seidel or the distal convoluted tubule (11), the curved part of the collecting tube (12), and the next following straight part of the collecting tube (13) belong to the cortex. Amongst these the sections marked 1, 2, 3, 10, 11 and 12 belong to the labyrinth, whereas 4, 9 and 13 form the medullary ray, section 4, i.e. the spiral tubule, being the most conspicuous feature in it. Owing to the collecting tubes of the medullary rays originating through the confluence of several (curved) collecting tubules, it follows that the number of the former is much smaller than the other kinds of tubes forming the medullary rays, viz. the spiral tubules (4) and the ascending limbs of Henle's tubes (9), the two latter being of course equal in numbers. The descending limb of Henle's loop (5), the first thick portion of the ascending limb (7), the next following spiral part (8), and the collecting tube (14), belong to the boundary layer of the medulla and form at the same time the continuation of the medullary ray; while Henle's loop itself (6), the large collecting tubes (15), and the ducts belong to the papillary portion of the medulla.

The line of demarcation between the cortex and the boundary layer is formed by the limit to which convoluted tubes extend and by the transition of the spiral tubule (4) into the descending limb of Henle's loop (5), and of the spiral portion of the ascending limb (8), into the straight narrow cortical part of the same (9). The line of demarcation between the boundary

layer and the papillary part is formed by the transition of the loop itself (6) into the first thick part of the ascending limb (7).

Proximal and distal convoluted tubules (3 and 11), irregular tubules (10), and curved collecting tubes (12) are met with in all parts of the labyrinth, including the peripheral layer of the cortex (*a* in the diagram), viz. the one mentioned as free of Malpighian corpuscles. The convoluted tubules of this region, viz. next the capsule of the kidney, form more or less distinctly looplike curvatures. The length of the different sections of the urinary tubules in the cortex is subject to very great differences, for to a Malpighian corpuscle, situated in the periphery of the cortex, and whose proximal convoluted tubule extends even into the layer *a*, must necessarily belong a spiral tubule (4) of much greater length than the one that belongs to a Malpighian corpuscle situated near a_1. And similarly the straight part of the cortical ascending limb of Henle's loop (9), leading to an irregular tubule (10) that is situated in the peripheral layer *a*, must be very much longer than one leading to an irregular tubule that is situated near the layer a_1.

The neighbouring Malpighian corpuscles and the different sections of neighbouring convoluted tubules bear in so far a certain relation to one another, as their spiral tubules, descending and ascending limbs of Henle's loops, and collecting tubules keep together in the same medullary ray and its prolongation into the boundary layer. Hence each 'duct' may be considered as the apex of a small cone whose long axis lies in the medullary ray; its basis is in the cortex, and is formed by the Malpighian corpuscles and the corresponding convoluted irregular and curved tubules above named. These cones are the primitive cones of Ludwig, and the medulla and cortex may thus be considered as composed of as many cones as there are 'ducts.'

The above sixteen divisions of the urinary tubules differ from one another in structure in a marked manner.

1. The *Malpighian corpuscle.* This is composed of the capsule of Bowman and the glomerulus. The capsule of Bowman is the saccular commencement of the urinary tubule; it consists of a hyaline membrana propria, thickened on the outside by a varying amount of fibrous-connective tissue, mentioned on a former page. The inner surface of the capsule is lined with a single layer of flattened epithelial cells, each with a flattened oval nucleus. In the young state these epithelial cells are less flattened, being more or less polyhedral.

The glomerulus is a network of convoluted capillary blood-vessels, grouped into two, three, or more conical lobules. These lobules occupy the cavity of the capsule of Bowman, without, however, filling it. The space between the surface of the glomerulus and the capsule varies greatly in the normal and abnormal conditions, according to the different states of secretion, being dependent on the amount and nature of the secretion present in it. The capillary blood-vessels of the various lobules of the glomerulus are held together by a homogeneous connective tissue, in which are

embedded flattened nucleated branched connective-tissue cells (Axel Key). The lobules of the glomerulus are covered with a membrane composed of a single layer of nucleated epithelial cells, which membrane dips in even between the capillaries of a lobule (Heidenhain).

The epithelial covering of the glomerulus is continuous with the epithelial lining of Bowman's capsule; this condition is due to the fact that, in the development of the Malpighian corpuscle, the extremity of the fœtal urinary tubule becomes invaginated by the progressive growth of the embryonal glomerulus. Bowman's capsule appears thus inflected over the latter.

The younger the Malpighian corpuscle the more distinct is the epithelium covering the glomerulus; in the human fœtus it is made up of polyhedral or even short columnar cells, at a time when the epithelium lining Bowman's capsule is already much flattened, as is well shown in fig. 2 of Plate XXXVIIA.

The glomerulus of each Malpighian corpuscle is connected with an afferent and efferent vessel; both these lie closely side by side where they join the glomerulus, and form, as it were, the peduncle of this latter.

The Malpighian corpuscles vary in size; they are generally larger in the parts of the cortex nearest the boundary layer, and decrease in size towards the surface of the cortex (Drasch).

2. Opposite this peduncle, Bowman's capsule passes into the urinary tubule through a short narrow neck. The flattened epithelium lining the former is not always easily followed into the latter, and consequently the cavity of the neck, which of course is a continuation of the space of the Malpighian corpuscle, appears as if without any epithelial lining, the membrana propria alone forming the wall of this part.

3. Immediately after the neck the urinary tubule becomes enlarged and much convoluted, and this has been above referred to as the proximal convoluted tubule. Its limiting membrana propria is a direct continuation of the hyaline capsule of Bowman, and it is lined with a single layer of epithelial cells. The tube possesses a distinct cavity of about one third or more of the whole diameter of the tube.

The membrana propria remains the same through all sections of the urinary tubule in the cortex and medulla. There are in some places oblong flattened nuclei to be recognised in this membrane, as if it were composed of endothelial plates; minute septules containing here and there an oblong or angular nucleus pass from the membrana propria in amongst the epithelial cells lining it, similar to what is the case in gland tubes of other organs, as described in previous chapters.

Now, with the exception of the descending limb of Henle's loop (5), the loop itself (6) and all parts of the collecting tube (12, 13, 14, 15 and 16), the epithelial cells lining the membrana propria of the other sections are made up of a substance containing

more or less complete rods or fibrils, placed vertically to the long axis of the tube. This fact was first pointed out by Heidenhain and is easily verified in the kidney of most mammals and man, especially when prepared with chromate of ammonia. These rods or fibrils, as already shown by Heidenhain, are generally most distinct in the outer part of the epithelial cell, that is the part near the membrana propria, while the inner part appears more uniformly and finely granular. But the rods or fibrils, when looked at from the surface, are clearly connected into a network (Klein), so that they are more probably septa of a honey-combed network seen in profile.

Wherever the cells show these 'rods,' their (cells) shape is polyhedral, or in some parts, to be presently mentioned, more or less flattened; many of them are angular and possessed of minute prolongations wedged in between neighbouring cells.

In the proximal convoluted tubule (3), now under consideration, the epithelial cells are, on the whole, polyhedral or short columnar. They are of unequal size, some being broader and longer than others. The sides of the cells are not straight, but either convex or concave, the convex sides of one cell fitting into the concave ones of its neighbours. The outer angles, viz. those next the membrana propria, possess in some cells short angular prolongations.

As already mentioned, they show distinct vertical striation, especially in the outer part of their substance.

A spherical nucleus is found in each cell in about the middle of its substance.

The first epithelial cells immediately next the neck are much shorter than the following ones, and this produces the appearance of a sudden tapering off of the epithelium towards the neck.

The height of the lining epithelial cells and the lumen of the tube vary considerably in the convoluted tubules in different kidneys of man and mammals and in different parts of the same kidney, for in some instances the epithelial cells are considerably larger, being cylindrical with convex free surface, and the lumen consequently smaller than in others. The substance of the cells is in these tubes more opaque than in those with polyhedral cells and large lumen. Judging by analogy from the experience of Stricker and Spina, this is probably due to a difference in the state of function, the latter appearance, viz. the cylindrical cells, the small lumen and the lesser transparency of the tubule as a whole, indicating an active state of secretion.

4. The spiral tubule, first pointed out by Schachowa as a definite section, possesses a more or less spiral course in the medullary ray; its thickness and the relation of its more or less columnar epithelium and lumen are about the same as in the convoluted tubule, just described. The striation of the epithelial cells is very distinct in the first part of the tube, but gradually, as the boundary layer is approached, it becomes less so,

the substance of the epithelial cells assuming a homogeneous aspect. In many instances the substance of the epithelial cells is in this section, on the contrary, of a reticular nature, the meshes being of a relatively large size.

As regards the first part of the spiral tubules, a distinction may be also noticed between tubes possessing a large lumen lined with comparatively transparent, short polyhedral epithelial cells, and tubes whose lumen is much smaller, the epithelium more opaque, and its cells more columnar.

The irregularity and inequality in the epithelial cells lining this tube are still more conspicuous than in the preceding section, especially in the first part of the former. These irregularities lead to a distinction into thin columnar cells with concave sides, and broader spheroidal cells with convex sides and convex free surface, and hence possessing a fungoid shape, 'fungoid cells' of Schachowa.

5 and 6. The descending limb of Henle's loop and the loop itself are exceedingly thin tubes, whose membrana propria is lined with a layer of very flat transparent cell plates, each possessed of an oval flattened nucleus. These tubes resemble in size and transparency capillary blood-vessels, but differ from them by the greater number of their nuclei and by the presence of a membrana propria outside the layer of cell plates. But this distinction into a membrana propria and lining cell plates is not always easily made.

7. As mentioned above, just where the ascending limb of Henle's loop enters the boundary layer it becomes suddenly enlarged, but reaches its greatest breadth a little distance from its entrance into this layer. The epithelial lining is again composed of polyhedral cells with very distinct vertical rods, when viewed in profile; each cell is possessed of a spherical nucleus situated in the innermost part of the cell, i.e. next the lumen. This latter is very conspicuous. The outline of the tube is not straight, and its breadth varies slightly from place to place.

8. About midway in the boundary layer the tube becomes again narrower and follows a more or less spiral course, hence it may be called the spiral portion of the ascending limb. Its outline is irregular, and it differs from the preceding by being narrower, and its lumen very small, just perceptible as a narrow canal. The epithelial cells lining it are short polyhedral, and show in the profile view very coarse thick rods, much more distinct than in any of the previous sections. Many cells appear possessed of short processes and more or less distinctly imbricated, a fact already known to Steudener. Each cell possesses a spherical or irregular or flattened nucleus situated near the lumen.

In the human kidney the substance of the epithelial cells of this section includes occasionally a considerable amount of brownish pigment granules (Klein).

9. When entering the medullary ray in the cortex the ascending limb becomes narrower; while ascending in the medullary ray it varies in thickness, in some places becoming again as thick as the preceding section of the boundary layer.

The lumen is very small, and the epithelial cells are the more flattened the narrower the tube; but they retain the flattened or angular nucleus next the lumen, and they also show the rods, but distinctly only in the outer part, i.e. next the membrana propria. Just like the cells of the previous section, they appear in many places very angular and possessed of processes, and imbricated.

10. The irregular tubule is one of the most conspicuous sections; it is situated amongst the convoluted tubules of all parts of the labyrinth, and has a very irregular and angular outline, in some places three and four times as thick as in others, and then of almost the same breadth as a convoluted tubule. But this greater thickness is due merely to a greater thickness of the lining epithelial cells, the lumen remaining everywhere a very narrow canal. The cells show in the profile-view exceedingly thick rods of a bright homogeneous aspect, more distinct than in any other section of the urinary tubule.

The cells are very angular and in many places imbricated. But in this, as in the former cases, this imbrication is due to the irregular outline of the tube and the great variation in height of the adjacent cells. Each cell possesses an oval or angular nucleus next the lumen.

11. The intercalated section of Schweigger-Seidel, or the distal convoluted tubule, is situated wherever the proximal convoluted tubule is found, with which it is identical in all respects.

12 and 13. The curved part of the collecting tube and the next following straight section of the collecting tube, situated in the medullary ray, are thin tubes with a distinct lumen, lined by a single layer of homogeneous cells, each with a spherical or oval nucleus. The shape of these cells varies greatly, some being polyhedral, others spindle-shaped and flattened, and still others angular and possessed of short processes.

14. This section of the collecting tube belongs to the boundary layer; it is broader than the preceding one, its lumen being larger and the lining epithelial cells more polyhedral, although there are still some more or less flattened cells amongst them. Many of the cells are angular, being drawn out into short processes. Each cell possesses a homogeneous matrix, and in it a spherical or oval nucleus. In the human kidney the epithelial cells of this section of the collecting tube are short columnar, but otherwise similar to those described just now.

With the exception of the descending limb of Henle's loop (5) and the loop itself (6), there appears in all other sections of the urinary tubules of the cortex and boundary layer of the kidney of the dog a delicate membrane lining the inner surface of the

epithelium, that is next the lumen. From place to place an oblong nucleus can be seen in it more or less distinctly wedged in between the epithelial cells. In the convoluted tubules (both sections) and in the spiral tubule (9) the number of nuclei of this *centrotubular membrane* is very small, but in the ascending limb of Henle's loop, especially in sections 8 and 10 of diagram 1, and also in the collecting tubes of the cortex, their number is considerable. They appear also here situated in depressions of the epithelium, and owing to the lumen of the tube being very narrow, as in sections 8, 9, 10 and 12, the former appears almost entirely occupied by the centrotubular membrane and its nuclei.

15 and 16. The collecting tubes and ducts of the papillary portion possess a comparatively large lumen lined with columnar transparent cells, each with an oval nucleus. The collecting tubes of the papillary portion join so as to form larger tubes; the size of their lumen and the height of their lining epithelial cells are dependent on the size of the tube.

The nuclei of all epithelial cells of the urinary tubules show a more or less distinct intranuclear network within a limiting membrane. This network is best shown in the nuclei of the human kidney, and here again in those of the collecting tubes and ducts.

Heidenhain, on the occasion of the discovery of the 'rod-structure' of the substance of epithelial cells in the convoluted tubules (both sections) and in the ascending limb (of Henle's loop), both in the medulla and cortex of the mammalian kidney, made the important observation that pigment matter (indigo-sulphate of sodium, phœnicin-sulphate of sodium) injected into the circulating blood of the dog and the rabbit is excreted by the epithelium of all those sections of the urinary tubules that possess the above-named rod-structure. Heidenhain maintains that the pigment is excreted through the substance of the epithelial cells themselves (rods and nucleus). Examining the kidney of the cat, into whose circulating blood carmine in ammonia had been injected, I find that carmine granules are present *in the interstitial substance between the epithelial cells* of the same sections of the urinary tubules, as in the above cases of Heidenhain, but not in the substance of the cells themselves. This is quite in accordance with what has been shown as regards the excretion of pigment in other epithelial and endothelial structures, as mentioned on former pages in connection with the observations of Thoma, Arnold, Küttner, and others (see p. 176), viz. that the pigment is deposited *between* and not *in* the epithelial or endothelial cells themselves.

The Blood-vessels.

These form distinct sets of vessels for the membrane of the pelvis, for the capsule, for the cortex, and finally for the medulla. Those of the pelvis and calices terminate as a network of capillaries underneath the epithelium. The arterial branches of the capsule are derived either from the extrarenal parts or from the cortical arteries, viz. from the interlobular branches. The efferent veins of the capsule are likewise of two kinds, viz. such as empty themselves into extrarenal veins and others leading into the stellate veins of the cortex. The former generally run in twos, in company with the arterial branches. The capillaries of the capsule are very numerous, and form a network with uniform meshes.

The large trunks of the arteries and veins, both for the cortex and medulla, penetrate, as already mentioned, from the submucous tissue of the pelvis into the boundary between cortex and medulla, whence they send off or take up respectively the branches supplying the cortex and medulla.

a) In the *cortex*. The arterial branches ascend from the first-named trunks in the middle of the sections of the labyrinth situated between two neighbouring medullary rays. These arterial branches are called the interlobular branches. While ascending towards the periphery of the cortex they give off from all sides of their circumference short vessels, the afferent arterioles, running transversely, one for each Malpighian corpuscle, where they break up into the network of capillaries forming the glomerulus described on a previous page. Some of the afferent arterioles before entering the Malpighian corpuscle give off a short lateral branchlet that breaks up into capillaries for the convoluted tubules.

Many arteriæ interlobulares are exhausted when they reach the periphery of the cortex, that is the part that does not contain any Malpighian corpuscles; but some penetrate into this layer, and terminate in the capillary blood-vessels, surrounding with their meshes the convoluted tubules; and finally a small number pass even beyond this layer and penetrate into the outer capsule, as mentioned above.

The efferent vessel of the Malpighian corpuscle is a venous vessel, and breaks up into a dense network of capillaries that entwine all tubes both of the labyrinth, including the peripheral layer, as well as of the medullary rays, the meshes of the former being more round, those of the latter elongated. In addition to the efferent vessel of the Malpighian corpuscles, the above-named branches of the afferent arterioles, and, for the peripheral layer of the cortex, the last outrunners of the interlobular arteries are to be named as supplying the capillaries of the cortex. The network of capillaries of the labyrinth and medullary rays forms one continuous system for the whole cortex.

The venous branches are distributed in the labyrinth, in the following manner. The capillaries of the peripheral layer of the cortex, viz. that without Malpighian corpuscles, lead into minute venous rootlets which open into a vena stellata, called so from the manner of the arrangement of its rootlets. Each vena stellata passes into the labyrinth of the cortex, and accompanies the arteria interlobularis as the vena interlobularis. On its way it takes up transverse branches coming from the capillary network of the labyrinth. The venæ interlobulares lead into the venous trunks situated between the cortex and medulla.

b) In the *medulla*. From the large arterial trunks situated between the cortex and boundary layer short branches are given off, which having entered the latter split up into bundles of straight arterioles, the arteriolæ rectæ.

The vessels belonging to one such bundle are all arterioles, and their number is increased by the addition of the vas efferens of the Malpighian corpuscles situated next the boundary layer.

These arterioles run in the boundary layer between the bundles of urinary tubules which, as mentioned on a former page, are the continuations of the medullary rays. On their way towards the papilla their number gradually decreases as they pass laterally into a network of capillaries for the urinary tubules, the meshes of which are elongated. At the margin of the cortex and medulla the capillaries of the former are continuous with those of the latter.

The veins originate as single vessels, beginning at the papilla, and their number is gradually increased by vessels coming out from the capillary network of the urinary tubules. Just like the arteries, so also the veins form bundles, venæ rectæ; these bundles are very considerable while running through the boundary layer between the continuations of the medullary rays. They empty themselves into the trunks situated between the cortex and medulla. The bundle of urinary tubules forming, in the boundary layer, the continuation of a medullary ray, has on one side a bundle of arteriæ rectæ, and on the other one of venæ rectæ; and between them there is a network of capillary vessels with elongated meshes winding round the urinary tubules.

Near the papilla the vessels form a uniform network with elongated meshes, and on the summit of the papilla itself we find around the mouth of each urinary duct a very delicate network of capillary veins.

In the foregoing description of the blood-vessels, I have followed Ludwig in his article on the Kidney, in Stricker's 'Manual of Histology.' The diagram 3 of Plate XXXVIIA., copied from Ludwig, gives a clear view of the distribution of the vessels in the cortex and medulla.

Numerous lymphatics arranged in a plexus are present in the capsule of the kidney; they may be traced into lymph spaces between the convoluted tubules of the periphery of the cortex (Ludwig). In the connective tissue accompanying the large blood-vessels may be seen a plexus of lymphatic vessels; from these the injection matter passes freely into the lymphatics of the capsule and into the lymph spaces between the urinary tubules both of the cortex and medulla.

The Ureter and Bladder.

The ureter is lined with stratified transitional epithelium; this consists of: a superficial layer of polyhedral cells of various sizes, each with one, two or more spherical or oval nuclei; then follows a layer of club-shaped or pear-shaped columnar cells, each with a spherical or oval nucleus; the broad part of the cells is directed towards the surface, the narrow stalk towards the depth; between these are wedged in other cells, spindle-shaped or conical cells, each with a flattened oval nucleus (see Chapter II.). The number of layers of these deep cells varies in different parts and according to the state of contraction of the ureter; it is greater in the contracted, smaller in the less contracted state. In the former state the epithelium as a whole is much thicker at the base than at the top of the folds.

The mucosa underneath the epithelium is a connective-tissue membrane, containing a dense network of blood capillaries in almost immediate contact with the epithelium (Engelmann). The loose submucous connective tissue is continued, as septa, between the muscle bundles of the next or muscle coat. This consists of bundles of unstriped muscle cells, which bundles form networks. They are grouped into an inner and outer longitudinal and a middle circular coat. Fibrous-connective tissue forms an outer thin sheath or adventitia.

There are rich plexuses of non-medullated nerves in the muscular coat, which in all respects resemble the ground plexuses already mentioned of the unstriped muscular tissue. In the nerve branches of the adventitia Obersteiner, and also Dogiel, observed ganglion cells.

The bladder is almost identical in structure with the ureter, with the difference that the mucosa, submucosa, muscular coat and adventitia (peritoneum) are much thicker. In the muscular coat the bundles run in a more irregular direction: in the greater part of the bladder those next the submucosa are more or less circular; outside these are bundles running more obliquely; and the outermost layer is composed of longitudinal bundles (Jurié). Towards the fundus the longitudinal bundles greatly prevail.

In connection with the plexus of non-medullated nerve fibres of the serous and subserous connective tissue are numerous smaller and larger ganglia (Fr. Darwin); some of the nerve branches connected with them have an intimate relation to the large blood-vessels of these parts.

In connection with the nerve branches of the muscular coat are also groups of ganglion cells; they have been figured in Plate XXIII. and described on p. 120.

According to Kisselew the nerve fibres of the mucosa terminate in special cells situated amongst the epithelial cells of the inner surface.

PLATE XXXVIIA.

Fig. I. is a diagram showing the course of the renal tubules and their variations in the different sections of the cortex and medulla.

A. Cortex limited on its free surface by the capsule.

a. Subscapsular layer not containing Malpighian corpuscles.

a_1. Inner stratum of cortex without Malpighian corpuscles.

B. Boundary layer.

C. Papillary part next the boundary layer.

1. Bowman's capsule of the Malpighian corpuscle.

2. Its neck.

3. Proximal convoluted tubule.

4. Spiral tubule of Schachowa.

5. Descending limb of Henle's loop.

6. The loop proper.

7. Thick part of the ascending limb.

8. Spiral part of the same.

9. The narrow ascending limb in the medullary ray.

10. The irregular tubule.

11. The intercalated section of Schweigger-Seidel, or the distal convoluted tubule.

12. The curved collecting tubule.

13. The straight collecting tubule of the medullary ray.

14. The collecting tube of the boundary layer.

15. The large collecting tube of the papillary part.

In the papilla itself, not represented here, this tube becomes confluent with others and thus forms:

16. The duct.

I

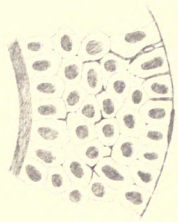

V

II

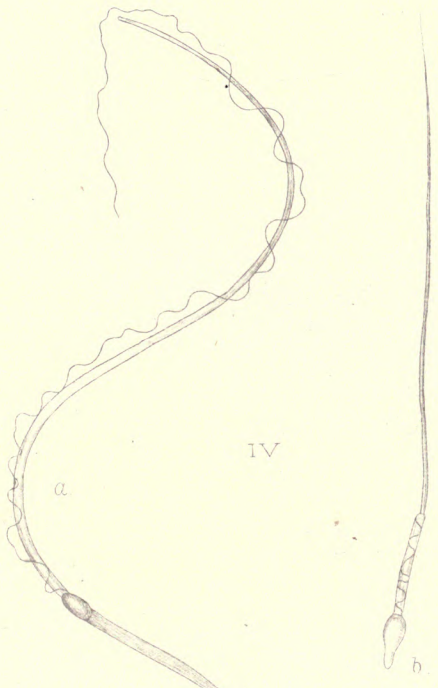

IV

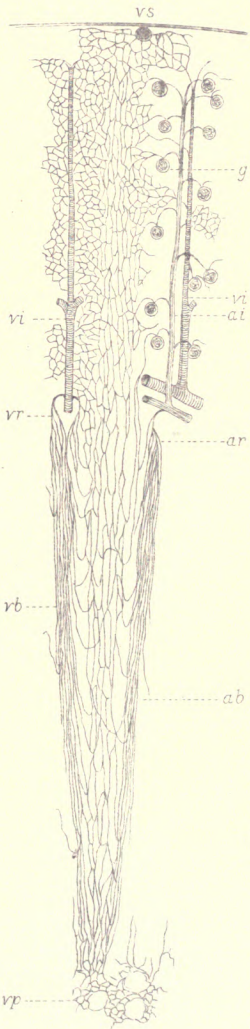

III

E. Noble Smith, fecit

Mintern Bros imp.

LIBRARY
OF THE
UNIVERSITY
OF
CALIFORNIA

I

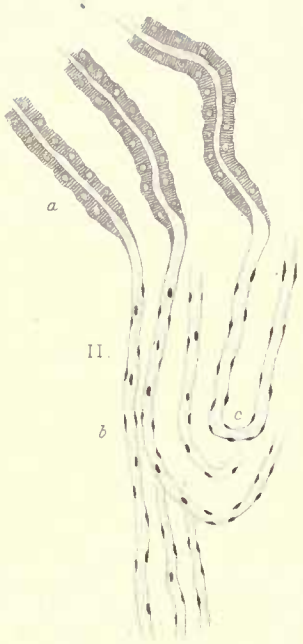



III

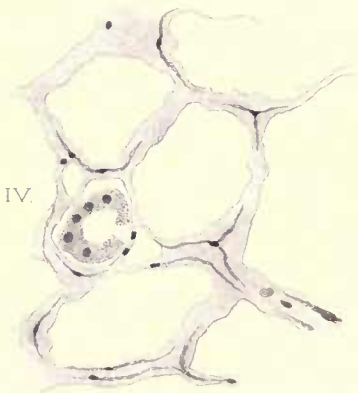

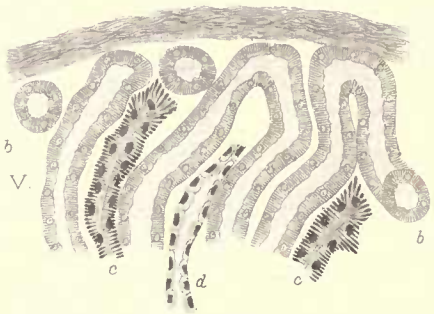

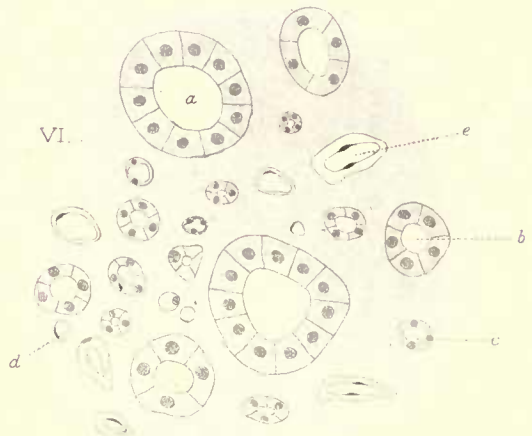

VII

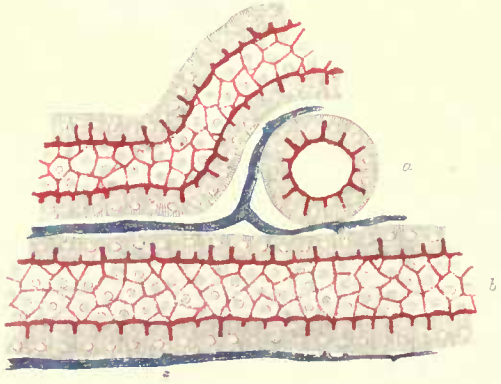

VIII



IX

Fig. II. Copied from Klein, fig. 149 in 'Handbook for the Physiol. Laborat.' Magnifying power about 350.

From a section through the cortical substance of a human fœtal kidney.

a. Glomerulus.

c. Epithelium covering the glomerulus.

d. Flattened epithelium lining Bowman's capsule.

f. Urinary tubules in section.

Fig. III. Copied from Ludwig, fig. 150 in Stricker's 'Manual of Histology.'

Diagram of the vessels of the kidney.

ai. Interlobular artery.

vi. Interlobular vein.

g. Glomerulus of Malpighian corpuscle.

vs. Vena stellata.

ar. Arteria recta.

vr. Vena recta.

ab. Bundle of arteriolæ rectæ.

vb. Bundle of venæ rectæ.

vp. Network of vessels around the mouth of ducts.

Fig. IV. Two fully developed spermatozoa, as seen under a high power. Copied from H. Gibbes, in 'Quarterly Journal of Micro. Sciences,' October, 1879.

a. Of triton cristatus.

b. Of horse.

Fig. V. From a section through the ovary of a rabbit, prepared in chloride of gold, showing part of the epithelium lining a Grafian follicle, as viewed in profile. A very beautiful nucleated reticulum is seen stretching from the membrana propria to the zona pellucida of the ovum between the epithelial cells of the membrana granulosa. Magnifying power about 350.

PLATE XXXVIII.

Fig. I. From a vertical section through the kidney of the dog, showing part of the labyrinth and the adjoining medullary ray.

The capsule of the kidney is supposed to be on the right-hand side. Magnifying power about 350.

a. The capillaries of the Malpighian corpuscle, viz. the glomerulus, are arranged in lobules. Bowman's capsule with its lining of flat epithelial cells, and the flat epithelial cells covering the glomerulus, are well shown.

The stalk of the glomerulus is directed to the left, and is cut away obliquely.

n. Neck of the Malpighian corpuscle.

c. Convoluted tubules cut in various directions.

The rodlike structures in the substance of the polyhedral epithelial cells is well shown.

b. The irregular tubule, 10 in diagram 1 of the preceding Plate.

d. e. and *f.* belong to the medullary ray.

d. Collecting tube (13).

e. Spiral tube (4).

f. Narrow section of the ascending limb (9).

The nature of the lining epithelium and its differences in these various tubes is well marked; see the text of this chapter.

Fig. II. From a vertical section through the same kidney as in fig I., showing the tubes of Henle's loops at the point of transition from the papillary part into the boundary layer. Magnifying power about 300.

a. The first thick part of the ascending limb (7 of diagram 1 of the preceding Plate) at the point of demarcation of the papillary part and the boundary layer.

b. and *c.* The transparent thin tubules of Henle's loops.

Fig. III. From a vertical section through the cortex and boundary layer of the kidney of the dog; showing the blood-vessels injected with Berlin blue. Low magnifying power.

a. Peripheral subscapsular part of the cortex.

b. Cortex, showing the glomeruli of Malpighian corpuscles, the dense network of capillaries of the labyrinth and of the medullary rays. The thin branches of the large vessels are the interlobular arteries, the thick ones the interlobular veins.

c. Boundary layer showing the bundles of arteriolæ rectæ and venæ rectæ; see diagram 3 of preceding Plate; between these bundles are seen the capillaries, forming a network with elongated meshes around the urinary tubules.

Fig. IV. From a horizontal section through the cortex of the human kidney, showing the honey-combed transparent matrix in which the urinary tubules and the capillary blood-vessels are embedded; a few branched nucleated connective cells are seen in it.

The large cavities correspond each to a transverse section of a urinary tubule, whose epithelium, except in one tube, has been removed by accident. The two small holes, at the side of the tubule whose epithelium is still present, are transverse sections of capillary blood-vessels. Magnifying power about 400.

Fig. V. From a vertical section through the same kidney as in fig. I. Magnifying power about 300.

a. Capsule of the kidney.

b. Convoluted tubules cut in different directions.

c. Irregular tubule (10).

d. Curved part of the collecting tube (12).

Fig. VI. From a horizontal section through the papillary portion of the human kidney. Magnifying power about 300.

In a uniformly stained transparent ground substance, which in reality is composed of fibrous connective-tissue, are seen urinary tubes and blood-vessels cut transversely.

a. Large collecting tubes.

b. Smaller ones.

c. Tubes of Henle's loops.

d. Capillary blood-vessels.

e. Venous capillaries; the endothelium is accidently detached from the wall of the vessels.

Fig. VII. From a vertical section through the same kidney as in fig. I., showing under a very low power the adjoining portions of the cortex and the boundary layer.

a. Labyrinth containing Malpighian corpuscles and convoluted tubules cut in various directions.

b. Bundles of urinary tubules of the boundary layer continued into the cortex as the medullary rays.

c. Bundles of blood-vessels, arteriæ or venæ rectæ.

Fig. VIII. From a vertical section through the labyrinth of the kidney of the cat, into whose circulating blood carminate of ammonia had been injected.

a. Convoluted tubules cut transversely.

b. Part of a spiral tubule of the medullary ray.

Between the tubules are capillary blood-vessels, injected with Berlin blue. The carmine is deposited, that is, has been excreted, not in the substance of the epithelial cells, but in the cement substance between them. When seen from the surface, the outlines of the epithelial cells are marked as a beautiful pink mosaic. Magnifying power about 350.

Fig. IX. From a vertical section through the cortex of the human kidney as seen under a very low power.

a. Capsule.

b. Urinary tubules cut in various directions.

c. Medullary rays and between them the labyrinth of tubules with Malpighian corpuscles.

The medullary rays are lost at some distance from the capsule; see the text of this chapter.

Owing to the very low power structural distinctions of the urinary tubules cannot be recognised.

CHAPTER XXXI.

THE MALE GENITAL ORGANS.

Testis and Epididymis of Man and Mammals.

The *framework.*—The capsule of the testis consists of an external and internal fibrous coat. The external coat, the tunica adnata, or the visceral layer of the tunica vaginalis propria, is a serous membrane, and consequently is a dense connective-tissue feltwork, with numerous elastic fibrils connected into a network. It is supplied with a network of capillaries and numerous nerve fibrils arranged in a plexus. On its outer or free surface it is covered with a single layer of flattened endothelial plates. Minute villi projecting from the surface contain, according to the state of development, a greater or smaller amount of connective-tissue; they are continuous with the ground membrane and are covered with germinating endothelial cells (see Chapter III.). The internal coat, or the tunica albuginea, is of lamellar structure, the lamellæ being composed of bundles of fibrous connective-tissue with the corresponding flattened connective-tissue cells. Its thickness increases towards the posterior margin of the testis, in which place, in the human organ, there exists a considerable accumulation of it, as the corpus Highmori, or the mediastinum testis.

As shown by Messing, the testis of the dog, cat, bull, pig, sheep, rabbit, hare, guinea pig, &c., possesses a central corpus Highmori; that of the mole, hedgehog, and bat a peripheral one; the rat and mouse have no corpus Highmori.

Numerous septa extend from the sides and front between the albuginea and the corpus Highmori; these septa are of the same structure as the albuginea and the corpus Highmori. Unstriped muscular fibres are mentioned by Kölliker as present in them. A dense plexus of lymphatics, being the efferent vessels, is contained in the capsule of the testis, most vessels being situated between the outer and inner coat. The inner coat possesses also a rich network of blood-vessels.

The connective-tissue septa are continuous with the connective-tissue existing between the seminal tubules, and are the carriers of the blood-vessels. The intertubular or interstitial connective-tissue, which has been carefully studied by Mihalkovics, in the confirmation of whose observations I join Gerster, has a conspicuously lamellar structure; each lamella consists of: (*a*) an endothelial membrane, that is, a hyaline membrane

composed of endotheloid plates (connective-tissue corpuscles), each with a clear, oval flattened nucleus; and (*b*) a small amount of fibrous connective-tissue, arranged as a plexus of fine bundles, or fenestrated membrane. The endothelial membrane covering this plexus is not a continuous membrane, but perforated by numerous holes which, coinciding with the fenestrations of the plexus of fibre bundles, forms the means of communication between neighbouring interlamellar spaces. These spaces are lymph spaces, and they are the rootlets of the lymphatic system of the testis (Ludwig and Tomsa), the above-mentioned endothelial membrane being a one-sided endothelial lining of the spaces; its presence has been known to Frey, Tommasi, Kölliker, v. La Valette St. George, and others.

The number of lamellæ present between the seminal tubes varies greatly in the testis of different animals, and in different parts of the same testis; in some animals (cat, dog) it is very considerable, in others only indicated (rat, mouse). The relation between the lamellæ and the seminal tubes is a very intimate one, but depends in a great measure on the amount and distribution of the fluid present in the interlamellar lymph spaces. For it is clear that if the interlamellar spaces, midway between two contiguous tubules, be distended, while those next the tubes are collapsed, the appearance will be produced as if the lamellæ next the tubes were part of the limiting membrane of the latter (Henle, Frey, Hessling, Kölliker, and others); but their separate and independent nature is easily recognised in places where the interlamellar spaces next the membrana propria of the seminal tubes are distended. It is then ascertained that the former, viz. the membrana propria, is a single homogeneous membrane, separated by a lymph space from the lamella next to it. The oval nuclei, present in the membrana propria (see below), are not to be confounded with those of the endothelial cells outside.

In the rat there exists only a very small amount of this intertubular connective tissue, and in many parts the seminal tubules are separated from each other by an open lymph space; in this case the membrana propria is covered with a continuous layer of beautiful endothelial plates.

Between the lamellæ of the intertubular connective-tissue are found groups of peculiar cells, arranged as longer or shorter, thicker or thinner, cylindrical, plate-like, or irregularly shaped, anastomosing masses. They are known since Kölliker, and have been considered by this observer as indifferent cells of the connective-tissue. Subsequent observers, especially Henle and Leydig, gave their attention to these cells; Waldeyer and Mihalkovics regard them in the same light, and consider them as the interstitial or parenchymatous connective-tissue cells. R. Harvey thinks these cells are ganglion cells. I have described them as epithelial cells, being derived from the epithelial columns of the Wolffian body, and corresponding to similar cells found in the ovary (see below). I consider them as intertubular, or interstitial, epithelial cells.

These cells are polyhedral, each with a spherical nucleus situated in the centre (cat and dog), or excentrically (guinea pig, boar). The cell substance appears 'granular,' but is in reality an exceedingly beautiful and dense network. In some instances (guinea pig) there are brownish-yellowish pigment granules contained in the cell substance. The nucleus includes within a distinct membrane a pale, honey-combed reticulum, containing occasionally one, seldom more, thickenings, nucleoli. The intranuclear and intracellular reticulum form a direct continuity.

As mentioned above, the groups of intertubular epithelial cells are situated between the lamellæ. Their number varies in different animals. They are most abundant in the dog, cat, and especially boar, where they form a predominant portion of the whole testis (Leydig). In this last instance the masses of these intertubular epithelial cells are supplied with their special system of blood-vessels.

The *parenchyma* consists of the seminal tubes, arranged in the well-known lobules between the above connective-tissue septa. The tubes are relatively large and very wavy and much convoluted; they possess a few lateral branches, by which they become connected into a network; they form terminal loops; in the peripheral portion of the testis the tubules are possessed of minute lateral cæcal branchlets (Mihalkovics). These branchlets are especially well shown in the young state (v. la Valette St. George).

Each seminal tubule in the adult testis is limited by a membrana propria, which appears as a hyaline elastic membrane, and containing oval, flattened nuclei at regular intervals, is probably an endothelial membrane. It is supported on its outside by the lamellæ of the intertubular tissue. Inside this membrana propria are several layers of epithelial cells, the *seminal cells*. Of these may be distinguished *the outer*, and *the inner* layer of cells. The former are situated next to the membrana propria. They are more or less polyhedral in shape, of about the same size, and possess faint outlines. They correspond to the germ-cells of Sertoli; their substance is transparent, and appears uniformly and finely granular, which appearance is due to the presence of a delicate reticulum. Each of these cells possesses a nucleus, and in this respect, and in this respect only, the cells are of two very distinct types (Klein): (*a*) such as contain an oval, transparent nucleus, limited by a definite membrane, and containing a more or less well-developed, honey-combed reticulum, with generally one, and occasionally two, or even three, irregularly shaped thickenings, or nucleoli; (*b*) the cells of the second type include each a spherical nucleus; this is slightly smaller than that of the former cells, it has no definite limiting membrane, and contains in a transparent matrix a beautiful convolution of relatively thick and short filaments, or rods, twisted in many directions,

and anastomosing with one another by relatively few lateral branchlets. These fibrils, or rods, stain very well in dyes, and, when looked at under a low power, present themselves as spherical, or more or less elongated, isolated dots, that is, according to whether they are viewed in optical transverse, oblique, or longitudinal section; but, under a high power and on careful focussing, it is soon ascertained that they are in reality fibrils or rods arranged in more or less complex convolutions.

Next to this outer layer of cells, but nearer to the lumen, are *the inner seminal cells* (celluli seminales of Sertoli); only in few tubes are these cells limited to one or two layers, generally they are arranged in more than two layers. These inner cells are polyhedral where they are situated closely side by side, but more spherical next the lumen of the tube, because more loosely connected with one another; they are of about the same size, and composed of a transparent substance with faint outlines, and include a single nucleus; this is identical with the nucleus of the above second type, viz. it is spherical, does not possess any limiting membrane, and contains a beautiful convolution of thick fibrils or rods in a transparent matrix. Whether the cells lie closely side by side, as is the case with those of the outer layer and those immediately next to it, or not, as those near the lumen of the seminal tube, they are always separated by a transparent interstitial substance; in the former case there is only a trace of it. A nucleated reticulum, in the meshes of which the seminal cells are contained, is found in some places to occupy that interstitial substance. This reticulum, first discovered by Sertoli, and called germ-reticulum by v. Ebner, supporting cells by Merkel, is not accepted by Mihalkovics; but there can be no doubt about its existence in the seminal tubes (Afanassiew). Its significance is probably no other than that of a similar reticulum, mentioned in former chapters in connection with various other glands, viz. it is continuous with the membrana propria and forms a support for the lining epithelial cells.

Now, when examining more carefully the fibrils of the nuclei of the second type of the outer cells, and those of the nuclei of the inner cells, it will be found that their arrangement is subject to certain definite variations: (1) either the fibrils form a uniform convolution, that is, they are distributed uniformly throughout the nucleus, being more or less twisted and united into a network; or (2) the fibrils are arranged in the periphery, but transversely in one and the same direction; a nucleus of this sort, when viewed in the direction of the fibrils, appears as if transversely ribbed, but viewed vertical to it, as if dotted at the periphery; or (3) the fibrils radiate towards one or two centres. All these differences indicate changes preparatory to division, as is now well known from the works of Strassburger, Hertwig, Mayzel, Eberth, Balfour, Schleicher, Peremeschko, and especially Flemming, whose very extensive and beautiful observations on the changes of the nucleus during division have been found fully confirmed by myself

in the case of the epithelial cells of the newt. As will be minutely considered in a future chapter, the above forms correspond to what is termed (Flemming, Klein): the 'convolution,' the 'basket,' the 'wreath,' the 'monaster,' or the 'dyaster.'

The oval nucleus, with the transparent, honey-combed reticulum, viz. the nucleus of the first type of the outer seminal cells, corresponds to a 'resting nucleus' (Flemming), that is, a nucleus not in the state of division. The number of these 'resting nuclei' is subject to considerable variations in different tubes; while in some they are relatively few and limited only to the outer layer of cells, we find, in others, their number much greater, and not limited only to the outer layer of cells, but present also, though very rarely, amongst the cells of the inner layers.

Towards the lumen of the tube the cells, as already mentioned, are loosely connected, and, in some places, their nucleus is seen in the very state of dividing, or already divided, into two small *daughter nuclei*, each with fibrils and rods of a similar arrangement as before the division (see a future chapter). In the latter instance the cell itself is just dividing, or has already divided, into two small *daughter cells*, each with one daughter nucleus. The cell substance of these daughter cells is less transparent than that of the mother cell, and its outline is very well marked.

The mother nucleus, as well as the daughter nuclei, during division, or immediately after, shows, as a rule, very clearly, in well prepared and stained sections, the above-mentioned arrangement of the fibrils or rods, but in some places the latter (fibrils or rods) are not distinct, the nucleus or nuclei appearing as a more or less uniform knobbed single or double clump, staining deeply in dyes.

In some tubes the number of the (small) daughter cells is greater than in others; in the former they may be found arranged in several layers loosely connected with one another.

Amongst the seminal epithelial cells with one nucleus are found, especially in the cat and dog, occasionally, but on the whole not frequently, large multinuclear cells. Where they occur they are found in groups, but the individual cells are more or less separated from one another. They are of very various sizes; some have a limited number of nuclei (2–4), others have 8–12 or more. The cells are spherical, and each of the nuclei contained in them is spherical, and of precisely the same nature as those of the inner seminal epithelial cells, viz. without a definite membrane and containing filaments or rods arranged in a complex manner, preparatory to division.

In few instances of the testicle of the cat are found, besides the multinuclear cells just mentioned, other large cells with one or several homogeneous nuclei deeply staining in logwood; these nuclei appear irregularly shaped, lobed, or possessed of knob-like prominences.

Now, the small cells, mentioned above as the daughter cells, undergo very interesting

changes, leading to the formation of the spermatozoa; for this reason they may be called the *spermatoblasts* (Sertoli). In describing these changes I shall refer to observations on the testis of man and various mammals (rabbit, mouse, guinea pig, dog, cat, and boar), which, although not completed yet, nevertheless permit already of a general statement of the plan of the formation of the spermatozoa.

Starting with the above-mentioned daughter cells or spermatoblasts, each with one small nucleus and arranged loosely next the lumen of the tube, we find that soon after their formation, their nucleus, while retaining its spherical shape, alters in so far as it becomes invested in a distinct membrane, and its convolution of fibrils or rods changes into a transparent honey-combed reticulum, in many instances without, but in some with one or two thickenings, nucleoli; that is to say, the nucleus becomes similar to what has been mentioned on the previous page as a 'resting,' i.e. non-dividing nucleus. At the same time we notice that the nucleus is not placed in the centre, but in the periphery of the cell.

Next, the nucleus becomes uniform in its substance, and transparent; it stains less in dyes, and all traces of a reticulum disappear. The cell substance is collected at one end of the nucleus as an elliptical granular mass, and appears separated from it by a transparent, clear bag.

In the next stage the nucleus becomes flattened and discoid, so that when viewed from the surface it is broad and circular, but appears narrow and staff-shaped when seen in profile. The cell substance at this time is drawn out into a cylindrical or club-shaped *granular body* separated from the nucleus by a shorter or longer *clear tube*, the former clear bag. At the front part of the nucleus is seen a short and tapering curved projection, and at its hind end—viz. that directed towards the clear tube and cell substance—there is also to be found a short pointed process extending into the clear tube just named. When examining one of these cells in a well stained specimen under a high magnifying power, it is seen that the hind third of the nucleus is tightly grasped by the front end of the above *clear tube*, and that the *granular body*—viz. the remnant of the cell substance—is placed like a cap over the hind end of the clear tube.

In the next stage the nucleus becomes more flattened and oblong, and in some animals more or less curved, while both the clear tube and the granular body become elongated. It is not easy to ascertain whether the clear tube extends also over the front part of the head. In the last stage the granular body has become changed into a long, thin, and homogeneous filament.

The fully developed and ripe spermatozoon consists of a homogeneous, well-defined, discoid oval *head*, which in some animals is in the profile view more saucer-shaped—i.e. convex concave—than in others; it possesses a more or less distinct, tapering, minute curved prolongation. Next to the head is the *middle piece* of Schweigger Seidel; its

length differs in different animals; it appears homogeneous and rod-shaped; attached to it is the *filament*, or *tail*, thinner and much longer than the middle piece, and ending in a pointed extremity. In triton and salamander the filament, or tail, is continued over the middle piece as a very conspicuous, wavy, or more or less spiral filament, but is separated from it (middle piece) by a thin homogeneous membrane (Leydig, Gibbes). This filament appears fixed to the blunt hind end of the head; this latter contains here an oval bright corpuscle, and is a very long and slightly curved rod, ending in front in a pointed extremity.

It is probable, from the observations of H. Gibbes: (*a*) that a similar arrangement exists also in man and mammals, viz. that the filament is continued over the middle piece as a fine wavy or spiral thread; but here this thread lies close on the former, viz. the middle piece; and (*b*) that there is a sheath which covers the hind part of the head and continued over the middle piece.

In what relation do, then, these different parts of the fully formed spermatozoon stand to the parts of the developing element, that is, the spermatoblast? A comparison shows at once that the head of the ripe spermatozoon is the changed nucleus of the spermatoblast; that the filament, or tail, is derived from what has been mentioned above as the granular body of the original cell. The middle piece of Schweigger Seidel is an outgrowth of the nucleus of the spermatoblast, that is, of the head of the spermatozoon, and the *clear tube* of the developing spermatozoon, described above as embracing the hind part of the nucleus and separating the latter from the granular body, is the sheath which in some instances (triton and salamander) is observable on the middle piece of the fully-formed spermatozoon.

The preceding statements very well agree with the observations of Kölliker, Henle, Schweigger Seidel, of v. la Valette St. George, as described in his exhaustive article on this subject in Stricker's 'Manual of Histology,' and in other subsequent publications, and of the important researches both of Merkel and Sertoli, which are to the effect that in mammalian animals, at any rate, the head of the spermatozoon is the transformed nucleus, while the filament, or tail, is derived from the body of the spermatoblast.

While the spermatoblasts or the daughter cells of the inner seminal cells undergo the changes which lead to their conversion into spermatozoa, important alterations occur in their position and arrangement. As described on a former page, the spermatoblasts lie more or less loosely side by side next the lumen of the seminal tube, their number varying greatly in different parts. Now, as soon as the stage is reached when the nucleus is flattened, and, as it were, free of the cell body, and this latter converted into a club-

shaped, granular mass, separated from the former by a clear sac or tube, these so altered spermatoblasts, which we shall henceforth designate as the 'young spermatozoa,' assume a definite arrangement, becoming collected into more or less conical, pyramidal, or fan-shaped groups, the stalk of which is sunk in between the inner seminal epithelial cells (see figs. VI.–VIII. of Plate XXXIX.). The young spermatozoa in each group are so placed that their nucleus, or head, is directed outwards, that is, towards the seminal epithelium, their granular bodies looking in the opposite direction, that is, towards the lumen. As the spermatozoa elongate, the above groups also elongate, and their stalk becomes much thinner; this latter contains now only the nucleus of the spermatozoa (see figs. VII. and VIII. of Plate XXXIX.). The stalk remains sunk in between the seminal epithelial cells. It is impossible to say what causes this peculiar arrangement of the developing spermatozoa in groups, or how they are fixed in between the seminal cells. The young spermatozoa in each group are held together by a transparent, sometimes indistinctly granular interstitial substance.

The inner broad ends of these groups, viz. next to the lumen of the seminal tube, are in the last-named stages close to one another, and connected into a network by a transparent, finely granular interstitial substance. This latter arrangement, viz. into a network, is of course shown only when these groups are viewed from the surface. Sooner or later, both the interstitial substance between the groups, as well as that between the individual spermatozoa, breaks up, and the spermatozoa, having reached their full development, become detached from one another.

The condition in which the seminal tubes, or the different sections of the same tube, present themselves, is, then, one of the following: (1) between the membrana propria and the lumen of the tube we meet with (*a*) the outer seminal cells, (*b*) the inner seminal cells, these latter in two or more layers, but in various stages, preparatory to division; then follow (*c*) the daughter cells, or spermatoblasts, in one or more layers, but loosely connected. Or, (2) *a* and *b* are the same, but the spermatoblasts begin to change into young spermatozoa. Or, (3) *a* and *b* as before; *c*, contains distinct young spermatozoa grouped in a definite manner; these groups are short and thick. Or, (4) *a* and *b* as before; *c*, the young spermatozoa are more developed and longer, their groups are more pyramidal, and each with a thin stalk sunk in between the inner seminal cells; the free or broad ends of the groups are connected into a network by an interstitial substance. Finally, (5) *a* and *b* as before; *c*, the groups of young spermatozoa are disintegrating, the fully-formed spermatozoa becoming isolated. In the latter or even the previous condition we may find the inner seminal cells undergoing again division into daughter cells.

The formation of the spermatozoa is not fixed to any definite locality, nor does it

occur or proceed with any regularity, for we may find any two of the above conditions not only in adjacent seminal tubes, but also side by side in the same tube.

Some observers (v. Ebner, Neumann, Mihalkovics, and others) consider each of the above groups of spermatozoa as formed in a single large cell (spermatoblast of v. Ebner and Neumann), consisting of: a nucleated (v. Ebner) or non-nucleated (Neumann) basis at or near the membrana propria of the seminal tube: a thin prolongation (our peduncle): and, finally, a broad fanlike lobed mass next the lumen of the tube, in which mass the spermatozoa are produced.

Such a view, if correct, would completely upset the account given of the formation of the spermatozoa in the preceding pages. The view that each of our groups of young spermatozoa is at first a single large cell, in which spermatozoa are developed, rests chiefly on the assumption that the part we called the peduncle of the group is connected with one definite seminal epithelial cell, being, in fact, an outgrowth of it, an assumption which appears to me not verified by observation. On the other hand, the formation of the young spermatozoa can be traced distinctly from our spermatoblasts, or daughter cells of the seminal epithelium, as well as the gradual arrangement of the former (spermatozoa) into groups.

The seminal tubules, when approaching the corpus Highmori, empty themselves into the vasa recta, which, in the corpus Highmori, by anastomosis become connected into the rete testis Halleri. The vasa recta and the tubes of the rete testis are much thinner than the seminal tubules; there is a constriction at the passage of the convoluted seminal tubule into a vas rectum of men (Stieda). The vasa recta and the tubes of the rete testis possess a hyaline membrana propria lined with a single layer of transparent short columnar cells (Stieda), which in the guinea pig are squamous (Messing).

The tubes of the coni vasculosi and the rest of the canal of the epididymis, including the vas aberrans Halleri, are considerably larger than the canals of the rete testis; they possess a large lumen lined with columnar epithelium. Outside this epithelium is the membrana propria, supported and thickened by unstriped muscle cells, arranged chiefly as a circular coat, but some have also a longitudinal direction.

The epithelium is composed of columnar thin cells, each with a bundle of exceedingly long cilia on the free surface (O. Becker, Kölliker). Each cell contains an oval nucleus in its outer portion. The substance of the cells is a beautiful reticulum, arranged preeminently in a longitudinal manner, and the cilia are prolongations of the fibrils of that network. The nucleus contains within a membrane the intranuclear reticulum. Underneath the superficial columnar cells there is always a more or less distinct layer of small

polyhedral cells. In some instances, amongst the superficial columnar cells, may be found goblet cells with or without mucous secretion. The cells, and their cilia, increase towards the canal of the epididymis.

The thickness of the epithelium is greatly dependent on the state of contraction of the muscular coat; it is, of course, greater when this (muscular coat) is contracted than when not.

The seminal tubules, as well as the tubes of the epididymis, are surrounded by a rich network of capillary blood-vessels.

Of the termination of the nerves in the seminal tubules and in those of the epididymis nothing positive is known.

In connection with the rete testis, Roth occasionally observed straight tubes, vasa aberrantia, running for a considerable distance along the epididymis, and terminating in a cæcal extremity, simple or branched; they are lined with a simple columnar ciliated epithelium.

The tubes known as Giraldé's organ, and situated in the first part of the funiculus spermaticus, are lined with columnar epithelium, possessed of cilia (Roth).

The pedunculated hydatid of Morgagni, situated on the head of the epididymis, which, since Luschka, Becker, and others, has been considered as the remains of the fœtal Müller's duct, is covered with columnar ciliated epithelium (Fleischl). That its pyriform body is comparable to an ovary and the small canal attached to it to an oviduct, as maintained by Fleischl, has been disproved by Roth; Waldeyer compares the whole organ to the pars infundibuliformis of the oviduct.

Vas Deferens and Vesiculæ Seminales.

The *vas deferens* consists of a mucous membrane, a muscular coat, and an outer coat or adventitia.

The mucous membrane is a dense connective-tissue feltwork, with networks of fine elastic fibres; in it is found a rich network of capillary blood-vessels.

The epithelium lining the canal is composed of columnar cells, which, with the exception of the part next the epididymis, are without cilia. Each cell includes an oval nucleus, situated in its outer part. The substance of the cell and nucleus differs in no way in structure from that described of columnar epithelial cells on several previous occasions. Between and underneath the columnar cells of this superficial layer are found conical, spindle-shaped, or polyhedral cells; in the contracted state of the muscle coat these cells appear to be arranged in several layers, so that the epithelium looks much stratified. In the intraperitoneal portion the epithelium as a whole is generally thinner than in the rest of the vas deferens.

The mucous membrane is much folded in the ampulla, and the minute depressions

of the surface hereby produced imitate glandular pits; they are considered as real glands by some observers (Henle, Leydig, and others).

The muscular coat consists of an inner circular and an outer longitudinal stratum of unstriped muscle cells. At the commencement of the vas deferens there is, however, in addition, a thin inner longitudinal coat.

The adventitia is fibrous connective-tissue, it contains the longitudinal bundles of unstriped muscle cells known as cremaster internus of Henle; further, the rich plexus of veins known as plexus pampiniformis; the plexus of lymphatic trunks with valves; and the nerve trunks of the plexus spermaticus. Small groups of ganglion cells and large ganglionic swellings are met with in connection with the branches of this plexus.

In the *vesiculæ seminales* we meet with the same coats as in the vas deferens, but they are thinner in the former than in the latter. The mucous membrane is placed in numerous folds, whereby pits and grooves are produced resembling minute glandular depressions (Henle). The epithelium is composed of a superficial layer of long columnar cells and a deep layer of more or less polyhedral cells.

The muscular coat is, as a whole, thinner than in the vas deferens, and consists of an inner and outer longitudinal and a middle circular coat of unstriped muscle cells, the first being the thickest.

In the thick fibrous connective-tissue adventitia are the large blood and lymphatic vessels and the nerve trunks, with numerous ganglionic swellings, some of them of a considerable size.

In the *ductus ejaculatorii* we also meet with a layer of columnar epithelial cells, and underneath these small polyhedral cells; outside the epithelium is a delicate connective-tissue mucosa; further outside is a muscular coat composed of an inner thick-longitudinal and an outer thinner circular layer. When passing into the vesicula prostatica the columnar epithelium is gradually replaced by stratified pavement epithelium.

The Prostate Gland.

The framework of the prostate gland is composed of a small amount of fibrous connective-tissue and of a great quantity of unstriped muscular tissue. The first forms the outer capsule and the thin septa passing inwards and carrying the blood-vessels; the second is arranged as a network of septa and trabeculæ surrounding the different parts of the gland tissue proper.

This latter consists of the ducts opening on the surface of the pars prostatica of the urethra, mostly at the basis of and near the colliculus seminalis; they branch into smaller ductlets which pass into the gland-alveoli. These latter are longer or shorter, wavy or convoluted, branched tubes, terminating in saccular blind extremities; many of

them are possessed of short, lateral, club-shaped branchlets. On the whole, each duct, and its corresponding section of the gland tissue, are comparable to a compound tubular gland, as described in former chapters.

The alveoli, as well as the ducts, possess a membrana propria, and a distinct lumen lined with epithelium. With regard to this latter the alveoli are of two different kinds: (1) alveoli lined with a single layer of thin and long columnar cells, each with an oval nucleus in the outer part of the cell; (2) alveoli whose lumen is lined with a layer of short columnar cells, and outside this but inside the membrana propria there is another layer of small, cubical, polyhedral or spindle-shaped cells. The columnar cells of the former layer possess a thin process, which passes through the outer layer, and reaches the membrana propria. The stratified pavement epithelium of the urethra is continued a short way into the mouth of the ducts.

The columnar cells lining the lumen of the alveoli, in the prostate gland of the newborn child, are much shorter than after puberty (Langerhans).

The ducts are lined with a layer of columnar cells, underneath which is a layer of small polyhedral cells, each with a spherical nucleus.

As in other glands, so also here the alveoli are surrounded by a dense network of capillary blood-vessels. Numerous ganglia are interposed in the plexus of the nerve-branches, present in the peripheral portion of the gland. In this portion occur also Pacinian corpuscles.

The Urethra.

The epithelium lining the mucous membrane is stratified pavement epithelium in the lower half of the pars prostatica and membranacea; in the upper half it is stratified transitional epithelium; in front of the bulbus urethræ the epithelium becomes columnar first at the sides, latest in the lower part. There exist, however, in this respect great differences in different urethræ, and at different periods of life. Thus, in the newborn child, there are, amongst the columnar epithelium, islands of stratified pavement epithelium even in the pars cavernosa of the urethra.

The fossa navicularis is lined with stratified pavement epithelium. Wherever this latter is found the mucous membrane forms minute conical papillæ, containing loops of the superficial capillary network.

The mucous membrane consists chiefly of fibrous connective-tissue, but there are present also large numbers of elastic fibres (Robin and Cadiat). It is surrounded by muscular tissue; at the root of the urethra this is made up of an inner circular and an outer longitudinal layer of bundles of unstriped muscle cells; in the pars prostatica the muscular coat is chiefly longitudinal and is intimately connected with the muscular

tissue of the prostate; in the membranous portion of the urethra the muscular coat is also pre-eminently longitudinal, and its bundles pass into the mucous membrane itself, where they run in a longitudinal direction between the large venous vessels connected here into a network. These large veins empty themselves into smaller veins situated in the tissue outside the muscular coat.

The plexus of large veins of the mucous membrane, with its muscular bundles just mentioned, represents the rudiment of a corpus cavernosum (Henle).

In the pars cavernosa the muscular bundles are separated from one another by the venous sinuses or cavernæ, and they form an essential part of the cavernous tissue.

Besides the lacunæ Morgagni, the mucous membrane possesses small simple mucous gland tubes lined with columnar epithelium (follicules of Robin and Cadiat), and longer branched mucous gland tubes, Littré's glands. The epithelium of the surface penetrates into the mouth of their ducts.

Each *gland of Cowper* resembles in structure the sublingual gland, being a large compound tubular mucous gland (see Chapter XXV.). The chief duct possesses a thick coat, rich in longitudinal bundles of unstriped muscle cells. Its epithelium, as well as that of the large and small branches, is composed of columnar cells, longer in the larger branches than in the smaller ones. In the gland tubes proper, or alveoli, the lumen is relatively large, and lined with columnar 'mucous' cells, whose outer thin portions are imbricated (Langerhans) in the same way as those described of the submaxillary gland of dog (see Chapter XXIV.). The substance of the cells is a beautiful reticulum (Langerhans); the nucleus is compressed and situated next the membrana propria.

Corpora Cavernosa.

Each corpus cavernosum is surrounded by dense tendinous connective-tissue, the albuginea, which also contains unstriped muscle cells; around this is loose connective-tissue containing fat cells, a plexus of nerve branches, and Pacinian corpuscles. The matrix of the corpus cavernosum consists principally of unstriped muscle tissue, to which is added a limited amount of fibrous connective-tissue and elastic fibrils. The bundles of unstriped muscle tissue form thicker or thinner septa and trabeculæ connected into a plexus. These masses surround and separate the huge venous vessels, the sinuses or cavernæ, anastomosing into a dense plexus. Each of these vessels is lined with a single layer of flattened endothelial plates. The arterial branches, ensheathed in the muscular trabeculæ of the matrix of the corpus cavernosum, break up into a rich network of capillaries, also situated in the matrix. These capillaries discharge their blood in two directions: (*a*) into the above sinuses or cavernæ (Langer); and (*b*) directly into the efferent venous branches. The arteriæ helicinæ of H. Müller, which formerly

REESE LIBRARY
OF THE
UNIVERSITY
OF
CALIFORNIA.

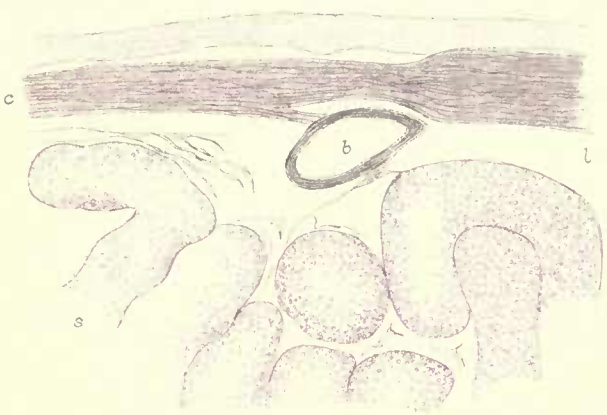

I

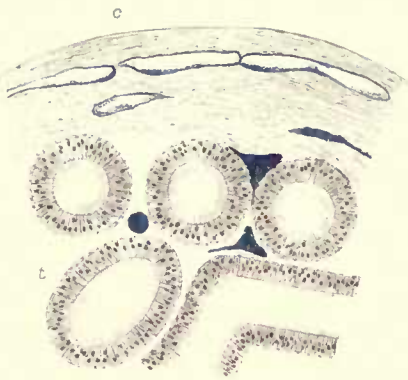

II

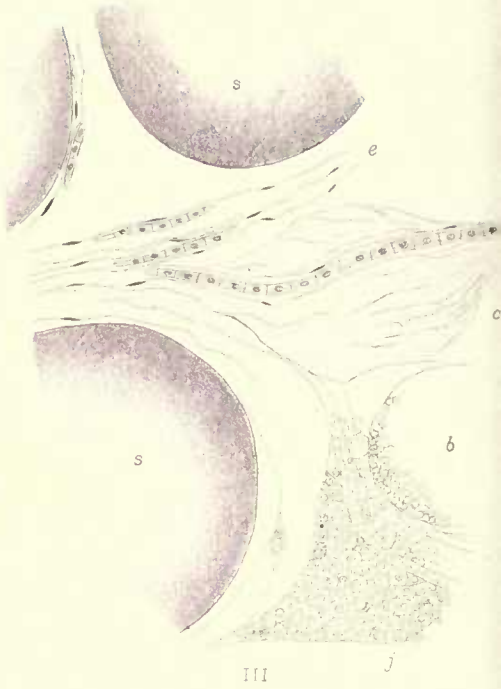

III

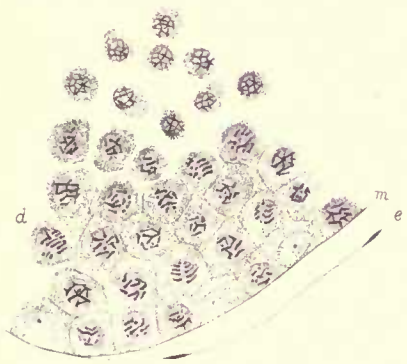

IV

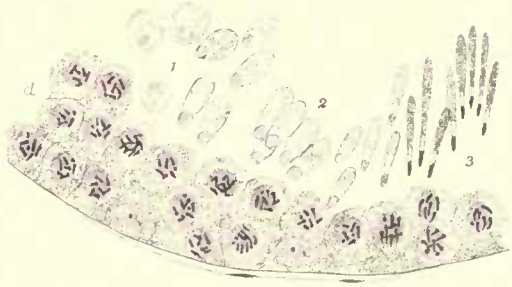

V

VI

VII



VIII

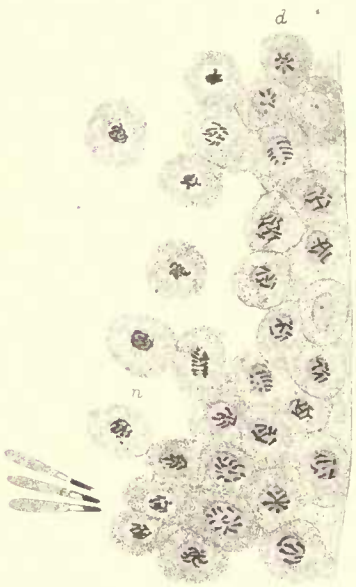

IX

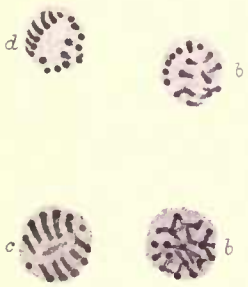

X

XI

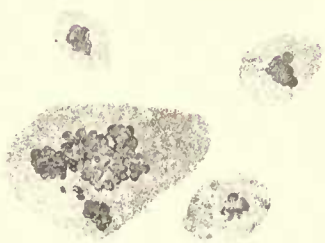

XII

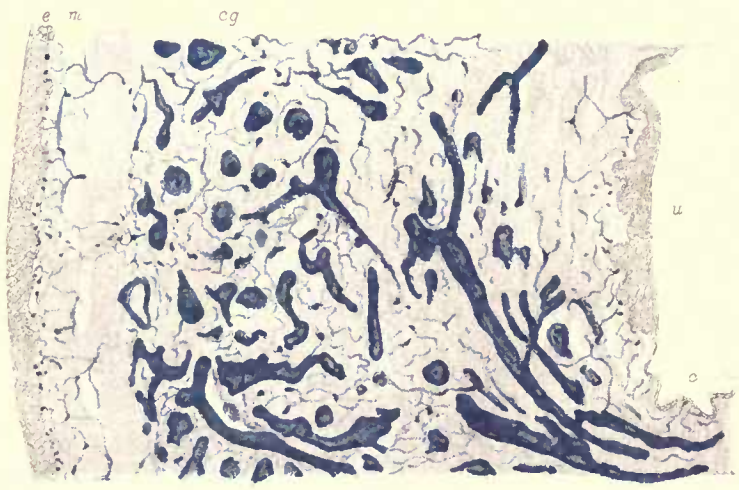

XIII

were supposed to open freely into the cavernæ, are due to a peculiar convoluted and twisted condition of the arterial branches, owing, of course, to the contracted state of the muscular matrix, while the cavernæ are collapsed (Henle, Langer, and others). In the peripheral, or cortical, part of the corpora cavernosa penis there exists, in addition, a direct communication between very fine arterioles and the cavernæ (Langer).

The corpus cavernosum urethræ consists of an inner and outer section; the former is a plexus of longitudinal veins of exactly the same nature as that mentioned above of the pars membranacea, with which it forms a direct continuity; in connection with it are the capillaries belonging to the mucous membrane of the urethra. The outer section is a real corpus cavernosum, like that of the penis, and is continued as the bulbus.

The cavernæ of the corpus cavernosum of the glans penis are also venous vessels connected into a plexus; into the cavernæ open the capillaries. These form a dense network, situated in the matrix between the cavernæ. The cortical layer of this corpus cavernosum is in direct communication with the vessels of the mucous membrane of the glans. This is a delicate connective-tissue feltwork covered with stratified pavement epithelium; numerous conical papillæ, containing capillary loops, extend from the former into the latter.

At the corona glandis exist generally small sebaceous glands, the glands of Tyson, continued from the inner lamella of the prepuce (see Skin).

A rich plexus of lymphatics, terminating as a network of fine vessels underneath the epithelium, is present in the tissue of the glans, including the papillæ.

Numerous isolated and small bundles of medullated nerve fibres are to be met with connected in a plexus. From these come off non-medullated nerve fibres forming a dense subepithelial network. For their termination in the epithelium and in end bulbs see a former chapter (XVIII.).

PLATE XXXIX.

Fig. I. From a vertical section through the testis of the dog. Magnifying power about 50.

c. Capsule consisting of an outer layer, the tunica adnata, and an inner, the tunica albuginea. Lymph vessels are indicated between the two layers.

b. Large blood-vessel in transverse section.

s. Seminal tubules cut in different directions.

l. Lymph spaces around and between the tubes.

Fig. II. From a section through the epididymis of the dog. Magnifying power about 50.

c. Capsule containing lymphatic vessels in transverse section, injected with Berlin blue.

t. The tubules of the coni vasculosi cut in different directions; the ciliated columnar epithelium lining them is just indicated. Between the tubes are the injected lymphatic vessels.

Fig. III. From a section through the testis of the cat. Magnifying power about 250.

s. Seminal tubules in section, the lining epithelium is not represented.

b. Part of a large vein filled with blood corpuscles.

c. A lamella of the interstitial connective-tissue seen from the surface; it appears as a hyaline membrane—in reality, an endothelial membrane—to which are attached minute bundles of connective-tissue fibres.

e. The same lamellæ seen in profile; owing to the low power the distinction into endothelial membrane and connective-tissue fibres is not visible.

i. Intertubular or interstitial epithelial cells (see the text).

j. The same seen from the surface.

The spaces between the above lamellæ and between these and the seminal tubes are lymph spaces, being the rootlets of the lymphatics of the testis.

Figures IV.—IX. represent portions of the wall of seminal tubules of the testis of the dog. In each of the figures the whole thickness of the wall is shown, viz. from the membrana propria to the lumen of the tube. Magnifying power 450.

m. Membrana propria of the tubule.

d. The lining epithelium; in this are to be distinguished the outer seminal cells next the membrana propria, then the inner seminal cells; some of the former and all the latter show their nucleus and its intranuclear network of a nature that indicates division (compare fig. X., and see also the text of this chapter). Next the lumen are loosely connected small epithelial cells, derived by division from the inner seminal cells; they are the daughter cells or spermatoblasts. Their nucleus contains a reticulum.

e. Endothelial membrane belonging to the intertubular connective-tissue. Between this and the membrana propria is a lymph space.

Fig. V.

d. Seminal cells.

1. Spermatoblasts; these are the changed daughter cells next the lumen (see preceding figure).

2. Earliest stage in the formation of the spermatozoa from the spermatoblasts.

3. Spermatozoa, somewhat further developed.

Figures VI. VII. and VIII. show the further development of the spermatozoa; the peculiar grouping of them is well brought out.

d. Seminal cells.

s. Spermatozoa.

Fig. IX. shows well the peculiar change of the nucleus of the seminal cells during and after division. In the layer *n* the network in the nucleus of the seminal cells shows the arrangement peculiar to division (see the text).

Fig. X. shows various forms of nuclei of the seminal cells under a higher power than represented in the preceding figures.

a is a 'resting' nucleus of one of the outer seminal cells.

b are nuclei preparatory to division; they have no membrane, and the contents are a beautiful 'convolution' of relatively thick fibrils or rods viewed in different directions.

c, similar nuclei, in which the fibrils radiate towards a central line; this form gradually leads to that of the 'wreath' and 'aster,' the radiation of the fibrils being towards a central point instead of a line.

d is a similar nucleus, but its fibrils, being arranged vertically to the plane of the microscope, are almost all seen in optical transverse section. They are limited to the periphery of the nucleus, and run more or less parallel with one another, 'basket-shaped' arrangement.

Fig. XI. Two groups of similar nuclei of testis of the cat; each of these groups is contained in one large cell, the substance and outline of which are not shown here.

The nuclei in each group are arranged in a spherical zone; the left group is seen from the top, the right one from the side.

The fibrils in the different nuclei have a variable arrangement, as 'convolution,' 'basket,' or 'aster.'

Fig. XII. From the same testis as the preceding figure, showing one large and three small seminal cells; the former has several, the latter each one irregular, lobed, homogeneous nucleus. Whether or not this uniformity in the substance of the nuclei and their lobed form is due to shrinking, or whether or not in reality these nuclei show similar fibrillar contents as those of the preceding figures, it is not possible definitely to ascertain. Magnifying power about 450.

Fig. XIII. From a vertical section through the glans penis of a newborn child; the blood-vessels are injected with Berlin blue. Magnifying power about 25.

e. Stratified epithelium of the surface of the glans.

m. Mucous membrane, possessed of numerous minute papillæ with networks of capillaries. Numerous transparent (empty) lymphatic vessels are indicated in the tissue of the mucous membrane.

cg. Corpus cavernosum, showing the network of venous sinuses or cavernæ connected with the capillaries of the stroma.

The vessels of the mucous membrane of the glans communicate with the vessels of the corpus cavernosum.

cu. Corpus cavernosum urethræ.

U. Urethra; its mucous membrane is lined here with stratified pavement epithelium.

c. The epithelium is much thinner, being composed of columnar cells.

The mucous membrane is possessed of minute papillæ, containing loops of the network of blood capillaries. These are in connection with the venous sinuses of the corpus cavernosum urethræ.

CHAPTER XXXII.

THE FEMALE GENITAL ORGANS.

The Ovary.

The *framework* of the human ovary, as well as that of mammals, consists of (*a*) the tissue of the hilum, and (*b*) the stroma of the parenchyma.

a) The first is loose fibrous connective-tissue, extending also into the parts containing the Grafian follicles, that is, into the parenchyma, or zona perenchymatosa of Waldeyer. It is very rich in big vessels, and may be therefore called, with Waldeyer, the zona vasculosa. Numerous bundles of unstriped muscle cells pass from the ligamentum latum into this zona vasculosa, and accompany the blood-vessels as longitudinal bundles. Some of them enter also the parenchyma.

b) The stroma of the parenchyma is a very peculiar tissue, consisting of bundles of shorter or longer transparent spindle-shaped cells, each with an oval nucleus. There is a very small admixture of fibrous connective-tissue, brought in chiefly with the vascular branches. The ovaries are, in this respect, subject to great variations, for in some cases (cat, dog) there is very little to be seen of such bundles, while in others (man, rabbit) we meet with bundles of connective-tissue, in some places of considerable size. The above bundles of spindle-shaped cells cross each other in many ways, and thus form a tolerably dense tissue.

According to the distribution of the parenchyma, that is, the Grafian follicles, the stroma forms larger or smaller continuous masses. There is generally in the cortex of the ovary a layer of stroma of appreciable thickness, not containing any ova; this layer is the albuginea of Henle. In man this albuginea shows a distinction into an outer and inner longitudinal and a middle circular layer of connective-tissue (Henle). In many mammals it consists only of bundles of spindle-shaped cells, which extend either longitudinally or obliquely. In the cat the bundles of the albuginea are grouped as a superficial thin longitudinal layer, underneath which in many places is a deep circular or slightly oblique layer. Around the larger and largest Grafian follicles the stroma of spindle-shaped cells is arranged in more or less concentric layers.

Between the spindle-shaped cells also branched cells are to be met with; they are elongated, each with an oblong nucleus, their processes pass in a longitudinal

direction amongst the spindle-shaped cells, and anastomose by lateral branchlets into a network.

It is difficult to definitely ascertain the nature of the spindle-shaped cells, viz. whether they are imperfectly developed connective-tissue or unstriped muscle cells. They certainly resemble unstriped muscle cells more than anything else. While Kölliker, Henle, Pflüger, Waldeyer, v. Winiwarter, and others regard the stroma as composed of connective-tissue, Rouget, Aeby, Klebs, and others assume a great amount of unstriped muscular tissue in it, while His considers the stroma almost entirely muscular.

Between the bundles of the spindle-shaped cells are seen from place to place smaller or larger cylindrical or irregular more or less anastomosing groups of small polyhedral cells, each with a spherical nucleus. The substance of these cells is a very fine reticulum; the nucleus contains also a reticulum, and in some instances contains one or more thickenings, nucleoli. These cells are most numerous in the deeper parts of the parenchyma; they are generally absent from the albuginea; they extend also into the tissue of the hilum, where they have been seen by Kölliker, but misinterpreted by this observer. Their significance is exactly the same as that of the intertubular or interstitial epithelial cells mentioned in the testis, viz. they are remnants of the epithelium of the Wolffian body, and we shall call them, therefore, interstitial epithelial cells. They have been known through His, Waldeyer, Romiti, Born, Balfour, and many others. Balfour has very distinctly traced them from the Wolffian body, and he describes them as the 'tubuliferous tissue' in the developing ovary.

The interstitial epithelial cells are well shown in the ovary of the cat, the dog, and the guinea pig, where they are easily recognised, besides by their shape, also by a slight yellow tinge.

The free surface of the ovary is covered with a single layer of columnar or short columnar epithelial cells, each with an oval nucleus; this is the germinal epithelium of Waldeyer, who first showed the great contrast of this epithelium and the layer of flattened endothelial cells covering the ligamentum latum; a similar contrast exists between the columnar (ciliated) epithelium of the oviduct and the flattened *endothelium* of the peritoneum around the abdominal extremity of the former.

The *parenchyma* consists of the *Grafian follicles*. These are of very various sizes and shapes, and are so distributed that the larger ones are seated in the deeper parts of the zona parenchymatosa, while the small ones lie near the surface, immediately underneath the albuginea. In most instances the latter are aggregated as smaller or larger groups; in some cases (cat and rabbit, Waldeyer) these groups are so close that they

form almost a continuous layer two or three deep underneath the albuginea, the cortical layer of Schrönn. This has been found (Romiti) to be the case in all mammals. From the superficial layer of small Grafian follicles to the deep-seated big ones are all gradations. The small Grafian follicles are generally spherical, the middle-sized ones spherical or oblong, and the largest are spherical, or more or less elongated or irregular; the last-named are possessed of one, two, or more prolongations (see below). As mentioned above, the bundles of spindle-shaped cells of the stroma pass in between and around the Grafian follicles, both where they are in groups and isolated; the amount of stroma is of course greater between the groups than between the individual follicles of a group. The spindle-shaped cells possess a more or less distinct concentric arrangement around the large Grafian follicles, thus forming a special outer membrane for the latter; this is the *tunica fibrosa* of Henle. The larger the follicle the more developed is the network of blood capillaries in this outer tunic.

Each Grafian follicle, including the smallest, is limited by a *membrana propria* (Kölliker, Foulis, Balfour and others), which is thicker in the larger follicles than in the smaller ones. It contains here and there a flattened oval nucleus, which appears staff-shaped when viewed in profile. Inside the membrana propria are the epithelial cells, or the *membrana granulosa* of the Grafian follicle, and in the centre of the follicle is the *ovum*.

In the smallest follicles, that is, in those next the albuginea, the membrana propria is a very delicate membrane, and between it and the ovum is a single layer of transparent and very flattened cells, each with a flattened or spherical nucleus. The ovum appears here as the most conspicuous part. In the follicles of the next size, the epithelium lining the membrana propria also consists of only one layer, but its cells are polyhedral, each with a spherical nucleus. Then follow follicles whose epithelium is composed of columnar cells still in one layer. In the next larger follicles the cells are in more than one layer, and in the largest they are in three, four, or more layers. The outermost cells, viz. the cells next the membrana propria, are distinctly columnar, placed vertically, and each contains an oval nucleus; those of the other layers, however, are smaller, transparent, and polyhedral, each with a spherical nucleus.

The cells are separated from one another by a linear interstitial cement-substance. In well preserved specimens there is a very delicate reticulum to be met with in this cement-substance; its meshes differ greatly in size, in some places they are not larger than one cell, in others each contains several cells. A few oval or angular or irregularly shaped nuclei may be found in this reticulum. It stretches from the membrana propria inwards, and in all probability is analogous to the nucleated reticulum of the seminal and other gland tubes, mentioned on former pages as supporting the epithelial cells.

In the fully formed Grafian follicle the ovum is embedded in a mass of epithelial cells, projecting like a mound from the epithelial lining of the follicle into the cavity of the latter. This mass is the discus or cumulus proligerus; the cavity contains an albuminous fluid, liquor folliculi. In some follicles there may be two or even three such cumuli, each containing an ovum.

The epithelial cells of the discus proligerus are, like the cells of the membrana granulosa, small transparent polyhedral or elongated cells; but those immediately around the ovum are beautifully columnar, each with an oval nucleus.

All transitional forms exist between the above ripe follicles and the small follicles, which do not contain any cavity yet, but in which the ovum is placed more or less centrally, the space between it and the membrana propria being filled with epithelial cells. The transition is effected by the appearance of albuminous fluid in small isolated cavities amongst the epithelial cells of the membrana granulosa, or between the ovum itself and the epithelium; in the latter case the ovum remains surrounded by the epithelial cells, discus proligerus. These cavities gradually increase in number and size, and become confluent, the follicle thus greatly enlarges, and the ovum, embedded in the discus proligerus, is pressed to one side and remains connected on this side with the membrana granulosa.

While this fluid appears, both the epithelial cells immediately surrounding the ovum, as well as those of the membrana granulosa, greatly increase in numbers.

In many follicles, containing a greater or smaller quantity of the liquor folliculi, we notice in this latter small cells, isolated or in small groups, more or less vacuolated. They are vesicular structures, containing a cavity surrounded by a thin membrane, the original cell-substance, at one point of which lies a spherical or slightly compressed nucleus. These cells are probably epithelial cells that have become separated from the follicular epithelium and are undergoing retrogressive changes (maceration). They gradually fade away entirely.

In connection with, or contiguous to, middle-sized and large Grafian follicles may be seen larger or smaller solid cylindrical, or oval, or irregularly shaped masses. These masses are limited by a membrana propria, and when they are connected with a Grafian follicle, their membrana propria is a continuation of the same structure of the Grafian follicle; they consist of more or less columnar transparent epithelial cells, of exactly the same characters as those of the granulosa of the Grafian follicles, with which in some instances they are distinctly continuous. These masses are very well shown in the ovary of the rabbit. Whether all apparently isolated solid masses of similar cells, in a section through the ovary, are in reality isolated or not, i.e. whether or not they are connected with a Grafian follicle, but owing to the direction of the section this connection

is not visible, it is impossible to say. They are not to be confounded with the groups of interstitial epithelial cells mentioned on a former page; both differ in shape, size, arrangement, and appearance.

Not all those masses that are connected with a Grafian follicle are solid prolongations of the epithelium of this latter; some show a small cavity, are therefore tubular, and still others, being at the same time larger, contain an ovum. Some of the large Grafian follicles are possessed of one or two solid prolongations, others, in addition, communicate with one or two small follicles each with an ovum. In the latter case we find, then, two or three Grafian follicles in open communication with one another; they are either very different in size (development), one or two being comparable to a small or middle-sized follicle, while the third may be a fully developed one; or they appear of nearly the same size. The communication may be through a narrow neck, as in some, or wide open, as in other instances. The Grafian follicles with two or three ova are only modifications of the last-named plan (see below).

The *ovum* is a nucleated cell, varying in size according to the size of the follicle. In the smallest follicles the substance of the ovum is in immediate contact with the flat epithelial cells of the Grafian follicle; but in the follicles of the next larger sizes, that is, whose epithelial cells are polyhedral or even columnar, there is a distinct bright membrane, zona pellucida, surrounding the substance of the ovum. The larger the ovum the thicker the zona pellucida. In all cases, from the smallest follicles that contain a zona pellucida to the fully formed ones, in which the ovum lies in its discus proligerus, the outer surface of the zona pellucida appears to form a direct continuity with the interstitial cement-substance, between the epithelial cells of the follicle; hence, when the outer surface of the zona pellucida is seen in the bird's-eye view, it shows the outlines or impressions of the surrounding epithelial cells. This connection of the zona pellucida with the interstitial substance seems to indicate that the former is a product, a cuticular excretion, of the epithelial cells themselves. The zona pellucida of the ripe ovum shows a very fine (vertical) striation, which, according to Pflüger, Leydig, and Waldeyer, is due to the substance of the epithelial cells, immediately surrounding the zona pellucida, being continuous as fine rods or threads into the latter membrane.

The substance of the ovum is very transparent; in the large ova it contains the yolk granules. In sections through the hardened ovary of the rabbit, dog, cat, guinea pig, the protoplasm contains a more or less distinct reticulum of fine fibrils.

In the larger ova the protoplasm surrounding the germinal vesicle is generally more transparent than that next the zona pellucida (Pflüger). These two substances also stain differently in osmic acid (Romiti).

The nucleus or germinal vesicle of the small ova, i.e. those next the albuginea,

is generally single, rarely it is double; it contains within a definite membrane a transparent matrix, and in it a delicate reticulum of fibrils, in some cases without any, in others with one or more irregularly shaped large clumps, nucleoli or germinal spots; this reticulum has been noticed by Balfour also in the young ovary.

The reticulum is very distinct if the ovary has been prepared with chloride of gold. In specimens hardened in the ordinary way (Müller's fluid) the germinal vesicle appears homogeneous with faint and fine granules, it stains more or less uniformly in dyes; in it are situated, generally peripherally, one or two or more bright spherical or angular clumps—germinal spot or spots.

The larger and largest ova contain generally one, seldom two, nuclei or germinal vesicles, whose structure does not differ from that of the small ova. In the fresh state and after some hardening reagents, e.g. Müller's fluid, the germinal vesicle shows only faintly the intranuclear reticulum; this comes out much more prominently in chloride of gold specimens.

Many follicles arrive at the stage of ripeness before puberty is reached, and are subject to a process of degeneration. But this process involves also follicles of earlier stages, and even the smallest follicles (Pflüger, Waldeyer, and others). It differs, however, according to Slavjansky, from the normal process by which a ripe Grafian follicle is converted, after puberty, into a corpus luteum.

The degeneration leading to the formation of a corpus luteum consists in a multiplication of the epithelial cells of the membrana granulosa, and in the sprouting of new capillary blood-vessels, with migratory cells, from outside the follicle into its hypertrophied epithelium. This new growth stands in a causal relation to the discharge of the ovum (Spiegelberg), and the cavity of the follicle is gradually filled up with the hypertrophied epithelium, with pigment granules and blood-vessels. The tissue now occupying the centre soon changes into gelatinous tissue. The cortical portion of the corpus luteum so much hypertrophies that it becomes gradually folded, and its cells undergo fatty degeneration, becoming filled with several small fat-globules, which gradually become confluent into one large drop; the nucleus is hereby pressed into the periphery of the cell.

The degeneration which occurs in Grafian follicles before puberty is similar to the above, but differs from it in the fact that the hypertrophy and fatty degeneration of the granulosa and the number of capillary blood-vessels in it are not so great. The vascular gelatinous tissue, occupying the centre of a corpus luteum, formed before puberty, remains separated for some time from the cortical portion of the latter by the persistence of the zona pellucida of the ovum. Good examples of degenerating follicles of this nature are to be met with in the ovary of halfgrown rabbits.

Development of the Grafian Follicles and Ova of Mammals.

In this I shall follow Balfour's account given in No. lxxii. (October 1878) of the 'Quarterly Journal of Microsc. Science;' for I have been able to convince myself of the accuracy of his observations.

The germinal epithelium of the early fœtal ovary undergoes a very rapid increase in thickness owing to the division of its cells. The division of the nucleus is here also associated with similar changes in the intranuclear network, as described in the testis, and as will be treated in detail in a future chapter; of these changes Balfour noticed some, e.g. the convolution and the aster.

The thickened epithelium becomes so permeated by the vascular stroma (embryonal connective-tissue), that the former, viz. the epithelium, is transformed into a honeycombed mass; this consists of irregularly shaped groups or nests of cells connected with each other and with the cells of the surface. These nests are largest in the depth and smallest near the surface.

According to Waldeyer these changes are brought about by a mutual ingrowth of the germinal epithelium and the stroma; but, according to Balfour, the segregation into nests is indicated already before the ingrowth of the stroma takes place, and it is the stroma alone that grows into the former, and thus produces the permanent separation of the nests. But in this, I think, Balfour goes too far.

The separation of the nests from the external layer of the epithelium, viz. the one persisting on the surface as the germinal epithelium, by the formation, from the vascular stroma, of a tunica albuginea, takes place only very gradually. Even some time after birth, some superficial nests appear still connected with the germinal epithelium, Pflüger's ovarial tubes.

But many of the apparent prolongations of the germinal epithelium of the surface into the stroma, to be noticed in sections long after birth (Pflüger, Waldeyer, and others), are not in reality outgrowths of that epithelium, but are due to folds and irregularities of the surface (Foulis, Balfour).

The small or external nests give origin to the cortical layer of small Grafian follicles of the fully developed ovary (see a former page), whereas from the deeper-seated nests are developed the larger follicles.

Some of the epithelial cells of the germinal epithelium, already in the earliest stages, enlarge and become converted into primitive ova (Waldeyer), and similar changes continue to occur in the nests, in the smaller superficial as well as in the larger deep ones (Balfour), viz. some of their cells become enlarged and converted into primitive ova.

These, viz. the ova, undergo division, as is evinced by the characteristic changes of their intranuclear network, but they appear also to become fused into a plurinuclear mass, which afterwards again divides into several ova (Balfour). Their products, by enlargement of the nucleus and cell, and by the substance of the latter becoming more distinct, change into the permanent ova. The nucleus of these, as Balfour correctly described, possesses a characteristic reticular structure.

Each nest contains a number of ova. The epithelial cells of the nests which are not converted into ova serve for the formation of the epithelium of the Grafian follicle. In the small nests, viz. in those of the cortical layer, the epithelial cells are relatively few and small, and by multiplication they gradually increase in number, sufficient to form an epithelial investment around each ovum. By an ingrowth of the stroma, the ova with their epithelial coat become separated from the rest of a nest, and then outside each a delicate membrana propria is formed. In some places the nests, being connected with one another, form more or less cylindrical masses, and the ova appearing in them have a chainlike arrangement, ovum-chains of Pflüger.

A similar change occurs also in the larger or deep nests, viz. the epithelial cells undergo multiplication, and many of the ova become gradually invested in their own layer of epithelial cells; these are at first polyhedral, but, as development proceeds, become more or less columnar. By the ingrowth of the stroma, the follicles become separated from one another, each containing one or two ova. A membrana propria soon appears around them.

It is to be noticed that, owing to a continued multiplication of the epithelial cells constituting these nests, larger or smaller portions of them (nests) remain without any ova. They may persist connected with a Grafian follicle or not. The masses of epithelial cells, which we described on a former page as cylindrical or irregular groups of epithelial cells, isolated, or connected with a Grafian follicle, receive thus a ready explanation.

Whether an increase of these epithelial masses takes place also in the adult, and whether some of their cells change into ova also some time after birth, are points difficult to decide, but all appearances are in favour of such a view, and Balfour's observations very much support it. Bischoff, Waldeyer, and others are of opinion that no ova are formed after birth; but Pflüger, Kölliker, and others hold the contrary view. According to Foulis, no new ova are formed in the human ovary two and a half years after birth.

There can be then no doubt that both ovum and epithelium of the Grafian follicle are derived from the primary germinal epithelium; Foulis maintains that only the ovum has such an origin, while the epithelium of the Grafian follicle is derived from

the stroma; but in this he is at variance with all recent investigators, as Pflüger, Waldeyer, Romiti, Balfour, and many others.

The human parovarium, or organ of Rosenmüller, consists of a number of tubes situated in the ligametum latum, or extending into the hilum, as is the case in many mammals. The tubes are lined with columnar ciliated epithelial cells in the human subject, in the dog they are lined with polyhedral cells (Waldeyer).

The termination of the blood-vessels is in a dense capillary network around the larger follicles, but the albuginea as well as the stroma contain numerous capillary vessels.

According to His, the lymphatics form, in the hilum, a network of tubes with valves, and are connected with lymph spaces that surround a greater or smaller part of the periphery of the large Grafian follicles.

Waldeyer traced very fine medullated new fibres into the parenchyma, where they are lost amongst the larger Grafian follicles.

According to Elischer, there is a network of non-medullated nerve fibres in the stroma of the ovary. The outer membrane of the large Grafian follicles possesses a distinct network of fine nerves with wide meshes; in connection with this is a dense network of fine varicose nerve fibrils placed closely against the membrana granulosa.

The Oviduct.

The wall of the oviduct, including the fimbriæ of the infundibulum, is composed of a mucous membrane, a muscular coat, and an outer adventitia, the peritoneum.

The mucous membrane is a dense connective-tissue feltwork, containing a rich network of capillary blood-vessels; on its inner free surface it is covered with columnar epithelium; the cells are conical and ciliated, and between them are wedged in spindle-shaped or inverted conical cells (see Chapter II.). The mucous membrane is placed in longitudinal or complex folds, and at the base of the folds there are more layers of the epithelium than at their top.

The mucous membrane does not contain any glands, neither in man nor in other mammals. In sections through the ampullar portion there appear depressions of the

epithelium into the mucous membrane, but these are due to the folds cut in various directions. Hennig, however, maintains the existence of tubular glands in the human oviduct as well as in that of mammals.

The muscular coat is composed of bundles of unstriped muscular cells, arranged pre-eminently circularly. There are, however, more externally oblique or even longitudinal bundles to be met with.

The adventitia is a connective-tissue membrane with networks of elastic fibres.

The Uterus.

As in the oviduct so also in the uterus the wall consists of a mucous membrane, a muscular coat, and an outer adventitia, the peritoneum.

The epithelium covering the free surface of the mucous membrane is a single layer of shorter or longer ciliated columnar cells, each with an oval nucleus. These cilia are very perishable, for soon after death and after hardening they are very difficult to recognise. Friedländer found in the human uterus the whole cavity of the uterus and the canal of the cervix lined with ciliated columnar cells. This columnar ciliated epithelium commences, according to Lott, in children in about the middle of the cervix; in adults it reaches to the ostium externum. The surface of the portio vaginalis is covered with stratified pavement epithelium. This is thinnest where the mucous membrane passes into that of the vagina; it gradually increases in thickness towards the ostium uteri externum, and just before this is reached the epithelium is thickest. Into the stratified pavement epithelium extend minute papillæ from the subjacent mucosa.

The mucous membrane differs greatly in structure and appearance in the cervix and in the fundus.

a) In the cervix it is a dense connective-tissue membrane arranged in a number of permanent folds, the palmæ plicatæ. Few and thin bundles of unstriped muscle cells penetrate from the outer muscular coat into the mucous membrane. Between, and in the palmæ plicatæ, are minute glands whose membrana propria is intimately connected with the connective-tissue of the mucosa. These glands are shorter or longer cylindrical or irregularly shaped tubes, possessed of a large lumen and lined with a single layer of columnar cells, which, in the newborn child at any rate, are ciliated. According to Friedländer, however, they are polyhedral and non-ciliated. Some of the epithelial cells are goblet cells (Friedländer, Wyder).

In the adult these gland tubes are longer than in the newborn child, owing to the mucous membrane being much thicker in the former than in the latter.

According to Kölliker, Hennig, Tyler Smith, and others, the mucous membrane of the cervix, in the lower portion, projects beyond the general surface in the shape of

minute long and thin papillæ, covered with ciliated epithelium, like the general surface, and each containing a loop of capillary vessels; but, according to Henle, with whom I agree, these 'papillæ' are in reality only sections through the septa or folds of the surface.

b) In the fundus the mucous membrane contains, according to Leopold, fibrous connective-tissue, in the shape of a spongy or honey-combed plexus of fine bundles, covered with endothelial plates of various sizes, each with an oval flattened nucleus. These endothelial plates are connected into more or less continuous membranes. The spaces of the spongy matrix are lymph spaces; glands and blood-vessels are situated in them. The endothelial plates form lamellated sheaths around the blood-vessels and glands (Leopold). Between the endothelial membranes exist also branched cells, connected by their processes into a network (Wyder). Most observers, including Friedländer and Leopold, mention bundles of unstriped muscular tissue penetrating into the mucous membrane from outside, viz. from the muscular coat, but in the uterus of the newborn child I fail to detect them, except in the immediate vicinity of the muscular coat, and according to Kundrat and Engelmann there are no muscular bundles to be found in the mucous membrane of the adult uterus.

An important constituent of the mucous membrane are the glands, glandulæ uterinæ. In the newborn child they are limited chiefly to the sides. They are short and branched, and their number increases towards puberty, new glands being formed by tubular ingrowths of the surface epithelium (Kundrat and Engelmann). The glands are simple tubular glands; they are wavy, slightly convoluted or spiral, and terminate in the depth of the mucous membrane either as a single or branched cæcal dilatation. In the dog the glands are of two kinds, single and compound tubular (Sharpey).

Each gland tube possesses a delicate membrana propria, which is an endothelial membrane (Leopold); and this is lined with a single layer of columnar, pyramidal, or conical epithelial cells, each with an oval nucleus, situated in the outer third of the cell (Lott, Goroschankin). The epithelial cells are ciliated. This had been seen first in the glands of the sow by Allen Thomson, and afterwards by Nylander; in man by Friedländer, and in many domestic animals (cow, sheep, rabbit, mouse, &c.) by Lattaud, Ercolani. The cilia are very perishable, and in hardened specimens very difficult to see. Goroschankin maintains that in the glands of the dog and the cat the lining columnar epithelial cells are without cilia.

Comparing these glands in the newborn child and in the adult, it will be seen that they are (absolutely and relatively) much longer in the latter case.

During menstruation and in pregnancy the glands greatly increase in length.

The length of the glands varies in different animals and in the different parts of the same uterus. The mucous membrane of the uterus of the kangaroo, owing to its very great thickness, contains unusually long gland tubes (Turner).

According to Kundrat and Engelmann, the thickness of the mucous membrane becomes increased during menstruation, the epithelium of the surface and that of the greater portion of the glands being destroyed by fatty degeneration and finally altogether detached; its restitution takes place from the epithelium of the deeper portion of the glands; but, according to S. Williams, not only the epithelium but also the greater part of the mucous membrane is destroyed by fatty degeneration. Wyder confirms this.

The muscular coat forms the chief part of the wall of the uterus; its bundles are entirely composed of unstriped muscular cells. Their (bundles) arrangement is very different in different parts of the uterus, but on the whole they are arranged, in the fundus of the normal human uterus, in three strata (Henle):

a) An outer thin stratum, next the peritoneal covering, its bundles are longitudinal; towards the middle stratum there appear between them oblique bundles.

b) A middle coat, the prevalent direction of its bundles is circular, but there are numerous small longitudinal bundles between them.

c) An inner stratum whose bundles run obliquely and transversely.

The inner and middle coat are of almost the same thickness.

In the cervix the muscular coat is thinner; the muscular bundles are also arranged in three strata (Henle), an outer and inner longitudinal and a middle circular layer.

The outer longitudinal bundles pass from the uterus into the muscular coat of the adjoining organs, viz. the oviduct, ligamentum teres, and vagina.

The muscular bundles in all strata anastomose with one another into plexuses, and are separated from one another by a scanty connective-tissue; this is better seen in the inner and middle than in the outer stratum. The connective-tissue consists of fibrous lamellæ separated from one another by endothelial membranes. Numerous lymph clefts and lymph vessels are contained in this intermuscular connective-tissue (Leopold).

In the inner stratum, next the mucous membrane, the intermuscular connective-tissue assumes the character of that of the latter.

In the uterus-horns of mammals the muscular coat is generally composed of an outer longitudinal stratum and an inner thicker circular stratum, but the bundles of the former pass as oblique bundles into the latter. Also the inner bundles of the inner stratum possess in many places a more or less oblique direction.

The arterial trunks penetrating through the muscular coat into the mucous mem-

brane break up into capillary networks for the glands and for the subepithelial layer of the mucous membrane. In the muscular coat the arteries terminate in networks of capillaries for the muscular bundles.

The arterioles entering the mucous membrane of the cervix and its capillaries are distinguished by the great thickness of their wall (Henle).

The arrangement of the venous vessels of the anterior and posterior side of the fundus is, in the normal uterus of the child at any rate, of a peculiar nature, viz.: near the peritoneum, and more or less embedded in the outer muscular stratum, is a plexus of relatively small veins, running chiefly in a longitudinal direction, but the middle stratum contains huge venous sinuses or cavernæ more or less longitudinally arranged and connected into a plexus.

The wall of these venous sinuses is composed, as usual, of an endothelial membrane, and outside this is a very thin connective-tissue membrane, but the plexuses of small bundles of the muscular coat give to these sinuses a powerful support, for they surround them as circular or longitudinal or oblique bundles, the first being predominant. These venous sinuses are in open communication, on the one hand, with the capillary blood-vessels of this stratum of the muscular coat, and, on the other, with the plexus of smaller veins situated externally, as mentioned above. From this, then, it follows that we have here a condition of things analogous to that existing in the corpus spongiosum of the urethra, described on a former page; viz. the capillary blood-vessels discharge their blood into large venous sinuses surrounded by, and embedded in, a plexus of muscular trabeculæ; these sinuses anastomose with a plexus of veins much smaller than themselves.

This middle stratum with its venous sinuses differs in this respect in a marked manner from the inner stratum of the muscular coat, inasmuch as the latter stratum is without any venous sinuses and contains only small vessels, both arterial and venous, which pass through it in an oblique direction.

The lymphatics are very numerous; according to Leopold they are present in the mucous membrane as the above-named lymph sinuses lined with endothelium. These sinuses are in open communication with lymphatic vessels and lymphatic clefts situated in the connective-tissue of the muscular coat. They form an intercommunicating system, and both kinds of lymphatics are lined with an endothelium. In man their arrangement is very complex, owing to the complex way in which the muscular bundles are arranged. They lead into a subserous plexus of large lymphatic tubes with valves and saccular dilatations. In the uterus-horns of mammals the lymphatics of the muscular coat are of a more regular arrangement, being pre-eminently longitudinal in the outer, circular

in the inner muscular coat. Between the two are situated the collecting lymphatics with valves.

According to Lindgren the lymphatics of the mucous membrane of the cervix are connected with saccular sinuses extending near the epithelium of the inner surface of the mucous membrane.

The nerves of the muscular coat have the same arrangement and termination as in other unstriped muscular tissue (Frankenhäuser, Arnold); those entering the mucous membrane are connected with ganglia (Frankenhäuser, Luschka, Koch, Kehrer, and others). According to Lindgren the mucous membrane contains a plexus of non-medullated nerve fibres, which, near the epithelium of the free surface, give off bundles of very fine fibrils.

The Vagina.

The mucous membrane of the vagina is a dense connective-tissue feltwork, with numerous elastic fibrils forming networks. It projects above the general surface in the shape of longer or shorter conical or irregular pointed or blunt permanent folds or papillæ. The epithelium of the free surface is a thick stratified pavement epithelium of the ordinary description; into this the superficial layer of the mucous membrane, viz. the mucosa, projects in the shape of long cylindrical or conical simple or divided papillæ.

According to v. Preuschen there exist in the mucous membrane tubular glands lined at their fundus with ciliated columnar epithelium. Hennig also describes tubular glands in the mucous membrane, especially of the fornix and introitus vaginæ; in the rest of the organ they are very rare.

The deeper part of the mucous membrane is loose in its texture, and represents the submucosa.

Outside this is the muscular coat, consisting of an inner circular and an outer longitudinal stratum of bundles of unstriped muscular cells. There are oblique bundles passing from one layer into the other. Muscular bundles penetrate into the submucosa, and further into the mucosa, where they may be traced up to near the epithelium. The muscular bundles are separated from one another by a relatively large amount of connective-tissue.

Outside the muscular coat is a layer of connective-tissue; embedded in it is the outer plexus of veins, plexus venosus vaginalis.

The arterial branches entering the mucosa break up into a capillary network from which simple or compound loops pass into the papillæ.

The variously shaped projections (folds or rugæ) above mentioned contain a plexus of large veins. The connective-tissue between these vessels includes bundles of unstriped muscular cells derived from the muscular coat, as mentioned above. We have thus an arrangement similar to a cavernous tissue (Gussenbaur).

A second plexus of veins is situated in the submucous tissue, whose meshes are elongated and parallel with the long axis of the vagina.

The connective-tissue, in which the above-named plexus venosus vaginalis is situated, that is the plexus outside the muscular coat, contains numerous bundles of unstriped muscular cells derived from the circular stratum, and hence this plexus also resembles a cavernous tissue (Gussenbaur).

The lymphatics form plexuses of fine vessels (capillaries) in the mucosa and of large tubes with valves in the submucosa. There are also numerous lymphatic vessels connected into networks in the muscular coat. The efferent vessels lead into a rich plexus of large lymphatic trunks with saccular dilatations situated in the connective-tissue outside the muscular coat.

The mucous membrane possesses either small well-defined solitary lymph follicles or diffuse adenoid tissue (Loewenstein).

The nerve branches form a plexus, in the nodes of which are contained ganglionic swellings.

The Urethra.

The epithelium lining the mucous membrane, in the part next the bladder, is a stratified transitional epithelium consisting of a superficial layer of short columnar, or club-shaped cells, below which are several layers of polyhedral or cubical cells; further outwards, that is nearer the orificium externum, it is a stratified pavement epithelium.

The mucosa is a dense connective-tissue containing rich networks of elastic fibres (Robin and Cadiat) and a greater or smaller amount of diffuse adenoid tissue. Numerous minute papillæ with capillary loops project into the epithelium.

A great many short simple or compound tubular mucous glands are found in all parts of the urethal mucous membrane, the glands of Littré; they are analogous to those described of the male urethra.

The deeper or loose section of the mucous membrane, viz. the submucosa, contains a plexus of large venous vessels; the tissue between them contains bundles of unstriped muscular cells, and thus resembles cavernous tissue.

This cavernous tissue is considered by some anatomists (Arnold, Henle, and others) as belonging partly or wholly to the next outer stratum, viz. the longitudinal layer of the muscular coat.

The muscular coat consists of an inner longitudinal and an outer circular stratum of unstriped muscular cells. To this latter are added a circular and in some places also a longitudinal layer of striped muscular fibres.

The Nymphæ, Clitoris, and Vestibulum.

All these parts are covered with a thick stratified pavement epithelium of the ordinary description. The mucous membrane underneath is a dense connective-tissue membrane, containing also elastic fibrils, and projecting into the epithelium as smaller or larger conical or cylindrical papillæ containing loops of capillaries.

The mucous membrane of the nymphæ contains sebaceous glands conspicuous by their size, but no hairs.

There is a superficial and a deep network of capillary blood-vessels in the mucous membrane of the nymphæ, permeating a plexus of large veins, whose supporting tissue contains bundles of unstriped muscular cells, and hence this portion corresponds in structure to cavernous tissue (Gussenbaur).

The corpora cavernosa clitoridis and the bulbi vestibuli coincide in structure to the cavernous bodies described of the analogous parts of the male (Gussenbaur).

The genital end-bulbs and Pacinian corpuscles of the clitoris have been described in a former chapter.

The glands of Bartholin are analogous to the glands of Cowper in the male. They are huge compound tubular mucous glands (see a former chapter).

The connective-tissue separating the lobules contains unstriped muscular tissue. The alveoli or gland tubes are lined with a single layer of columnar mucous cells, imbricated with their outer pointed extremity (Langerhans). The ducts are lined with shorter or longer columnar epithelial cells. The chief duct possesses a special wall of connective-tissue and unstriped muscular cells. The stratified epithelium of the vestibulum is continued a short distance into the mouth of the chief duct.

The Mammary Gland.

As in other glands, so also here we distinguish the *framework* from the *parenchyma*; the former is lamellar connective-tissue, subdividing the latter into the lobules and containing a small amount of elastic fibres; in some cases, as in the rabbit, guinea pig, cow (Winkler, Kolessnikow), there are also small bundles of unstriped muscular cells to be met with. From the interlobular septa minute bundles of connective-tissue may be traced between the gland-alveoli. These bundles are well seen in the marginal parts of a lobule; in the centre of this latter the alveoli are separated from one another

apparently only by the capillary blood-vessels. But there are everywhere branched nucleated connective-tissue corpuscles to be found between the alveoli; according to Winkler also elastic fibrils, and in the rabbit, occasionally but not constantly, unstriped muscular cells.

In the resting as well as in the secreting gland there are also migratory or lymph corpuscles to be found between the alveoli. They are relatively more numerous in the former than in the latter; they vary in numbers in different glands and in different parts of the same gland. According to Creighton, in the resting gland, they are derived from the epithelium contained in the gland alveoli. The resting gland contains, in addition, in the connective-tissue surrounding its alveoli large granular yellow (pigmented) nucleated cells; similar cells are found also in the alveoli, and Creighton maintains that both are identical, being derived from the alveolar epithelium; from the connective-tissue they find their way into the neighbouring lymphatic glands. The production of the small lymphoid and the large pigmented cells constitutes, according to Creighton, the principal function of the resting gland.

The large ducts, passing from the lobules, possess a thick connective-tissue sheath and unstriped muscular cells. These latter are derived from the muscular bundles of which the skin of the nipple of the breast abounds.

The parenchyma of the active mammary gland consists of the ducts and the alveoli. The membrana propria of the ducts is an endothelial membrane (Langerhans); it is lined with a single layer of columnar epithelial cells, each with an oval nucleus. On the nipple the rete Malpighii of the epidermis is continued a short distance into the mouth of the ducts.

In the large lobular ducts the epithelial cells are short columnar or polyhedral. They give off the short terminal ductlets, lined with a single layer of flattened pavement cells, each with a spherical or slightly flattened nucleus.

It is necessary to remember that also in this gland the height of the epithelial cells lining the ducts is dependent in a great measure on the state of contraction or distension (by secretion or otherwise) of the latter, for we find the epithelial cells in a large duct, if distended, less columnar than in a smaller branch, if contracted.

Where the terminal ductlets join, so as to form a larger duct, the latter possesses a saccular dilatation.

Each terminal ductlet takes up several alveoli; these are longer or shorter wavy and convoluted tubes possessed of cylindrical or saccular lateral branchlets. Owing to the wavy and curved nature of the alveoli, each section made through the gland shows them cut in various directions, transversely, obliquely, or longitudinally.

The diameter of the alveoli is larger than that of the ductlets. Each alveolus is

limited by a membrana propria, lined with an epithelium; in the centre of the alveolus is a distinct lumen. This latter varies in different alveoli of the same lobule; in the alveoli that are in a state of secretion it is a very conspicuous cavity, and is three and four times as large as in others, in which it is reduced to a minute canal. The state of secretion is indicated by its products (milk, albumen) being contained in the epithelial cells and in the lumen of the alveolus (see below).

The membrana propria is a delicate transparent membrane, composed of a basket-shaped network of flattened branched nucleated cells (Langer, Kolessnikow).

The epithelium lining the lumen is a single layer of granular-looking epithelial cells, each with a spherical nucleus. In the 'secreting' alveoli, that is in those with a large lumen, and containing the products of secretion, the epithelial cells are polyhedral or cubical, each with a spherical or slightly compressed nucleus.

According to Kolessnikow in some alveoli there is a second layer of small round cells to be found underneath the polyhedral cells lining the lumen; a similar relation also exists, according to the same observer, in some of the ducts.

In the alveoli with a minute lumen the epithelial cells are uniform and more or less columnar. But in the 'secreting' alveoli, some of the lining epithelial cells contain one or more larger or smaller milk globules; the cells containing one big globule appear enlarged either towards the lumen, and are then columnar, or in the broad diameter, and are then cubical.

The larger the globule, contained in the cell, the more distinctly is the nucleus pressed to the periphery, the cell substance being reduced to a protoplasmic mantle around the milk globule; the appearance of such a cell is identical with that of a fat-cell filled with one large oil-globule (see Chapter VI.).

The milk globules contained in the epithelial cells are each distinctly contained in a cavity (vacuole) of the latter, but they possess their own delicate albuminous membrane. Of precisely the same nature are the milk globules contained in the lumen of the alveolus, that is those that have been ejected from the epithelial cells, they possessing each their albuminous envelope, Ascherson's membrane (C. Schwalbe). This envelope can be recognised as a delicate membrane becoming faintly but distinctly stained in logwood. In a preparation of hardened gland treated with alcohol and oil of cloves, the fat of the milk globule having been dissolved, the albuminous envelope is alone left behind.

The alveoli differ as regards the number of the epithelial cells containing milk globules, as well as regards the number of the latter excreted into the lumen of the alveolus.

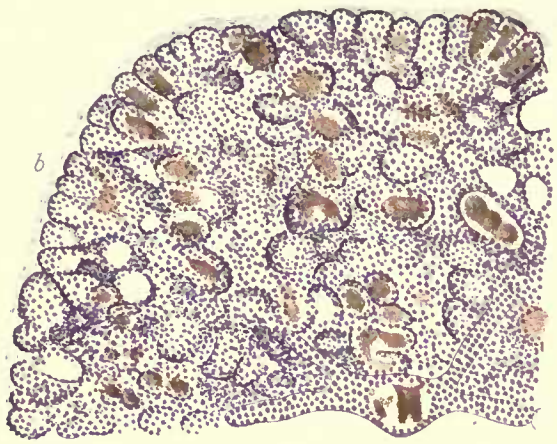

I

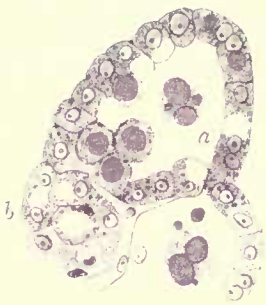

II

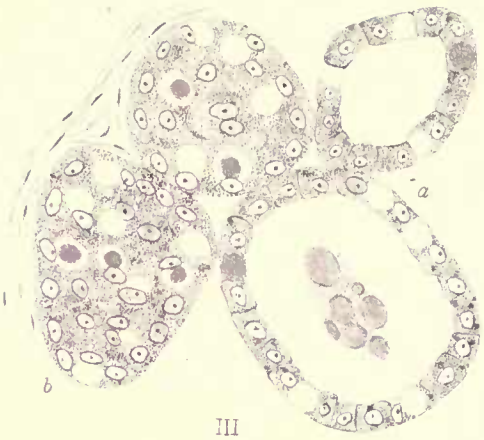

III

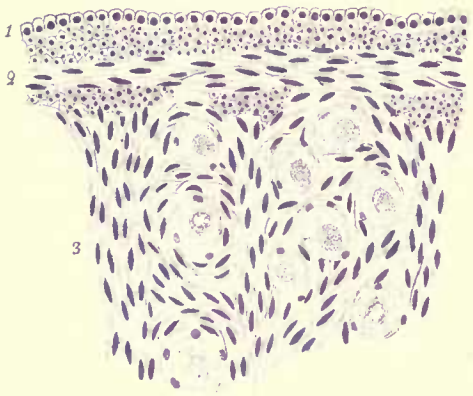

VI

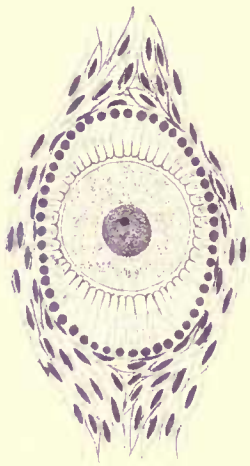

V

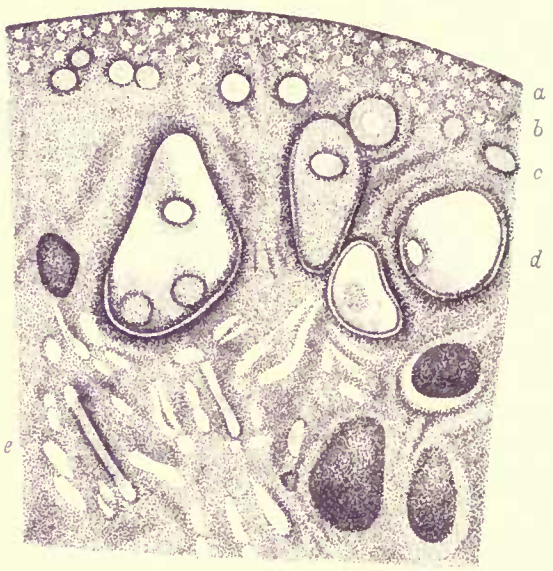

IV



VII

VIII

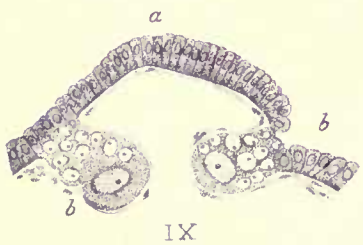

IX

XI

X

From all the appearances it seems then clear, that the production of the milk globules is similar to that of oil-globules in fat-cells, viz. it takes place within the cell substance, the smaller globules becoming gradually confluent into larger ones (Langer, Creighton, Winkler, Schmid, Kolessnikow, and others).

It is most probable that the epithelial cells eject the milk globules produced in them without however becoming themselves (epithelial cells) destroyed (Langer). According to Schmid the epithelial cells, after having for some time secreted milk globules, undergo degeneration, and become replaced by new cells produced by the division of the other epithelial cells.

The *milk* of a mammary gland in full secretion contains in a transparent homogeneous interstitial fluid the milk globules. These are of very various sizes, and each consists, as already stated, of a thin albuminous envelope and a fat-globule. Very few remnants of broken-down cells and nuclei are found in the milk.

In the *colostrum* there are contained numerous nucleated cells more or less filled with milk globules—the *colostrum* corpuscles. These exhibit amœboid movement, and while moving may eject the milk globules (Stricker).

During the transition of the resting gland into the state of lactation the alveoli filled with epithelial cells become greatly enlarged in numbers, their epithelium undergoing a corresponding multiplication ; the central cells of each alveolus become gradually filled with milk globules produced in them, and are carried away by the ducts as colostrum corpuscles (Hasse, Henle, Kölliker, Langer, Creighton, Buchholz, and others) ; the peripheral cells persist in the alveolus as the epithelium lining the membrana propria.

The alveoli of the active gland are surrounded by a dense network of capillary blood-vessels, which for each lobule form a continuous system.

In the interlobular connective-tissue lie networks of lymphatic vessels (Langhans). The alveoli are surrounded by lymph spaces (Coyne) like the seminal tubes or the alveoli of the salivary glands (see former chapters). According to Kolessnikow they empty themselves into the interlobular lymphatic vessels.

PLATE XL.

Fig. I. From a section through a lobule of the mammary gland of the cat in the later stages of pregnancy. Magnifying power about 45.

a. A lobular duct branching into four small ducts. The alveoli of the gland are

indicated as spherical oval or oblong structures, many of them containing a coagulum stained brownish purple.

b. The connective-tissue around the lobule.

The epithelial cells lining the ducts as well as those of the alveoli are indicated by their nuclei only.

Figs. II. and III. from the same gland as shown in fig. I., but under a much higher power, about 400.

a. Alveoli in transverse section, their lining epithelium is seen in profile. It consists of a single layer of polyhedral or short columnar cells, each with a spherical or oval nucleus. Some of the cells contain a larger or smaller cavity, either filled with a milk globule stained purple, or empty, the milk globule having been discharged. In the cavity of the alveoli are seen such discharged milk globules of various sizes; they are embedded in a finely granular matter, coagulated albumen. The purple staining of the milk globules is most probably due to their being each ensheathed in an albuminous envelope.

b. The lining epithelium viewed from the surface.

Fig. IV. From a vertical (longitudinal) section through the ovary of a half-grown cat; magnifying power about 40.

a. The albuginea; the germinal epithelium covering it is not shown, owing to the low magnifying power.

b. The cortical layer of small Grafian follicles.

c. The next layer of middle-sized Grafian follicles.

d. The deep layer of Grafian follicles, one containing three ova, each in a separate discus proligerus.

e. The zona vasculosa of the hilum.

Fig. V. A Grafian follicle of the layer *c* of the previous figure under a higher magnifying power, about 350.

The Grafian follicle is surrounded by layers of the spindle-shaped cells of the stroma. A delicate membrana propria with staff-shaped nuclei forms the boundary of the follicle itself. The membrana propria is lined with the membrana granulosa, a single layer of beautiful columnar epithelial cells. The centre of the follicle is filled with the ovum, containing a large nucleus or germinal vesicle, in which is seen the germinal spot or nucleolus. The ovum is surrounded by a bright zona pellucida, here represented as a clear space, the outer surface of which is intimately connected with the interstitial substance between the cells of the granulosa.

Fig. VI. From the same preparation as fig. IV., but under a higher power, about 350.

1. Germinal epithelium of the surface.

2. Albuginea, composd here of spindle-shaped cells, arranged as a superficial longitudinal and a deep transverse layer.

3. The groups of small Grafian follicles forming the cortical layer of Schrön.

Each of these follicles shows a distinct membrana propria lined with a layer of transparent flattened cells, membrana granulosa. The nucleus or germinal vesicle of the ovum contains a beautiful reticulum, not well shown in the figure.

Fig. VII. From the layer *d* of the same specimen as in figure IV. Magnifying power about 350.

a. Membrana propria and membrana granulosa (indicated by its nuclei) of a portion of a large Grafian follicle.

b. The ovum in its discus proligerus.

c. The stroma of spindle-shaped cells.

d. A bundle of spindle-shaped cells cut transversely.

e. Group of interstitial epithelial cells (see the text).

Fig. VIII. A small Grafian follicle of layer *c* of figure IV., under a magnifying power of about 350.

The membrana propria, the epithelium lining it, the zona pellucida, and the ovum are well shown.

The germinal vesicle contains a well-developed reticulum, not distinctly shown in the figure.

Fig. IX. Copied from Kolessnikow in 'Archiv für mikroskopische Anatomie,' vol. xv. Plate xxv.

From a section through the ovary of perca fluviatilis.

a. The germinal epithelium.

b. Two nests of epithelial cells, each with an ovum.

The surrounding stroma is not represented here; the nests are still in connection with the germinal epithelium of the surface (see the text).

Fig. X. From a transverse section through the fundus uteri of a newborn child. Magnifying power about 40.

a. Cavity of the uterus, lined with a layer of columnar epithelium; the gland tubes embedded in the mucosa are seen cut in various directions.

The figure represents not quite one half of the circumference of the cavity of the uterus.

b. The mucosa; owing to the low magnifying power only the nuclei of its cells are indicated here.

c. The inner muscular layer, composed of bundles, most of them cut obliquely because running in an oblique or more or less longitudinal direction.

d. A broad middle layer of circular muscular bundles; between them are veins, of the cavernous body (see the text); the venous vessels are cut here in various directions; between them are arteries and capillaries cut transversely.

e. The outer layer, containing oblique and longitudinal muscular bundles, and between them small veins, most of them cut transversely.

Fig. XI. Portion of a venous sinus of the layer *d* of the preceding figure. Magnifying power about 90.

s. Lumen of the venous vessel.

m. Matrix composed of plexuses of bundles of unstriped muscular cells, and between them connective-tissue; the matrix projects into the vein in the shape of shorter or longer septa or trabeculæ.

c. Minute vessels, chiefly capillaries, filled with, and greatly distended by, blood-discs stained brownish purple.

UNIVERSITY OF CALIFORNIA

CHAPTER XXXIII.

THE SKIN.

THE skin of man and mammals consists of the following parts: the epidermis, the corium or cutis with the papillæ, and the subcutaneous tissue with the fat.

THE EPIDERMIS.

The different parts of the epidermis, viz. the rete or stratum Malpighii, the stratum of granular cells of Langerhans (stratum granulosum of Unna), the stratum lucidum, and the stratum corneum, have been mentioned in Chapter II. pp. 15 and 16. A few points only will be added here to the previous description. As regards the rete Malpighii—the term stratum Malpighii is preferable—it has been mentioned that the cells of the deepest layer are more or less columnar with oval nuclei, whereas those of the middle layers are polyhedral, with more or less spherical nuclei. The substance of the cells of the deepest layer, both in the skin of dark individuals and in such parts of the skin of man and mammals generally as are normally coloured (viz. the nipples, scrotum, and labia majora), contains a variable amount of brownish pigment granules.

Both in the deepest and middle strata we meet with nuclei, whose outlines are more or less notched, and which therefore present a lobed, hourglass-shaped, or irregular appearance. This is probably due to the fact that during life the nuclei are possessed in a certain small degree of the power of spontaneous contraction (Flemming).

The nucleus of some of the cells of the deepest layer contains within a distinct but delicate membrane a honeycombed reticulum, without any nucleolus. That of others does not possess any special limiting membrane, and includes a more or less dense convolution of fibrils deeply staining in the different dyes. Then there are cells, whose nucleus has still further advanced towards division: the nucleus is larger, does not possess any membrane, and its fibrils become arranged as a rosette; then they change into a star—Monaster, and later on into a double star—Dyaster. Now the cell itself becomes divided into two in a line separating the two stars of the dyaster. Each of these daughter stars is of course much smaller than the mother star preceding the stage of the dyaster. The daughter star changes into a *Convolution*; this again changes into a nucleus, similar in size, shape, and appearance to the nucleus of the cells in the middle layer of the stratum Malpighii, being spherical, well-defined by a

distinct membrane, and including a honeycombed reticulum with or without one or more thickenings—nucleoli.

This indirect division of nuclei will be fully described in a future chapter, but it may be pointed out here that as a rule in the normal state only the cells of the deepest layer undergo the division, and that the cells derived from them pass on into the next layers.

Occasionally, though very rarely, a nucleus of a cell above the deepest layer may be seen in one of the stages of indirect division.

This mode of division has been observed in the nuclei of the deepest layer of cells of the epithelium of the cornea, of the skin and mucous membranes in the adult and embryo, under normal and abnormal conditions, in lower and higher vertebrates (Mayzel, Eberth, Flemming, Klein, Peremeschko).

The cells of the deepest and middle layers are separated from one another by a clear interstitial cement-substance, which, as has been stated on former occasions, increases to a considerable extent under inflammatory conditions. The cell-substance is a dense reticulum, and hence presents the appearance of 'granular' protoplasm, but contiguous cells remain connected by minute processes, i.e. of the prickle cells, described p. 16.

Towards the surface of the stratum Malpighii the epithelial cells and their nuclei become more and more flattened, and gradually filled with peculiar granules. These granules are more or less discoid, and therefore appear rodlike in the profile view. They increase in size and numbers towards the surface of the stratum Malpighii, as has been stated p. 16. They stain a deep purplish blue in hæmatoxylin, and hence become very conspicuous in preparations coloured with this dye. This section of the stratum Malpighii, viz. the cells containing the granules, represents the 'stratum of granular cells' (Langerhans), 'stratum granulosum' of Unna. The granules are neither protoplasm nor horny matter, Keratin, like that of the cells of the stratum lucidum or stratum corneum, but are probably a transitional stage between the two.

The stratum granulosum varies in thickness, in the different localities, like the epidermis as a whole; in some places where the epidermis is very thick, as in the palm of the hand and foot, this layer is also well developed, consisting of three, four, and more layers of cells. In other places, as on the inner side of the arm and forearm, thigh, the cubital, popliteal, and similar regions, where the epidermis is very delicate, the stratum granulosum is only rudimentary. It is better developed at the mouth of the hair follicles and in their neighbourhood than in the parts between them, it is also well developed near the nails; it is not found in the nail-bed (Heynold), but its absence is limited to the matrix of this (Hebra).

In the stratum lucidum the scales are very closely pressed against one another, and

each of them contains a rudiment of a staff-shaped or flattened nucleus. In many places longitudinal rows of what at first appear as bright granules can be distinguished in this stratum. These granules are, however, minute air-cavities between the layers of scales. After becoming confluent into clefts, a separation of these layers is effected, and a condition is produced such as is found in the superficial section of the stratum corneum, viz. the layers of scales are more or less separated from one another by longer or shorter clefts.

The stratum Malpighii rests on the papillary layer of the corium, and is sunk in between the papillæ as the interpapillary processes; the length of these varies in direct proportion to the height, the breadth in an inverse proportion to the closeness of position of the papillæ. The constitution of the interpapillary processes differs from the other part of the stratum Malpighii in the following points: the vertical diameter, i.e. the thickness, of the stratum Malpighii is of course greater in the interpapillary processes than between them. This increase in thickness is due to the presence of a greater number of layers of what were previously described as the middle layers of polyhedral cells, with spherical nuclei; the deepest cells of the interpapillary processes are placed vertically on the sides of the papillæ of the corium and the grooves or pits between them; those of the rest of the stratum Malpighii rest on the summits of the papillæ.

Occasionally the cells of the middle layers of the interpapillary processes are more or less elongated in a direction vertical to the surface; hence they appear spindle-shaped, and their nuclei are then oval; under these circumstances also the cells of the deepest layers are much drawn out, and are very thin, and spindle-shaped (Klein). Such a condition is due to the softness of the epithelial cells, and to their being consequently easily brought into those shapes by the shrinking of the skin during hardening or otherwise.

The surface of the stratum Malpighii, including the stratum granulosum, possesses a wavy outline where the stratum corneum and the stratum lucidum are elevated into permanent ridges with corresponding furrows between, as in the palm of the hand and on the fingers; the breadth of the ridges is here about that of two or three papillæ with their corresponding interpapillary processes taken together.

The stratum Malpighii is firmly fixed on the surface of the corium by an albuminous cement identical with that which is found between the epithelial cells. The lower or deeper surface of the epithelial cells, that is the one resting on the corium, is in well-prepared specimens not quite flat, but indentated, and toothed; when, as in the above-named condition of shrinking, the cells of the deeper layers are elongated to an abnormal extent, the appearance is produced as if they were continued by fine filamentous processes into the tissue of the papillæ. The epithelial cells themselves are, however, not continued into the tissue of the papillæ; only the albuminous inter-

stitial or cement-substance between the epithelial cells can be traced into the similar substance containing the lymph-canalicular system and separating the bundles of connective-tissue of the matrix of the papillæ, a relation which has been minutely described on a former occasion, Chapter XXII. p. 175, in connection with the epithelium of mucous membranes and the endothelium of serous membranes. And just as in the case of the mucous- and serous membranes, so also in the skin, the branched lymph-spaces and the connective-tissue corpuscles of the papillæ extend into, or rather are continuous with, branched lymph-spaces and their cells situated in the interstitial cement-substance of the stratum Malpighii; here they may be seen to extend between the cells of the deeper and middle layers, their processes extending chiefly in a direction parallel to the surface; hence they are better seen in horizontal sections through the stratum Malpighii; their processes are then seen to lose themselves in the interstitial substance. These branched connective-tissue cells are very conspicuous, and easily perceived when they contain pigment granules, as is the case in the pigmented parts of the skin of lower vertebrates and of mammals, as well as in the skin of dark individuals, and in the pigmented localities of the skin in general. These pigment granules are not to be confounded with the ones present in the substance of the deepest epithelial cells themselves. The intraepithelial branched nucleated connective-tissue cells have been mentioned in Chapter II. on p. 18; they are met with not only in all parts of the skin of man, mammals, and lower vertebrates, but also in all epithelium of mucous membranes and glands, as has been pointed out on many previous occasions.

Biesiadecki saw them in the epidermis of the human skin, but took them to be leucocytes migrating into the epithelium to become there converted into epithelial cells. Langerhans found them in chloride of gold specimens, since they become deeply stained by this reagent, and chiefly for this reason they were by this observer and by Podkopaeff believed to be nerve terminations.

Eberth and Eimer also saw them; the latter found them to be very numerous in the nipple of the cow, but did not regard them as connected with nerve fibres.

That they very probably are possessed of amœboid movement is shown by: (1) the very great differences exhibited by their processes; in some instances they are possessed of short thick knoblike processes, in others of long filamentous branched ones; (2) in the intraepithelial pigmented and unpigmented cells of the epithelium of the tail of the tadpole such movements, although slow, can be nevertheless distinctly observed. Similar movements have been observed in the intraepithelial branched cells of the cornea by v. Recklinghausen, Stricker, and others.

Early in the fœtal state the branched connective-tissue cells of the skin and mucous membranes grow into the epidermis or epithelium respectively of the surface, and

thus represent the rudiments of the intraepithelial branched cells, as just described of the adult organs.

The Corium.

The boundary between the stratum Malpighii of the epidermis and the superficial part of the corium is represented by a fine but distinct membranous structure, basement membrane, which is very conspicuous in preparations stained with dyes. While in some instances it appears as a bright substance separating the deepest layer of epithelial cells from the corium, in others it takes the staining very readily. But in all instances it appears to be merely the deepest portion of the epithelium and, in fact, is made up of the basis of the individual epithelial cells which has undergone a chemical and morphological alteration. The basement membrane is then a direct product of the deepest layer of the epithelium, and its several constituent elements are comparable to the foot-plate (Fussplatte: Lott, Rollett, and others) of the deepest or columnar cells of stratified epithelium.

The superficial part of the corium is raised as conical or cylindrical papillæ. These vary to a very great extent, both as regards their number and their size in different localities, and at different points of the same locality. They are best developed in the corium of the human skin. The papillæ are largest in the palm of the hand, on the volar side of the fingers, and the sole of the foot; they are well shown on the scalp, lips of mouth, less so in the thin parts of the skin, as on the inside of the thigh and arm. In all instances, however, there exist the greatest differences as regards breadth and shape; thus, for instance, in the scalp and other localities we meet with rudimentary thin and narrow papillæ next to, or between well developed broad conical or cylindrical ones. In connection with this it is necessary to bear in mind that many papillæ, being flattened from side to side, may in section present themselves either from their broad or narrow side.

The matrix of the corium consists of bundles of fibrous connective tissue forming smaller or larger groups—trabeculæ, which cross each other and interlace in a complex manner, and so produce the feltlike density of the tissue of the skin. In the superficial parts of the corium, including the papillæ, the bundles and their groups are small and their division and mode of interlacing is intricate; in the deeper parts, or the subcutaneous tissue, the trabeculæ or groups of bundles are large; they branch, re-unite, and cross each other in many directions. For this reason the superficial part of the corium contains much smaller and more numerous interfascicular spaces than the deeper parts. In the former there is all through the matrix a more or less uniform distribution of the hyaline interstitial interfascicular substance containing the lymph-canalicular system with its branched connective-tissue corpuscles, while in the latter there are larger and

more continuous interfascicular channels and spaces and the connective-tissue corpuscles, as mentioned on a former occasion, form more continuous endotheloid membranes.

All blood-vessels and nerve branches, ducts, glands, hairs, &c., are situated in the interfascicular spaces.

The fixed connective-tissue corpuscles of the skin have been described in Chapter IV. pp. 28 and 29; they are in the superficial parts of the corium small transparent cells, composed of chief and secondary plates, all of them possessing filamentous processes; in the subcutaneous tissue they are larger and less branched; in some places they are even seen to form an endotheloid covering for the trabeculæ.

Each connective-tissue corpuscle includes an oval flattened nucleus, in which a fine reticulum can be made out. As regards the structure of these corpuscles refer to what has been said on p. 29.

In the superficial parts of the corium, especially in the papillary body as well as in the deeper parts of the subcutaneous tissue containing the coiled tube of the sweat glands, we meet with a few migratory cells in the interfascicular spaces, besides the flattened connective-tissue corpuscles; they are either small pale lymphoid corpuscles with one or two spherical nuclei, or they are two or three times larger, and possessed of coarse granules, which in some instances are brown pigment granules.

The small pale corpuscles in the normal state are rare; the corpuscles with coarse granules are occasionally tolerably numerous even in the normal state; they move very slowly, possess a relatively large clear, spherical, or oval nucleus; they correspond to Waldeyer's plasma cells. When unpigmented they assume in hæmatoxylin a deep purplish-blue colour, and hence become very conspicuous.

Considerable numbers of elastic fibres are present in all parts of the connective-tissue matrix of the corium; these fibres are much more numerous in the subcutaneous tissue than in the superficial part of the corium, and in the papillæ they are scarce. They present themselves as fine and coarse elastic fibres, connected by lateral branches into a network. The direction of these fibres is always parallel to that of the trabeculæ, to the surface of which they are closely attached.

In most instances we find fine and coarse elastic fibres side by side in the same place, but there exist great differences in the skin in different localities and of different individuals, both in the quality of the fibres, viz. whether fine or coarse, as well as in their number.

The deep section of the subcutaneous tissue contains smaller or larger groups of fat-cells, or a continuous thicker or thinner stratum of fat-cells arranged in lobules, the adipose stratum; between the lobules are thicker or thinner septa of fibrous connective

tissue. Fine bundles of connective tissue and connective-tissue cells penetrate together with the capillaries into the interior of the lobule between the fat-cells.

As regards the structure, arrangement, and development of the fat-cells the reader is referred to Chapter VI. pp. 42 and 43. I wish to add here that just as in other parts of the body, as in the serous and mucous membranes, in the loose tissue connecting neighbouring organs, &c., so also in the skin the fœtal fat tissue contains larger or smaller vascularised groups of cells which are in various stages of transformation into fat-cells, that is to say, whose protoplasm contains only a few or not even any oil globules. Gradually the oil globules make their appearance in all cells, and their number in each cell becoming greater, they become confluent into one large oil globule which now is the most conspicuous part of the cell; the protoplasm with the oval nucleus at one side forms a mantle around the oil globule, as has been described in Chapter VI. Now, what I wish specially to point out is, that even in the stage when few or no oil globules have appeared as yet in the above cells, these latter, being placed closely side by side, give one the impression that they all are spherical or oval cells slightly pressed against one another and separated from place to place by a capillary blood-vessel only. In reality, however, these cells are possessed of finer or broader processes, by which they anastomose with one another; the number of these processes is not however very large.

In a section through a hardened ganglion, the individual ganglion cells appear to be without processes, although in reality they may be possessed of one, two, or more.

At an early stage of development, when the lobule consists only of few cells, their nature of branched connective-tissue cells can be easier recognised. The very numerous lymphatics supplying the lobules of adipose tissue will be described below.

The Sweat-glands.

They are exceedingly numerous, and distributed uniformly in most regions of the skin. Each sweat-gland is a simple tube composed of a coiled portion, or the gland proper, situated in the subcutaneous tissue, and a duct, passing in a more or less vertical or oblique direction and slightly wavy through the corium, and opening on the free surface of the epidermis. The coils in the same gland are separated by a small amount of connective tissue, containing the numerous capillary blood-vessels, lymphatics, and in some places also a few fat-cells.

Beginning with the free opening, or the mouth, we trace the duct as a narrow canal,—at one place flattened and cleft-like, at another more cylindrical,—and limited by a bright homogeneous membrane, through all the layers of the epidermis in a more or less zigzag or spiral manner. The epidermic cells or scales respectively immediately surrounding the

duct form a sort of concentric outer layer around the above bright membrane. It passes from the epidermis into the corium *through an interpapillary process*, this latter being continued, but decreasing in thickness, on the duct as its epithelium.

The duct possesses also a continuation of the basement membrane mentioned above, and this is traceable over the whole length of the gland tube as the membrana propria. With nitrate of silver this membrane presents the appearance of an endothelial membrane (Czerny), but I doubt whether the individual scales possess a nucleus like true endothelial plates ; on the contrary, I am inclined to think that, just like the basement membrane, it is composed of the outer portion, the basis or foot-plate, of the epithelial cells next to it.

The duct consists then of: (*a*) a narrow canal ; (*b*) a homogeneous bright membrane lining this ; (*c*) an epithelium which is composed of two or three layers of small polyhedral epithelial cells each with a spherical or oval nucleus, and (*d*) outside this a delicate membrana propria.

The lumen or canal of the duct is distinct, in most places cylindrical, and therefore circular in transverse section. Whether the bright membrane lining this is homogeneous or possessed of flattened nuclei it is difficult to ascertain ; in some places, when looked at in profile, it certainly seems as if there were present in it at rare intervals staff-shaped nuclei. The lining membrane stains well in carmine. When it reaches the subcutaneous tissue, the duct becomes suddenly many times coiled up.

The first or proximal section, about one-third or one-fourth of the coiled tube, retains the same structure as the duct, and differs from it in the fact that it is coiled up and that its lumen is somewhat larger. The remainder, or *the distal part* of the coiled tube, is of a different nature, inasmuch as the membrane lining the lumen is reduced to a very delicate film, and the epithelium, which hitherto consisted of two or three layers of small polyhedral cells each with a spherical or oval nucleus, is replaced by a single layer of columnar longitudinally striated cells, each with a spherical nucleus in the outer part of the cell. The membrana propria of this section is however much thicker than in the former, and contains *on its inner surface*, that is, the one next the epithelial cells, a single and continuous layer of very slender unstriped muscle cells arranged parallel to the long axis of the tube. In some glands this muscle layer is more conspicuous than in others ; in some it is rudimentary, not being quite a continuous layer. As Ranvier pointed out, in the fœtus this layer of muscle cells is represented by a layer of cells identical in aspect and origin with the epithelial cells, so that in the fœtal gland there are two layers of epithelial cells, one, the inner one, which gives origin to the permanent epithelium, while the other is changed into the unstriped muscle cells.

As in other glands, so also here the state of contraction and that of distension by

the secretion has an important effect on the diameter of the lumen and the length of the lining epithelial cells. The smaller the lumen, the longer and thinner the epithelial cells; the more distended the former the shorter the latter. This distal portion of the coiled tube is then, even under a lower power, conspicuously different from the proximal, being thicker and more transparent.

In some localities, as in the scalp, palm of hand, and sole of foot, and especially the axilla, the scrotum, nipple, and labia majora, the distal portion of the coiled tube becomes greatly developed: being much longer, broader, and its muscle coat more conspicuous than in other localities.

In the sweat-glands of some of the domestic animals, as in the dog, pig, sheep, the gland consists of a long, more or less straight, narrow duct and a wavy or more or less convoluted tube; the former opens generally into the neck of a hair-follicle; it has a cylindrical lumen lined with a delicate membrane, which in some instances (dog) appears distinctly composed of nucleated scales. A single layer of short polyhedral cells, each with a spherical or oval nucleus, is found outside this membrane; the boundary is formed by a membrana propria. The duct passes suddenly into a broad tube (Stirling) which corresponds to the distal part of the coiled tube of the human sweat-gland. The longitudinal muscle coat is everywhere strikingly developed, and lies between the epithelium and the membrana propria. The epithelium is a single layer of shorter or longer columnar, transparent, or longitudinally and finely striated cells. The limiting membrana propria is generally thick, much thicker than in the human sweat-glands. The epithelial cells lining the duct do not appear continuous with those of the rest of the tube, and seem to commence suddenly at the end of the duct.

In all sweat-glands connective-tissue cells of the surrounding tissue may be seen to extend through the wall, and they may be found as small-branched nucleated corpuscles between the epithelial cells, as has been noticed of other glands in a former chapter.

The *ceruminous glands* of the external ear-passage are situated in the subcutaneous tissue; they are similar in structure to the sweat-glands of other parts, but the coiled tube corresponds in structure to the distal part only of the ordinary sweat-gland. The tube is large and is lined with a single layer of columnar cells, each of which possesses a clump of pigment granules in the inner part; a spherical nucleus is situated in the outer portion of the cell; between this layer of epithelial cells and the distinct homogeneous limiting membrana propria is a continuous layer of unstriped muscle cells (Sangster).

The human anus is surrounded by an elliptical zone containing large coiled gland tubes, the *circumanal glands* of A. Gay. Each of these glands corresponds to a huge sweat-gland; it is composed of a duct and of the coiled tube which in its structure coincides with the distal part of the ordinary sweat-gland, viz. its epithelium is a single layer of transparent columnar cells; outside these is a continuous longitudinal layer of unstriped muscle cells, and outside these is the thick homogeneous limiting membrana propria.

The peculiar sweat-glands situated in the eyelid, and known as the glands of Moll, will be described in connection with the eyelid.

The presence of a longitudinal layer of unstriped muscle cells was first pointed out by Kölliker in the sweat-glands of the axilla, of the root of penis, and of the nipple. Krause and Heynold found them in all glands.

That the muscle coat is between the homogeneous membrana propria was pointed out by Kölliker, myself, Sangster, and Hesse; for the glands of Moll the same was pointed out by Sattler.

That the duct of the sweat-gland possesses, next to the lumen, a homogeneous membrane, a sort of cuticle, was correctly described by Heynold and also by Hörschelmann; with the latter I find it also in the proximal part of the coiled tube.

That the coiled tube of the sweat-gland of man, with the exception of the ceruminous and circumanal glands, consists of a smaller proximal and a longer and larger distal part has been indicated already by Heynold and Hörschelmann, both of whom stated that the duct contributes to the formation of the coiled tube.

According to Hesse the ducts of the sweat-glands of the axilla and anus often open into the mouth of a hair follicle.

Renaut pointed out a difference of aspect during rest and secretion in the epithelial cells of the sweat-glands of the horse, being transparent with peripherally placed nucleus before, granular with central nucleus immediately after, secretion.

The sweat glands in the earliest stages are solid knob-like projections of the stratum Malpighii into the tissue of the corium; they appear closely at the side of the hairs but much later than the latter, about the fifth month in the human fœtus. They are, like the stratum Malpighii of the fœtus, composed of polyhedral small cells, each with a spherical nucleus. The cells of the outermost layer, however, like those of the deep layer of the stratum Malpighii, are slightly elongated, columnar. These rudiments grow through the corium into the subcutaneous tissue, where they begin to coil.

Very soon, however, before they have grown far into the depth of the corium, the epithelium of the duct shows a distinction into central and marginal cells, the former being much elongated and spindle-shaped. It is quite possible that these elongated cells are

the cells from which the inner membrane lining the canal is derived. Of a canal there is little to be seen in the duct at birth, whereas even at this period the coiled tube shows already a distinct though small lumen. At birth the distal part of the coiled tube possesses a well-marked muscle coat, and its epithelium consists of a layer of columnar cells.

The Hair-follicle, the Hair, and the Sebaceous Gland.

In each hair-follicle we distinguish the mouth, the neck, the main portion or the body, and finally the bulbous extremity. The mouth is a funnel-shaped opening on the free surface, and the neck lies in the level of the papillary layer of the corium.

The direction of the hair-follicle, and of course also of the hair occupying its axis, in the skin, is always an oblique one, the distal or bulbous extremity forming in most cases a straight line with the rest, but sometimes, as in the case of the hairs of the lips of the mouth, it is slightly curved. According to Stewart this is the normal state with the hairs of the scalp of the negro.

The distal extremities of the well-developed hair-follicles extend into the septa of the adipose tissue; they extend therefore much deeper into the subcutaneous tissue than the sweat-glands, whose coiled tube, as mentioned previously, reaches no farther than the superficial section of the subcutaneous tissue.

The hair-follicles in the scalp are situated in groups of three or four, and the individual hair-follicles of these groups are of various thicknesses.

The size and especially the length of the hair-follicles vary greatly in the different localities.

Each hair-follicle consists of the vascular *hair-sac*, the *papilla* and the *outer root sheath.*

The hair-sac is composed of an outer longitudinal and an inner transverse coat. It appears as if it were part of the surrounding tissue of the corium, with which it is intimately connected, but it must be regarded as altogether an organ independent of this latter. It is in reality a continuation of the papillary layer of the corium, which it resembles in being supplied with a network of capillaries and, as will be pointed out below, from which it developes in the fœtus; it is continuous with the connective tissue of the septa which penetrate between the lobules of the adipose tissue.

The bundles of the outer coat are longitudinally arranged, while those of the inner are more oblique or transverse. In many places only the outer or longitudinal coat is distinct; in some, however, especially near the distal extremity or the bulb, a rudiment of transverse thin bundles can also be made out. On the inner surface of the transverse coat may be seen a continuous layer of relatively short and broad unstriped

muscle cells, each with a relatively long staff-shaped nucleus. The muscle cells are situated transversely to the long axis of the hair, and are best seen in the distal third or fourth of the hair-follicle, that is to say in the bulbous part.

At the rounded extremity of the hair-follicle the tissue of the hair-sac, exclusive of the muscular layer, is pushed in as the club-shaped, pear-shaped, or spherical papilla into the similarly shaped excavation of the bulbous extremity of the hair. The tissue of the papilla is composed of a hyaline matrix in which few thin fibrous bundles and numerous branched connective-tissue cells may be met with besides capillary blood-vessels and nerve fibres.

The hair-sac, inclusive of the papilla, is separated from the next following or inner stratum of the hair-follicle by a glassy hyaline basement membrane; this is thin near the mouth of the hair-follicle, increases in thickness towards the distal part, and reaches its greatest thickness near the bulbous extremity; it becomes again thinner as it approaches the papilla, and over this it is only a very delicate membrane.

This glassy membrane of the hair-follicle is a direct continuation of the basement membrane of the corium, and like this is derived from the deep portion of the epithelial cells next to it: in the case of the basement membrane of the corium, the deep layer of the stratum Malpighii; in that of the hair-follicle, the outer layer of the outer root-sheath. As will be pointed out presently, this is a direct continuation of the epidermis of the surface, and so may be regarded as the epithelium of the hair-follicle.

At the mouth and neck of the hair-follicle the outer root-sheath is identical with the epidermis, and therefore includes all its layers (v. Ebner), viz. the stratum corneum, the stratum lucidum, the stratum granulosum, which is specially well marked here, and the stratum Malpighii; in the rest of the hair-follicle the outer root-sheath is represented by cell-layers identical with the stratum Malpighii only. Consequently, like this latter, it consists of a marginal layer of columnar cells, each with an oblong nucleus, and several layers of polyhedral cells, each with a spherical nucleus. Nearest the central axis of the hair-follicle, that is towards the hair itself, the cells are much flattened and possessed of flattened oval nuclei. In some cases the cells of the marginal and middle layer of the external root-sheath are prickle cells, like those of the stratum Malpighii. The outer root-sheath varies in thickness in different parts of the hair-follicle; it reaches its greatest thickness about the middle portion of the follicle. Near the extremity it becomes suddenly reduced to a single layer of flattened cells, and then passes over the papilla, the cells, however, changing from flattened into columnar ones. Over the papilla they merge insensibly into the mass of polyhedral cells forming the hair-bulb itself.

Just as we mentioned of the stratum Malpighii and the sweat-glands, so also in the

external root-sheath and its continuation over the papilla, we meet with branched connective-tissue cells, in their respective lymph-canalicular system, penetrating from the hair-sac, or the tissue of the papilla respectively, between the cells of the outer root sheath ; here their processes are lost in the interstitial or cement-substance.

This relation is very distinct in the fœtal as well as in the adult hair-follicles. In the fœtal skin of many mammals these interstitial branched cells of the outer root-sheath are pigmented.

In sections showing the outer root-sheath, or portions of it, in a bird's-eye view, the richness of these intraepithelial branched cells is very marked. In those parts where the glassy membrane separating the external root-sheath from the hair-sac is very well developed and thick, the branched lymph-canalicular system containing these branched cells and extending from the connective-tissue of the hair-sac through the glassy membrane into the interstitial substance, i.e. between the cells of the outer root-sheath, is easily followed.

Each hair is divided into the *root* embedded in the hair-follicle, the *shaft*, freely projecting over the surface of the skin, and terminating in an attenuated free extremity, and the *bulb* or the thickened distal extremity, inflected over and fixed on the papilla. The root of the hair consists of the *substance of the hair*, the *cuticle*, and the hair sheath, or the *inner root sheath.*

The substance of the hair is composed of very long filamentous, spindle-shaped, or narrow and long flat horny scales, which, when treated with caustic alkalies or strong acids, can be isolated from one another. They are then seen to contain a linear remnant of a nucleus. The hair scales are arranged in groups, which in a transverse section through the hair appear as small polyhedral zones; in strongly pigmented hairs the outlines of these zones are unpigmented. Between the hair scales are found the finest air bubbles, as in white hairs, or rows of minute pigment granules, generally absent in white hair, but present in various quantities and shades of colour in coloured hair.

These pigment granules, when not abundant, are not contained in the hair scales themselves, but in the interstitial substance separating them, as is more easily ascertained at the bulb. Besides these pigment granules there is diffuse pigment contained in the hair scales. But it is chiefly the granules situated in the hair substance which determine the colour of the hair (Pincus, Boccardi). The different coloration in one and the same grey hair is due to the pigment granules being present in smaller numbers in some places than in others (Pincus). The hair becomes grey if the pigment situated between the cells of the bulb is not reproduced, as it then becomes gradually exhausted (Boccardi and Arena).

In many instances the central part of the hair proper is occupied, not by the elongated filamentous hair-scales, but by one, or two, or three rows of small polyhedral or cubical cells, each with a spherical nucleus. Their nature and shape can be easily ascertained by treating the hair with strong alkalies or strong acids. This is the *marrow* of the hair. Its cells are in the natural state filled with minute air-globules, hence appear black in transmitted light. After hardening the skin, the marrow can be distinguished in transverse section through the hair as a more transparent central portion without any pigment granules.

The surface of the hair is covered with the cuticle; this is a single layer of minute horny scales without any nucleus, slightly elongated, and arranged transversely over the substance of the hair. They are slightly imbricated with their margins, and hence, when the cuticle is seen in profile, form a toothed or zigzag line like the teeth of a saw.

Next to the cuticle of the hair lies the inner root-sheath. This is composed of three different layers: a *cuticle*, an inner or *Huxley's layer*, and an outer or *Henle's layer*. The cuticle presents itself as a very delicate film, and is distinct only when the hair is treated with strong alkalies or acids; it appears then as an almost homogeneous membrane, composed of scales imbricated with their margins and without nuclei. The inner, or Huxley's layer, is a single or occasionally double layer of cubical or oblong homogeneous cells, each with a small remnant of a nucleus; this is not, however, always distinct, especially not in the hair of some animals (pig, dog). The outer, or Henle's layer, on the other hand, consists of small, polyhedral, glassy-looking cells, ordinarily without a nucleus; in some animals (pig) they show, however, a staff-shaped nucleus.

In sections through hardened specimens showing the root of the hair in longitudinal view, the above three layers of the inner root-sheath appear as one thick glassy membrane on each side of the cuticle of the hair, and in it there is but a faint indication of a division into its three layers.

The inner root-sheath lies close to the hair proper and reaches to near the neck of the follicle, where it terminates abruptly. Between the inner and outer root-sheath there is a delicate membrane to be noticed in some hairs, but this is probably only the most superficial layer of the flattened scales of the outer root-sheath.

The shaft is identical in structure with the root, except that it does not possess a root-sheath and that its substance is harder and dryer.

Both the root of the hair and the inner root-sheath form one organ and pass into, or rather develop from, the mass of cells forming the hair bulb. This is a mass of polyhedral cells covering the papilla, each with a spherical nucleus; those immediately

over the papilla are more or less columnar, and represent, as mentioned above, a direct continuation of the marginal layer of cells of the outer root-sheath.

How are the cells constituting the bulb continuous with, or, in other words, how are they transformed into the different parts of the hair and inner root-sheath?

a) At the bulb the polyhedral cells immediately around the papilla in the direction of the axis of the hair pass into, at first slightly then more distinctly, elongated and spindle-shaped cells, whose nuclei elongate in proportion as the cells become drawn out; from these we gradually pass to the very long cells with staff-shaped nuclei that form the substance of the hair-root. Where there is a marrow, the polyhedral cells of this latter form an uninterrupted continuity with similar cells in the centre over the papilla.

b) The polyhedral cells next to the axial cells forming the hair-substance pass, in a single layer, into the cuticle of the hair.

c) The next outer layer of polyhedral cells of the bulb is continuous with the membrane separating the cuticle of the hair from Huxley's layer.

d) The one or two layers of cells following next pass into the layer of Huxley; and finally

e) The outermost layer or two into the layer of Henle.

In all these different layers, as we pass from the bulb on to the root of the hair, we see the small protoplasmic polyhedral cells of the bulb becoming gradually flattened and transformed into horny scales; their nucleus loses its spherical shape, becomes more staff-shaped, and ultimately altogether disappears, except in the cells of Huxley's layer as mentioned above.

Both in the fœtal, young, and adult hair, but more easily in the former, a special layer of cells (*f*), beginning at the bulb end of the root and extending on the lower third of this latter, can be distinguished between the above layers *b* and *c*, that is, between the cuticle of the hair and that of the inner root-sheath. This layer, *f*, consists of spindle-shaped cells each with a relatively long staff-shaped nucleus; the cells and their nuclei are placed transversely across the long axis of the hair, and resemble in all respects unstriped muscle cells just like those of the inner coat of the hair-sac. When focussing on this part of the root of the hair, when this has been cut in a longitudinal direction, the above layer of transversely arranged cells appears around the hair exactly like the transverse muscle cells in a small artery. They stain differently from the other cells of the root, and are conspicuous amongst them; they diminish in size as we ascend the root, and finally disappear altogether. They are not continuous with either the cuticle of the hair or any part of the inner root-sheath.

The bulb contains a quantity of pigment granules varying in amount and shade of

colour according to the colour of the hair; but this pigment is present only in the part around the papilla, that is in the part which is continuous with the substance of the hair. When not very abundant, these pigment granules are contained in the branched cells of the interstitial substance only, as stated above, and by them the epithelial cells of the bulb are finely mapped out. When very abundant, however, they also appear contained in the substance of the epithelial cells themselves.

Passing from the bulb on to the hair root, the cells, as we have seen, become elongated, and the configuration of their interstitial substance changes accordingly, and consequently the arrangement of the pigment becomes of an elongated nature, always remaining between the cells of the hair substance, as mentioned on a former page.

The hair-follicles and hairs of animals are in most respects identical in structure with those of man, the pigment in the interstitial substance of the cells constituting the hair substance and its bulb being in coloured hairs very great. The tactile hairs in the snout, eyelids, face, fingers, &c., of many mammals are distinguished from the ordinary hairs by the presence of an erectile tissue, viz. blood-sinuses surrounded by unstriped muscle tissue, chiefly around the neck of the hair-follicle.

The Sebaceous Gland.

Each hair-follicle is connected with one or two sebaceous glands opening into the neck of the former. The epithelium of the outer root-sheath, and the homogeneous basement membrane outside it, are connected with the epithelium and membrana propria respectively of the duct, passing sideways in an oblique direction into the corium, but always remaining more or less close to the hair-follicle.

In the large sebaceous glands the duct after a short distance branches into three or more short smaller ducts, each of which passes into a single or double, longer or shorter flask-shaped or saccular, pear-shaped or tubular alveolus, with a cæcal extremity.

The alveoli, as a rule, never reach so deep as the coiled tube of sweat-glands, being situated in the middle portion of the corium.

The ducts are lined with stratified epithelium similar to the outer root-sheath; but it, viz. the epithelium, is reduced to one or two layers of small cells, while the lumen is filled with remnants of the altered gland cells constituting the elements of the sebum.

In the alveoli we find a marginal layer of small polyhedral granular-looking epithelial cells, each with a spherical nucleus; these cells are continuous with the marginal layer of cells of the duct, while the rest of each alveolus is occupied by polyhedral cells, whose intracellular network is filled with fat globules; when these are dissolved

away by reagents the above network becomes very conspicuous. The cells increase in size from the marginal layer towards the centre of the alveolus.

The marginal layer of cells by division produces new cells; these are gradually pushed on towards the centre of the alveolus, the spaces of the intracellular network becoming at the same time distended by, and filled with, fat globules, and hence the cells gradually become larger. The nucleus is spherical, single, and situated about the middle of the cell.

Ultimately the cells are shifted into the duct; here they do not possess any nucleus, and having altogether lost their regular shape and outline, shrink and collapse into amorphous remnants, their fatty contents having previously become free.

The sebaceous glands vary greatly in size in different localities; they are generally larger where the hair-follicles are larger. In the fœtus and young child the sebaceous gland and its duct are comparatively much larger than the hair-follicle, and hence the appearance is produced as if the hair were situated in, that is, as if it were part of the duct of the sebaceous gland.

As a rule, the duct of the sebaceous gland opens into the neck of the hair-follicle, but in certain localities, as in the labia pudendi majora, scrotum, nostrils, we also find some sebaceous glands opening with their duct free on the surface of the epidermis; in these cases the sebaceous glands are of a very large size. This is the case also with the large sebaceous glands, or Tyson's glands, on the prepuce and the corona of the glans penis. There are no sebaceous glands on the volar side of the hand and the foot, the dorsal side of the last phalanx of the digits, and the glans penis. Sebaceous glands of a very large size, both as regards the number and length of the ducts and alveoli, are met with in the skin of the sheep.

The Muscle of the Hair.

The arrector pili is composed of unstriped muscle cells; in the hair of the adult human skin, especially in the scalp, the muscle attains a very great thickness, being composed of several bundles separated from one another by the connective tissue of the corium; but these bundles are always connected with one another so as to form a plexus. The muscle begins at the hair-sac, a short distance above the bulbous portion of the hair-follicle.

The muscle cells can be traced very closely to the glassy limiting membrane between the hair-sac and the outer root sheath, and they are continuous with the transverse muscle cells belonging to the inner coat of the hair-sac. The muscle ascends in an oblique direction through the corium towards the surface of this latter, generally

so as to form a sharp angle with the hair axis; it grasps the bottom of the sebaceous gland like a sling (Hesse), and when arrived at the surface of the corium its bundles branch and anastomose so as to form a plexus more or less horizontally placed. The bundles, after a shorter or longer course, lose themselves in the connective tissue of the papillary layer of the corium. The arrector pili of dog's hairs includes very many elastic fibrils (Stirling).

At the point of insertion of the arrector pili into the hair-sac we often see the outer root sheath forming one or two smaller or larger projections. Similar but more finger-shaped and more numerous projections are found in those hairs, both of children and adults, that are to be shed.

These projections indicate probably an active growth of the cells of the outer root sheath, and are due to the permanent irritation caused by the (pulling) action of the arrector pili.

In the hair-follicles in which the old hair is to be replaced by a new one, we commonly see one or two, or even three, such projections of the outer root sheath, each transformed into a cyst; this contains a large transparent cavity, and its wall is made up of several cell layers, which by a solid thinner or thicker neck are connected with the cells of the outer root sheath. Derby and Gay found such cystic outgrowths under pathological conditions, but Esoff has shown that they are of normal occurrence in the hairs that are to be shed.

The corium of the scrotum, nipple of the breast, labia pudendi majora, penis, contains independent bundles of unstriped muscle cells; these bundles are of various thicknesses and run in an oblique or horizontal direction in all layers of the skin, but are always connected into plexuses, as has been long ago pointed out by Kölliker, to whose observations we owe most of our knowledge of the muscles present in the skin of man.

Striped muscle fibres in bundles enter the skin of the face from outside and terminate in the papillary layer of the corium.

Growth, development and new formation of the hair and hair-follicle.

The hair grows at the bulb, owing to the multiplication of its protoplasmic cells, chiefly those immediately surrounding the papilla.

The oldest cells, viz. those furthest from the papillæ, become gradually elongated, and are then to be regarded already as part of the substance of the hair. The layer of cells containing the elements of the cuticle of the hair keeps pace with the substance of the hair. But the cells forming the inner root sheath do not grow at the same rate, being very much slower; this latter keeps the same pace as the external root sheath of the hair-follicle.

The rudiments of the first hairs appear in the human fœtus about the end of the third month, and, just as in mammals, are at first solid knoblike outgrowths of the stratum Malpighii into the corium (Remak, Kölliker), especially of the deepest layer of columnar cells. In some instances the corium shows a slight elevation preceding the formation of the rudiment of the hair (Reissner, Götte); but this is absent in many instances (Feiertag).

The rudiment of the hair rapidly elongating becomes cylindrical, and we notice in it the following different elements: the majority of the cells are small and polyhedral, in the marginal layer they are hexagonal or slightly columnar; the former possess a spherical, the latter an oval nucleus; the cells and their nuclei in the axial portion of the hair-rudiment are slightly flattened. There is a distinct limiting membrane between the marginal layer of cells and the surrounding tissue; this membrane represents the rudiment of the glassy basement membrane. Each of the hair-rudiments is from the earliest time surrounded by a thick layer of a tissue altogether different from the rest of the corium and representing the rudiment of the hair-sac; it is well marked off from the corium, is composed of a network of flattened, spindle-shaped or branched cells, and stains as a whole better than the rest of the corium; although relatively very bulky, it nevertheless can be traced directly to a thin layer similarly constituted and situated immediately underneath the epithelium of the surface, that is to say, a layer which gives origin to the papillary body of the corium.

On a previous page we have pointed out that a definite distinction must be drawn between the hair-sac and the surrounding corium, and we see this is borne out by the development. The branched cells of the rudiment of the hair-sac soon make their way into the above solid cylindrical hair-rudiment, and thus give origin to the branched nucleated cells that we described as present in the adult state between the cells of the outer root sheath.

The tissue of the hair-sac grows much more rapidly than the hair-rudiment, and having closed round the deep extremity of the latter, grows now against it as the papilla, and thus produces the inflection and enlargement of the bulb. Henceforth the multiplication of the cells at the bulb naturally leads to the new offsprings being pushed up in the axis of the hair-rudiment towards the surface, and becoming elongated constitute the elements of the hair-substance, its cuticle and inner root sheath; the cells of the primary solid cylinder represent the rudiment of the cells of the outer root sheath only. The gradual conversion of the cells of the bulb into the spindle-shaped horny scales of the substance of the hair, the differentiation at the bulb of the cell-layers, and their conversion into the cuticle of the hair and the inner root sheath are easily understood from the description given above of these parts of the adult hair.

One of the latest parts to appear is the mouth of the hair-follicle. The hair itself and the inner root sheath, having reached the stratum corneum of the surface, for a short time continue to grow underneath it for a considerable distance in a horizontal or slightly oblique direction; ultimately, however, the stratum corneum is broken, and the mouth of the follicle having thus been established, the hair henceforth grows beyond the free surface, loosing the adhering parts of the inner root sheath from the neck outwards.

As soon as the rudiment of the papilla makes its appearance, the hair-follicle, then still a solid cylindrical mass of cells, pushes out, near its connection with the surface epithelium, a small knob composed of the same polyhedral cells as the hair-follicle; this knob gradually elongates, divides at its extremity, and its branches are converted into the alveoli of the sebaceous gland. The duct is therefore an outgrowth of the neck of the hair-follicle.

According to Löwe, the correctness of whose statements must be questioned, the marginal layer of epithelial cells lining the limiting membrana propria of the alveoli of the sebaceous gland is alone derived from the deepest layer of columnar cells of the epidermis, while the rest of the gland cells are offsprings of the stratum corneum.

The fully developed fœtal hair (lanugo) is very thin, its follicle and papilla do not reach into the subcutaneous tissue. It becomes replaced in many localities soon after birth by a much coarser hair, whose follicle and papilla pass down into the depth of the subcutaneous tissue. This new hair is produced from the outer root sheath of the primary hair-follicle (Kölliker), as will be presently described.

Every hair in the young child, as well as in the adult, sooner or later undergoes a peculiar change, which leads to the formation of Henle's hair knob, or the intercalated hair (Schalthaar) of Götte, or the bedhair (Beethaar) of Unna, differing in several important respects from the normal or perfect hair, as described on a former page, and called by Unna the papillary hair. The mode of change of the latter into the bedhair is the following: the cells of the bulb over the papilla cease to multiply, and consequently the hair and its inner root sheath stop growing; first the inner, then the outer root sheath atrophy; but the root of the hair remains connected with the papilla for some time by a thin streak of cells; ultimately also this disappears. This process of atrophy extends up to near the point where the arrector pili is attached to the hair-sac; here the external root sheath becomes conspicuously enlarged and the hair root terminates in it with Henle's 'hair knob,' being an enlarged broomlike extremity, which with its fibrous horny elements branches out amongst the adjacent cells of the outer root sheath. The inner root sheath is wanting just at the extremity, but is met with at a short distance higher up. The hair continues to grow at its knob at the expense of the adjacent

flattened cells of the outer root sheath, and in this condition, viz. as a bedhair, it may retain its position and existence for a considerable time. In many instances it is, however, eliminated spontaneously or by the growth of a new hair produced from the cells of its (viz. the bedhair's) outer root sheath.

As mentioned previously, this part of the external root sheath, viz. about the region of attachment of the arrector muscle, contains on its surface sometimes few, sometimes many, smaller or larger, knoblike or cylindrical solid projections of epithelial cells. Now, in some instances, one of these grows into the depth as a cylindrical solid cell-mass, either making for itself a new path, i.e. becoming provided with a new hair-sac, or advancing in the path of the former hair; this is the rudiment of the outer root sheath of the new hair. Its extremity becomes inflected over a new papilla, just as was the case in the fœtal process. The cells of this inflected part rapidly increase in numbers, and thus form the bulbous extremity, in connection with which the hair itself and its inner root sheath are formed in exactly the same manner as in the embryo. Now, the new hair, as it grows upwards in the axis of the new outer root sheath, either passes altogether at the side of its bedhair and ultimately reaches the surface, its follicle becoming provided with a new neck and mouth; or it makes its way into the follicle of the bedhair. In this case the hair knob being pressed by the pointed extremity of the new hair is gradually pushed upwards towards the free surface and finally is altogether ejected. Hair-follicles with two hairs, one an old hair-knob and the other a young newly formed papillary hair and growing from the depth, are to be explained in this manner.

Stieda exhaustively proved the degeneration of the old papilla and the formation of a new one; Feiertag, Schulin, and especially Unna by his elaborate and careful researches, fully established it.

Biesiadecki, v. Ebner and Remy, however, still adhere to the older doctrine (Langer), according to which the old papilla persists, and in connection with it the new hair is produced.

The Nails.

The nails are, like the hairs, peculiar transformations of the stratum Malpighii.

The *body* of the nail, except at the *free margin*, is fixed over the *nail-bed*, while its *root* is firmly held over the *nail-matrix*, that is, the posterior part of the nail-bed, and is inserted in a fold, the *nail groove*; this being at the same time the fold by which the posterior margin of the nail-matrix passes into the free skin. But throughout its whole extent, except at the free margin, the nail is in immediate and close contact with the nailbed. This latter is corium covered with the stratum Malpighii.

In a vertical section the *substance* of the nail appears composed of a great many

strata of horny homogeneous transparent scales, the *nail cells*, which when treated with certain reagents show each a staff-shaped, or a discoid, much flattened remnant of a nucleus. The number of these strata increases from behind forwards and from the lateral margin towards the middle line.

The stratum Malpighii of the nail-bed possesses exactly the same structure as that of other parts, with the difference that the stratum granulosum is absent in the region of the matrix, but is present, although only rudimentary, in the rest of the nail-bed (Hebra).

At the nail groove the stratum corneum and stratum lucidum of the free skin pass a short distance over the nail-root. A similar relation exists also between the lower surface of the nail-margin and the adjacent skin.

The corium of the whole nail-bed is very vascular; its deeper portion is firmly connected with the subjacent periosteum by stiff bands of connective tissue. Together with the stratum Malpighii it is placed into permanent and regular folds, which are leaflike in the posterior part, including the region of the lunula, but low ridges in the rest of the nail-bed. The nail possesses on its lower surface the corresponding linear indentations, deep in the posterior portion, shallow in the rest. On the above folds of the nail-bed longer or shorter papillæ may be met with.

Papillæ are absent in the corium of the lower part of the nail groove, and there are no glands here or in the nail-bed.

The rudiment of the nail appears in the human fœtus in the third month, the nail groove being the first part differentiated.

The stratum Malpighii of the fœtal nail-bed in its whole extent is covered with a stratum corneum as in the ordinary skin, and the nail is developed and continues to increase in thickness underneath it (stratum corneum) by a conversion of the superficial layers of the stratum Malpighii into horny scales. This conversion extends over the whole surface of the nail-bed (Kölliker).

By the end of the fifth month the front margin of the nail breaks through the stratum corneum, and by the seventh month the greater part of the nail has become clear of it. After birth the nail grows chiefly at its root by the continued conversion of the superficial layer of cells of the stratum Malpighii of the matrix into the nail-cells.

Unna does not admit the correctness of the doctrine put forward by Kölliker, viz. that after birth the stratum Malpighii of the nail-bed outside the matrix continues to participate in the formation of the nail-cells, but maintains that such is the case only in the region of the lunula. In this he is supported by Hebra; but, according to this doctrine, it is difficult to explain how the nail should be thicker in front of the lunula than in the region of the latter, if not by a conversion of the cells of the stratum Malpighii of that (viz. front) part of the nailbed.

The Blood-vessels.

Passing from the depth of the skin towards the surface, we find the blood-vessels arranged in the following systems (Tomsa) :

a) The vascular system of the adipose tissue ; each lobule is supplied with an arteriole which, near its entrance into the lobule, passes into the dense network of capillaries ; the meshes of this have a diameter of one, two or three fat-cells ; generally two venous vessels originate in the periphery of the lobule ; both artery and veins join their respective trunks in the interlobular connective-tissue septa. The capillaries of neighbouring lobules often anastomose with one another.

b) The vascular system of the sweat glands. The arterioles ascend from the depth and pass into a dense network of capillaries twining round the coils of the gland ; special veins originate from them. The duct, however, is supplied with an arteriole from the superficial arteries of the corium ; the capillaries of the duct form a network with elongated meshes, and are connected with the capillaries of the surface of the corium, as well as with those of the coiled tube.

c) The vascular system of the hair-follicles. There is a minute arteriole ascending into the papilla, and having formed a simple or compound loop of capillaries, it returns as a minute vein. The capillaries of the hair-sac run between the outer longitudinal and inner circular coat, and form a network with elongated meshes. Their afferent arteriole comes off from the large branches in the same level as those supplying the papillæ of the corium.

d) The same is also the case with the arteriole of the sebaceous follicle and the arrector pili ; the capillaries form a dense network surrounding the alveoli of the former, while in the latter the meshes of the capillary network are much elongated. The capillaries of the hair-sac, the sebaceous follicle, and the arrector pili are continuous with the capillary network of the papillary body, and the efferent veins of this latter are at the same time the efferent veins of the former.

e) Those arterial branches that ascend up to the surface give off, besides the arterioles for the sweat-duct, hair-sac, sebaceous gland, and arrector pili, as mentioned above, also the arterioles of the papillæ. Most of the papillæ receive a minute branchlet, which passes into a single or compound loop of relatively wide capillaries. The descending branch of this passes into a network of relatively large venous vessels, extending horizontally in the superficial layer of the corium. The efferent veins of this superficial network are narrow ; they pass in an oblique direction towards the depth, and on their way join the efferent veins of other deeper systems.

The corium of the nail-matrix contains a plexus of vessels with broad meshes ; in

the rest of the nail-bed it is much denser, and from it arise the vascular loops for the folds and ridges of the nail-bed mentioned above.

In the skin of the ear-lobes, nostrils, and lips, instead of the above superficial network of venous vessels there occur venous sinuses (Tomsa), into which on the one hand open the capillary blood-vessels coming from the papillæ, and from which on the other hand come off the efferent veins.

The direct communication of arteries with veins in the skin of various localities in man and mammals, e.g. in the tip of the nose, finger, ear-lobe, &c., as observed by Hoyer, has been mentioned in Chapter XIX. p. 143.

The Lymphatic System.

The following description is a summary of the results of a special research on the Lymphatic System of the skin and mucous membranes, which I undertook for the Medical Officer of the Local Government Board, in whose forthcoming Reports a full account of it with illustrations will be given. In that account I have referred in detail to the observations of Sappey, Teichmann, Neumann, and others.

The lymphatic vessels of the skin are very numerous. They may be divided into the following systems :

a) The lymphatics of the connective-tissue matrix. All layers of the corium and subcutaneous tissue contain plexuses of lymphatic vessels, whose wall is a single layer of elongated spindle-shaped or sinuous flattened endothelial plates ; these vessels vary in breadth from place to place, and many of them are possessed of valves and corresponding constrictions. The vessels of the superficial layer of the corium are on the whole larger than those of the next layers of the corium, and those of the deep sub-cutaneous tissue are largest. As regards the direction of the plexuses, most of them are more or less horizontal, that is, parallel to the surface of the skin ; but there are vessels passing in an oblique manner through several layers of the corium.

The plexuses in the different layers are denser in the corium than in the deep subcutaneous tissues.

From the plexus of the superficial layer of the corium ascend saccular or tubular vessels into the papillæ ; they either terminate here with a cæcal extremity before they have reached the middle of the height of the papilla, or they form a single or even a compound loop. This is especially the case where the papillæ are large and well developed, as in the skin of the finger and the scalp of man.

In all layers of the corium, including the papillæ, we find fine vessels which are connected on the one hand with the plexus of the corresponding layer and on the

other terminate freely either with a pointed extremity, running out into a longer or shorter fine canal, or with a cæcal extremity, as is the case in some papillæ. These vessels have no valves and correspond to true lymph capillaries.

Both the arterial and venous branches passing through the corium are either accompanied on one or both sides by a lymphatic vessel, or they are crossed obliquely by such a vessel, and then this latter appears to pass through the sheath of the blood-vessel.

The lamellated connective-tissue septa between the lobules of fat-cells contains a plexus of lymphatics especially dense in the skin of man; the vessels are finer and more numerous than immediately above or below.

What is the relation of the lymphatics to the interfascicular spaces, and to the stratum Malpighii of the epidermis ?

As has been described minutely in Chapter XXII., of the connective tissues in general, the lymphatic capillaries stand in an open communication, by true stomata, with the interfascicular spaces, which are the lymph rootlets.

This direct mode of connection is especially marked in those lymph vessels which terminate or run out freely in the tissue. Another or indirect mode is this: the interstitial semifluid cement-substance of the endothelial wall of the lymphatic vessel is continuous with the same substance of the interfascicular spaces, and formed as well as fluid matter may find its way from the latter into the cavity of the former.

In the same way the lymphatic rootlets or interfascicular spaces of the papillæ and the superficial parts of the corium, are connected intimately on the one hand with the interstitial substance of the stratum Malpighii, and on the other with the lymphatic vessels. This relation has been minutely considered in Chapter XXII. p. 175, and has been also referred to in this chapter, in the description of the relation of the stratum Malpighii to the papillary layer of the corium.

b) The adipose tissue is supplied with a great many lymphatics; these are: first the numerous lymphatic vessels which form plexuses in the interlobular connective-tissue septa, and secondly the intralobular lymphatics. The interlobular lymphatics are very much more numerous in the human skin than in that of animals. They take up everywhere fine clefts and sinuses which are traceable between each two fat-cells. These represent the intralobular or intercellular lymphatics. Each fat-cell appears over a greater or smaller part of its circumference surrounded by a lymph-sinus.

c) Between the coils of the sweat gland-tubes are lymph-clefts. They are bordered by the coiled tube on the one hand, and the intertubular connective tissue on the other, or they are contained within the latter. They are taken up by the lymphatic vessels of the surrounding connective tissue. Also along the duct lymph-clefts may be

traced for longer or shorter distances, and the duct appears in places in half or more of its circumference invaginated in these lymphatics.

d) The hair-sac contains lymph channels, which are in communication with the surrounding lymphatics. They form sinuses round the outer root-sheath, and penetrate into the interstitial cement-substance between its (viz. the outer root-sheath's) epithelial cells; this is a relation similar to that mentioned above in connection with the stratum Malpighii. A further connection exists between the interstitial substance of the outer root-sheath and a space separating this latter from the inner root-sheath, and a similar one between this latter and the hair itself.

e) The alveoli of the sebaceous glands are surrounded for a larger or smaller part of their circumference by lymphatic spaces and sinuses, connected both with lymphatic vessels and with the interfascicular lymph-spaces of the surrounding connective tissue.

Elongated lymph-clefts are also found between the parts of the bundles of the arrector pili, similar to those observed in other unstriped muscular tissue.

The collecting lymphatics of large or small cutaneous districts possess besides the lining endothelium an elastic intima, a circular muscular media, and a thin adventitia. In this latter are situated blood-vessels forming for the lymphatic a special system, composed of an artery, vein, and a network of capillaries (Biesiadecki). Dogiel quite recently demonstrated a similar network of blood capillaries on the large lymphatics underneath the skin of the ear-lobe and the hind extremity of the rat, and in the mesentery of the cat and dog.

The Nerves.

The nerve branches of the subcutaneous tissue contain chiefly non-medullated and only a few medullated nerve fibres. But the number of medullated nerves is greater in those localities where there are tactile corpuscles (hand, foot, glans penis).

In the superficial part of the corium they break up into a dense plexus—which may appropriately be called the stroma plexus—of fine non-medullated nerve fibres, extending horizontally, and in close neighbourhood of the superficial network of the blood-vessels; each of the nerve fibres is still possessed of its hyaline sheath of Schwann lined with nerve corpuscles.

These fibres give off immediately underneath the stratum Malpighii minute varicose elementary fibrils, forming a network, the subepithelial network. From it fibrils ascend into the stratum Malpighii (Langerhans, Padkopaeff, Eberth, Eimer, Mojsisovics, Palladino, and others) both above the summit of the papillæ and into the interpapillary processes; here they ascend vertically towards the stratum lucidum. Their course is more or less wavy but they remain always *between* the epithelial cells, and when

arrived close to the stratum lucidum are said to terminate with a minute swelling, either without previously branching or after doing so, and after running for a short distance in a horizontal direction: according to Eberth, in the skin in general, Eimer and Mojsisovics for the snout of the mole, Palladino for the lips of the horse. The branched corpuscles in the stratum Malpighii, stated by Langerhans to be terminal organs of the nerve fibres, have not this character (Eberth, Eimer, Palladino), but, as we mentioned on former occasions, belong to the lymph-canalicular system of the stratum Malpighii.

In some localities (such as the hand, foot, penis, &c.), medullated nerve fibres come off from the nerve branches of the subcutaneous tissue, and terminate each in a Pacinian corpuscle. These generally occur in small groups and are situated either in the same layer as the coiled tube of the sweat glands, or deeper among the adipose tissue. Their structure in no way differs from that described of these organs in general in Chapter XVIII. p. 127.

Besides these endings, medullated nerve fibres may also be traced into the papillæ containing a tactile or Meissner's corpuscle, as in the skin of the hand, foot and glans penis, and the lips of the mouth of man and the anthropoid apes.

They are situated in papillæ with or without capillary blood-vessels, more often in those that are nearer to the sweat gland duct than in those farther away (Stewart). They are single, or occasionally but rarely double (Thin).

Each tactile corpuscle is an oblong, oval, or curved body, enclosed in a dense connective-tissue capsule, and including according to its size a larger or smaller number of nucleated transparent cells flattened against one another and placed transversely to the long diameter of the corpuscle. A medullated nerve fibre enclosed in a thick perineural or Henle's sheath (see Chapter XVIII.) approaches the corpuscle, the sheath of the former passes into that of the later, while the medullated nerve fibre enters the corpuscle, and, ascending towards its apex, entwines it twice to thrice. Its mode of termination is not definitely ascertained.

Langerhans describes special minute budlike structures situated amongst the above nucleated cells which he considers as the termination of the nerve fibre. But according to Merkel, the tactile corpuscle is merely an aggregation of 'touch-cells' (see p. 130); he describes also in other parts of the human skin, especially in that of the snout of the pig, and in the small tactile hairs of the snout of the pig (Dietl), single and compound Merkel's end bulbs. (See pp. 130, 131.)

The hair follicle is supplied with fine nerves, which have been specially investigated by Schöbel, Burkart, Palladino, and especially Jobert and Bonnet. According to Jobert fine medullated nerve fibres, having run in a circular direction in the outer coat of the hair-sac, change into a longitudinal direction and become at the same time

non-medullated. As such they either terminate here or penetrate to the glassy membrane along which they may be followed for some distance; ultimately this is perforated and the nerve fibres penetrate to the cells of the outer root-sheath. The hair-follicle of the tactile hairs possesses a greater supply of nerve fibres than that of the ordinary hairs.

According to Bonnet, all hairs, both those with an erectile body, viz. the tactile hairs proper, as well as those without one, viz. the ordinary hairs, possess special nerve-endings. In the ordinary hairs these consist of medullated nerve fibres which in the region of the sebaceous gland form circular tours in the hair-sac, close to the glassy membrane. They pass into fine non-medullated fibres, whose real termination could not be ascertained.

In the tactile hairs the medullated nerves entering the hair-sac are very numerous, and form superficial and deep plexuses in the outer and inner coat respectively of the hair-sac. They perforate the glassy membrane, terminate in peculiar end-bulbs on the inner surface of this latter and also between the columnar cells of the outer root-sheath.

In the rat and mouse there exists a special plexus of medullated nerve fibres around the neck of the follicle of the tactile hairs, the nerve-ring of Schöbel.

According to Arnstein, several medullated nerve fibres ascend along the hair-sac, and when arrived at the neck of the hair-follicle of the skin of the back and of the ear of the mouse, pass into non-medullated fibres which branch into several minute fibrils, perforating at the same time the hair-sac; these fibrils either terminate freely on the glassy membrane or they penetrate between the cells of the external root-sheath, where they terminate as an intra-epithelial network. A similar terminal network of fine fibrils, the intra-acinous network, is described by Arnstein, between the epithelial cells of the alveoli of the sebaceous gland.

CHAPTER XXXIV.

THE EYELIDS, THE CONJUNCTIVA, AND THE LACHRYMAL GLANDS.

The skin of the eyelids does not differ in structure in any material respect from that of other delicate parts of the general integument. The corium is very thin, the papillæ very small, and the subcutaneous tissue exceedingly loose and containing very numerous and wide lymphatics.

A few groups of fat-cells extend from the attached margin into the corium of the lid.

The very fine hairs do not reach very deep, and they are possessed of small sebaceous glands; the sweat glands are also relatively small, but do not differ from those of other parts of the skin.

Large cells with pigment granules are to be met with in the connective tissue (Waldeyer).

At the anterior edge of the free margin of the lid, the epidermis possesses the same character as on the outer skin, but the papillæ become longer and the hairs are represented by the thick and long cilia which in all respects, including their sebaceous glands, resemble the well-formed thick hairs of other parts.

They are remarkable chiefly for their rapid change and new formation (Donders).

Immediately behind the cilia we meet with the ducts of the glands of Moll, which often, but not by any means always, open into the ducts of the sebaceous glands. Each of the former penetrates in a wavy or vertical direction into the depth of the lid and passes into the slightly coiled tube of the gland proper.

The structure of the duct and gland tube is precisely the same as that of a large sweat gland. Also the distinction between the proximal and distal portion of the gland tube pointed out in the previous chapter is to be noticed here. A longitudinal layer of unstriped muscle cells is also here interposed between the membrana propria and the layer of transparent columnar epithelial cells lining the lumen of the tube (Sattler). The difference between this gland and an ordinary sweat gland is merely this, that the tube of the former is not so much coiled and that it reaches to a greater depth than the latter.

Approaching the posterior edge of the free margin, but before reaching it, we meet with the mouths of the Meibomian glands. These are closely placed side by side in a single row, and each of them possesses a straight duct which is embedded in the tarsal plate, in the direction of the short diameter of this latter and parallel with the conjunctival surface of the lid. It takes up on all sides of its circumference shorter or longer saccular, flask-shaped, or pear-shaped single or branched alveoli.

But the whole gland does not extend into the distal portion of the tarsal plate (see below).

As regards structure the duct and alveoli completely resemble a sebaceous gland, as described in the preceding chapter. The stratified epithelium of the duct is identical with the stratum Malpighii of the surface, i.e. the lid margin; the marginal layer of small polyhedral cells, each with a spherical or slightly flattened nucleus, the central large polyhedral cells filled with fat globules and each containing a spherical nucleus, the remnants of these cells in the narrow neck of the alveoli opening into the duct, all these relations are the same in the alveoli of the Meibomian gland and in those of an ordinary sebaceous gland. When prepared with spirit and oil of cloves the intracellular honeycombed reticulum of the gland cells of the alveoli, whose meshes contain the above fat globules, is brought out in both cases with great distinctness.

According to most observers the alveoli possess a membrana propria, but Waldeyer questions this; Colosanti describes also unstriped muscle cells forming as it were a capsule round the alveoli.

As the posterior edge of the lid margin is reached the stratum Malpighii becomes thickened and also the papillæ undergo a corresponding lengthening. Passing this edge we arrive at the conjunctiva palpebræ, a delicate vascular mucous membrane covered with a thin stratified epithelium, which, although modified in its constitution, is nevertheless a continuation of the stratum Malpighii. In most places we find it consisting of one or two layers of small polyhedral cells, on the top of which is a layer of longer or shorter columnar or conical cells (Klein, Waldeyer, Reich). Some of them are often found as mucous-secreting goblet cells (Stieda, Waldeyer).

On the distal portion of the conjunctiva palpebræ, i.e. next the fornix conjunctivæ, the mucous membrane with its covering epithelium is placed into regular folds anastomosing with one another, hence in a vertical section through this part there appear small depressions of the surface which look like glandular inflections (Henle), but in reality are merely the furrows between those folds (Stieda, Waldeyer). The epithelium covering these folds differs from that covering the proximal part of the conjunctiva palpebræ, i.e. the one next the lid margin, inasmuch as in the former its superficial layer is composed of beautiful columnar cells (Waldeyer).

In this region of the conjunctiva palpebræ we meet with the ducts of minute mucous glands, sunk into, and embedded in the tarsal plate, that is in its distal portion into which the Meibomian glands do not penetrate, as mentioned above. Each duct divides into two or three small branches and then passes into branched and convoluted tubular structures, of exactly the same nature and appearance as the alveoli of mucous glands, described on former occasions. The chief and secondary ducts are lined with a single layer of columnar epithelial cells, while the alveoli possess a layer of thin columnar mucous cells.

These glands form the first section of the group of glands, identical in structure and nature, of which the greater number is situated in the beginning of the conjunctiva fornicis, i.e. next the tarsal plate. They were first discovered by Krause, and, according to this observer and myself and Schmidt, are much more numerous in the upper than in the lower eyelid. Those of the tarsal plate have been described and figured by myself, and afterwards by Wolfring.

The mucosa of the conjunctiva palpebræ is a thin connective-tissue membrane, which in the adult human subject contains a variable amount of diffuse adenoid tissue. This is generally better developed in the distal than in the proximal part.

The mucosa is firmly fixed on the tarsal plate; this is a very dense feltwork of bundles of fibrous-connective tissue without any cartilage, and its anterior and posterior surface is intimately connected by connective-tissue bundles both with the skin section of the lid, and with the conjunctiva palpebræ.

At the free margin of the lid the dense tissue of the tarsal plate reaches up to the epithelium, while at the opposite margin it is connected with the bundles of unstriped muscular cells representing the muscular band of Müller.

The central part of the eyelids, viz. that between the subcutaneous tissue of the outer skin and the tarsal plate, is occupied by the bundles of the striated fibres of the sphincter orbicularis. They are separated by a loose connective tissue, containing occasionally also groups of fat cells. A comparatively thick layer of muscle fibres is pushed in between the mouths of the Meibomian glands and the cilia, and this is the musculus ciliaris Riolani, of which a minute portion extends beyond the mouths of the Meibomian glands close to the epithelium of the posterior edge of the free margin of the lid.

In the fœtus the epithelium covering the margin of the lids forms, by coalescence, for both lids, one continuous mass (Schweigger-Seidel); from this epithelium the cilia and Meibomian glands originate, after the same plan as in the skin generally. The branched pigment cells between the deep layer of the epithelium and the cells of the outer root sheath of the fœtal cilia are very conspicuous.

The conjunctiva fornicis is an exceedingly delicate connective-tissue membrane covered with stratified epithelium of which the superficial layer is composed of more or less columnar cells.

The deep portion of the membrane is very loose and contains numerous elastic fibrils.

The epithelium of the conjunctiva bulbi is, like that of the fornix, stratified, but towards the cornea it assumes the character of stratified pavement epithelium.

The mucous membrane of the conjunctiva bulbi contains, in man and mammals, a great amount of diffuse adenoid tissue, and this can be in some instances traced close to the corneal margin. At the limbus the mucosa forms small papillæ.

Between its deep layer and the sclerotic, and the tendons of the eye muscles, there is an exchange of connective-tissue bundles.

The caruncula lacrymalis contains in its loose deep tissue fat-cells, fine hairs, sebaceous glands and sweat glands similar in nature to Moll's glands of the eyelids. There are also unstriped muscular fibres in its tissue. The surface is very uneven and except at the summit, where the epithelium is like the stratum Malpighii, it is composed of a superficial layer of columnar and one or two deep layers of small polyhedral cells. In the caruncula lacrymalis of two negroes Giacomini found, similar to what is the case in the ape, a minute cartilage, which possessed the structure of fibro-cartilage.

The distribution of the blood-vessels in the human eyelids has been specially and minutely investigated more recently by Fuchs and Langer.

The distribution of the blood-vessels of the skin of the eyelids, of the cilia, and glands of Moll is similar to that in the skin of other localities.

A rich superficial network of capillaries is present in the conjunctiva palpebræ, the limbus, and the caruncula lacrymalis.

In the conjunctiva palpebræ the superficial network is very close, and so is also that surrounding the alveoli of the Meibomian glands.

A rich plexus of vessels, chiefly veins, distinguishes the conjunctiva bulbi.

The lymphatics of the conjunctiva form, according to Schmid, a superficial and deep network, connected with one another by many short branches. The vessels of the superficial network are very fine, and some of them terminate with a pointed or cæcal extremity. The vessels of the deep plexus are possessed of valves. The superficial network is densest at the limbus corneæ; both in the conjunctiva bulbi and in the limbus the lymphatics stand in direct communication with the interfascicular lymph-clefts of the sclerotic and cornea respectively (Recklinghausen, Leber, Waldeyer).

I have found the superficial network of the conjunctiva pelpebræ exceedingly dense, and its vessels diminishing in size towards the lid margin.

The deep plexus lies close to the tarsal plate, a few vessels passing from the former through the latter join the lymphatics of the intermuscular connective tissue of the sphincter orbicularis. At the free margin of the lid the lymphatics of the conjunctiva palpebræ pass directly into those of the skin (Fuchs).

The sinuses around the alveoli of the Meibomian glands (Czerny) are in direct connection with lymphatic vessels (Fuchs).

The efficient lymphatics of all parts of the conjunctiva run towards the angles of the eyelids.

As mentioned above, the conjunctiva in the adult human eye contains in many instances diffuse adenoid tissue. According to Stieda, and especially Morano, real lymph follicles occur also occasionally in the human conjunctiva, but this is denied by Sattler and others.

In the case of many mammals definite groups of lymph follicles, like those of the tonsils, are a common occurrence about the inner eye angle (Kleinschmidt, Frey, Huguenin, Schmid and Waldeyer). Bruch saw them first in the conjunctiva of the lower eyelid of cattle, and they are here known as the glands of Bruch. In the third eyelid of the rabbit, sheep, cattle, these lymph follicles form a conspicuous part.

Frey and Huguenin traced lymph sinuses and clefts, situated between the follicles, into the lymphatic vessels of the conjunctiva. Also Waldeyer followed the lymphatic vessels in the lower eyelid of cattle up to the glands of Bruch.

THE NERVES.—The nerve branches are composed of medullated fibres. When arrived at near the surface they lose their medullary sheath, but retain their hyaline sheath of Schwann and the nerve corpuscles, and anastomose into a plexus, the sub-epithelial plexus of Arnold. From this very fine primitive fibrils are given off, which, having run a short distance underneath the epithelium, ascend between the cells of this latter, where most of them terminate in a network (Helfreich, Morano).

Krause showed the existence of small tactile corpuscles in some of the papillæ near the ciliæ; as in other places, they are also here connected with a medullated nerve fibre.

The termination in end-bulbs of Krause in the conjunctiva of man and calf has been mentioned in Chapter XVIII. p. 129. In the conjunctiva palpebræ medullated nerve fibres accompanying the blood-vessels are described by Colosanti; they lose their medullary sheath while perforating the membrana propria of the alveoli of the Meibomian glands, and terminate as a network of fine non-medullated nerve fibres between the gland cells.

The Lachrymal Glands.

These correspond in structure to the true salivary glands. A connective-tissue capsule is in connection with the septa by which the gland is divided into lobes and lobules.

The larger or interlobular ducts are lined with a layer of thin columnar cells; the intralobular branches, the lachrymal tubes of Boll, are lined with a layer of columnar cells, whose external portion, just like those of the corresponding parts in the salivary glands, appears very distinctly fibrillated; the inner portion, that is the one next the lumen, is only slightly striated. The nucleus is situated in about the middle of the cell.

Each branch of the intralobular ducts passes through an intermediate portion into the alveoli. The former is a long fine tube lined with a layer of flattened cell-plates, often imbricated with their margin (Boll). These cells are traceable into the interior of the alveoli as the centroacinar cells, similar to what has been observed by Langerhans in the pancreas. The alveoli are longer or shorter, tubular, more or less convoluted structures, possessed of lateral and terminal tubular or saccular branches.

The membrana propria is composed of homogeneous flat branched cells, from which membranous septa penetrate between the epithelial cells of the alveolus. These latter are a single layer of polyhedral, cubical, 'granular'-looking cells, each with a spherical nucleus, and in this respect they completely resemble the lining cells of the alveoli of the serous or true salivary glands.

The central fine lumen of the alveoli and its connection with the intercellular substance, or, what some observers call the intercellular capillary ducts, is the same as in other glands, and has been fully described in connection with the salivary glands; see Chapter XXIV. p. 190.

Reichel studied the state of the alveoli in rest and during secretion, and found that in the former condition the lining cells are well defined, conical or cylindrical, and composed of a transparent, slightly granular protoplasm, each possessed of an irregular nucleus situated in the outer third; while during secretion the cells are smaller and very opaque and granular, and their outlines not well defined, the nucleus being at the same time spherical and placed centrally.

The distribution of the blood-vessels is identical with that of the salivary glands.

The terminal distribution of the nerves is not known. The lymphatics form a plexus of valved vessels in the interlobular connective tissue; they take up large lymph sinuses surrounding the alveoli, which form a continuous system of spaces (Boll).

Harder's gland, occurring in most mammals on the inner angle of the eye, and

closely placed against the surface of the eyeball and the inner margin of the nictitating membrane, has been carefully studied by Wendt. It bears a definite relation to the lachrymal glands, being larger in those animals which possess only small lachrymal glands and *vice versâ*. Wendt finds that in the rodents, as mouse, rat, and guinea pig, it resembles a large compound sebaceous gland; in the ox, sheep, and pig it is, however, identical with the lachrymal gland, i.e. is a serous gland, while in the rabbit and hare it consists of two different sections, of which the upper smaller one appears white and resembles the sebaceous gland, while the other, viz. the lower one, is larger, and in the fresh state rose-coloured; its structure is the same as that of the lachrymal glands; its alveoli are lined with pyramidal cells, whose protoplasm shows a reticular nature. Injecting the alveolar cavities from the ducts, it is seen that the injection-matter penetrates into the interstitial cement-substance between the epithelial cells. Wendt does not admit that the membrana propria of the alveoli of the rose-coloured or serous portion of the adult gland is a basket-shaped network of flat branched nucleated cells as described by Boll and many others (see former chapters), but considers it a homogeneous non-nucleated membrane.

Giacomini found a rudiment of the Harder's gland also in the Cercopithecus, Cynocephalus, and man.

CHAPTER XXXV.

THE CORNEA AND SCLEROTIC.

THE cornea consists of the anterior epithelium, the anterior elastic or Bowman's membrane, the substantia propria, the posterior elastic membrane or membrana Descemeti, and the endothelium lining the posterior surface.

1) The anterior epithelium is a stratified pavement epithelium of a similar nature as that of other regions: viz. the deepest layer is composed of columnar cells, each with an oval nucleus; then follow two or three layers of polyhedral cells, each with a spherical nucleus, they and their nucleus become flattened towards the surface; finally there are two or three superficial layers of scales, each with a discoid nucleus, more or less oval in outline.

The cells of the deepest layer are of different heights, club-shaped, cylindrical, pear-shaped; the deep extremity by which they are fixed on the subjacent tissue is flattened and plate-like, the foot-plate of Lott and Rollett. But neither in this, nor in the fact that many of the polyhedral cells of the middle layers possess instead of smooth surfaces one, two, or three pitlike depressions to receive the convex surfaces of their neighbours (Kölliker, Cleland), does the epithelium of the cornea differ from other stratified epithelium. The cells both of the deepest and middle layers are in most instances prickle cells.

The nucleus of the deepest cells contains a delicate regular reticulum, without any nucleoli, that of the cells of the middle layers a less uniform reticulum and often one or more thickenings in it, nucleoli.

The very same changes of the intranuclear network that we described in Chapter XXXIII. leading to the division of some of the nuclei of the deepest cells are also here to be noticed, and have been observed in the normal and inflamed state by Mayzel and Eberth. They will be referred to in detail in a future chapter.

The division of the cells takes place chiefly in the deepest layer (Lott), and as in other places the next following layer of polyhedral cells owes to this its origin.

But that in this process of division some of the deepest cells divide into a nucleated polyhedral top-cell and a deep mass of protoplasm which at first is without any nucleus but in which afterwards a nucleus is formed *de novo*, as maintained by Lott, Krause and others, is most decidedly erroneous, and I fully agree with Flemming on this point, viz.

that the division of the cell is always subsequent to the division of the nucleus, and that this invariably takes place after the indirect manner described on former occasions. There is at no time a cell to be found in the deeper or other layers that does not possess a nucleus.

Amongst the epithelial cells of the middle strata are seen branched spaces in the interstitial cement-substance; the processes of these spaces lose themselves in the cement-substance. The spaces contain branched nucleated corpuscles which on the warm stage show distinct though slight amœboid movement. They have been noticed in the epithelium of the cornea of the frog and mammals (Ribbert, Raehlmann), and correspond to the similar spaces and cells described on former occasions as present in every epithelium and as representing the intraepithelial rootlets of the lymphatic system.

The lower surface of the epithelium is in most instances smooth and firmly fixed on the anterior elastic membrane, but occasionally, especially in the human cornea prepared with spirit, appears as if possessed of very minute teethlike spikes let into minute depressions of the elastica anterior (Henle, Langerhans).

The epithelium of the cornea is directly continuous with that of the conjunctiva, but differs from it in many respects; the former is conspicuously more transparent, and its layers more numerous. In dark eyes of animals (sheep, dog) the epithelium of the conjunctiva contains pigment, and this ceases suddenly at the margin of the cornea, not being continuous into the epithelium of this latter.

2) The elastica anterior or Bowman's membrane is a transparent homogeneous-looking membrane, distinct from the subjacent substantia propria and continuous with the basement membrane of the conjunctiva. It contains indications of bundles of minute fibrils, and is not continuous by bands of connective-tissue fibrils with the substantia propria, nor does it contain cellular elements (corneal corpuscles) as maintained by Waldeyer. The elastica anterior is best developed in the human cornea, less so in that of most mammals. In rabbit it is also distinct, but not in dog, in the latter case it is reduced to a very delicate layer.

Bowman's membrane is perforated by a few thin channels passing through it in an oblique manner (Engelmann), they are channels containing nerve branches, the rami perforantes (see below).

3) The substantia propria is composed of lamellæ of bundles of fibrillar connective tissue. The bundles amongst themselves and the fibrils within a bundle are united by the usual semi-fluid albuminous interstitial cement-substance, which is easily dissolved by a ten per cent. solution of common salt (Schweigger-Seidel). The bundles of these lamellæ run in a direction parallel to the surface of the cornea, but not

only groups of bundles of adjacent lamellæ, but also those belonging to the same lamella, cross under right angles. Neighbouring lamellæ anastomose with one another, owing to bundles passing between them; but in this respect there exist great differences in the different sections of the cornea, in the anterior section such bundles are much more numerous than in the posterior. Near the elastica anterior some of these bundles pass through several lamellæ in an oblique manner and represent the fibræ arcuatæ.

There are few isolated delicate elastic fibrils to be met with between the lamellæ (Henle), they are only seen from place to place.

The interstitial cement-substance is collected as a distinct layer between each two adjacent lamellæ. In each layer of this interlamellar substance lies one layer of lacunæ and their anastomosing canaliculi, first discovered by v. Recklinghausen and named by him the lymph-canalicular system. They do not possess any limiting membrane, although such an one has been ascribed to them by Leber, Lavdowsky, and others.

Their arrangement, shape, and differences in different animals have been fully considered in Chapters IV. and XXII. In most instances the lacunæ are flat, more or less oblong, and possessed of numerous canals of various thicknesses, most of them being branched and anastomosing with those of neighbouring lacunæ. In the cat they are in groups (Stricker), so that two or three or more lacunæ are in contact with one another and joined into larger cavities.

A similar grouping of lacunæ is generally found in the anterior sections of the young cornea.

The lacunæ of the anterior sections are generally larger and less branched than in the deeper parts of the cornea (His).

Each lacuna contains the nucleated plate of a cell, the corneal corpuscle. Each of these is possessed of processes extending into the above canaliculi, and by them the corneal corpuscles anastomose in a network. The lacunæ and canaliculi are not completely filled out with the branched corneal corpuscles, and there is enough room left for the circulation of plasma irrigating the tissue, and for the passage of migratory cells, and in many places also for the nerve fibrils (Recklinghausen, Stricker, Rollett, and others).

Most lacunæ and the corpuscles are flat in a direction parallel to the surface of the cornea, but in every preparation there are some found whose narrow side is looking towards the surface of the cornea. The lacunæ or corneal corpuscles respectively of neighbouring layers anastomose with one another (Rollett).

Each corneal corpuscle consists of a hyaline ground-plate, in which is embedded an oval nucleus. Around this nucleus is a 'granular'-looking protoplasm, which is in reality

a very dense reticulum of fibrils; this substance is continued into the processes (see Chapter IV.). As has been stated on p. 29, this distinction into a ground-plate and a 'granular'-branched part of the corneal corpuscle probably accounts for the opposing views of the nature of the corneal corpuscles: Hoyer and Schweigger-Seidel considering them merely as endotheloid plates without processes, these latter being artificial products; Stricker, Rollett, Waldeyer, and others, as more or less branched cells, while still others, Thanhoffer, Thin, Henle, assume altogether two types: one, the endotheloid cells and the other, the branched typical corneal corpuscles. The nucleus in most instances is limited by a distinct membrane and includes a delicate intranuclear reticulum, which under certain reagents shows one or two larger collections, nucleoli. But in the fresh state and under suitable circumstances it can be ascertained that the reticulum is uniform and is connected with the intracellular fibrils. We meet with many corneal corpuscles, whose nucleus does not possess any definite membrane, and whose intranuclear network is therefore not separated from the intracellular one, but owing to the much greater density of this latter (intracellular network) is nevertheless well marked off from it.

The corneal corpuscles are endowed with slight contractility, observed in the normal state, under the influence of thermal, electrical and mechanical influences (v. Recklinghausen, Kühne, Mayzel, Rollett, Waldeyer), and under inflammatory conditions (Stricker and Norris, Rollett and others).

In the normal state very few migratory cells can be detected in the lacunar system of the cornea, but under inflammatory conditions their number greatly increases (pus corpuscles), and they may be seen squeezing themselves through even the finest canaliculi. Owing to their moving in the lymph-canalicular system they then present themselves chiefly in elongated shapes.

4) The elastica posterior or the membrana Denemeti is a very strongly resistent elastic membrane. It is present in the cornea of all mammals as a very conspicuous structure. Although of a hyaline aspect it is nevertheless composed of bundles of very delicate fibrils (Tamamscheff, Schweigger-Seidel).

5) The posterior surface is covered with a single layer of polyhedral slightly flattened granular-looking endothelial cells, each with a single oval slightly flattened clear nucleus containing under some conditions a single or double nucleolus. Klebs, Stricker, and Norris attribute to these cells amœboid movement.

According to v. Ewetsky, each endothelial cell is composed of a superficial hyaline plate and a subjacent protoplasmic nucleated portion. Swaen maintains that the endothelium of the frog's cornea consists of two layers: a superficial layer of protoplasmic contractile, and a deep layer of hyaline non-contractile cells.

In some instances in the fresh state and after reagents, especially after hardening, the cells appear separated from one another by small globular spaces. Under abnormal conditions these increase in number and size, and the cells appear hereby changed into more or less branched corpuscles, connected by their processes.

As will be minutely described in a future chapter, Mayzel observed indirect division of the nuclei of these cells.

With the exception of the very margin there are no blood-vessels in the cornea. The fœtal cornea possesses a network of capillaries extending underneath the anterior epithelium over the whole surface of the cornea, as the precorneal, vascular network. But a short time after birth all vessels disappear, except those at the margin of the cornea, where they terminate in arcuate loops directed towards the centre of the cornea. These vessels carry a small amount of connective tissue from the conjunctiva into the cornea.

The Lymphatics.—There are no proper lymphatic vessels in the cornea. As has been mentioned on a former page, the lymphatics of the conjunctiva anastomose at the limbus with the interlamellary lacunar system of the margin of the cornea. A similar communication exists between the lacunar system and the perivascular lymphatics of the blood-vessels in the marginal portion of the cornea (v. Thanhoffer). The lacunar system is an intercommunicating system for the whole cornea. Injections into the lacunæ of the superficial layers of the cornea penetrate also into the interstitial substance of the deep epithelial cells of the anterior surface (Leber). All nerves from the larger branches to the finest fibrils of the substantia propria are contained in the interlamellar cement-substance, very often passing through the lacunar system and its canaliculi. The larger nerve branches are possessed of a perineural sheath which, just as in other places, is composed of a single layer of endothelial plates (v. Recklinghausen, Durante, Thanhoffer, Thin, see pp. 85 and 125), but this endothelial membrane cannot be said to represent the endothelial wall of a lymphatic vessel in the accepted sense.

The corneal tubes of Bowman, which present themselves in the cornea into whose tissue injection matter had been forced, are artificial products (Rollett), being shorter or longer spaces dug out in the interstitial cement-substance between the bundles of one and the same lamella, or long canals dug out between the lamellæ.

The Nerves of the cornea have been described on p. 125, but I wish here to make a few additional remarks concerning their termination, having lately had the opportunity of a renewed inquiry into this subject. The detailed account of this will be found in the 'Journal of Micr. Science,' October, 1880.

The nature and arrangement of the branches of the subepithelial plexus or stroma

plexus (Waldeyer) have been described and figured on a former occasion (see Plate XXIV.).

The fine nerve fibrils which form the subepithelial network are derived from the branches of the stroma-plexus in two different ways: either through the rami perforantes breaking up into bundles of minute fibrils, or directly from the stroma-plexus as single primitive fibrils or as small bundles of them. The former is the more common mode. In the latter instance, viz. when derived directly from the stroma-plexus, previously to entering the subepithelial network, they branch, and some of them running for a long distance within Bowman's membrane ultimately enter the subepithelial network, as mentioned before, while others do not enter Bowman's membrane, but remain in the superficial layers of the substantia propria, where, after branching, they terminate; these are the deep fibrils of Hoyer's subbasilar plexus. Similar fine nerve fibrils are met with in most parts of the substantia propria, but they are most numerous in the anterior layers. In the frog's cornea they are exceedingly abundant and compressed, as it were, into a relatively thin stratum, next the membrana Descemeti. Their very great length, their relatively few branches, and their peculiar straight course are very remarkable. In some places they seem to run in a straight line, without branching, and after a shorter or longer course they bend sharply into a direction at a right angle. In other places they, as well as their branches, run a wavy course, or they change their course under right angles in rapid succession. As has been mentioned above, the minute nerve fibrils, coming off from the subepithelial network, enter the epithelium and, having ascended into the middle and superficial layers, give off lateral branches; both, viz. the primary fibrils as well as their branchlets, pursue a longer or shorter horizontal course between the epithelial cells, but in a more or less wavy manner, and parallel with the surface, repeatedly changing their level. These fibrils give off a good many lateral branches, and anastomose with one another in but few places. What has not been observed before is this: whether the fibrils are next to the superficial layer of epithelial cells or not, they are possessed of exceedingly numerous very fine lateral branchlets, which in ordinary gold specimens are not marked at all, or only as minute rodlike prominences, sticking out at the side of the above fibrils; in perfect specimens, however, they are seen to be the commencement of exceedingly delicate fibrils, which branch dichotomously like the twigs of a tree and break up into a network of very short rods. This ultimate network lies between the epithelial cells and occurs in most layers, except the deepest and the most superficial layer.

Many of the intraepithelial nerve fibres, especially the finer and finest ones, are often seen to possess smaller or larger, spherical or angular, varicosities, just like the fibrils of the subepithelial network (see p. 125). That the intraepithelial nerve fibrils

seem to terminate with such a varicosity or end-knob has been asserted by Cohnheim, Tolotschinow, Lavdowsky, Krause and others; but they are not at all constant (Hoyer, Klein, Izquierdo), and, as I have shown just now, are not the real termination.

The fine nerve fibrils of the substantia propria enter into close relation with the lacunar system or the corneal corpuscles respectively, for every one of these fibrils running in the interlamellar cement-substance must of necessity pass through or by a lacuna and its canaliculi. And the fact of this relation may be, and probably is, the cause of the assertions of so many observers of a direct anatomical connection of these nerve fibrils with the corneal corpuscles (Kühne, Lippmann, Moseley, Lavdowsky, Thanhoffer, Izquierdo and others). In mammals they branch, and by these branches anastomose only in very few places; in the frog's cornea such anastomoses are oftener met with. It is very difficult to ascertain the real termination of the fine nerve fibrils. In ordinary preparations they seem to run out freely in the tissue, but in isolated instances of perfect gold specimens of the cornea of the rabbit and the kitten, as well as of the frog, I have ascertained that they terminate with an exceedingly delicate network of fine and short fibrils, situated not in, but on the surface of the corneal corpuscles.

The Sclerotic.

The sclerotic membrane is of a dense texture, similar in structure to that of the dura mater or a fascia. It consists of groups of bundles or trabeculæ of fibrillar connective tissue crossing each other in different directions, with a slight tendency to a lamellar arrangement. Between the groups of bundles are the interfascicular lymph-spaces containing the flattened branched connective-tissue cells, identical in shape with those of the cornea. This connective-tissue matrix passes into that of the cornea, the bundles becoming, however, more transparent. In most dark-eyed mammals we find near the point of transition the connective-tissue cells of the sclera containing brown pigment granules, but they are absent in the corneal tissue.

Near the ligamentum pectinatum the bundles of the sclerotic become more regularly arranged, being parallel with one another in a more or less annular direction.

Between the bundles of all parts we meet with networks of fine elastic fibrils; these are especially numerous near the ligamentum pectinatum.

On the inner surface of the sclerotic the trabeculæ arrange themselves in some places into thin lamellæ, and these pass in company with blood-vessels from the inner surface of the sclerotic to the outer surface of the chorioidea. The portion of this tissue next the inner surface of the sclerotic is known as the lamina fusca, that next the outer surface of the chorioidea as the suprachorioidal tissue. The connective-tissue corpuscles of these lamellæ are likewise flattened, and some are much less branched

than others, their processes being fewer, and shorter, and broader. (In dark eyes many of the cells contain yellowish or brownish pigment granules; see below.)

The lamellæ are covered with an endothelium, and are separated from one another by more or less continuous lymph-spaces (Schwalbe).

As regards the outer surface of the sclerotic various regions are to be distinguished, viz. the subconjunctival region, then that of the insertion of the tendons of the eye muscles, and the region of the Tenonian lymph-space. The bundles of the subconjunctival loose connective tissue, and those of the tendons are intimately connected with those of the sclerotic. In the region of the Tenonian lymph-space (Schwalbe) the proper tissue of the sclerotic is covered with a thin layer of connective tissue; this is the inner or episcleral lamina of the Tenonian capsule (Schwalbe); the inner surface of the outer lamina and the outer surface of the inner lamina are lined with an endothelial membrane (Schwalbe).

Helfreich describes in the tissue of the sclerotic a dense plexus of non-medullated nerve-fibres. Waldeyer saw in the human sclerotic repeated divisions of axis cylinders. In the superficial layers such fine branches may be followed for a considerable distance accompanying the blood-vessels.

The sclera contains its own blood-vessels, consisting of arterioles, capillary and venous networks. The capillaries and veins are distinguished by an outer special endothelial sheath (Michel). The tissue of the sclera is, besides, perforated by the vessels destined for the chorioidea.

The above-named interfascicular lymph-spaces form an intercommunicating system; which has been beautifully demonstrated by Michel in injections into the sclerotic. There exists, in the immediate neighbourhood of the ligamentum pectinatum iridis, at the point of junction of the cornea and sclerotic but belonging to the sclerotic, a circular canal, compressed in a direction parallel to the surface of the sclerotic, lined with a special endothelial membrane; it forms an indirect communication with the interfascicular lymph-spaces of the surrounding parts of the sclerotic. This is the canal of Schlemm.

According to Schwalbe the canal of Schlemm, like the spaces of Fontana, with which it communicates, is a lymph-canal, but according to the more recent investigations of Leber, it is a venous plexus, while Waldeyer considers it with Schwalbe as a lymph-space. It communicates with the anterior chamber of the eye (Schwalbe), anastomosing by fine clefts and holes with the spaces of the ligamentum pectinatum.

This latter is a spongy tissue situated at the point of junction of the cornea and sclerotic on the one hand, and the iris, ciliary processes and ciliary muscle on the other. The trabeculæ and lamellæ which constitute its matrix are composed of elastic fibres,

thick and thin ones, arranged as a network; this is in many instances so close that more or less complete elastic membranes (fenestrated membranes) are hereby formed (Henle, Schwalbe).

Next the cornea and next the insertion of the ciliary muscle the fibres assume a special annular direction as the anterior and posterior limiting ring of Schwalbe.

The trabeculæ and lamellæ are embedded or ensheathed in a more or less hyaline elastic substance which is a direct continuation of the membrana Descemeti; their free surface is covered with a layer of flattened polyhedral endothelial cells directly continuous on the one hand with the endothelium of the membrana Descemeti, and on the other with a similar layer of cells covering the anterior surface of the iris.

The connection of the ligamentum pectinatum with the sclerotic is also a very intimate one, since the elastic fibrils between the connective tissue trabeculæ around the canal of Schlemm pass directly into those of the former.

The continuity of the ligamentum pectinatum with the iris, processus ciliares and musculus ciliaris, is effected in this way: The elastic trabeculæ and lamellæ of the spongy substance of the ligamentum pectinatum pass directly into the tissue at the root of the iris, hereby they retain their arrangement as a spongy substance; in some mammals the spaces are here very considerable and are called the spaces of Fontana.

The membrana Descemeti, which, as we have mentioned above, is continued over the ligamentum pectinatum, passes directly into the delicate basement membrane of the anterior surface of the iris. The continuity of the endothelium has been mentioned above. From the matrix of the iris and processus ciliares, especially the former, trabeculæ of connective-tissue bundles with elastic fibres pass into the matrix of the ligamentum pectinatum; these trabeculæ, the iris-processes of Rollett, are also covered with a continuation of the membrana Descemeti (Königstein, Briggs) and are very conspicuous in pigmented eyes both in man and mammals, owing to the branched connective-tissue cells contained between their bundles being pigmented.

The elastic tendons of the meridional portion of the ciliary muscle are continued into the elastic trabeculæ and lamellæ of the ligamentum pectinatum.

RECEIVED LIBRARY OF THE UNIVERSITY OF CALIFORNIA

CHAPTER XXXVI.

THE IRIS, CILIARY PROCESSES, AND CHORIOIDEA.

1. The Iris.

The Iris consists of the following layers, counting from the anterior to the posterior surface :

a) The endothelium consists of polyhedral cells, each with a spherical or slightly oval nucleus ; in dark-coloured eyes of man and mammals the cell substance is filled with dark brown pigment granules.

b) Underneath the endothelium is a very delicate hyaline basement membrane ; its continuity with the hyaline elastic membrane of the ligamentum pectinatum and with Descemeti's membrane has been mentioned above.

c) The substantia propria : this forms the matrix of the iris and consists of bundles of connective tissue chiefly accompanying the blood-vessels ; near the ciliary margin, especially towards the posterior surface, they are arranged in larger groups densely interwoven with one another.

Between these bundles of connective tissue are found very numerous branched cells ; in dark eyes many of them contain a variable amount of pigment granules. Both the unpigmented and pigmented cells are generally elongated, slightly flattened, and with thin processes, which, extending chiefly in the level of their broad diameter, cause that the cells when viewed in profile appear more or less spindle-shaped, with only few processes. Around the blood-vessels and near the posterior surface these pigment-cells are most numerous. In the latter place they are very closely arranged, and being parallel to the surface form almost a layer of their own.

Besides these branched cells there are a few migratory cells to be met with in the sheath of the blood-vessels.

d) A hyaline thin layer, being a kind of basement membrane ; it is a continuation of the lamina vitrea of the ciliary processes and bears also the name of membrana pigmenti.

e) The uvea ; this is composed of polyhedral epithelial cells each with an oval or spherical nucleus ; the cell substance is in all instances, albinos excepted, filled with dark brown pigment granules. In blue eyes this is the only layer of the iris that contains pigment granules.

According to Hirschberg and Loewe the pigmented epithelium of the posterior surface consists of two layers : a superficial and a deep one ; the former being continuous with the pars ciliaris retinæ, the latter with the uvea of the processus ciliares.

Near the pupillary margin are the circular bundles of unstriped muscle fibres of the sphincter pupillæ ; they are situated nearer to the posterior than to the anterior surface and diminish in breadth towards the pupillary margin. They are separated from one another by small masses of the iris stroma. At the pupillary margin the muscle fibres of the sphincter are continuous with a thin membrane of muscle cells extending over the whole posterior surface of the iris (Henle, Hüttenbrenner, Ivanoff), but underneath the above superficial layer of pigment cells, to the ciliary margin, where its muscle cells change into a circular direction and anastomose into a plexus (Ivanoff). These muscle cells are all directed from the pupillary to the ciliary margin and represent the dilatator pupillæ.

The Blood-Vessels of the Iris.—The arterial vessels are those derived from the circulus arteriosus major and from the ciliary processes. The superficial layer of the tissue of the iris contains the capillary networks; these are densest near the posterior surface, and form a continuation of the capillary network of the ciliary processes ; the sphincter pupillæ has its own dense capillary network.

The veins follow the arterial branches and just like these are situated chiefly in the middle layer of the stroma.

The adventitia and media of the arterial vessels is very thick and in the latter especially muscular (Arnold, Hüttenbrenner).

According to Faber there exists a direct transition of arterial vessels into venous branches.

The Lymphatics.—The iris has no lymphatic vessels in the ordinary sense, but there exist lymphatic sinuses in the sheath of the blood-vessels, especially of the arteries and between the trabeculæ of the connective-tissue bundles; at the ciliary margin of the iris they open into the spaces of Fontana and into those of the ligamentum pectinatum.

The Nerves of the iris are very numerous and the number of the medullated nerves is in direct proportion to the muscular tissue. The human iris possesses fewer nerves than that of mammals, and this again fewer than that of birds (Pause).

The nerves are arranged, according to Arnold, Formad, Faber, and others, in this manner : in the outer or ciliary portion of the iris the nerve branches form a plexus ; from this are derived : (*a*) non-medullated fibres terminating as a delicate network on

the dilatator; (*b*) medullated nerves passing eventually into fine non-medullated fibrils arranged as a network close to the anterior surface; and (*c*) a network of non-medullated fibres belonging to the sphincter pupillæ.

According to A. Meyer, there are in addition fine non-medullated nerve fibrils which accompany the capillary blood-vessels and are connected into a network.

According to Faber there are ganglion-cells contained in the nerve-networks of the iris.

2. The Ciliary Processes.

These consist of a matrix which is similar to that of the iris, being a continuation of it; it is chiefly composed of bundles of connective-tissue fibres with pigmented branched corpuscles between them. These are most numerous in the part next to the chorioidea. Elastic fibres are also to be met with. The stroma is directly continuous with the tissue of the ligamentum pectinatum, as mentioned above. The part nearest to the sclerotic is of loose texture and contains the larger vascular branches; the superficial layer of the ciliary processes contains the capillary blood-vessels.

The stroma of the ciliary processes is covered on its free surface with a glassy hyaline membrane, lamina vitrea, in which on being treated with certain reagents, ten p. c. saline solution amongst others, bundles of fine fibrils can be detected. It is a continuation of the basement membrane on the posterior surface of the iris, but is much thicker and possessed of a network of folds (H. Müller), the meshes of which are much closer towards the iris than towards the chorioidea.

The pigmented epithelium or uvea, which follows behind the lamina vitrea, is a continuation of the same layer of the iris, and is identical with it in structure.

Finally, the uvea is covered with the pars ciliaris retinæ, a single layer of columnar transparent cells, each with an oval nucleus (see below).

The space between the ligamentum pectinatum, sclerotic, ciliary processes and adjoining portion of the chorioidea is occupied by the ciliary muscle, originating at the ligamentum pectinatum. Nearest to the iris are the few circular bundles of the portio Mülleri, while the radiating part occupies the root of the ciliary processes, in fact causes the projection of them; the greater portion of the muscle, however, has a meridional direction, and extends from the ligamentum pectinatum between the sclerotic and ciliary processes and chorioidea, for a considerable distance backwards. It is separated from the sclerotic by the thin lamina fusca.

The bundles of this muscle are arranged in lamellæ, separated from one another by connective tissue, of which in dark eyes the branched pigmented cells form a conspicuous part. Within each lamella the bundles form plexuses. Near the termination,

both of the radiating and meridional portion, but especially of the latter, the formation of plexuses becomes very marked, owing to the peculiar platelike enlargements of the muscle bundles; each of these gives off a number of thin, almost threadlike branches, which at the same time represent the terminations of the former (Ivanoff). Besides the network of capillaries, the ciliary muscle possesses a rich plexus of non-medullated nerve fibres, with which are connected numerous ganglion cells, either in small groups or in larger collections.

The arterial branches of the ciliary processes and ciliary muscle are derived from the circulus arteriosus iridis major. In the ciliary processes the network of capillaries is very dense, and, corresponding to the elevations of these, forms conical groups, which, when viewed from the surface, are not unlike the capillary networks in the intestinal villi viewed obliquely.

3. The Chorioidea.

The chorioid membrane, being a continuation of the ciliary processes, contains a stroma of bundles of connective tissue, with numerous networks of elastic fibres and flattened branched pigmented cells. Counting from the sclerotic inwards, we meet with the following layers :—

a) The lamina fusca; this is a loose lamellar continuation of the scleral connective tissue, both fibrillar connective tissue and elastic networks. The connective-tissue cells are pigmented and unpigmented. The former are either large plates with few short and broad processes and oval nucleus, or they are small and possessed of numerous fine and branched processes, or they are altogether unbranched and more or less spheroidal. In the last instance the nucleus is spherical. The unpigmented cells are small flattened branched cells and endothelial plates, each with an oval nucleus, and covering the surface of the lamellæ, as mentioned above.

b) The lamina or membrana suprachorioidea is merely the continuation of the lamina fusca, but is considered part of the chorioidea both by right of custom and by the fact that when separating by force the sclerotic from the chorioidea it remains attached to the latter. Like the lamina fusca, it consists of lamellæ of connective-tissue bundles, including networks of elastic fibrils. The lamellæ, covered with endothelium, are separated from one another by large more or less continuous lymph-spaces. The fewer these lamellæ the more considerable are the lymph-spaces (Schwalbe). The blood-vessels and nerves, running between the sclerotic and chorioidea, obtain on their passage a special sheath from the stroma of the lamellæ. The connective-tissue cells of the lamellæ of the lamina suprachorioidea are of the same nature as those of the lamina fusca.

c) Next to the lamina suprachorioidea follows a deep loose layer, containing the

larger blood-vessels, the stratum vasculosum of Loewe; it is a continuation of a similar section of the ciliary processes.

d) Then follows the elastic layer of Sattler. This observer finds in the human chorioidea, and also in that of many mammals, underneath or outwards of the chorio-capillaris, an endothelial membrane, then a stratum of elastic networks, generally without cells and containing the small branches of the arteries and veins. A second endothelial membrane separates it from the next following elastic layer, which generally contains branched pigment cells.

e) Further comes the membrana chorio-capillaris, containing the dense network of capillaries. These vessels are ensheathed in a special layer of spindle-shaped and flattened cells, pigmented or unpigmented; the former are either large flat plates with few broad short processes, or they are small with numerous fine long processes. The unpigmented cells are small and branched; spheroidal cells, both with or without pigment granules, occur also here.

f) A hyaline smooth lamina vitrea separates the chorio-capillaris from the uvea.

g) This last, viz. the uvea, is considered a part of the retina.

In the region of the ora serrata the uvea is covered with the pars ciliaris retinæ, mentioned above.

Ivanoff mentions bundles of unstriped muscle cells which are to be met with even in the posterior parts of the chorioid membrane; although outrunners of the meridional portion of the ciliary muscle, they are supposed by him to be independent muscular bundles belonging to the tissue of the chorioidea.

According to Hällstén and Tigerstedt the chorioidea of man and many mammals (especially rabbit) possesses a continuous layer of unstriped muscle cells situated close to the outer surface of the chorio-capillaris, and probably identical with Sattler's inner endothelial membrane. The cells of this muscular membrane have a meridional direction, except at the entrance of the optic nerve and at the ora serrata, where they are arranged circularly.

The dense network of capillaries of the membrana chorio-capillaris is derived from the arteriæ ciliares breves and recurrentes. The vessels leading into the venæ vorticosæ are derived from the chorio-capillaris, from the iris, ciliary processes and the greater part of the ciliary muscle.

The wall of the capillary blood-vessels of the chorio-capillaris is, like that of other capillaries, a single layer of elongated endothelial plates (Hällstén and Tigerstedt).

The lymphatics will be considered in connection with those of the eyeball in general.

CHAPTER XXXVII.

THE LENS AND VITREOUS BODY.

1. The lens of man and mammals is enclosed in a thick resistent elastic capsule, which in the fresh state and after reagents shows parallel to the surface very fine and dense striæ. The capsule is thickest on the anterior surface, and diminishes in thickness towards the posterior pole. The posterior surface of the anterior capsule, that is the part covering the anterior surface of the lens substance, is lined with a single layer of hexagonal transparent granular-looking epithelial cells, each with a spherical or oval nucleus. When properly hardened the substance of the cells contains a delicate dense reticulum, and so does the nucleus, but it is less dense in the latter than in the former.

The capsule covering the posterior surface is without any epithelial lining, and is in close contact with the substance of the lens. At the margin the nucleated hexagonal epithelial cells change into nucleated lens fibres, which gradually elongating run in a slightly curved direction from the posterior to the anterior surface. This condition is recognisable already in the earliest stages of the fœtal lens. Passing then from the margin of the lens towards the posterior pole, we see in a bird's-eye view a similar hexagonal mosaic as on the anterior surface, but the latter is due to the hexagonal nucleated epithelial cells, while the former belongs to the ends of the lens fibres touching the posterior capsule.

The substance of the lens is made up of the lens fibres and the interstitial substance. The lens fibres are bandlike structures passing from the posterior surface to the anterior, their posterior extremity is slightly enlarged and is in close contact with the posterior capsule, while the anterior one touches the epithelium of the anterior capsule.

The fibres of the outer layers of the lens substance contain each an oval nucleus, visible under all conditions, those near the middle of the lens possess each a rudiment of a nucleus only demonstrable with strong acids.

The nuclear zone of Mayer is the zone near the margin of the lens in which the lens fibres show a distinct nucleus, that is the region of transition of the epithelial cells into the lens fibres.

In this zone the nuclei are situated in a curved plane belonging to the anterior half of the lens.

The lens fibres of the peripheral portions are broader and thicker than those in the centre, the former are softer and their substance less firm than that of the latter. Those in the centre or the so-called nucleus of the lens are firmest. In all parts they show a very delicate and dense longitudinal striation. The shape of each lens fibre is that of a band, hexagonal in transverse section, but so that the two parallel surfaces are greatly larger than the other four. In a section that comprises a number of lens fibres transversely cut, a beautiful and regular hexagonal mosaic is obtained.

The surface of the lens fibres is not smooth, but beset with minute ridges and furrows more or less regularly and closely distributed, the ridges of one lens fibre fitting into the furrows of its neighbour (Valentin, Henle, Kölliker, Babuchin, Fubini, and others). These ridges and furrows are best marked on the narrower sides of the lens fibres—the short sides of the lens-hexagons—less so on the broad sides, although rudiments of them are also seen on the latter. Looking at the narrow sides of the lens fibres in the bird's-eye view a transverse striation is noticed. The fibres of the central part of the lens have larger and more irregular ridges and furrows than those ot the periphery.

The lens fibres extend between the anterior and posterior surfaces of the lens and are arranged in concentric lamellæ parallel to the surface. Each lamella consists of a single layer of lens fibres joined at their broad surfaces. Their extremities are slightly enlarged. At the two surfaces of the lens these extremities are in contact with one another in the sutures, or the rays of the so-called lens-stars. In the lens of the new-born child the star both of the anterior and posterior surface consists of about three rays radiating alternately from the anterior and posterior pole towards the lens margin. In the lens of the adult each of the three rays possesses three or more secondary rays. These sutures extend from the surface of the lens towards the centre, and when viewed in the fresh organ appear as very fine and wavy lines, but after treatment with hardening reagents, or better still after boiling, they appear as narrower or broader clefts. In the natural state these sutures contain a semifluid homogeneous interstitial cement-substance. The same substance is present between the lamellæ, and also, though in a lesser quantity, between the fibres of the same lamella. This interstitial substance is the same as met with in all other organs, viz. the interfascicular substance of fibrous connective tissue, the cement-substance of epithelium and endothelium, of unstriped muscle cells, &c.

In the interlamellar cement-substance of the lens longer or shorter, broader or narrower channels may be met with in some places ; in transverse sections they appear as polyhedral discontinuities between the lamellæ. Fine canals extend from them between the lens fibres of the same lamella. I therefore agree with O. Becker against Babuchin and Arnold that there exist channels in the interstitial substance, which probably have not

only an important bearing on the changes of the shape of the lens during accommodation, but are also essential in the nutrition of the organ.

2. The vitreous body is enclosed in a capsule, the membrana hyaloidea. This is a hyaline quite structureless delicate membrane. It increases in thickness towards the ora serrata, and forms here the Zonula ciliaris. It does not cover the fossa patellaris of the corpus vitreum (Ivanoff, Schwalbe), but passes from the margin of this latter to the margin of the lens as the Zonula Zinnii, thus forming the anterior wall of the lymphatic canal known as canalis Petiti. Like the rest of the hyaloidea, the Zonula ciliaris is hyaline, but contains longitudinal thin, and stiff elastic fibres, which over the ciliary processes and towards the root of the iris increase in number and thickness. They become at the same time grouped into bundles. In sections of hardened preparations the Zonula ciliaris remains adhering to the surface of the ciliary processes, and the bundles of its stiff fibres are very marked.

Immediately underneath the hyaloidea are found isolated small granular-looking cells, each with a single or double transparent nucleus. These cells are the subhyaloid cells of Ciaccio. They are possessed of amœboid movement (Ivanoff), and are met with not only in the region of the corpus vitreum, but also in that of the Zonula ciliaris. According to Ivanoff similar cells occur also between the hyaloidea and the retina.

The substance of the corpus vitreum, that is the humor vitreus in man and mammals, appears, according to almost all observers (Brücke, Hannover, Bowman, Doncan, Stilling, Ivanoff, Gerlach, Smith, Schwalbe, and many others), arranged in layers separated from one another by clefts. These clefts possess in the peripheral parts a more concentric arrangement, and they radiate from here towards the centre. According to more recent observers, especially Stilling, Ivanoff, and Schwalbe, these spaces are not lined with any membranous structures.

In the centre of the adult corpus vitreum exists the canalis hyaloideus or canal of Stilling; it extends from the papilla optici to the posterior capsule of the lens, and is lined with a hyaline membrane, a continuation of the membrana hyaloidea. It is not to be confounded with the canal of the embryonal corpus vitreum containing the arteria hyaloidea.

Of solid structures there exist in the adult corpus vitreum few and scarce fibres; they are the remnants of the embryonal vessels (Lieberkühn). Ivanoff mentions in the region of the ora serrata fibres which are supposed by him to pass into the Zonula ciliaris of the hyaloidea, but this must be questioned. Schwalbe saw in the human corpus vitreum in one instance fine bundles of fibrils.

Similar to the subhyaloid cells of the surface, mentioned above, there exist similar cells close to the membrane lining the canal of Stilling (Schwalbe). In the substance

of the corpus vitreum occur isolated cells at considerable intervals from one another; like the subhyaloid cells, they are possessed of amœboid movement, and include one, two or three nuclei. They are, according to Ivanoff, either spherical, or more or less branched with or without one or two large vacuoles. Lieberkühn and Schwalbe correctly maintain that these cells are all of the same kind, viz. colourless blood corpuscles; there exist all intermediary forms between them; those with vacuoles are probably degenerating forms.

CHAPTER XXXVIII.

THE RETINA.

COUNTING from the outer to the inner surface of the retina, the following layers are distinguished :—

1) The uvea or pigmented epithelium of the retina.
2) The layer of rods and cones.
3) The limitans externa.
4) The outer nuclear layer.
5) The outer granular or outer molecular or internuclear layer.
6) The inner nuclear layer.
7) The inner granular or inner molecular layer.
8) The layer of ganglion cells.
9) The layer of nerve fibres.
10) The limitans interna.

1. THE UVEA.

The uvea or tapetum nigrum or the pigmented epithelium is the continuation of the same layer of the iris and the ciliary processes ; it is considered a part of the retina, and not of the chorioidea, because it developes, like the retina, from the secondary eye-vesicle or optic cup of the embryo (Kölliker, Babuchin), the former (viz. the uvea) being its outer, the latter (viz. the retina) its inner membrane; and also because the pigmented epithelium bears an intimate relation to the retina (see below).

The individual cells are polyhedral. The substance of the cell is crowded with brownish black pigment rods, which however possess the shape of rhombic flattened crystals with sharp angles (Frisch). Their tint is darker in dark eyes than in light ones. They are slowly bleached by the light in the presence of oxygen (Kühne), but retain their colour in the absence of oxygen (Mays). The part of the cell next to the chorioidea is generally free of the pigment, and this contains a single spherical or oval clear nucleus generally flattened parallel to the surface. Many of the cells of the albino rabbit contain two nuclei (Schwalbe). According to Angelucci the cells of the rabbit generally are of two kinds : (*a*) such as possess two, and (*b*) as possess only a single nucleus. The

former are twice as large as the latter. In the frog the unpigmented part of the cell is covered, according to Angelucci, with a cuticular substance. In albinos generally the cells contain only few pigment granules, but none in the tapetum lucidum of nocturnal animals and ruminants. A large fat globule has been noticed by H. Müller in each of the unpigmented cells of the rabbit. When viewed from the external surface the cells appear polygonal, separated by clear lines (Henle) of the ordinary semifluid albuminous interstitial cement-substance (Schwalbe). Most of them are hexagonal or pentagonal, but there are also some with more sides. The cells vary very much in size, the large ones appear isolated and in small groups, as centres around which the small ones are arranged (Kuhnt). According to Morano the cells are broader in the peripheral part of the frog's retina than in the centre, the relation being about 5 to 3 or even less.

When viewed in profile, each cell sends between the outer members of the rods (see below) a great number of fine parallel filaments, each of which contains a row of pigment crystals, the individual crystals being sufficiently apart so as to allow the pale substance of the filament to be recognised. As long as the filaments are still within the cell body they are grouped in bundles and are also connected into a network, but they become isolated cilia-like fibrils when entering the level of the rods. The longest and best marked such filaments are present in amphibia, they are only short in man and mammals; in the former instance they extend as far as the boundary between the outer and inner members of the rods, or according to Merkel, even further, while in man and mammals they as a rule penetrate only a short distance between the rods.

These fibrils are closely adhering to the surface of the rods and appear more or less completely to invaginate them (M. Schultze). Under the influence of sunlight they are retracted into the cells (Boll); see also below. According to Ewald and Kühne the pigment crystals as such are capable of movement (displacement) within the protoplasm of the cells.

The diameter of the cells being as great as that of a number of rods taken together, it follows that each cell of the tapetum covers at once a group of rods.

2. The Rods and Cones.

Each *rod* consists of an outer and inner member. The former is of a cylindrical shape and its substance is bright and glistening. The outer member of both the rods and cones is composed of the neurokeratin of Kühne and Ewald (Kuhnt). Continued strong light produces a swelling of the rods, but they shrink again when exposed to darkness (Ewald and Kühne). The substance of the outer member comports itself in most instances different from that of the inner as regards staining power and refraction (M. Schultze, Brown, Rudnew, Valentin, Boll, Kühne, and others). In the fresh state

and after reagents (iodine-serum, osmic acid) the outer member exhibits fine longitudinal striæ, due to the presence of fine ridges and furrows (Hensen, M. Schultze), and also closely placed transverse striæ. After certain reagents, especially serum and dilute liquor potassii, the outer member of each rod separates in a great many thin homogeneous-looking transverse discs (Hannover), owing to the swelling up of a cement-substance between the discs (M. Schultze). Ritter, Manz, Schiess, and others describe, after treatment with water and dilute chromic acid, a central filament in each outer member (Ritter's filament). The length of the outer member is generally greatest at the back of the eye, it diminishes towards the ora serrata.

The outer extremity of the outer member is ensheathed, as mentioned above, by the filaments of the tapetum, it is as a rule rounded or slightly conical.

The inner extremity is in contact with the inner member, from which it is separated by a thin layer of a cement-substance. When seen in profile the line of division is generally a straight one, but occasionally it is a broken one, and this is owing to the outer and inner member not joining in a single straight plane, their several extremities being facetted. But there is also another mode of junction between the two members, that is by a membranous sheath; this is a continuation of the cortical substance of the inner member and extending on and embracing the adjoining extremity of, the outer (Schwalbe). According to Landolt this sheath extends over the whole outer member of the batrachian rods.

The inner member of the rods in man and mammals is cylindrical, but with convex surfaces; it is broader than the outer one and about as long as the latter.

In fishes and birds the inner member is more filamentous, but forming a bulbous enlargement at the point of junction with the outer member. In the frog's retina there are two distinct types of inner members, as I can fully confirm Schwalbe's observations; one being filamentous and long and joined to a short outer member, the other short and thick and joined to a long outer member. Hoffmann observed the same relations also in the retina of Bufo and Bombinator, but not in Triton and Salamandra.

The inner member is pale or indistinctly granular and shows a fine longitudinal striation due to the presence of fine fibrils which extend over it from the limitans externa in the shape of a basket-like sheath (Krause, M. Schultze).

In the outer extremity of the inner member exists in many instances (birds, Krause; many other vertebrates, M. Schultze) a peculiar lenticular structure, whose presence becomes very distinct after maceration in iodine-serum and osmic acid.

In the human and mammalian retina, however, there exists in the cortical portion of the inner member, instead of the lenticular structure, a peculiar mass of longitudinal fine bright fibrils (M. Schultze).

According to Krause each inner member contains a central thread.

Each *cone* consists like the rod of an outer short conical member and an inner longer and broader one, the body of the cone, with convex sides. The former contains within a delicate sheath (M. Schultze) a transparent substance which, just like that of the outer member of the rod, easily separates into a great many thin transverse discs. Also around the inner extremity of the body of the cones there projects from the limitans externa a basket-shaped arrangement of fibrils surrounding it like a sheath. The cortical substance of the body of the cones is also longitudinally striated (M. Schultze).

I have been able to ascertain that in the frog's retina this striation of the cone-body and the inner member of the rods is in reality due to a fine reticulum arranged longitudinally.

Where the inner member of the rods contains the above-named lenticular structure, the body of the cones possesses an elliptical one. Dobrowolsky saw this also in the cones of the human retina.

After certain reagents, Müller's fluid, iodine-serum, osmic acid, &c., the body of the cones of the ape (M. Schultze), of man (Krause, Hensen), and other mammals and birds (Krause), exhibits a central filament, which according to Krause is connected with the elliptical structure.

The outer extremity of the body of the cones in most birds, reptiles, and amphibia, where it joins the outer member, contains a spherical corpuscle, which in most instances is coloured red, orange, yellow, green, or according to Krause and Dobrowolsky also blue. Hoffmann saw coloured globules in the inner members of the cones, also in the retina of Halmaturus.

Double cones, each possessed of two outer and two inner members, the latter joined at their inner extremity, occur in the lower vertebrates, but not in mammals.

The relation of the rods and cones as regards length varies in different animals; in man and most mammals the extremity of the outer member of the cones reaches as far as the middle of the outer member of the rods; in the frog it does not pass much beyond the boundary between outer and inner member of the rods, while in fishes it extends nearly as far outwards as the outer member of the rods.

The body of the cones is always thicker than that of the rods, and is nearly, if not quite, as long.

The number of the rods is in man, most mammals, and also amphibia, and most fishes, greatly in excess of those of the cones, except in birds, where the opposite holds good. In the macula lutea of the retina of most vertebrates there exist only cones; some fishes (shark and roach), and some mammals (bat, mole), do not possess any cones

even in the macula lutea, while other vertebrates, as the owl, rat, mouse, guinea pig, and rabbit, possess only small and few cones.

In the animals with cones in the macula lutea, the further away from this latter the fewer the cones.

Both between the outer members of the rods and more distinctly between the latter and those of the cones there exists a homogeneous transparent albuminous substance which is fluid in the fresh and living state (Schwalbe, Henle, H. Müller).

Leydig observed first that the living retina possesses a red colour, but Boll investigated this more minutely in mammals and especially the frog, and found that in the living state and after preserving it in the dark, the retina possesses a purple red colour lodged in the outer members of the rods. On the influence of the sunlight, this gradually makes room for a satiny lustre, and then altogether fades away. Retinas of eyes kept in the dark, or in red, or yellow light, easily separate from the pigmented epithelium, owing to an active retraction of the pigmented fibrils which in the ordinary state pass from the above cells between the rods, as described above. Kühne and Ewald showed that this colour is originally purple, the visual purple, and is a pigment diffused in the outer members of the rods; it can be isolated; independent of the living state it can be reproduced when faded, by the contact with the pigmented epithelium; the cones do not contain the visual purple, and in some retinæ (Rhinolophus hyppoxideros, fowl, pigeon) also the rods are without it; in the human retina and in that of the ape (Macacus cynoglossus) the rods about the ora serrata are likewise without it; where there exist numerous cones with coloured globules, the surrounding rods possess no visual purple. Boll found in the frog's retina, besides the purple rods, also a few of a bright green colour.

In the human retina, in the living state and after death, provided the retina had in the latter instances been kept in the dark, the visual purple has been noticed by Boll, Kühne, Schmidt-Rimpler, Adler, and Nettleship. Adler found that the presence of the visual purple is in direct proportion to the intact normal function of the retina.

3. The Limitans Externa.

The inner members of both rods and cones penetrate in a sharp line, which in profile view appears as a thin boundary line, through the limitans externa (M. Schultze), into the layer of the outer nuclei. The limitans externa possesses consequently smaller and larger holes, through which the members of both rods and cones respectively pass. Many of the rods and cones appear united with the limitans externa by minute lateral projections (Schwalbe).

When viewed from the surface the limitans externa appears as a reticulated structure with fine striæ in it (M. Schultze). From it issue fine fibrils to ensheath

the inner extremities of the inner members of both rods and cones, as mentioned above.

4. The Outer Nuclear Layer.

Having passed the limitans externa, each rod and cone continues on its radial course through this layer as the rod- or cone-fibre respectively, and at the same time becomes a great deal thinner; this is especially the case with the rod-fibres, which resemble fine filaments.

Each rod- and cone-fibre contains at one point an oval nucleus. Owing to the relative thinness of the rods and cones, and consequently owing to the relatively and absolutely great abundance of them, the number of layers of the nuclei forming the outer nuclear layer is very considerable; in the retina of the batrachiæ, owing to the thick rods and cones, the number of the nuclei is much smaller, being reduced to two, or at most three layers.

In the retina of man and mammals the nuclei of the cone-fibres are in close contact with the limitans externa, while those of the rod-fibres are arranged in several layers further away.

Owing to this relation, viz., the close position of the nucleus to the body of the cones in man and mammals, it follows that the outer portion of the cone-fibre, i.e. the part between the nucleus and the body of the cone, is very much shorter than the inner one, while in the rod-fibres the two portions, viz. the inner and outer, are both of an easily perceptible length.

But this condition is not common to all vertebrates, for in batrachiæ the relation is reversed, the nuclei of the rod-fibres lying in immediate contact with the limitans externa.

About the macula lutea of the retina of man and mammals, where the number of rods becomes greatly reduced, of course also the layers of the nuclei diminish in numbers, especially in the inner parts of this, i.e. the outer nuclear layer; and there exists here a narrower or broader stratum between the above nuclei and the next following outer granular layer of the retina, in which only the inner portions of the cone-fibres are to be met with. This is Henle's outer fibrous layer.

While the outer part of the rod-fibre is always the gradually attenuated continuation of the inner member of the rod, that of the cone-fibre often contrasts in a marked manner with the body of the cone, inasmuch as this latter appears to rest with a broad extremity on the limitans externa (Kölliker), while the cone fibre is here very thin. Thus it appears as if the cone-fibre were an independent thread penetrating into the body of the cone like its axial fibre (Krause and others).

As regards the nuclei themselves, those of the rod-fibres differ from those of the cone-fibres not only in position, as mentioned above, but also in their aspect. In man

and mammals the nucleus belonging to a rod-fibre is, in the fresh state, and after many reagents, transversely striated (Henle, Krause, Ritter, and others), owing to its being apparently composed of some two or even three bands of a transparent hyaline substance alternating with two or three more highly refractive discs. Their limiting membrane is indistinct. The nucleus of a cone-fibre is on the other hand limited by a distinct membrane, is larger and has a clear contents, and in this may be recognised, after certain reagents (spirit, chromic acid), a pale transparent honeycombed reticulum.

In the retina of the frog there is also a very marked distinction between the nuclei of the rod- and those of the cone-fibres; the latter are more spherical, larger, do not possess any distinct limiting membrane, and include a uniformed fine reticulum, while the former are slightly smaller, oval, and within a definite limiting membrane contain a reticulum coarser and generally more or less shrunk away from the membrane, besides being always placed close to the limitans externa.

Each rod- and cone-fibre at the boundary of the next inner layer of the retina, viz. the outer granular layer, possesses a conical enlargement (M. Schultze), which is very much more conspicuous in the cone-fibres than in those of the rods; very fine fibrils come off from this enlargement, and penetrate into the granular layer, where they are lost. According to Max Schultze, these fibrils are nerve-fibrils.

According to Merkel each cone-fibre passes directly into the outer process of the cells of the inner nuclear layer (see below).

All these elements of the outer nuclear layer, viz. the rod-fibres and their nuclei, the cone-fibres and their nuclei, are embedded in a homogeneous honeycombed membranous matrix, which includes also a good many fibrils (Max Schultze) and whose spaces are of exactly the size and shape of the above nuclei. This honeycomb is in connection with the radial fibres of Müller (see below), and represents in fact the terminal membranous expansion of the latter. *The limitans externa* above mentioned is *the outer boundary layer of this honeycombed matrix.*

The rods and cones with their respective fibres and nuclei represent the membrana Jacobi of the authors, they are in fact epithelial cells, peculiarly transformed (M. Schultze), and hence may be considered as the sensory epithelium (Schwalbe) analogous to the sensory epithelium in the olfactory, acoustic and taste organ, and, according to M. Schultze, the above epithelial cells, are the real terminations of the nerves of the retina.

All the layers of the retina internally to this sensory epithelium are developed, together with this latter, from the inner lamina of the optic cup. So that these layers, viz. the outer granular, the inner nuclear, and the inner granular layer, the ganglion-cells and the layer of nerve fibres, are comparable to a part of brain matter, modified in a

certain manner, and pushed out towards the periphery (Hannover); hence Brücke's designation of it as tunica nervea, or Henle's as stratum nerveum.

5. The Outer Molecular Layer.

The outer granular or molecular layer is a dense network of minute fibrils with varicosities (M. Schultze); they are embedded in a homogeneous ground substance. Both in vertical and horizontal sections the reticular nature of this layer is very distinct, and the granules between the fibrils are only the latter seen in optical section. In the outer portion of this layer, longer or shorter fibrils are met with which run for considerable distances a horizontal course (M. Schultze, Hulke) and are possessed of minute varicosities. Embedded in, and intimately connected with the above reticulum are branched cells, flattened in a direction parallel to the surface (Golgi and Manfredi, Schwalbe, Krause), and containing a spherical clear nucleus. In the retina of the pike they are arranged in several layers of flattened endotheloid slightly branched cells (H. Müller).

The nature of the branched cells of this layer is considered by M. Schultze to be that of ganglion cells.

The radial or Müller's fibres (see below) penetrate vertically through this layer and appear on all sides connected with the reticulum by fine lateral branchlets (M. Schultze, Heinemann, Landolt), but according to Schwalbe, they (viz. Müller's fibres) pass simply through it (reticulum) without entering into any connection with it.

6. The Inner Nuclear Layer.

This layer differs in many respects from the outer nuclear layer, its nuclei being larger and in man and mammals arranged in fewer layers than those of the outer nuclear layer, while in the amphibia the reverse is the case, the inner nuclei forming more layers than those of the outer.

The nuclei of the inner nuclear layer are of three different kinds: (*a*) very elongated transparent nuclei with a very distinct limiting membrane, they belong to the radial or Müller's fibres and lie either altogether within, or only closely at the side of them. (*b*) The greater number of nuclei of this layer are oval, placed with the long axis vertical to the surface; in most instances they are without any distinct limiting membrane, and include a uniform honeycombed reticulum; in the young retina (human as well as of mammals) many of them contain a nucleolus. These nuclei belong to spindle-shaped cells, the body of which is limited to a thin zone of protoplasm around the nucleus and drawn out at the poles into an outer and inner process. The outer is broad and branched and passes through the outer granular layer, while the inner is very thin, threadlike, and beset with minute varicosities; it penetrates radially

into the next following inner granular layer, through which, according to Retzius and Schwalbe, it passes undivided.

In the macula lutea the inner processes of these cells have not a radial direction, as in all other parts of the retina, but run a more oblique course (M. Schultze, H. Müller, Hulke and others).

These cells are now considered by most observers to be bipolar ganglion cells (M. Schultze, Merkel, Schwalbe). According to Merkel they are of two different kinds: those connected with the cone-fibres and those connected with the rod-fibres. The former possess according to Merkel an unbranched, the latter a branched outer process. But in this latter statement he is contradicted by Kuhnt, according to whom all outer processes of the cells of the inner nuclear layer are branched. Kuhnt however confirms Merkel in the observation that they are connected either with the rod-fibres or with the cone-fibres. Also Gunn saw a connection of the cone-fibres with the outer processes of some of these cells.

c) At the inner boundary of the inner nuclei is a layer of nucleated cells (Vintschgau); they are flattened and parallel to surface and are connected with one another in a network. These cells are particularly well shown, forming almost a separate layer, in the young retina both of man and mammals.

The matrix of the inner nuclear layer is, just like that of the outer nuclear layer, a honeycomb of membranes and fibrils, intimately connected with the sides of the radial or Müller's fibres. The holes and channels of the matrix are occupied by the above bipolar ganglion cells.

7. The Inner Granular or Molecular Layer.

This layer is always much thicker than the outer granular layer, with which it coincides in structure, viz. being a dense reticulum of very fine fibrils (M. Schultze, Kölliker, Manz and others). In birds and amphibia this layer appears stratified, owing to the reticulum being much denser in some horizontal planes than in those between (M. Schultze).

Into this reticulum pass from inwards the processes of the ganglion cells and through it penetrate in a radial direction Müller's fibres; according to some (Max Schultze) they give off to it lateral branchlets, while others (Retzius, Schwalbe, Hoffmann, Emery) deny such a connection (see below). The processes of the ganglion cells may be traced into the inner parts of the granular layer for a longer or shorter distance in a radial, oblique, or even horizontal manner, branching on this way and ultimately altogether losing themselves in the reticulum. As mentioned above, the varicose inner processes of the bipolar ganglion cells of the inner nuclear layer

pass through the inner granular layer in a radial direction. Retzius and also Schwalbe consider these the only nerve fibrils passing through this layer.

According to M. Schultze and others the reticulum of both the outer and inner granular layer is partly supporting (connective-tissue), partly nervous tissue; but according to Schwalbe the whole reticulum is supporting tissue. Golgi and Manfredi found in this layer the same branched, flattened cells as in the outer granular layer.

8. The Layer of Ganglion Cells.

Except in and around the macula lutea the ganglion cells are arranged in a single layer. In the former they form several layers. In man and mammals the ganglion cells are conspicuous by their large size; in that of the batrachiæ they are very small, the cell substance being reduced to a thin layer around the nucleus. This latter is in all instances large and spherical, and limited by a distinct membrane. Its contents are a clear substance with a more or less distinct honeycombed reticulum, and in the young state one or two nucleoli (Schwalbe). Also these nucleoli include a delicate dense reticulum (Frommann). The cell-substance is like that of other ganglion cells, a network of fibrils (M. Schultze). Their processes are of two kinds: (*a*) each ganglion cell sends generally one process towards the next following layer of nerve-fibres (Bowman) and becomes in fact continuous with a nerve fibre (Corti, Kölliker, H. Müller and others); occasionally this process is double and both pass into nerve fibres; (*b*) towards the inner granular layer each ganglion cell sends off one or two branched processes: these break up entirely into fine fibrils, identifying themselves with the reticulum of the inner granular layer (M. Schultze). But according to Retzius, Manz, Schwalbe, and others, this process or processes pass simply through the inner granular layer and reach the inner nuclear layer. The ganglion cells anastomose with one another in some instances (Corti, Steinlin, Santi Sirena).

The ganglion cells are separated from one another by the radial or Müller's fibres, which, while passing here give off lateral fibrous membranous homogeneous structures, anastomosing into a sort of honeycomb, in whose meshes lie the ganglion cells; their processes are surrounded by a clear fluid albuminous substance. A few flattened nucleated cells (Golgi and Manfredi) besides the blood-vessels, to be mentioned below, are also contained in this layer.

9. The Layer of Nerve-Fibres.

This layer is thickest immediately around the papilla nervi optici in a direction vertically upwards and downwards, and still more so at the sides (Liebrich); it gradually diminishes in thickness towards the ora serrata. In the macula lutea the nerve fibres

do not exist as a complete layer, being greatly interrupted by the many layers of ganglion cells.

At the entrance into the plane of the retina the bundles of the nerve fibres of the optic nerve curve round from a horizontal into a vertical direction and pass on as the nerve-fibre layer, the bundles radiating from the papilla nervi optici towards the whole circumference of the retina. They always remain grouped in bundles (Kölliker), which in many places are arranged as a plexus (Michel).

The nerve fibres at the point of entrance into the retina, or rather, already in the level of the lamina cribrosa of the eyeball, lose, as a rule, their medullary sheath and throughout the retina pursue their course as simple axis-cylinders of very different thicknesses; after certain reagents they exhibit more or less regular varicosities (M. Schultze).

In the rabbit's retina there are two bundles of nerve fibres with medullary sheath passing from the optic nerve into the retina (Bowman).

In the human retina and that of the mammals it is exceptional to find medullated nerve fibres, even in the neighbourhood of the papilla nervi optici.

The connective tissue band which includes the central blood-vessels of the optic nerve, may be followed for a short distance into the nerve-fibre layer of the retina as thin bundles of connective tissue between the nerve-fibre bundles. Further away the nerve bundles are separated from one another by the same lymph-spaces that have been mentioned in Chapter XIV. p. 100, of the optic nerve, containing also the flat nucleated cells, described there as neuroglia cells. According to Schwalbe, they are more of the character of endothelial cells.

Numerous fine fibrils arranged in horizontal networks have been observed in this layer by Kuhnt; they anastomose by means of fine trabeculæ with the reticulum of the inner granular layer, with which they are indentical in their nature.

10. The Membrana Limitans Interna.

The inner boundary of the retina is formed by the inner extremities of the radial or Müller's fibres, just as the limitans externa of M. Schultze is the outer boundary layer of the honeycombed matrix into which the outer extremities of the radial fibres of Müller break up.

The fibres of Müller are pyramidal structures, which with their broad bases are in close contact and thus form a complete inner boundary of the retina, the limitans interna (Schwalbe). These bases are of various sizes, and when viewed from the surface in suitable preparations, e.g. in those stained with nitrate of silver, appear as a mosaic of

more or less polygonal fields of various sizes, and thus resemble an endothelium (W. Norris and Shakespeare), without however being one.

Each fibre of Müller possesses at its inner extremity, and while passing through the nervous layer, a pyramidal enlargement, which becomes attenuated in the layer of the ganglion cells. As mentioned previously, it passes through all the other layers in a radiating manner and terminates at the limitans externa.

In the inner nuclear layer each Müller's fibre is possessed of a nucleus, as described above, and this forms the boundary between what is regarded as the inner and outer portion, the former belonging to the layer of nerve fibres, ganglion cells, and the inner granular layer, while the latter extends through the rest of the retina to the limitans externa. According to the digestion-experiments of Kuhnt, the two portions are chemically different from one another. The nucleus belonging to the Müller's fibre in the inner nuclear layer appears in some instances as if applied to the surface only of the fibre, that is, as if it belonged to a cell fixed on the fibre. This condition may be observed, not only on the radial fibres of the frog's retina (Manz, Schwalbe), but also in that of mammals and man.

In the layer of the nerve fibres and ganglion cells, but especially in the former, each pyramidal enlargement gives off laterally membranous, homogeneous structures, as well as fibrils; by these they anastomose with one another and with the honeycombed matrix of those layers. The substance of the radial fibres is longitudinally striated and each contains in the pyramidal extremity an oval clear nucleus.

The connection of the radial fibres of Müller with the matrix of the reticulum in the inner and outer granular layer, and with the honeycombed stroma of the inner and outer nuclear layer has been mentioned above.

11. The Macula Lutea and Fovea Centralis.

This part of the retina of man and apes owes its yellow colour to the presence of a diffuse yellow pigment present only between the elements of the retina (M. Schultze).

The difference between the layers of the macula lutea and of the surrounding portions of the retina have been mentioned already above, viz. the absence of rods and of a continuous nerve-fibre layer, the presence of several layers of ganglion cells, and the great length and curved or oblique direction (Bergmann) of the cone-fibres in the macula lutea.

As has been mentioned above, there being no rods here, the nuclei are wanting in the inner part of the outer nuclear layer, and this is entirely occupied by the inner portions of the cone-fibres, thus forming Henle's outer fibrous layer.

The cones of the macula lutea are thinner than in the surrounding parts, and, when

viewed from the surface, stand in beautiful curved lines, converging towards the centre of the macula lutea (M. Schultze).

In the fovea centralis of all layers the cones and outer nuclei only retain their position. The cones become much attenuated and extremely long. The cone-fibres are also very long and pass in an almost horizontal direction into the inner nuclear layer *at the side* of the fovea centralis.

The inner nuclear layer, and that of the ganglion cells, is altogether wanting, and only a thin continuation of the inner granular layer is continued over the fovea centralis.

12. The Ora Serrata.

The layers of the retina terminate rather abruptly, and only the radial fibres of Müller, or their inner pyramidal extremities, becoming shortened and broader and more smooth on their surface, are continued as columnar transparent epithelial-like cells (Schwalbe), each with an oval nucleus. This forms the pars ciliaris retinæ, which, as stated on a previous page, can be traced over the processus ciliares up to the root of the iris.

The substance of the cells is more or less distinctly longitudinally striated; the nucleus, in many instances, contains within a definite membrane a spongy honeycombed reticulum and one large central nucleolus.

13. The Blood-vessels.

The capillaries of the retina are connected with the branches of the arteria and vena centralis nervi optici.

In the optic nerve the central blood-vessels are surrounded by a special plexus of fine nerve fibres (Krause).

The larger vascular branches surround the macula lutea and send into it minute twigs. At the margin of the fovea centralis the capillaries return as loops.

The arterial and venous branches are situated internally to, or within the nerve-fibre layer. The capillaries are arranged in networks with large meshes. They occur in the inner granular layer: one network near the inner nuclear layer, the other near the layer of ganglion cells; then there is a capillary network in the inner nuclear layer, and the most superficial capillaries are found in the outer granular layer.

14. The Lymphatics.

His was the first to show that the blood-vessels of the retina (chiefly the veins and capillaries) are invaginated in lymph-spaces, perivascular lymph-spaces. According to

Schwalbe they can be injected from the lymphatics of the optic nerve, that is, by injecting underneath the pial sheath of this latter.

The lymph-channels between the bundles of the nerve-fibre layer have been mentioned above; they may be also injected from the lymphatics of the optic nerve (Schwalbe), and for obvious reasons radiate from the papilla nervi optici.

15. The Lamina Cribrosa.

Where the optic nerve joins the retina, the sclerotic and chorioidea enter a very intimate relation with its sheath as lamina cribrosa. That sheath and its lymph-spaces, as well as the structure of the optic nerve, have been fully described in Chapter XIV. pp. 99 and 100.

It seems misleading to speak of a 'perforation of the membranes of the eyeball (sclerotic and chorioidea) by the optic nerve,' as the optic nerve has been connected with the retina already since the primary optic vesicle of the embryo, and the sclera and chorioidea, which develop at a later period, close, as it were, around the point of junction of the optic nerve and the retina.

In the frog the sclera and chorioidea, although closing round the optic nerve, do not penetrate into it as a lamina cribrosa, but in the mammalia and man early in the embryo the tissue of the sclera and chorioidea, especially of the former, penetrates into the optic nerve at the point of its junction with the retina.

The outer or dural sheath (Key and Retzius) of the optic nerve passes into the outer strata of the sclerotic, its connective-tissue trabeculæ being directly continuous with one another (Donders); while the middle or arachnoidal sheath and the inner or pial sheath pass into the inner strata of the sclerotic, only few trabeculæ of the pial sheath anastomose with those of the chorioidea.

In the level of the sclerotic many thinner and thicker trabeculæ of connective tissue, derived from the inner strata, pass in a transverse direction between the bundles of the optic nerve. Here they anastomose with the longitudinal connective-tissue septa between the bundles of nerve fibres, which, as mentioned on p. 100, are continuous with one another and the pial sheath. These transverse bundles form a network, and thus constitute the chief part of the lamina cribrosa; in pigmented eyes, especially in the dark eyes of mammals, they carry with them large numbers of branched pigment cells, also arranged transversely.

The longitudinal septa between the bundles of the optic nerve at the entrance into the lamina cribosa, and while in this latter, contain very numerous nucleated cells, especially abundant in the young retina (Wolfring).

The lamina cribrosa receives undoubtedly a few thin trabeculæ with pigmented cells from the chorioidea, although many histologists (Donders, Klebs, Henle, Schwalbe) deny this participation.

Outside the dural sheath of the optic nerve exists the supravaginal lymph-space. The subdural space of the optic nerve communicates with the supravaginal space by the lymph-canalicular system of the dural sheath (Michel).

The supravaginal space passes into the Tenonian lymph-space (Schwalbe), mentioned above as existing between the inner lamella of the Tenonian capsule fixed on the outer surface of the sclerotic and the outer lamella composed of the connective tissue surrounding the eyeball.

The subdural lymph-space of the optic nerve (subvaginal space of Schwalbe) extends a short distance into the sclerotic between its outer and inner section, it is generally slightly larger than the subdural space and terminates with an attenuated margin (Jäger, Michel). The sub-arachnoidal space of the sheath of the optic nerve anastomoses at the level of the lamina cribrosa with the lymph-spaces between the pial sheath and the nerve bundles (see p. 100), by means of lymph-clefts (lymph-canalicular system) of the pial sheath (Schwalbe); the intrabulbar end of the subarachnoidal space of the optic nerve communicates with the perichorioidal lymph-space of Schwalbe, which, as has been mentioned on a former page, extends between the sclerotic and chorioidea and is permeated by a spongy mass of trabeculæ, covered with endothelium and containing numerous networks of elastic fibrils. This communication between the two spaces is established by means of interfascicular lymph-clefts (lymph-canalicular system) passing in an oblique direction through the inner strata of the sclerotic (Michel).

The perichorioidal lymph-space or lymph-spaces communicate with the Tenonian space by means of lymphatics invaginating the venous vessels passing from the chorioidea outwards (venæ verticosæ). The interfascicular lymph-spaces of the sclerotic communicate both with the perichorioidal and Tenonian lymph-space (Waldeyer).

The anterior chamber of the eye does not seem to communicate directly, either with the perichorioidal or the Tenonian lymph-space, or with the lymphatic vessels of the conjunctiva.

The communication is an indirect one, by means of the lymph spaces of the cornea, sclerotic, and ligamentum pectinatum. Injections into the anterior chamber pass also into the anterior ciliary veins (Schwalbe, Heisrath).

According to the observations of Knies and Weiss, there exists a current passing from the anterior chamber of the eye through the interstitial cement-substance of the endothelium of the membrana Descemeti into the lymph-canalicular system of the cornea, or through the spaces of the ligamentum pectinatum into the sclerotic.

But also in the posterior parts of the eyeball there exists a current from behind forward including the substance of the lens, according to Weiss only the external layers of its posterior half.

REESE LIBRARY
OF THE
UNIVERSITY
OF
CALIFORNIA.

I

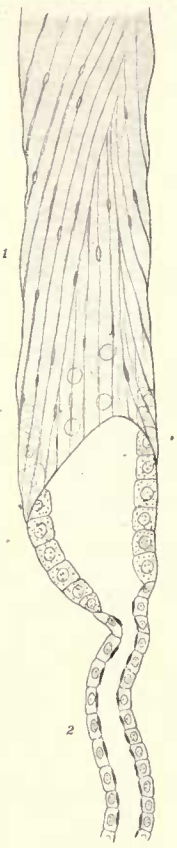

II

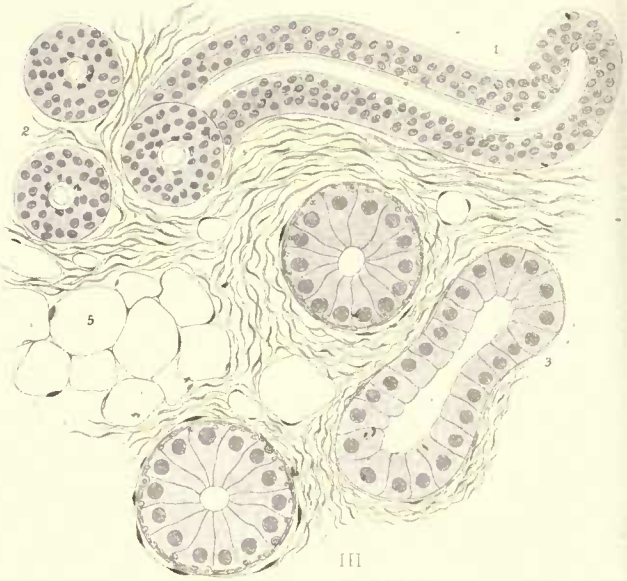

III

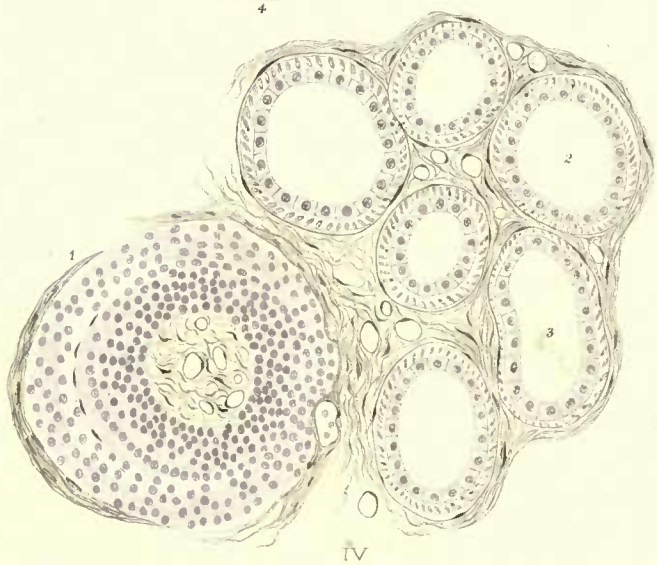

IV

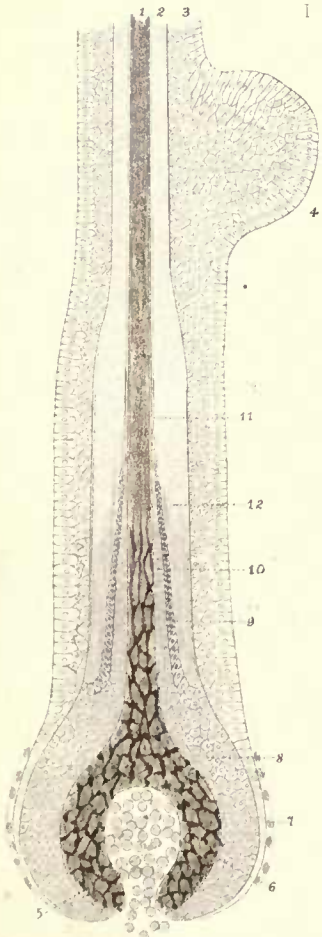

V

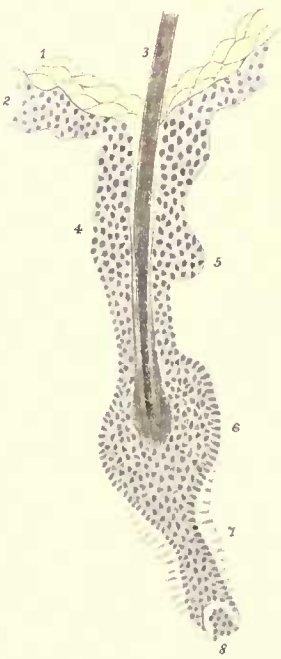

VI

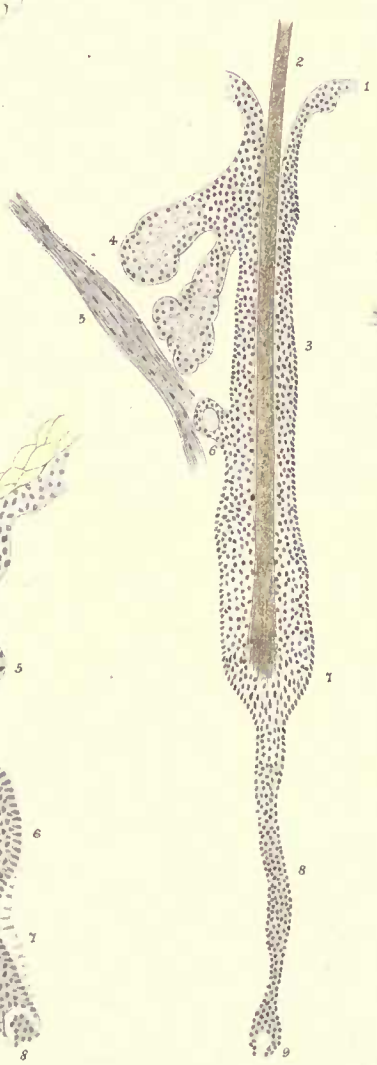

VII

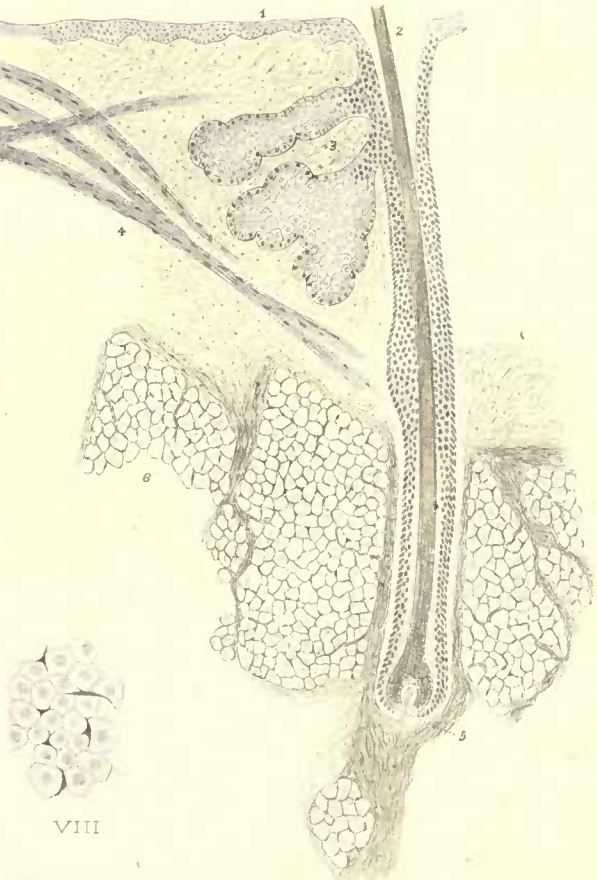

VIII

IX

PLATE XLI.

Fig. I. From a vertical section through the skin at the volar side of the human finger. Magnifying power about 40.

1. Stratum corneum.
2. Stratum lucidum.
3. Stratum granulosum.
4. Stratum Malpighii.
5. Papillary layer of the corium.
6. An interpapillary process of the stratum Malpighii continued as the duct of a sweat gland and cut away obliquely.
7. The subcutaneous tissue containing the coiled tube of the sweat glands.
8. The adipose tissue.
9. A Pacinian corpuscle in transverse section.
10. Sweat-gland tubes cut in various directions.
11. An arterial trunk cut transversely.
12. The mouth of a sweat-gland duct.
13. A tactile or Meissner's corpuscle.

Fig. II. Part of a dog's sweat gland. Magnifying power about 350.

1. The wall of the gland tube is seen from above ; it shows a layer of longitudinal very thin unstriped muscle cells.

2. The duct is lined with a cuticle and a layer of nucleated polyhedral cells. The point where it opens into the gland tube is well marked by the alteration in size and by the difference of the lining epithelium.

Fig. III. A part of the layer 7 of figure I. highly magnified (about 400), to show the structure of the coiled tube of the sweat gland. This consists of two different portions, a proximal and distal one. The former is nearer the duct, possesses the same structure as this, but differs from it by being coiled; its lumen is lined with a thick homogeneous membrane; then follow several layers of small polyhedral cells, of which only the nuclei are here shown. A limiting membrana propria forms the outer boundary. The distal portion is composed of a coiled tube much broader than the former ; its lining epithelium is a layer of columnar transparent or longitudinally striated cells. Between this and the limiting membrana propria is a longitudinal layer of thin unstriped muscle cells.

1. Proximal part of the coiled tube in longitudinal,

2. The same in transverse section.

3. Distal part cut longitudinally.

4. The same cut transversely. The muscular cells inside the membrana propria are not represented with sufficient distinctness.

5. Fat-cells.

Fig. IV. Coiled tube of sweat gland in section, from the ear-lobe of pig. Magnifying power about 300.

1. A hair-follicle in transverse section.

This is cut at the papilla, which with its capillary blood-vessels is seen in the centre; it is surrounded by the cells—indicated by its nuclei—of the bulb of the hair. Then follows a thick layer of nuclei indicative of the cells of the external root-sheath, and finally the inner coat of the hair-sac. Between the bulb of the hair and the external root-sheath is seen at one side a rudiment of the inner root-sheath in the form of a layer of flattened cells.

2 and 3. The coiled tube in transverse and oblique section. The layer of unstriped muscle cells between the lining epithelium and the membrana propria is well shown.

Between the coils of the tube is fibrous connective tissue with many capillary blood-vessels.

Fig. V. From a vertical section through the scalp of a fully developed human embryo, showing a papillary hair and its root-sheaths. The figure comprises the region of the neck, but not that of the mouth of the hair-follicle. Magnifying power about 300.

1. The substance of the hair.

2. The inner root-sheath. Between 1 and 2 the cuticle of the hair.

3. The layers of the outer root-sheath.

4. The rudiment of the sebaceous gland.

5. The papilla, its cells indicated by their nuclei.

6. The bulb of the hair; the outlines of its polyhedral cells are marked by brown pigment granules embedded in the interstitial cement-substance. As the cells of the bulb elongate to form the cells of the hair substance, also the configuration of the intercellular pigmented cement-substance alters accordingly.

7. The transverse layer of unstriped muscle cells of the hair-sac, indicated here by their nuclei.

8. The layers of polyhedral cells from which the cuticle of the hair and the various layers of the inner root-sheath are developed and at whose expense they continue to grow.

9. A layer of spindle-shaped cells, here cut transversely because they are arranged transversely on the long axis of the hair.

10. Cells continuous with the cuticle of the hair and the cuticle of the inner root-sheath.

11. Cuticle of the hair.

12. Thick homogeneous-looking inner root-sheath; its division into Henle's and Huxley's layer is not shown here.

Fig. VI. Longitudinal section through a bed-hair of the lip of a newborn child. Magnifying power about 90.

1. Stratum corneum of the epidermis.
2. Stratum Malpighii.
3. Hair shaft projecting from the mouth of the hair-follicle.
4. The outer root-sheath.
5. The rudiment of the sebaceous gland.
6. The enlargement of the outer root-sheath around the hair-knob.
7. The rudiment of the new hair, being an outgrowth of the outer root-sheath; it is surrounded by the unstriped muscle cells of the hair-sac.
8. The rudiment of the new papilla.

Fig. VII. Longitudinal section through a bed-hair of the adult human scalp. Magnifying power about 60.

1. Epidermis of the mouth of hair-follicle.
2. Hair shaft.
3. Outer root-sheath.
4. Alveoli of the sebaceous gland.
5. Musculus arrector pili.
6. A cystic outgrowth of the outer root-sheath.
7. The hair-knob.
8. The rudiment of the new hair.
9. The rudiment of the new papilla.

Fig. VIII. Surface view of part of the outer root-sheath of a cilium of a newborn child, to show the branched cells between the epithelial cells of the outer root-sheath. Magnifying power about 300.

Fig. IX. Longitudinal section through a papillary hair of the adult human scalp. Magnifying power about 60.

1. Epidermis of the general surface; only its stratum Malpighii is here indicated.
2. The mouth of the hair-follicle.
3. The alveoli of the sebaceous gland.
4. The bundles of the arrector pili.
5. The papilla.
6. Adipose tissue.

PLATE XLII.

Fig. X. Transverse section through two hairs of the paw of a fœtal kitten. Magnifying power about 300.

A is a section through a thicker hair and is further away from the hair-papilla than B.

1. The cells of the substance of the hair.
2. The cuticle of the hair.
3. The cuticle of the inner root-sheath.
4. The inner or Huxley's layer.
5. The outer or Henle's layer.
6. The cells of the outer root-sheath, indicated by their nuclei.
7. The circular layer of the hair-sac.
8. Lymph-space.
9. The surrounding connective tissue.

Fig. XI. Longitudinal section through the hair of the lip of a fœtal rabbit. Magnifying power about 300.

1. The hair-papilla is indicated by the nuclei of its cells; a few branched cells are seen amongst them, similar ones are also extending between the cells of the hair bulb.
2. The hair-bulb, its cells indicated by their nuclei.
3. The marginal layer of cells of the outer root-sheath at the bulb.

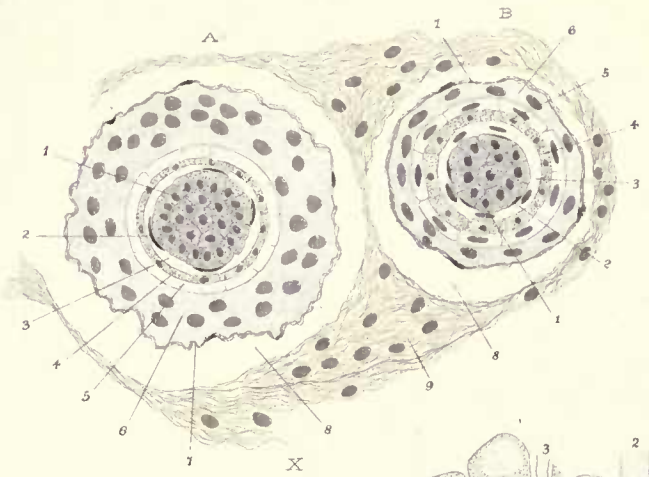

X

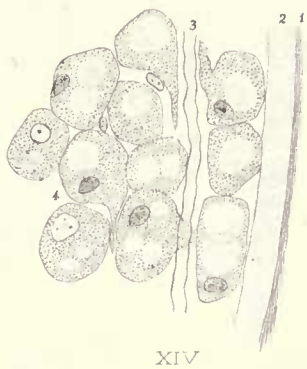

XIV

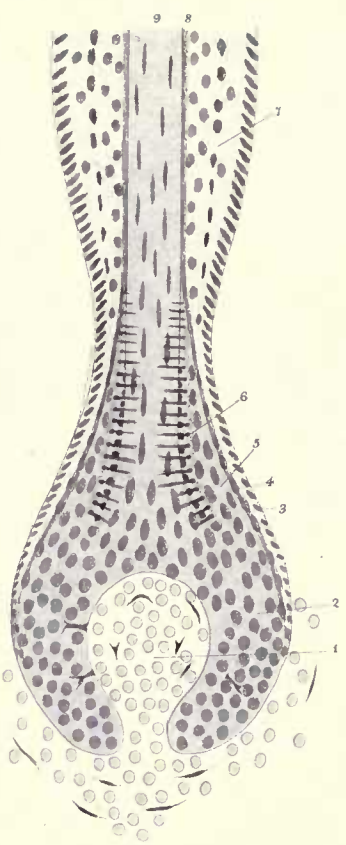

XI

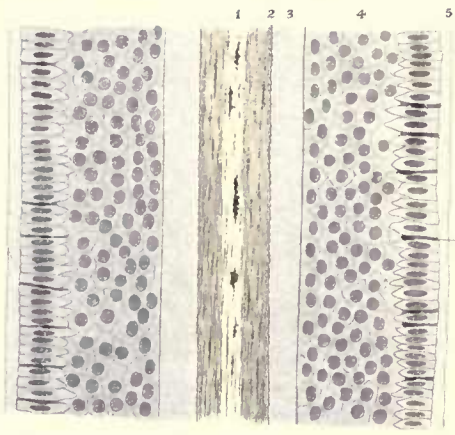

XII

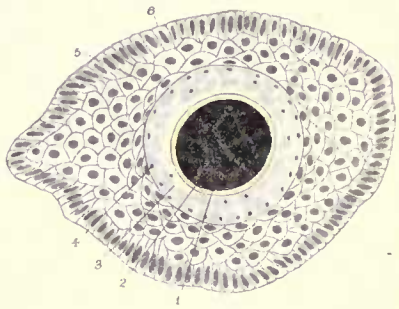

XV

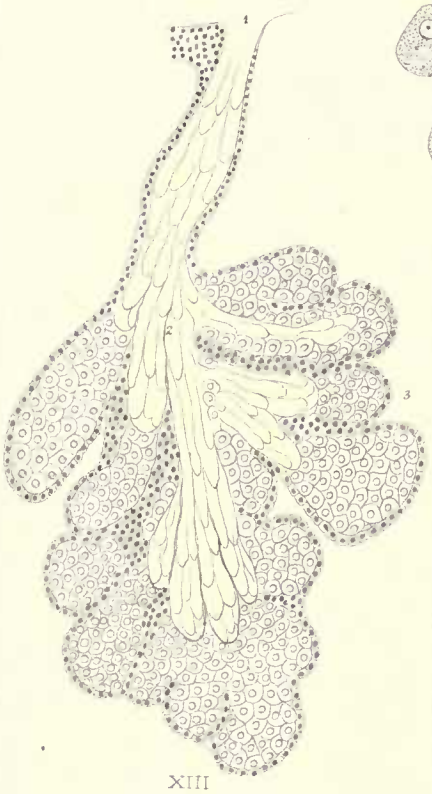

XIII

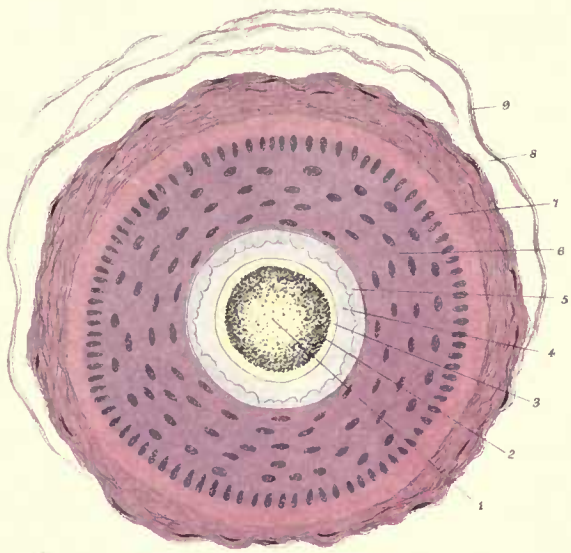

XVI

XVII

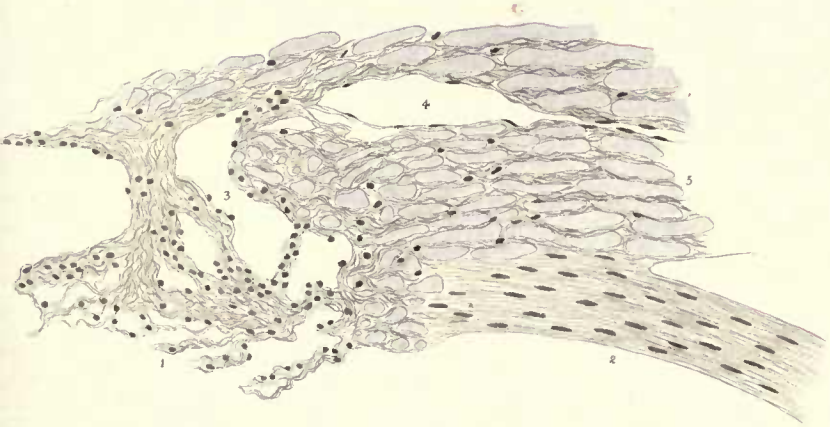

XVIII

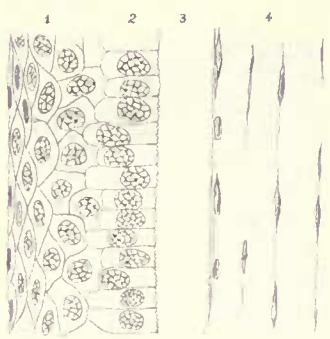

XIX

XX

E. Noble Smith, fecit

Mintern Bros imp

4 and 5. The cells from which the inner root sheath is formed.

6. The layer of transversely arranged spindle-shaped cells, which have been referred to in the text as resembling unstriped muscle cells.

7. The outer root-sheath.

8. The rudiment of the inner root-sheath.

9. The hair substance.

Fig. XII. From a longitudinal section through a cilium of a newborn child. Magnifying power about 400.

1. The hair substance, rows of pigment granules in it; the marrow is indicated as a clear central part with a few (large) groups of air-bubbles.

2. The cuticle of the hair.

3. The inner root-sheath, its constituent parts not differentiated here.

4. The cell-layers constituting the outer root-sheath.

5. The glassy membrane.

6. Intraepithelial connective-tissue cells.

Fig. XIII. A sebaceous gland from a vertical section through the lip of mouth of the sheep. Magnifying power about 200.

1. The duct.

2. The branches of it.

3. The alveoli.

The minute details of structure of the cells of the alveoli are not indicated here The distinction between the nucleated cells filling the alveoli themselves and their remnants in the branches of the duct is here too sharp.

Fig. XIV. From a section through a lobule of fœtal subcutaneous fat-tissue. Magnifying power about 450.

1. Part of the connective-tissue septum between two fat-lobules.

2. Lymph-space.

3. A capillary blood-vessel.

4. Fat-cells in various stages of formation, filled with oil globules, dissolved out in the preparation from which this drawing is obtained. Some of the cells are distinctly possessed of processes.

Fig. XV. Transverse section through the hair of ear lobe of the pig. Magnifying power about 350.

1. The pigmented substance of the hair.
2. The cuticle of the hair.
3. Huxley's layer of the inner root-sheath.
4. Henle's layer of it. Many of the cells of both contain a remnant of a nucleus.
5. The cell-layers of the outer root-sheath.
6. The marginal layer of columnar cells with oval nuclei.

Fig. XVI. Transverse section through the hair and hair-follicle of the adult human scalp. Magnifying power about 350.

1. The marrow.
2. The pigmented substance of the hair.
3. The cuticle of the hair; next to this is a delicate line, indicating the cuticle of the inner root-sheath.
4. Huxley's layer.
5. Henle's layer of the inner root-sheath.
6. The outer root-sheath.
7. The glassy membrane; next to this is the circular coat of the hair-sac.
8. A lymph-space between the circular coat of the hair-sac and the connective tissue forming its outer coat.

Fig. XVII. Vertical section through the eyelid of a newborn child. Magnifying power about 25.

1. The conjunctiva palpebræ; its epithelium is indicated as a purple line. The mucosa is represented much too thick.
2. The mouth of the duct of a Meibomian gland.
3. The cilia.
4. The skin of the lid; sweat glands and hairs are only faintly indicated as prolongations of the stratum Malpighii.
5. The bundles of the sphincter orbicularis in transverse section.
6. The inner and outer bundles of the musculus ciliaris Riolani; between the two passes the duct of the Meibomian gland. The alveoli of this latter appear all cut away in various directions.

Fig. XVIII. From a vertical section through the ligamentum pectinatum iridis and the adjoining portion of the sclerotic and ciliary muscle. Magnifying power about 200.

1. The spongy mass of elastic trabeculæ forming the matrix of the ligamentum

REESE LIBRARY
OF THE
UNIVERSITY
OF
CALIFORNIA

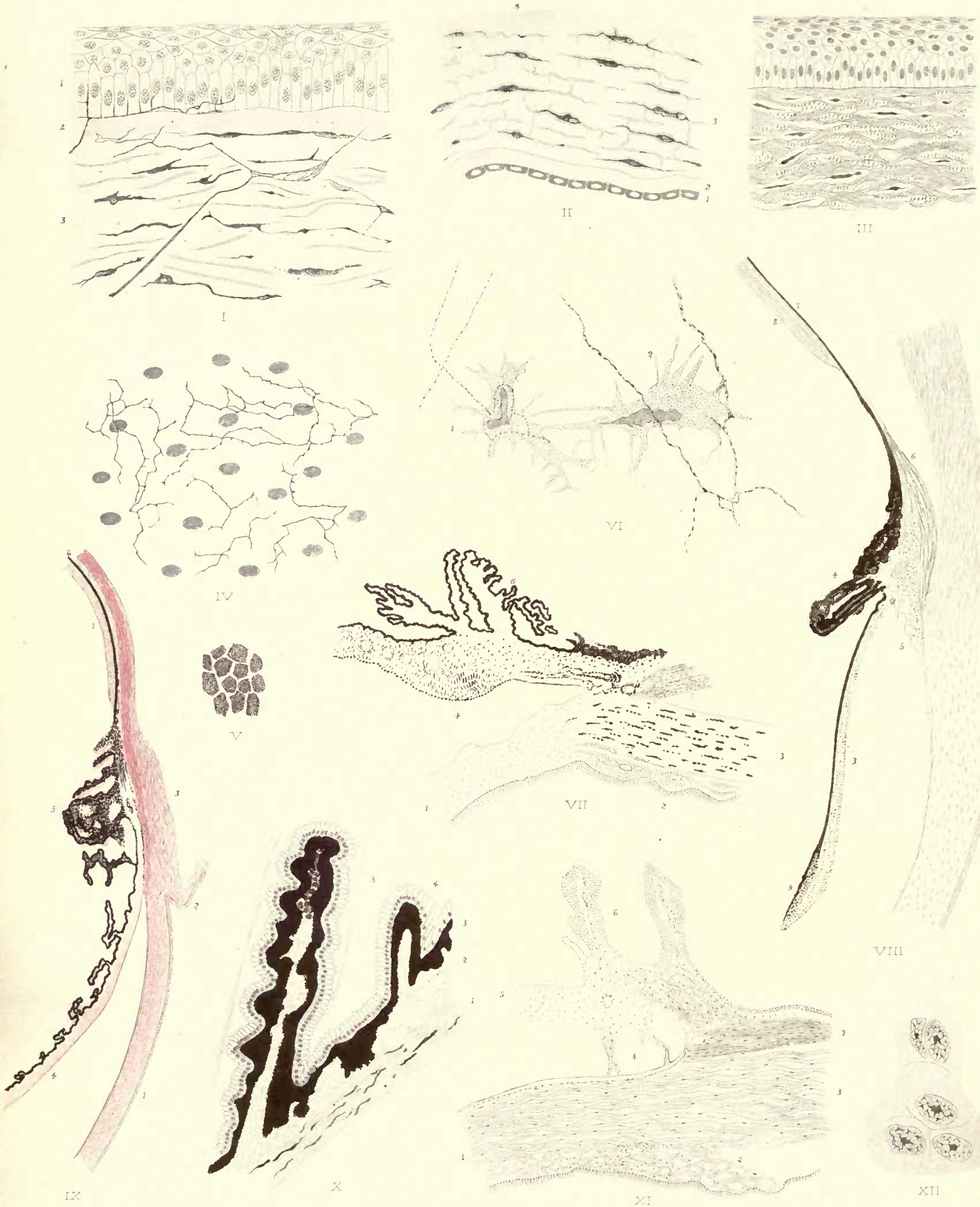

E. Noble Smith, fecit. Mintern Bros. imp.

pectinatum. The nuclei seen on them correspond to the endothelial cells covering them.

2. The meridional portion of the ciliary muscle.

3. The spaces in the spongy matrix of the ligamentum pectinatum.

4. The canal of Schlemm, lined with an endothelial membrane and giving off to the right a narrow channel.

5. The bundles of the sclerotic in transverse section; between them are seen the nuclei of the connective-tissue corpuscles and networks of elastic fibrils joining those of the trabeculæ of the ligamentum pectinatum and of the tendon of the ciliary muscle.

Fig. XIX. From a vertical section through the anterior layer of the cornea of a newborn child. Magnifying power about 350.

1. The stratified pavement epithelium.

2. The deepest layer of columnar cells.

3. The anterior elastic membrane of Bowman.

4. The anterior strata of the substantia propria, with the corneal corpuscles seen in profile.

Fig. XX. From a vertical section through the anterior layers of the cornea of the rabbit after staining with chloride of gold. Magnifying power about 200.

1. The stratified epithelium; many of the intraepithelial nerve fibrils are shown, especially those which run horizontally, that is parallel to the surface, in the superficial layer.

2. Long fine nerve fibrils of the subepithelial network derived from a thick branch further down. Some of them appear as if belonging to the deepest layer of the epithelium, but this is due to the fact that fibrils are here shown which in reality lie underneath the epithelium.

3. The anterior strata of the substantia propria.

PLATE XLIII.

Fig. I. From a vertical section through the anterior portion of the cornea of the rabbit, stained with chloride of gold and hæmatoxylin. Magnifying power about 400.

1. The stratified anterior epithelium.

2. Bowman's membrane.

3. Substantia propria; the connective-tissue ground-substance is indicated as of a

uniform tint, in it a few elastic fibrils; the corneal corpuscles are seen in profile, and therefore appear as thin elongated corpuscles. A nerve branch ascends obliquely from the depth and near Bowman's membrane gives off fine fibrils. In this latter are seen three black dots; they are transverse sections through fine nerve fibrils running in that membrane in a horizontal direction. A thin ramus perforans passes right through Bowman's membrane on the left of the figure, and gives off fine fibrils running closely underneath the epithelium and forming part of the subepithelial network. A few intraepithelial nerve fibrils ascend between the columnar cells of the deepest layer.

Fig. II. From a vertical section through the same cornea, but showing the posterior layers.

1. The endothelium of Descemet's membrane.
2. Descemet's membrane.
3. The substantia propria; the corneal corpuscles in their lymph-canalicular system are well shown. Some of the canaliculi join the lacunæ of different strata.

Fig. III. From a vertical section through the anterior part of the cornea of the dog. Magnifying power about 300.

1. The stratified epithelium.
2. A delicate Bowman's membrane.
3. The substantia propria. Between longitudinally cut bundles of the connective-tissue matrix there are shown numerous others cut transversely. The lacunæ with the corneal corpuscles are shown in profile.

Fig. IV. From a horizontal section through the cornea of the rabbit, stained with chloride of gold, showing the superficial layer of the epithelial cells, indicated by their oval nuclei only, and underneath it the fine intraepithelial nerve fibrils. Magnifying power about 400.

Fig. V. A few pigmented epithelial cells of the uvea of a processus ciliaris of a newborn child, seen from the surface. The clear interstitial cement-substance is well marked. Magnifying power about 300.

Fig. VI. From a horizontal section through the substantia propria of the frog's cornea, stained with chloride of gold. Magnifying power about 450.

1. Fine nerve fibrils terminating in a minute network, not *in*, but *on* a corneal corpuscle.

2. A second corneal corpuscle simply crossed by nerve fibrils. On the right the nerve fibril does not actually terminate in the substance of the corpuscle; it is in reality above the corpuscle.

Fig. VII. From a meridional section through the eye of the ox. Magnifying pow er about 30.

1. Cornea.
2. Conjunctiva, at the limbus containing diffuse adenoid tissue.
3. Sclerotic; the connective-tissue corpuscles contain much pigment.
4. Root of iris.
5. Ciliary muscle; only its meridional portion is here shown.
6. Ciliary process.

Fig. VIII. From a meridional section through the eye of a child. Magnifying power about 40.

1. Cornea.
2. Sclerotic.
3. Iris.
4. Ciliary process.
5. Ligamentum pectinatum.
6. Meridional portion of the ciliary muscle, its bundles forming plexuses. The radiating portion is shown as minute dots—because transversely cut—between the meridional portion and the ciliary process.
7. Chorioidea.
8. Retina of the ora serrata.
9. Sphincter pupillæ.

Fig. IX. From a meridional section through the eye of a sheep. Magnifying power about 30.

1. Cornea.
2. Conjunctiva of the limbus.
3. Sclerotic.
4. Iris; the pigment of its tissue and of its anterior epithelium has been omitted.
5. Ciliary process. Numerous folds are seen on the posterior surface of this as well as of the iris.

6. Chorioidea with the uvea.

7. Retina.

Fig. X. From a vertical section through the ciliary processes of the eye of the ox. Magnifying power about 200.

1. Dense fibrous matrix with pigmented connective-tissue corpuscles.
2. Loose connective tissue; the capillary blood-vessels in it are omitted.
3. The uvea.
4. Pars ciliaris retinæ, a layer of columnar cells.
5. Zonula ciliaris with bundles of fibres in it.

Fig. XI. From a meridional section through the eye of an albino rabbit. Magnifying power about 60.

1. Cornea.
2. Conjunctiva of the limbus.
3. Sclerotic.
4. Ligamentum pectinatum.
5. Root of the iris.
6. Ciliary processes, covered with the unpigmented uvea; its cells appear stratified because viewed obliquely.
7. Meridional portion of the ciliary muscle.

Fig. XII. A few of the cells of the pars ciliaris retinæ of the same preparation as in Figure X., but viewed from the top. The markings between the cells are not perfect; the nucleus of the cells contains a distinct reticulum and nucleolus. Magnifying power about 660.

PLATE XLIV.

Fig. XIII. From a horizontal section through the rabbit's cornea, stained with chloride of gold, showing two oval nuclei of the superficial epithelial cells, and fine nerve fibrils terminating in a very delicate network. Magnifying power about 660.

Fig. XIV. From a horizontal section through the substantia propria of a rabbit's cornea, stained with chloride of gold, showing several corneal corpuscles and fine nerve fibrils crossing them. Magnifying power about 450.

Fig. XV. Branched pigmented connective-tissue corpuscles of the tissue of the iris of the ox, seen from the surface.

Fig. XVI. The same seen in profile.

XIII

XIV

XV

XVI

XIX



XVII

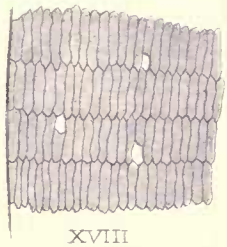

XVIII

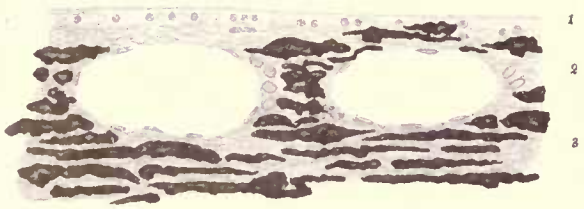

XX

XXI



XXIII



XXII

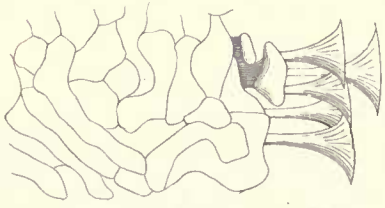

XXIV

XXV

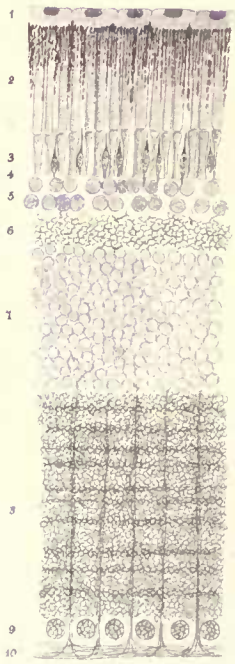

XXX

XXVI

XXVII

XXVIII XXIX

REESE LIBRARY
OF THE
UNIVERSITY
OF
CALIFORNIA.

Fig. XVII. Pigmented connective-tissue cells of the deep tissue of the chorioidea of the same eye; the cells are very little branched. Magnifying power in all three figures about 350.

Fig. XVIII. From a transverse section through the lens of a dog's eye, showing the lens fibres transversely cut and arranged in strata. The three angular openings correspond probably to lymph channels running parallel with the lens fibres. Magnifying power about 350.

Fig. XIX. Copy of part of Figure IX. by Iwanoff in the 'Handbuch d. gesam. Augenheilkunde,' by Graefe and Saemisch, part i. p. 280. Showing groups of ganglion-cells in the nerve plexus of the chorioidea of an adult.

Fig. XX. Transverse section through the chorioidea of the ox. Magnifying power about 250.

1. Chorio-capillaris. Outside this is a layer of elastic fibrils, Sattler's layer, shown on the left side of the figure.
2. The layer of large veins, venæ vorticosæ.
3. The outer layer containing numerous pigmented connective-tissue cells flattened in a direction parallel to the surface.

Fig. XXI. From a vertical section through the eye of a sheep's fœtus. Magnifying power about 30.

1. The rudiment of the eyelid.
2. The sclerotic continued into the cornea.
3. The outer layer of the optic cup, or the pigmented epithelium of the retina.
4. The rudiment of the retina.
5. The epithelium lining the anterior capsule of the lens. At the margin the cells pass into the lens fibres. The nuclear zone of the latter is well shown.
6. The posterior portion of the lens fibres.
7. The rudiment of the corpus vitreum with capillary blood-vessels.

Fig. XXII. From a transverse section through the eye of the sheep. Magnifying power about 100.

1. Inner portion of the sclerotic.
2. Suprachorioidal lymph-space, permeated by lamellæ with pigmented cells.
3. Outer layer of the chorioidea, containing numerous pigment cells.
4. Sattler's layer.

5. The tapetum nigrum, or epithelium of the retina.
6. The layer of the rods and cones.
7. Limitans externa.
8. The outer nuclear layer.
9. The outer granular or outer molecular layer.
10. The inner nuclear layer.
11. The inner granular layer.
12. The layer of the ganglion cells.
13. The layer of the nerve fibres.

The radial or Müller's fibres passing through the two last-named layers are well shown.

Fig. XXIII. Transverse section through the retina of the dog. Magnifying power about 350.

1. The rods and cones.
2. Limitans externa.
3. The outer nuclei.
4. The outer granular layer.
5. The inner nuclei.
6. The inner granular layer.
7. The ganglion cells.
8. The nerve fibres.
9. The limitans interna, being composed of the ends of the radial or Müller's fibres.

Fig. XXIV. Copy of part of fig. XVI. from Schwalbe in 'Handbuch d. ges. Augenh.' by Graefe and Sameisch, p. 371, showing part of the inner surface of the human retina, stained with argentum nitricum. On the right side the radial fibre-cones project with their free basis.

Fig. XXV. From a vertical section through part of the frog's retina. Magnifying power about 350.

1. The outer member of the rods.
2. The inner member, between them the cones.
3. The limitans externa.
4. The honeycombed matrix, in whose meshes are contained the outer nuclei.
5. A nucleus belonging to a connective-tissue corpuscle at the inner boundary of the reticular outer granular layer.

6. A few of the inner nuclei. The spindle-shaped cells of which they form part have been omitted.

Fig. XXVI. Two radial Müller's fibres of the retina of the rabbit. Magnifying power about 400.

1. The layer of the outer nuclei.
2. The layer of the inner nuclei. The oval nuclei here shown belong to the radial fibres.
3. The connection of the radial fibres with the matrix of the inner granular layer.
4. The region of the ganglion cells. Here the radial fibres overlap each other in the preparation, and appear therefore in the drawing as if they formed a single fibre. The inner extremity of the fibres is not shown.

Fig. XXVII. From a vertical section through the retina of the rabbit. Magnifying power about 400.

1. The region of the outer nuclei.
2. The outer granular layer.
3. The inner nuclei.
4. The nucleus of a connective-tissue corpuscle.
5. The inner granular layer. Its reticular matrix is well shown.
6. The inner extremities of the radial or Müller's fibres.
7. The limitans interna formed by the inner free surface of the radial fibres.

Fig. XXVIII. A ganglion cell from the same retina as that represented in fig. XXIII. Magnifying power about 660.

1. The outer processes of the ganglion cell terminate apparently in the reticulum of the inner granular layer.
2. The body of the ganglion cell.
3. Nerve fibres.

Fig. XXIX. Two ganglion cells of the same retina as in the preceding figure.

1. Inner granular layer.
2. The ganglion cells.
3. A blood-vessel in transverse section.

4. A portion of a Müller's fibre indicated only.

5. The nucleus of a connective-tissue corpuscle.

Fig. XXX. Transverse section through the frog's retina. Magnifying power about 150.

1. The pigmented epithelium of the retina; the outer part is unpigmented and includes the oval nucleus.

2. The outer members of the rods, ensheathed in the pigmented filaments of the cells of the epithelium.

3. The inner members of the rods and the cones between them.

4. The region of the limitans externa.

5. The outer nuclei.

6. The outer granular layer.

7. The inner nuclei. They are represented incorrectly too small.

8. The inner granular layer, showing stratification.

9. The nuclei of the ganglion cells.

10. The nerve fibres.

The pyramidal extremities of the radial fibres are well shown.

CHAPTER XXXIX.

THE OUTER AND MIDDLE EAR.

THE cartilaginous matrix of the *auricula* has been described in Chapter VIII. as reticular or elastic cartilage. The skin covering it is in no way different from that of other parts.

It is continued into the *meatus auditorius externus*, where it differs in so far as the ordinary sweat glands are replaced by the larger ceruminous glands, which have been described in a former chapter, p. 315.

Towards the membrana tympani the hairs and their sebaceous glands become scarcer, and the corium much thinner. The subcutaneous tissue in both the cartilaginous and osseous portion is so firmly connected with the connective tissue of the perichondrium or periosteum respectively, that it may be regarded as part of these.

The cartilage of the meatus auditorius externus is elastic cartilage, being a direct continuation of the cartilage of the auricula.

THE MEMBRANA TYMPANI.

The *membrana tympani* consists of an outer, middle, and inner lamella. The first is a direct continuation of the skin of the meatus auditorius externus, the second is the membrana propria, and the third is the mucosa. The skin part is a delicate membrane composed of delicate bundles of connective tissue covered with a thin epidermis. This last-named differs in no way in structure from that of the meatus auditorius externus. The papillæ of the corium present in this latter do not pass beyond the margin, i.e. the tendinous ring of the membrana tympani, except at the posterior upper part, where they extend as far as the processus brevis of the malleus.

The membrana propria, or middle stratum, contains, besides a limited number of elastic fibrils and elastic membranes (Helmholz), stiff bundles of connective tissue similar to tendinous tissue grouped as larger or smaller trabeculæ. They possess either a radiating arrangement, as in the layer next to the cutis, or a circular one, as in that next to the mucosa, or they pass in various directions and branch out either into the one or the other.

Some of those of the outer and inner layer run out into the skin part and into the mucosa.

Between the trabeculæ are left longer or shorter clefts, and larger or smaller saccular sinuses lined with endothelium, and forming an inter-communicating system of lymphatic vessels (Kessel).

The membrana propria is wanting in the fissure or notch of Rivini.

The mucosa is a very delicate connective-tissue membrane, covered with a single layer of squamous nucleated epithelial cells; groups of small cells are interspersed amongst the others. Small stomata exist between them (Kessel).

The blood-vessels form capillary networks for the skin part as well as for the mucosa, and for the membrana propria; these networks anastomose with each other (Gerlach, Kessel, and others). The venous vessels empty themselves into the plexus of veins at the margin of the membrana tympani, and into the venous plexus surrounding the handle of the malleus.

The lymphatics are also arranged in three layers (Kessel):

a) A subepithelial network of fine vessels in the cutis.

b) A similar one in the mucosa; and

c) The inter-communicating system of wide lymphatics of the membrana propria.

The latter anastomose with either of the other two.

There is a lymph-canalicular system of lacunæ and canaliculi in the connective tissue of the mucosa and membrana propria of the same nature as that described of the serous membranes (Kessel).

Kessel found also that the movement of the membrana tympani assists in the absorption by the lymphatics from the tympanic cavity.

The (non-medullated) nerves are arranged as plexuses of the cutis, of the membrana propria, and of the mucosa. The finest fibres form a subepithelial network both for the cutis and the mucosa, and from it pass fibrils amongst the epithelial cells (Kessel).

The capillary blood-vessels are everywhere crossed and accompanied by fine nerves; they are connected into a plexus and provided with pear-shaped or triangular nucleated cellular (ganglionic) enlargements (Kessel), which appear to enter into an intimate relation with the blood capillaries.

Kessel could not ascertain their real termination in the capillaries.

The Tuba Eustachii.

The mucous membrane lining the tuba is a continuation of that of the upper or nasal part of the pharynx, and as such consists of the epithelium, the mucosa, and the submucous tissue.

The epithelium consists of two or three layers of elongated spindle-shaped or

conical cells, of which the top layer is conical and ciliated. Amongst these a good many mucous-secreting goblet cells are found.

A very delicate basement membrane separates the epithelium from the mucosa. This is a delicate membrane composed of fine bundles of connective tissue with the connective-tissue cells and a few elastic fibrils. The mucosa of the membranous portion of the human tuba in the young condition contains groups of lymph-follicles (Gerlach), thus forming the tuba-tonsils of v. Teutleben. In the adult tuba the lymphatic tissue does not form well-defined follicles, but possesses more the character of diffuse adenoid tissue (v. Teutleben).

The submucosa contains, in man and most mammals, besides a plexus of wide lymphatics, numerous compound tubular mucous-secreting glands, identical in structure with those of the pharynx and palate. These glands are absent in the semicylindrical space below the cartilage of the tuba, which by Rüdinger is called the safety tube. The mucous membrane is here very thin, and appears composed entirely of thin lamellæ with endotheloid connective-tissue corpuscles.

The striated fibres of the musculus dilatator tubæ do not end in the submucous tissue (Rüdinger), but the tendon is fixed on the perichondrium of the hook-shaped end of the cartilage plate. But some fibres of the musculus levator veli palati terminate in the submucous tissue of the distal part of the tuba. A dense network of capillaries supplies the mucosa in the same manner as is the case in the mucosa of the pharynx.

The cartilage of the tuba in man and most mammals is in its chief portion hyaline cartilage of the ordinary description, with the usual inner and outer perichondrium. In the adult state in most places groups of fine elastic fibres anastomosing into a network may be seen to pass from the inner perichondrium, i.e. that next the mucous membrane, in a vertical direction through the hyaline ground-substance towards the outer perichondrium. The number of the elastic fibrils is greater in the hook-shaped part than in the rest of the plate. Thus this cartilage approaches to a great extent to the reticular or elastic cartilage, and for this reason has been associated with the latter in Chapter VIII. p. 51.

The Cavum Tympani.

The cavum tympani and the cellulæ mastoideæ are lined with a delicate mucous membrane, whose deeper portion acts at the same time as the periosteum.

The epithelium of the promontorium, the ossicula auditus, the roof of the cavum tympani, and the cellulæ mastoideæ, like that of the mucosa of the membrana tympani, is a single layer of more or less flattened polyhedral cells; in all other parts

it is similar to that of the tuba Eustachii, viz. stratified and columnar, consisting of a top layer of ciliated conical cells, between the extremities of which are pushed in spindle-shaped cells, and the thin extremities of inverted conical cells, which, with their nucleated basis, form the deep boundary of the epithelium (see Chapter II.). Among the superficial cells are goblet cells.

The mucosa underneath the epithelium is a dense fibrous membrane, containing, besides the lymph-canalicular system and its lining branched cells, a rich network of blood capillaries, networks of fine non-medullated nerve fibres, and lymphatic sinuses and tubes lined with endothelium (Kessel).

v. Tröltsch and Kessel mention simple mucous-secreting glands as being present in the mucous membrane of the human cavum tympani.

The larger nerve branches of the plexus tympanicus, situated in the deep tissue of the mucous membrane of the cavum tympani and of the cellulæ mastoideæ, are composed of medullated nerve fibres, and they are associated with larger or smaller groups of ganglion cells either placed in the course of the branches or at the point of their anastomosis (Pappenheim, Kölliker, Krause, Kessel).

The numerous thicker and thinner, simple or complex connective-tissue trabeculæ, which in the cavum tympani and in the cellulæ mastoideæ traverse the respective cavities extending like bridges between the mucosa of neighbouring osseous projections, and in most places acting as the carriers of blood-vessels or nerves, are ensheathed in a single layer of polyhedral epithelial cells continuous with those of the mucosa. In some places these trabeculæ acquire a large size, as in the ligaments of the malleus. In connection with such trabeculæ, projecting from the floor of the cavum tympani, in the cellulæ mastoideæ, and especially about the stapes, Kessel observed peculiar oval bodies of various sizes, consisting of a central fibrous axial cord, around which fibrous lamellæ are arranged concentrically, and between these are clefts filled either with a homogeneous or granular matter, or with spindle-shaped-looking elements. Generally the axial cord having passed through more than one of these oval bodies, or having entered one, splits up into several branches, each of which may again become the axial cord of an oval body. The nature of these bodies, although resembling in a limited sense Pacinian corpuscles, is not ascertained.

CHAPTER XL.

THE INTERNAL EAR.

Of this only the membranous labyrinth will be considered here, since the osseous part does not require any special histological description.

The Utricle, Saccule, and the Semi-circular Canals.

These agree on many points in their arrangement and structure. They all have an excentric position within their bony equivalent, being much closer placed against the bone of one side than of the other, so that the perilymph is accumulated chiefly at one side of them.

The utricle lies closer to the median wall of the vestibule, the saccule less so, while the membranous semi-circular canals are placed closely against the convex side of the bony canals. In all instances the periosteum lining the inner surface of the bone sends out thicker or thinner trabeculæ connected into a spongy fenestrated tissue, the ligaments of Rüdinger, which surrounding the (membranous) wall of the several structures, viz. utricle, saccule, and semi-circular canals, fix these latter very firmly to the bone. In man and mammals other similar but thinner trabeculæ joined into a fenestrated spongy tissue extend, generally only on one side, from the membranous wall to the periosteum of the further side. In the rat the whole space of the perilymph is occupied by this tissue. The free surface of the periosteum and that of the above ligaments and of the other trabeculæ is covered with a continuous layer of endothelium (Key and Retzius). Numerous vessels are carried by these trabeculæ, and there are present in them nucleated cells of various sizes, some of them very large and granular and corresponding to plasma cells.

The trabeculæ consist of bundles of fibrous tissue, which by repeated crossing and reuniting are arranged in a spongy substance, completely resembling that described of the subarachnoidal tissue of the spinal cord.

The structure of the wall of the utricle, saccule and semi-circular canals is the same. The above-named fibrous ligaments of the periosteum form the outer or fibrous coat; inside this is the tunica propria, a glassy-looking membrane, which is thinnest at the side that is next the bone. In the adult organs the membrana propria is raised

above the internal surface as numerous papillary projections (Rüdinger) of various sizes and composed of a hyaline or slightly fibrillar tissue. These projections are absent next to the bone (Rüdinger, Utz). A single layer of flattened nucleated epithelial cells covers the inner free surface.

In the whole extent of the nerve-entrance into the utricle, saccule, and the ampullæ, the wall of these projects into the interior as a peculiar thickening known as the *macula acustica* in the utricle and saccule and as the *crista acustica* in the ampullæ (M. Schultze).

The branches of the nervus vestibuli are in connection with ganglionic masses, and having passed through the tunica propria reach the macula or crista acustica respectively. Here they run in small bundles separated by spindle-shaped and branched cells; they ascend towards the surface.

Before they reach the basement membrane, at any rate in the macula acustica of the guinea-pig, they have to pass through a layer of small cells with oval nuclei. This layer is of considerable thickness and may be appropriately called the nuclear layer; in it the medullated nerve fibres form plexuses in a vertical direction. (See fig. VII. of Plate XLV.)

The individual nerve fibres remain medullated up to the basement membrane, situated immediately underneath the epithelium; they lose their medullary sheath when perforating the basement membrane—in some places already before—and their axis-cylinders split up into a number of fine fibrils connected into a network; this network lies within the epithelium of the macula and crista. The epithelium is here pigmented, and of a slightly yellowish tint, much thickened, and consisting, as shown by M. Schultze, of a superficial layer of conical or cylindrical *epithelial cells*, between which are situated spindle-shaped *sensory cells* with a spherical or oval nucleus. Each of the sensory cells possesses an outer thick process extending to the free surface and projecting as a long stiff pointed hair or rod, the acoustic hair, into the endolymph (M. Schultze, Odenius, Kölliker, Hasse, and others); the inner process is very thin and filamentous, and is connected with the fine nerve-fibrils of the intraepithelial network, just mentioned. In the guinea-pig I find also in the peripheral portions of the macula acustica a deep layer of inverted conical cells, each with an oval nucleus; these cells are with their basis closely attached to the basement membrane. Max Schultze has described these cells and Rüdinger found them also in the peripheral parts of the crista acustica. Rüdinger maintains that the fine nerve fibrils pass simply *through* the spindle-shaped cell, and terminate as the acoustic hairs, being at the same time connected with the nucleus; but Retzius states that in fishes only the first-named conical or cylindrical epithelial cells are connected centrally with the nerve fibrils, while peripherally they give off the

acoustic hairs. But in mammals this is most decidedly not the case; in the macula acustica of the guinea-pig's labyrinth, viewed in profile and from the surface, it is evident that the cylindrical or conical *epithelial* cells have nothing to do with the acoustic hairs; these distinctly belong to the spindle-shaped *sensory* cells.

Pritchard first described a hyaline cuticle covering the epithelium of the macula acustica of the cat, and he very justly considers it analogous to the lamina reticularis of the organ of Corti (see below). This observer finds that the cuticle contains holes through which pass the acoustic hairs, but I find in the guinea-pig, where this cuticle attains to a very conspicuous thickness, that there are two kinds of holes, small ones, through which project the acoustic hairs, and larger ones for the basis of the conical epithelial cells. In a bird's-eye view of the macula acustica of the saccule these relations are very well shown. Kuhn found a similar cuticle on the surface of the epithelium of the macula and crista acustica of batrachiæ; he calls it the membrana tectoria.

At the sides of the macula and crista acustica, near the foot of these prominences, the epithelium becomes suddenly thinner, but remains columnar; it does not contain any spindle-shaped cells, and consequently also no acoustic hairs projecting over the surface, but there is still left a trace of a cuticle on the free surface of the epithelium. Pigment occurs occasionally (guinea-pig) as a special layer of flattened irregular cells in the tunica propria and close to the epithelium. This pigment layer extends only to the foot of the macula or crista acustica.

The canalis reuniens of Hensen, joining the saccule with the canalis cochlearis, is of the same structure as the former; a single layer of flattened epithelium lines the delicate tunica propria, and outside this is a fibrous coat connected with the periosteum.

The aqueductus vestibuli contains a minute membranous tube lined with an epithelium composed of a single layer of polyhedral cells (Böttcher, Key and Retzius); its fibrous wall contains capillary blood-vessels.

It divides into two branches, one of which opens into the utricle and the other into the saccule, thus forming the communication between the endolymph of these two organs. Hasse for this reason calls it the ductus endolymphaticus. The membranous tube terminates with a cæcal extremity, the saccus endolymphaticus of Hasse, within the dura mater (Key and Retzius).

The ultimate branches of the arteries and the capillary networks are situated in the outer or fibrous coat of the utricle, saccule, and semi-circular canals. The vessels are very much more numerous and the network denser in the macula and crista acustica than in the other parts.

The lymphatics will be considered in connection with the *cochlea.*

The otoliths of the labyrinth of man and mammals form groups on the macula acustica both of the utricle and saccule, and also in the ampullæ of man and birds, and are fixed to the epithelium by a tenacious gelatinous substance. They are either amorphous clumps or small crystals of carbonate of lime, chiefly of rhombic shapes. What remains of the otoliths after treatment with acids is, according to Henle, organic matter (otolith-cartilage).

The Cochlea.

In the cochlea, as in the rest of the labyrinth, we distinguish the membranous canal, canalis or ductus cochlearis, from the bony shell. This latter consists of the capsule, the modiolus, and in connection with it the lamina spiralis ossea.

The bony part of the cochlea does not present any features of special histological interest, except the modiolus.

In this ascends the cochlear nerve, composed of medullated nerve fibres, which, like those of the optic nerve, possess neither the hyaline sheath of Schwann nor the nerve corpuscles.

They are arranged in bundles, which are contained in larger or smaller osseous canals. Towards the upper parts these canals become fewer and larger; in some cochleæ, e.g. guinea-pig, we find the bundles of nerve fibres, especially in the middle and upper parts of the modiolus, contained in a common large canal. Within each bundle are found numerous nuclei belonging to connective-tissue corpuscles which correspond to the endoneurium.

As the cochlear nerve descends in the modiolus and passes the root of the lamina spiralis ossea, it gives off numerous branches to, or rather receives them from, the ganglion spirale Corti, contained in the canalis ganglionaris. There exist considerable differences with regard to the position of this ganglionic layer; in some instances it belongs already to the lamina spiralis ossea (cat), while in others (guinea-pig) t is close to, but outside it.

The ganglion cells are all bipolar, each process being continued as a medullated nerve fibre (see Chapter XVI.).

Their nucleus is comparatively large.

The thin connective-tissue septa composed of fine bundles of fibres, but chiefly of nucleated cell plates, which in the efferent nerve branches separate the nerve fibres, are also traceable into the ganglionic layer, where they are seen running as septa between the neighbouring ganglion cells.

Thus in a transverse section through the ganglion, the appearance is produced as if the ganglion cells were surrounded by a nucleated capsule; but there is no structure comparable to the capsule of the ganglion cells as found in the spinal and similar ganglia.

Into the ganglionic layer enter smaller and larger nerve-branches from the lamina spiralis ossea. Both those entering as well as those leaving the ganglionic layer are contained generally not in one common osseous canal, but are embedded in several smaller or larger such canals. The nerve bundles within the lamina spiralis ossea form a continuous layer and lie in a common space between the thicker upper vestibular and the thinner lower tympanic lamella of osseous substance. There are also here nucleated cells, endoneurium, to be met with between the nerve fibres.

The nerve fibres form here very rich plexuses; they are medullated fibres from the entrance into the osseous portion of the lamina spiralis immediately after leaving the organ of Corti (see below).

This division of the nerve fibres, viz. within the lamina spiralis ossea, varies in length, of course according to the length of the lamina spiralis, cæteris paribus, being longer in the lower than in the upper turns.

But also the number of the nerve fibres in the lamina spiralis ossea and the size of the ganglion spirale, i.e. the number of the ganglion cells, decrease as we ascend towards the apex of the cochlea.

Besides the channels for the nerve branches the modiolus contains in its marginal portion channels for blood-vessels and lymphatics. These channels occur mostly where the osseous septum between the scala tympani and scala vestibuli of adjacent turns joins the modiolus. The blood-vessels, especially the arteries, are here very conspicuous by their exceedingly convoluted nature. The substance surrounding these vessels and filling up those channels of the modiolus is homogeneous, in it are embedded delicate bundles of fibrous tissue and numerous nucleated flattened endotheloid cells.

The blood-vessels, chiefly arteries, are accompanied by lymphatic vessels, whose wall is a single layer of endothelial cells. These lymphatics either run simply at the side of the vessels, or, as is oftener the case, form continuous spaces and sinuses by which the arteries appear completely invaginated. In such cases we find the blood-vessel ensheathed in a special endothelial membrane, and from this to the outer endothelial wall of the lymph-space extend thinner or thicker bridges also ensheathed in endothelium.

The cavity of the ductus cochlearis, containing the endolymph, is comparable to that of the utricle, saccule and membranous semi-circular canals, while the space containing the perilymph is, in the case of the cochlea, unlike that in the rest of the labyrinth, where it is single, divided into the scala vestibuli and the scala tympani. Also in the cochlea

the membranous canal is placed excentrically, and, as in the case of the semi-circular canals, next the convex surface of the bone capsule.

In the human cochlea it is generally asserted that the scala vestibuli is smaller than the scala tympani; but in the cochlea of the guinea-pig the scala vestibuli is distinctly larger than the scala tympani.

The canalis or ductus cochlearis consists of the following parts:

(1) The membrane of Reissner; (2) the ligamentum spirale—vestibular portion; (3) the membrana basilaris or lamina spiralis membranacea; and (4) the crista spiralis.

The crista spiralis and membrana basilaris form the lower or tympanic, the ligamentum spirale the outer, and the membrana Reissneri the inner or vestibular boundary of the triangular cochlear canal. The three angles are: the *outer* or sulcus spiralis externus, the *upper* or angulus vestibularis superior, and the *inner* or angulus vestibularis inferior. At the first the membrana basilaris passes into the ligamentum spirale (zona pectinata); at the second the ligamentum spirale is in contact with the membrane of Reissner; and at the third this membrane passes into the inner end of the crista spiralis (habenula sulcata auct.).

Passing from the upper to the inner vestibular angle we meet with the membrane of Reissner, which does not present any unevenness at any point. Passing from the inner to the outer angle, i.e. along the lower wall of the cochlear canal, we meet with the following parts (see figs. I., II., and III. of Plate XLV.):

The crista spiralis.

The sulcus spiralis internus, situated between the labium vestibulare and labium tympanicum (Huschke) of the crista spiralis.

The habenula perforata, that is the row of holes through which the nerve fibres pass into the lamina spiralis ossea.

The organ of Corti.

The outer extremity of the membrana basilaris or the zona pectinata.

Passing from the outer angle, i.e. the sulcus spiralis externus, to the upper vestibular angle, that is along the vestibular part of the ligamentum spirale, we meet with the ligamentum spirale accessorium, including the vas prominens, and finally the stria vascularis.

The *membrane of Reissner* consists of two layers of flattened cells separated by an exceedingly delicate hyaline membrana propria. The layer of cells lining the surface looking into the cavity of the cochlear canal is composed of polyhedral somewhat flattened cells of epithelial, i.e. epiblastic origin, being derived from the primary otic vesicle. Each cell consists of a transparent substance and an oval nucleus.

The cells are more flattened in about the middle of the membrane, and increase somewhat in their thickness-diameter both towards the upper and inner angle of the membrane.

Next to the upper angle, i.e. where the membrane is in contact with the ligamentum spirale, the epithelial cells contain in some instances minute brownish pigment granules.

The epithelium at the upper angle passes into the epithelium of the stria vascularis, and at the inner angle into that of the crista spiralis (see below).

The vestibular side of the membrane is covered with a layer of exceedingly flattened endothelial scales (Gottstein), each with a rounded or slightly oval nucleus; the breadth of these cells is very much greater than that of the epithelial cells of the opposite side.

At the upper and inner vestibular angle the endothelial layer passes into the similar layer of flattened endothelial cells lining the inner periosteum of the scala vestibuli.

The *ligamentum spirale* (Kölliker) is a crescentic mass of connective tissue fixed to the inner surface of the bone and forming part of its periosteum; it consists of a tympanic and a vestibular portion; the two joining at an angular projection pass into the outer extremity of the membrana basilaris.

The substance of the ligamentum spirale shows in a homogeneous matrix a great many stiff elastic fibrils crossing each other and interlacing; most of them have a direction parallel to the surface of the ligamentum spirale, but distinctly radiating towards the membrana basilaris. Very numerous flattened endotheloid or spindle-shaped cells, each with an oval nucleus, are contained between them. When viewed from the surface many of these cells are seen to be more or less branched.

The surface of the vestibular portion of the ligamentum, that is the one facing the cochlear canal, is covered with an epithelium, which on the one hand is continuous with that of Reissner's membrane, and on the other, with that of the sulcus spiralis externus.

The epithelial cells, or the cells of Claudius, lining the sulcus spiralis externus and those of the outer extremity of the membrana basilaris, i.e. the zona pectinata, are more or less columnar cells, each with a slightly oval nucleus. Towards the ligamentum spirale accessorium, a projection caused by a blood-vessel and close to the stria vascularis, presently to be described, the epithelial cells become polyhedral and more or less flattened.

But there are spindle-shaped, club-shaped, and pear-shaped cells extending between them from the tissue of the ligamentum spirale. Over the lig. sp. accessor. itself the epithelium is quite flattened.

On the stria vascularis, which forms the chief part of the vestibular section of the

ligamentum spirale, the epithelial cells are columnar or conical, each with an oval nucleus; their substance is opaque. But these columnar epithelial cells do not form a continuous compact layer, since there project vertically between them, from the substance of the ligamentum spirale, spindle-shaped-looking cells extending to the free surface, and with these cells, also, here and there a capillary loop. In many instances, notably the guinea-pig, brownish pigment in smaller or larger clumps and in granules is met with here.

This pigment is contained between, and in the cells of the stria vascularis, notably in the cells which extend from the tissue of the ligamentum spirale. At the boundary between the stria vascularis and the matrix of the ligamentum spirale there are occasionally met with small branched pigment cells extending in a direction parallel to the surface.

In the sulcus spiralis externus a distinct but delicate hyaline basement membrane can be traced underneath the epithelium from the surface of the ligamentum spirale to the extremity of the membrana basilaris.

The *membrana basilaris* especially in the region of the organ of Corti is the most important and most complex part of the wall of the cochlear canal.

We distinguish in it: (*a*) the epithelium of the surface facing the cochlear canal, which, specially modified, forms the organ of Corti, and represents the sensory epithelium; (*b*) a delicate hyaline (upper) basement membrane; (*c*) the tunica propria; (*d*) a second hyaline (lower) basement membrane; (*e*) an endotheloid layer of cells on the surface facing the scala tympani.

Leaving for the present the epithelium, and considering the other layers, I find as regards these the following: both the upper and lower hyaline basement membrane are delicate and homogeneous layers, the former being a continuation of the most superficial stratum of the vestibular part of the ligamentum spirale, the latter of a similar stratum of its tympanic part. The tunica propria, on account of its greater thickness, is the matrix of the membrana basilaris and is continuous at its outer extremity, i.e. in the zona pectinata, with the bulk of the matrix of the ligamentum spirale, while at its inner extremity, viz. in the region of the habenula perforata, it passes into the matrix of the tympanic labium of the crista spiralis, and is also intimately connected with the periosteal tissue of the lamina spiralis ossea.

When viewed from the surface in hardened specimens the tunica propria shows an uniform and fine parallel striation, owing to its containing a great many fine stiff fibrils (Hannover, Henle, Böttcher, Hensen, Nuel) running in the direction from the ligamentum spirale towards the habenula perforata. They are continuous with the

fibrils of the ligamentum spirale; they are not connective-tissue fibrils, nor elastic fibrils although they are very like them.

The cells covering the tympanic side of the membrana basilaris, when viewed from the surface, appear as small granular cells, each with a spherical nucleus, and very loosely placed side by side and connected with one another by short thick processes. In some places they are further apart from each other than in others; in the first case they possess long processes, which are branched and by which the cells are connected into a network. In the profile view the branched nature of these cells cannot of course be recognised, and they appear like polyhedral cells.

In the region of the arch of Corti (see below) the membrana basilaris contains the venous *vas spirale* of Huschke, which lies in a lymph-space (Böttcher).

In man and most mammals the membrana basilaris contains no other blood-vessel; Nuel found one in the dog, and I have seen in the membrana basilaris of the lower turns of the cochlea of the guinea-pig also one or the other capillary blood-vessel closely placed against the posterior basement membrane but contained within the tunica propria. In the region of the vas spirale, that is exactly underneath the arch of Corti, the membrana basilaris forms occasionally a slight bend towards the tunnel of the arch.

Following the epithelial cells, or the cells of Claudius, lining the sulcus spiralis externus over the zona pectinata of the membrana basilaris, we arrive at the *organ of Corti.* Compare fig. III. of Plate XLV. The first structures we meet here are the epithelial cells, which are directly continuous with the cells of Claudius, but which are larger and thicker than the latter; they are known as the *supporting cells* of Hensen. Some of these contain, notably in the guinea-pig, fat globules (v. Winiwarter). Their position in the cochlea of this animal is different from that of others, in so far as they do not form, as is usually the case, a simple continuation of the last row of the outer hair cells, presently to be described, but they, viz. the supporting cells, ride, as it were, on the last row of the hair cells (see Plate XLV.).

Next come the *outer hair cells.*

These cells are placed in longitudinal rows,[1] but so that when viewed from the surface, i.e. in the bird's-eye view, the cells of the neighbouring rows alternate in a regular manner. The rows are counted from the outer pillar of the Corti's arch as the first, second, third, fourth, &c.

[1] The term 'longitudinal' is used here and in the following as the direction of the long axis of the cochlear canal, the term 'transverse' as the direction across the cochlear canal—i.e. from the ligamentum spirale to the crista spiralis.

In the cochleæ of most mammals there exist three rows of outer hair cells, in the guinea-pig there are four in the upper turns; Waldeyer found four or even five rows in the human cochlea, and, according to Pritchard, in man and the ape there exist in about the middle height of the lamina spiralis five, and on the top even six rows of hair cells.

Each of the outer hair cells possesses on its free surface a small bundle of fine stiff rodlike cilia (Middendorp, Deiters).

Although carefully studied and described by Deiters, they have nevertheless become well understood only since Gottstein and Waldeyer, to whose researches may be added those of Lavdowsky and Nuel.

Each hair cell is in reality only a part, the upper one, of a double cell, whose lower portion is the cell of Deiters, while the former is the hair cell proper or the cell of Corti. Nuel's cellule acoustique descendant is comparable to the cell of Corti; his cellule acoustique ascendant to the cell of Deiters. Both are composed of granular protoplasm containing a clear nucleus, and they extend between the membrana basilaris and the lamina reticularis (see below). The hair cell proper or the cell of Corti sends a branched process, the basilar process of Gottstein, towards the membrana basilaris, while from its free surface a number of cilia-like hairs pass through a special hole, the ring, of the lamina reticularis (see below). According to Nuel there are generally ten to twelve hairs to each cell, arranged in the form of a horseshoe, the opening of this being directed inwards.

The cell of Deiters or the lower part of the double cell is more or less spindle-shaped and possesses a long homogeneous process which runs up to the lamina reticularis, with which it is intimately connected: this is the phalangeal process of Gottstein.

According to Nuel the cells of Corti of each row are fused together in their middle part, i.e. in the region of their nucleus.

The hair cell proper and the cell of Deiters of the same double cell are intimately connected with one another (Gottstein).

In the guinea-pig the two cells of the double cell are distinct from one another; the one, viz. the hair cell proper, being conical and possessed of a long (basilar) process, while the other is spindle-shaped.

The outer hair cells generally decrease in length further away from the arch of Corti, but in the guinea-pig the reverse is the case, owing to the peculiar position of the head-plate of the outer pillar and of the lamina reticularis (v. Winiwarter).

Then follows the *arch of Corti*, composed of the outer and inner[1] pillar or rod, each in a single row. The arch of Corti forms, as it were, the centre of the organ of Corti; it

[1] The terms 'outer' and 'inner' are used invariably with reference to the modiolus, in the same way as was the case above with the sulcus spiralis 'externus' and the 'inner' vestibular angle of the cochlear canal.

is generally the most elevated point, acting at the same time as a firm support of the other elements which appear grouped around it.

Both pillars are elongated, more or less S-shaped rodlike structures, on which we distinguish a thickened upper extremity or the head, a thickened lower extremity or the foot, and an elongated rod-shaped middle part or the body. The pillars of the two rows touch with their head, while their foot, resting on the membrana basilaris, forms a sharp angle with this latter. Thus a triangular space, the tunnel of the arch, is formed between the two rows of pillars and the corresponding portion of the membrana basilaris.

The head of the inner pillar is more or less distinctly triangular in the profile view, and possesses an inner short and an outer much longer platelike prolongation. This latter is the head-plate and is so curved, that with its concave (outer) surface it firmly grasps the head of the outer pillar; it terminates in the lamina reticularis (see below). The head of the outer pillar is of considerable size; it possesses a convex surface which, as just mentioned, closely fits into the concavity of the long platelike process of the head of the inner pillar.

Outwards, that is, towards the outer hair cells, the head of the outer pillar sends off a long platelike process, the head-plate, which, as will be presently mentioned, forms the first phalanx of the membrana reticularis.

In most cochleæ the top of the head of the outer pillar is the highest point of the organ of Corti, that is farthest away from the membrana basilaris; but in the guinea-pig this is not so, since the head-plate of the outer pillar and the greater part of the membrana reticularis covering the outer hair cells, ascend in an oblique direction (v. Winiwarter.) From this it follows that the outer hair cells of the most external row are longer than those next the outer pillar.

The outer pillar is much thicker than the inner, and there exists this definite relation between the two, that the head of the outer pillar fits exactly into that of two inner ones, or rather into the head plates of two inner pillars; the convex surface of the head of each outer pillar appears, therefore, double-facetted.

The body of the outer pillar is always longer than that of the inner, and this gives, of course, to the whole outer pillar a greater length. In the guinea-pig this relation is almost exaggerated, and in addition the body of the inner pillar is distinctly bent inwards towards the tunnel in about its middle part. The body of the outer pillar shows a relative increase in length from the lower to the upper turns of the cochlea (Pritchard). The body of both the inner and outer pillar is comparatively slender and curved.

The foot is pyramidal and larger in the outer, columnar and smaller in the inner pillar. The substance of both the pillars is, in the fresh state, homogeneous and bright.

After hardening reagents it is longitudinally striated, owing to being composed of minute fibrils (Nuel). It is dissolved in liquor potassæ, but otherwise is very resistant towards reagents (Böttcher).

In close contact with the foot and facing the tunnel (Corti), and also with the head (Waldeyer) of both the inner and outer pillars, are separate masses of granular-looking protoplasm, each such mass, viz. at the foot and head, containing a nucleus (Waldeyer); that of the head is not always distinct; at the foot the nucleus is small and spherical. The large oval clear nucleus drawn by Waldeyer in Stricker's book is not the natural state.

The protoplasm of the inner pillar in the top scale of the guinea-pig's cochlea extends along the inner surface of the body of the pillar up to its head, a condition which is maintained by Hensen for the protoplasm of the pillars in general.

The protoplasm of the foot of the outer pillar is occasionally continuous over the surface of the membrana basilaris of the tunnel with that of the inner pillar (Böttcher); or instead of this arrangement a network of threads (Deiters' supporting fibres) is found extending between the foot of the outer and inner pillar, see fig. III. of Plate XLV.

On the inner side of the inner pillar rest the *inner hair cells* of Deiters in a single row. These are relatively large and thick cells, each with an oval nucleus and a bundle of fine hairs projecting on their surface. Each of these cells extends into the depth with one or two basilar processes (Böttcher, Gottstein) buried between irregularly outlined nucleated small cells, the 'granular cells' of Waldeyer. Inwards of these, having now arrived at the tympanic labium of the crista spiralis, follow columnar epithelial cells in a single layer, each with an oval nucleus. They may be appropriately called the inner supporting cells, since they correspond to the supporting cells outside the outer hair cells; they gradually diminish in height, but at the same time become much broader, and thus pass into the flattened polyhedral epithelial cells lining the sulcus spiralis internus.

Before passing to the crista spiralis we have to consider the *lamina reticularis* of Kölliker.

This is a cuticular resistant hyaline structure and may be considered as composed of an outer larger and an inner smaller division; the former begins with the head-plates of the outer and inner pillars and extends over the outer hair cells and for a little distance also over Hensen's supporting cells, while the latter or smaller division begins with the short process of the head of the inner pillars, and loses itself over the inner supporting cells.

The outer division is the lamina reticularis proper, it possesses circular or oval openings through which the ciliated bases of the outer hair cells project. The matrix of the lamina reticularis is raised slightly like a special rim at these openings, and hence appears here double-outlined; this gives rise to the distinction of the *rings* of Böttcher. The hair cells being placed alternately in longitudinal rows, also their rings are arranged similarly in rows, and they are counted, like the hair cells, from the outer pillar as the first, second, third, or even fourth row of rings. The parts of the membrane between the rings, owing to their being shaped like the phalanges of the fingers, are distinguished as the *phalanges* of Deiters; these naturally are also placed alternately in rows.

When viewing this division of the lamina reticularis from above and passing from the arch of Corti outwards we observe: the spatula-like head-plates of the outer and inner pillars forming the first row of phalanges alternating with the hair cells (or their rings) of the first row; then a second row of phalanges similarly alternating with the hair cells (or their rings) of the second row, then a third row of phalanges alternating with the hair cells (or their rings) of the third row, and in the cases in which there is a fourth row of hair cells (see above) there is of course a further row of phalanges. The substance of the lamina reticularis loses itself as a thin cuticle between the free ends of Hensen's supporting cells.

Owing to this regular alternation, it follows that the rings of the first and third row and the phalanges of the second row follow each other in straight, transverse lines; and similarly the head-plates of the outer and inner pillars, i.e. the phalanges of the first row, the rings of the second row, the phalanges of the third row, and if there be a fourth row of rings, also these latter follow each other in straight transverse lines.

The hair cells being arranged in a slanting direction, it follows that while the ciliated basis is held in the above ring, the body of the cell is covered, as with a shield, by the phalanx of the next outer row (Gottstein); and the comparison becomes still more justified, if it is remembered that the above-named phalangeal process of the hair cell is fixed to this very phalanx.

The inner division of the lamina reticularis commences in a somewhat similar manner, viz. the short or inner process of the heads of the inner pillars form the first phalanges, alternating with the inner hair cells or their rings; these latter correspond in appearance to the first row of the outer rings (Deiters). But there being no further hair cells, the lamina loses itself as a thin cuticle amongst the basis of the inner supporting cells.

As mentioned above, that portion of the boundary of the cochlear canal which lies between the habenula perforata and the inner angle (angulus vestibularis inferior) is the *crista spiralis*, with the sulcus spiralis internus between its tympanic and vestibular labium.

The matrix of the labium tympanicum is a direct continuation of the tunica propria of the membrana basilaris, and, like this latter, shows under certain conditions, especially in hardened specimens, a fine striation in a longitudinal direction.

Both the vestibular and the tympanic labium are firmly fixed on the vestibular surface of the lamina spiralis ossea, with whose periosteum they become identified. In the labium vestibulare, which is greatly thicker than the labium tympanicum, the matrix appears as a direct continuation of the periosteum, and contains in a dense fibrous matrix numerous nucleated cells and a few capillary blood-vessels. At the free surface of the labium vestibulare the substance of this latter appears divided by elongated deep furrows or pits into oblong parallel masses, which towards the inner angle of the cochlear canal, owing to the furrows becoming reticulate, are shorter and more or less irregularly shaped. These are the *acoustic* or *auditory teeth* of Huschke. Waldeyer showed that the epithelial cells lining the sulcus spiralis internus, which we left above, is continued into the furrows and pits between Huschke's teeth as a layer of small polyhedral cells; at the insertion of the membrane of Reissner they pass into the cells lining this latter.

In a vertical section through the crista spiralis these epithelial cells are always recognised by the layer of oblong nuclei arranged in a single line apparently in the substance of the labium vestibulare and extending from the sulcus spiralis to the attachment of Reissner's membrane.

From near the inner angle of the cochlear canal and close to the surface of the labium vestibulare of the crista spiralis, across the sulcus spiralis internus and over the organ of Corti, is stretched a delicate membrane, *Corti's membrane* (Kölliker) or the *membrana tectoria* of Claudius. It is very delicate just over the crista, becomes suddenly thicker while bridging over the sulcus spiralis, and terminates with an attenuated border over the outer hair cells (Hensen, Gottstein), to whose surface it is closely attached. In hardened specimens the membrana tectoria appears finely and longitudinally striated (Löwenberg, Hensen and others); it is of a tenacious consistency (Hensen) and is probably a cuticular formation (Kölliker).

The medullated nerve fibres, as mentioned above, run between the vestibular and tympanic lamella of the lamina spiralis ossea, and on this way form very rich plexuses. At the point of passing through the holes of the habenula perforata they all lose their medullary sheath, and their destination, according to Waldeyer and Gottstein, is this: each axis cylinder either divides in a few branches or breaks altogether up into the constituent primitive fibrils. The former represent of course smaller or larger bundles

of primitive fibrils, the latter are very characteristic besides their fineness, also by their regular minute varicosities. But they all have to pass through the layer of nucleated small cells, the granular cells of Waldeyer, underneath the inner hair cells. Each of the axis cylinders or their larger branches become connected with the pointed extremity of the inner hair cells and represent the *inner radial nerve end-fibres*, while the fine varicose primitive fibrils are the *outer radial nerve end-fibrils*; these latter pass between the bodies of the inner pillars, crossing in a slightly ascending transverse direction the tunnel of the Corti's arch in about its middle height, and having emerged again beween the outer pillars, terminate finally in the substance of the outer hair cells.

There exist also other threads which pass through the tunnel, e.g. the fibres of Deiters' (see above), and threads which have the same origin as these latter, but, like the nerve fibrils just mentioned, have an ascending direction and appear to lose themselves close to the spindle-shaped cells of the outer hair cells, i.e., the cells of Deiters.

Max Schultze observed bundles of fine fibrils, which running in a spiral direction are called the *spiral fibre bundles.* According to M. Schultze and Deiters they are directly derived from the axis cylinders of the nerve fibres after having passed through the holes of the habenula perforata. Waldeyer distinguishes one inner bundle of these spiral fibrils running immediately underneath the row of inner hair cells and three outer bundles running underneath the rows of outer hair cells, but so that one is situated in the space between the row of outer pillars and the first row of outer hair cells, the next between this latter and the second row, and the third between this latter and the third row of the outer hair cells.

According to Rosenberg the spiral fibrils are more numerous in the young than in the adult cochlea.

A careful examination of the cochlea cannot fail to ascertain the fact that as we ascend from the lowest turn towards the cupola all parts decrease in absolute size in a definite manner.

Thus the lamina spiralis ossea gradually decreases in length, the crista spiralis and the ligamentum spirale both in length and thickness; the stria vascularis decreases conspicuously in length, while the membrana basilaris less so, although distinctly. The membrana tectoria, owing to the decrease in length of the crista spiralis and membrana basilaris, of course also diminishes in length.

The organ of Corti in all its parts, including the pillars and hair cells, shows a slight but distinct diminution in size from the basis of the cochlea towards the top.

THE BLOOD-VESSELS.—The capillary blood-vessels of the cochlea form networks belonging to the periosteum including those of the lamina spiralis ossea, and connected

with them are the capillaries of the deeper parts of the crista spiralis; one or the other capillary vessel is seen within the outer portion of the membrana basilaris; and finally there are numerous capillaries in the ligamentum spirale and connected with the vessels of the periosteum of the bony capsule.

THE LYMPHATICS.—Schwalbe found that injection matter penetrates from the subdural space of the brain through the meatus auditorius internus into the perilymphatic space of the labyrinth.

Michel confirmed this, while E. Weber found this connection to exist only between the subdural space of the brain and the perilymphatic space, notably of the scala tympani (Key and Retzius), by means of the aqueductus cochleæ.

Hasse for this reason considers the aqueductus cochleæ as the ductus perilymphaticus.

Key and Retzius showed that also the acoustic nerve possesses a continuation of the dura mater as the outer or dural sheath, and one of the arachnoid membrane as the inner or arachnoidal sheath. The subdural space of the brain is continued into a subdural space of the nerve, and similarly the subarachnoidal space of the brain can be traced between the inner sheath and the bundles of the nerve fibres. Key and Retzius further saw that the injection matter follows the bundles of nerve fibres, and ensheathing them, passes also into the lamina spiralis ossea.

Hasse maintains that there exists a connection of the aqueductus vestibuli through its cæcal extremity, i.e. the above-named saccus endolymphaticus, between the subarachnoidal space of the brain and the endolymph of the labyrinth.

But Key and Retzius do not admit any such connection of the subarachnoidal or subdural space with the cæcal extremity of the aqueductus vestibuli.

Zuckerkandl succeeded in injecting from this saccular intradural extremity the endolymph-space of the utricle, and Weber-Liel filled from it by aspiration the whole of the endolymphatic spaces of the human labyrinth, i.e. the utricle and saccule, the semicircular canals and the cochlear canal, all forming one intercommunicating system of spaces. Weber-Liel succeeded also in demonstrating the connection of the perilymphatic space of the labyrinth with the aqueductus cochleæ; this likewise possesses an intracranial connection, but whether with the subdural or subarachnoidal space could not be decided.

CHAPTER XLI.

THE NASAL MUCOUS MEMBRANE.

THE skin at the anterior nares is of the same structure as that of the lips; its large sebaceous glands have been referred to in a former chapter.

The first part of the mucous membrane following the skin is composed of a very delicate mucosa, it contains few connective-tissue bundles and a great many endotheloid cells. The epithelium covering it is of this peculiarity, that, like the epidermis, it still possesses a rudiment of a stratum corneum, composed of horny scales, in which remnants of staff-shaped nuclei can be made out. Underneath it are several layers of epithelial cells, completely resembling the stratum Malpighii. There are numerous glands embedded in the deep section of the mucous membrane, that is the part next the cartilage. These glands are, as regards structure, in many respects similar to the muco-salivary glands, e.g. submaxillary gland of dog (see Chapter XXIV.). The alveoli are more or less branched and wavy tubes, extending in a direction more or less parallel with the free surface. They are possessed of a small but distinct lumen lined with a single layer of more or less columnar epithelial cells, each with a single spherical nucleus.

Their substance appears granular, and in man and mammals is not unlike the mucous cells of the mucous glands. The alveoli pass into a duct, which is considerably broader and of a wavy course; it does not pass straight towards the surface, but has at first a direction more or less horizontal, and finally opens in an oblique manner with a wide mouth on the free surface.

The lumen of the duct is wide, and its epithelium, except at the mouth, is a single layer of beautiful columnar cells, each with a spherical nucleus in about the middle of the cell. The outer portion of the cell substance appears composed of longitudinal fibrils like those of the epithelial cells lining the intralobular ducts of the salivary glands (see Chapter XXIV.). But also the inner portion of the cell substance shows a faint longitudinal striation.

The mouth of the duct is lined with a continuation of the surface epithelium, consisting, like this, of a stratum corneum and a stratified pavement epithelium.

The stratified pavement epithelium of the surface is replaced sooner or later by columnar epithelium, consisting of a superficial layer of cylindrical or conical cells with

their basis on the free surface; between these are pushed in spindle-shaped or inverted conical cells; the latter are fixed with their basis on the mucosa.

The basis of the superficial cells bears a bunch of fine cilia. In the immediate neighbourhood of those parts which are covered with stratified pavement epithelium the superficial conical cells are without cilia, but in the rest of the mucous membrane of the respiratory region they are ciliated. Many of the superficial cells present themselves also here as goblet cells.

The epithelium rests on a basement membrane, which is delicate in most mammals, but acquires a very great thickness in some parts of the human organ (Heiberg); it then appears hyaline and permeated by the lacunæ and canaliculi of the lymph-canalicular system, which, as pointed out by Heiberg, forms the connection between the lymph-canalicular system of the mucosa and that of the interstitial cement-substance of the epithelium (see Chapter XXII. p. 175).

The mucous membrane contains in its superficial portion in some parts diffuse adenoid tissue, which in rare places assumes the shape of spherical lymph follicles. The thicker the mucous membrane the more likely it contains adenoid tissue, and the larger the glands in its deeper or submucous section. This is continuous with the perichondrium or periosteum respectively.

Where the mucous membrane acquires a great thickness, as in some parts of the septum and in the conchæ, the glands attain to a large size and the alveoli and corresponding ducts are grouped in more or less distinct lobules. Where the mucous membrane is very thin, also the glands are short and small. The glands are of two kinds, either mucous or serous glands (Heidenhain). The former are identical in structure with those described in Chapter XXV., the latter with the true salivary glands. The serous glands are more numerous and much larger. Their alveoli are branched, possess each a small lumen, and are lined with a single layer of epithelial cells, which during secretion appear thick and almost polyhedral and transparent; during rest they are distinctly columnar and more 'granular'-looking. The intracellular network is very conspicuous, especially in the state of secretion. In this latter state their spherical nucleus is pressed close to the limiting membrana propria, while during rest it is further away from it, but not quite in the centre of the cell.

The intralobular ducts of the nasal serous glands are identical in structure with the intralobular ducts (the salivary tubes of Pflüger) of the true salivary glands.

In connection with the wall of the alveoli and of the duct can be traced fine nucleated fibres, single or branched; they terminate apparently in connection with the epithelial cells both in the alveoli and in the duct; whether they are nerve fibres or not cannot be definitely ascertained, although their long course, their nuclei, and the fact of their being

branched make it probable that they are fine nerve fibrils. There is one other feature about these glands which is of interest, viz. where they are large, e.g. in the thick portions of the mucous membrane, the alveoli, especially those nearest to the surface, are filled with a substance which resembles the fatty matter in the sebaceous and in the Meibomian glands. This fatty matter in the nasal glands is found in the shape of smaller or larger globules scattered through the substance of the gland cells, which at the same time are much larger here than in other parts of the same gland.

In the guinea-pig and rabbit the interalveolar tissue contains here numerous finer and thicker bundles of unstriped muscle cells which are connected into a plexus; in their meshes are contained the gland alveoli. In some parts large blood-vessels, chiefly veins, with thin walls appear also embedded in, or surrounded respectively by the muscular plexus, and thus completely resemble a cavernous tissue.

Also lymphoid cells, each with a spherical nucleus, are met with in these parts in the interalveolar connective tissue.

That the presence of this unstriped muscular tissue is of importance for the ready discharge of the secretion of the gland alveoli cannot be doubted, considering that owing to the relative rigidity of these regions the secretion would otherwise not easily reach the surface of the mucous membrane.

The mucous membrane of the 'olfactory' region, or rather of the 'olfactory' places, is of a different nature from that in the 'non-olfactory' or respiratory region. It contains in its epithelium and mucosa a small amount of pigment (M. Schultze). Its epithelium is covered on the free surface with the membrana limitans externa of v. Brunn, through the holes of which project the outer processes of the olfactory cells (see below).

According to v. Brunn this membrane consists in reality of a deeper and superficial layer, the former is the proper limitans externa, while the latter is composed of very fine and short rudimentary cilia of Krause.

The limitans proper is a cuticle, such as exists also on the epithelium of the non-olfactory places.

The epithelium consists of:—

a) A superficial layer of slender cylindrical or conical *epithelial cells*, whose substance is finely and longitudinally striated,—not merely on the surface of the cell substance, as maintained by Babuchin, but throughout. Each of these cells has on its free basis, that is the one on the free surface, a smooth and sharp outline without a trace of cilia. Its oval nucleus lies in the inner portion of the cell; this extends vertically inwards, that is towards the depth, with a pointed filamentous branched or unbranched process. Owing

to the regular longitudinal striation of the outer two-thirds of the cell substance and the relative deep position of its nucleus, these cells present a peculiarly delicate appearance not unlike that seen on the epithelium covering the papillæ fungiformes of the frog's tongue.

The contrast between these cells and the superficial ciliated cells of the non-olfactory parts is very striking, especially in the places where the two, viz. olfactory and non-olfactory, are in contact: those of the olfactory parts being longer, more delicate, without cilia, and never goblet cells.

b) Between the above epithelial cells extend the *olfactory cells* of Max Schultze; these are delicate spindle-shaped cells, each with a spherical nucleus; the cell substance surrounds, as a thin zone, the nucleus and sends both towards the free surface and the depth a thin filamentous process. The outer process is the thicker of the two and projects through holes of v. Brunn's membrana limitans externa beyond the general surface as a single thick rod or as a bundle of fine cilia. In mammals and man the former, in lower vertebrates the latter is found to be the case. The inner process is very delicate and, as first pointed out by M. Schultze, is possessed of minute varicosities.

The olfactory cells are very numerously interposed between the above cylindrical epithelial cells, their nuclei are not all in the same level, and in a vertical section appear therefore in several layers. But this entirely depends on the locality: the thicker the mucous membrane is, the thicker also the olfactory epithelium and the more numerous the olfactory cells. When seen from the surface—i.e. in the bird's-eye view—the free ends of the olfactory cells appear as small dots between the larger circles indicating the free bases of the epithelial cells (Babuchin).

c) The lowest layer of the olfactory epithelium is occupied by inverted conical epithelial cells, whose basis, resting on the mucosa, includes an oval nucleus slightly flattened in a direction parallel to the surface. These cells correspond to the couche basilaire of Sidky. Each of these cells sends a pointed branched or unbranched process vertically outwards, i.e. between the olfactory cells. These processes occasionally, in sections through hardened specimens, break off together with the olfactory and the epithelial cells; and there remain, then, fixed on the mucosa only the bases of the deepest epithelial cells now resembling flattened polyhedral cells.

Of a transition of the epithelial cells into the olfactory cells, of a network of the inner processes of the former near the basement membrane, and of a connection of this network with the nerve fibrils, as maintained by Exner, I find no indication, and, like Cisoff and v. Brunn, must consider it as completely erroneous and due to bad preparations. Babuchin, Cisoff, Paschutin, Sidky, Felisch, and others, have confirmed Max Schultze in his sharp distinction between the columnar epithelial cells and the olfactory

cells. In good thin well-stained sections of well-prepared material (e.g. guinea-pig's and rabbit's olfactory organs) this distinction is very well shown.

According to M. Schultze, Babuchin, and others, the olfactory epithelium consists only of the superficial layer of cylindrical epithelial cells and the olfactory cells, but in the guinea-pig and rabbit I never miss the lower layer of inverted conical cells mentioned previously.

The mucosa is separated from the epithelium by a delicate basement membrane. The tissue of the mucosa is of a loose texture, and contains numerous flattened nucleated endotheloid cells. Numerous gland tubes, the glands of Bowman, pass through the mucosa, each tube extending from the deepest part of this latter, i.e. from near the periosteum, in a more or less vertical direction to the free surface. On its way the tube is wavy, slightly convoluted and in many instances, especially where it is long, gives off two or more branches.

The gland tube gradually increases in thickness towards the depth of the mucous membrane, and thus appears more or less club-shaped. Its duct is the part which is situated in the epithelium of the surface, through which it passes in a vertical direction; it opens on the free surface with a small mouth. Occasionally the epithelium as a whole forms here a goblet-shaped depression, a relation noticed already by Babuchin. Both the duct and the gland proper possess a membrana propria. The gland tube possesses a very small central canal, lined with a single layer of 'granular'-looking cells, each with a spherical nucleus. In the deeper parts of the gland the cells are columnar, in the more superficial ones they are polyhedral, but their substance is a distinct reticulum, which is very conspicuous when the gland is secreting, the cells being then much larger.

Occasionally in hardened specimens the lining epithelium as a whole becomes detached from the membrana propria, and it is then found that each cell is possessed of a thin prolongation by means of which it remains connected with the membrana propria; in the natural state this prolongation lies horizontally on this membrane, and by means of it the contiguous cells appear imbricated with one another in the manner described in Chapter XXIV.

The epithelium of the duct consists of a layer of very flattened cells, each with a spherical or flattened nucleus. In hardened preparations in which the olfactory epithelium has become removed by accident or otherwise, the ducts are well shown, being now isolated and freely projecting from the mucosa. The great number of the ducts is now much easier ascertained than when the epithelium is still present.

A most important part of the mucosa are the branches of the olfactory nerve. As has been mentioned in Chapter XII. they are composed of non-medullated fibres which,

as pointed out by M. Schultze, are each possessed of a hyaline sheath of Schwann with nerve corpuscles. Their axis cylinder is a bundle of primitive fibrils (M. Schultze). The nerve branches running in a longitudinal manner represent each a smaller or larger, simple or compound bundle (see p. 85), ensheathed in an endothelial sheath, the perineural sheath, as was also pointed out of other nerve branches.

While ascending in an oblique manner through the mucous membrane, they branch and reunite and thus form a plexus. In the superficial layer of the mucous membrane they rapidly branch and break up into isolated or small groups of axis cylinders; these finally give off fine primitive fibrils immediately underneath the epithelium. These fibrils ascend into this latter and, as is now proved (M. Schultze, Babuchin, and especially Cisoff and v. Brunn), become connected with the fine filamentous inner processes of the olfactory cells.

Babuchin observed in the epithelium apparently free ends which he thinks may well be the ends of the nerves of common sensation.

The thicker the mucous membrane the more numerous and the larger are also the nerve bundles, and in fact they are the elements which besides the glands determine the thickness of the mucous membrane.

There exists this definite relation that the more numerous the nerve bundles the thicker also the epithelium, or rather the more numerous the olfactory cells, since only these latter are subject to the variations. In the guinea-pig, and rabbit, and I have no doubt also in man and many other mammals, this relation comes out with striking distinctness in many regions where 'olfactory' parts are in contact with non-olfactory ones. Thus, for instance, if a transverse section of any of the numerous projections be examined, e.g. the conchæ and other foldlike prominences, we find that the free margin of the projection possesses a thick mucosa with long gland tubes and very numerous and large nerve bundles, and consequently a very thick olfactory epithelium. From the margin towards the root, i.e. the point of fixation of the projection, the number of the nerve bundles, the length of the gland tubes, and consequently also the thickness of the mucous membrane, gradually decrease; and the same decrease is observed in the olfactory epithelium or rather of the olfactory cells of this latter. Near the root and at this latter the mucosa is of the non-olfactory nature, possesses no olfactory nerve bundles, no glands or very short ones, and consequently a very thin mucous membrane, and its epithelium is a ciliated epithelium, as described above.

Not the whole olfactory region of the authors is covered with 'olfactory' mucous membrane, since in many places we find smaller 'olfactory' portions alternating with non-olfactory ones.

Occasionally a non-olfactory fold or projection of the mucous membrane on the septum or in the lateral parts of the nasal cavity is met with which contains large glands in lobules and is of course covered with ciliated epithelium. On such projections, generally on its very margin, may occur over a small extent an 'olfactory' mucosa; in this latter place we find an olfactory epithelium, a layer of mucosa containing single gland tubes, of the same kind as those of other olfactory regions, and a few branches of the olfactory nerve, *super-imposed* over lobules of glands, which clearly belong to the non-olfactory surrounding part since their ducts open in this latter.

The BLOOD-VESSELS form rich networks of capillaries in the superficial parts of the mucous membrane. The glands possess of course their own capillaries.

The LYMPHATICS of the olfactory mucous membrane have been injected by Schwalbe and afterwards by Michel from the subdural space of the brain. Key and Retzius demonstrated a rich network of finer and larger lymphatics, the latter with valves. They take up the lymph lacunar system of the tissue of the mucous membrane; the alveoli and ducts of the glands are surrounded by networks of the lymph-lacunæ. In the olfactory parts the network of lymph-lacunæ extends up to the epithelium, and in some places Key and Retzius saw tubular lymphatics ascend through the epithelium to the free surface in company with the gland ducts.

The olfactory nerve branches are ensheathed in lymph-channels which are in connection with the lymphatics of the mucous membrane.

Key and Retzius made very successful injections of these lymphatics, as illustrated on Plates XXXVII. XXXVIII. and XXXIX. Part I. of their magnificent work: 'Studies of the Nervous System,' &c.; these injections were carried out in the rabbit and dog from the subdural space of the brain and the subarachnoidal space of the spinal cord.

The organ of Jacobson is met with in all mammals and, as has been proved by Dursy and Kölliker, also in the human embryo. In mammals it is a bilateral oblong saccule or canal, compressed from side to side and situated in the anterior lower part of the septum narium, each being contained within a cavity of the osseous substance, but separated from this latter by a more or less perfect cartilaginous capsule. This cartilage is hyaline cartilage and is independent of the cartilage of the nasal septum above it.

Like Loewe, I also find the median wall entirely different in structure from the lateral, and there exists a very sharp boundary between the two. The former is lined on its free surface, that is, the one facing the inner cavity, with an epithelium which in many respects is similar to the olfactory epithelium, while the latter possesses ordinary ciliated columna epithelium.

As regards the olfactory epithelium of the median wall, its great thickness is very conspicuous. The superficial cells are thin conical epithelial cells, each with a narrow indistinct nucleus. Between these are pushed in the spindle-shaped olfactory cells; each of these possesses a spherical or slightly compressed nucleus several times larger than that of the conical epithelial cells. Around the nucleus is a relatively large amount of protoplasm drawn out into an outer broader and an inner long and fine process, just as is the case with the olfactory cells previously described. The number of these spindle-shaped cells is very great and they are thus the cause of the great thickness of the epithelium as a whole. A deep layer of inverted conical epithelial cells appears wanting. There is a delicate cuticle on the free surface.

A thin mucosa contains numerous minute branches of the olfactory nerve. There are no glands in this part of the wall.

The lateral wall is lined, as mentioned above, with columnar epithelium similar to that of the non-olfactory places; it consists of a superficial layer of columnar or conical cells, each with a bunch of fine short cilia; then follow numerous spindle-shaped cells, each with an elliptical nucleus; and finally pushed in between them are the deep inverted conical cells. I cannot understand Loewe's assertion that the superficial cells of the lateral wall possess no cilia. Among the superficial conical cells are found the ordinary goblet cells. The subepithelial mucosa contains a plexus of large veins with trabeculæ of unstriped muscle tissue between, i.e. a cavernous tissue.

Outside this is a more or less continuous layer of serous glands. The thickness of this layer is greatest in the lower part of the lateral wall.

The ducts open into the lower sulcus of the cavity, and in some instances the ciliated epithelium of the surface is continued into the duct.

PLATE XLV.

Fig. I. From a longitudinal section through the cochlea of the guinea-pig; one half of the section being represented only. The cochlea had been prepared with osmic acid and then stained with logwood. Magnifying power about 50.

1. Scala vestibuli.
2. Scala tympani.
3. Ductus cochlearis.
4. Inner or lower vestibular sulcus.
5. Sulcus spiralis externus.
6. Upper vestibular sulcus.

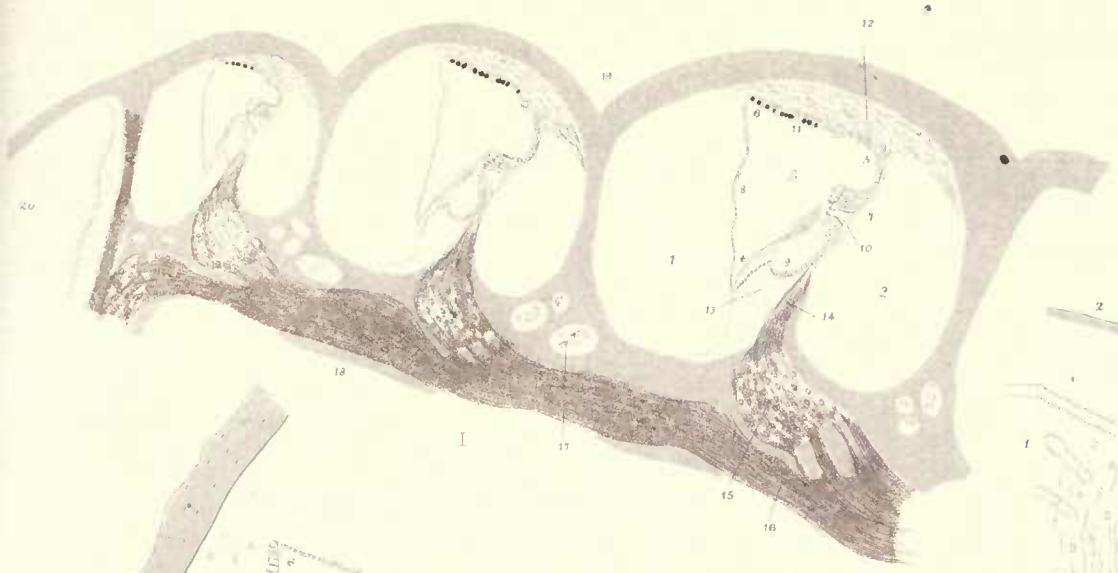

I

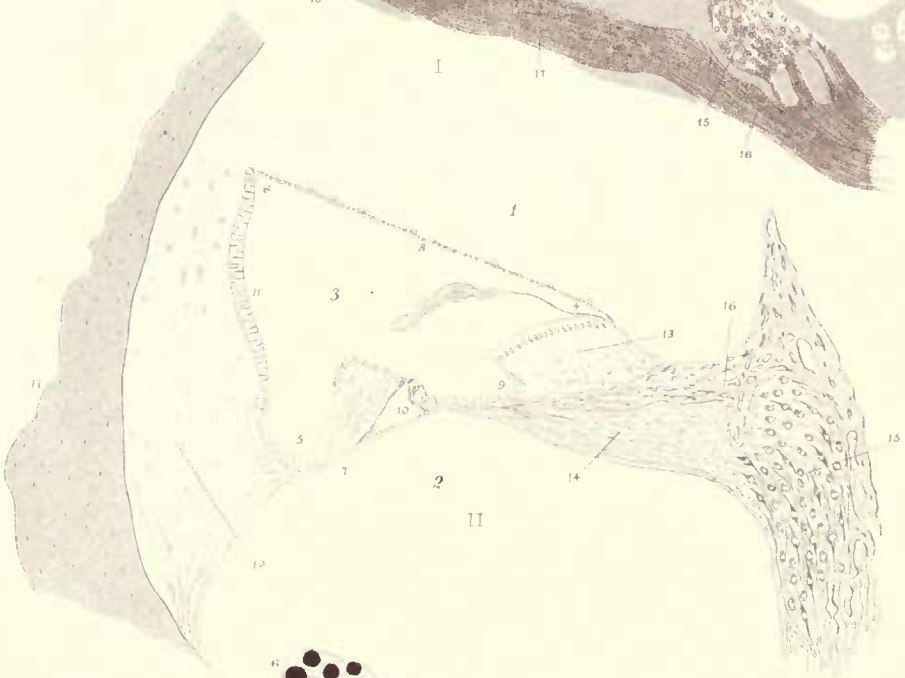

II

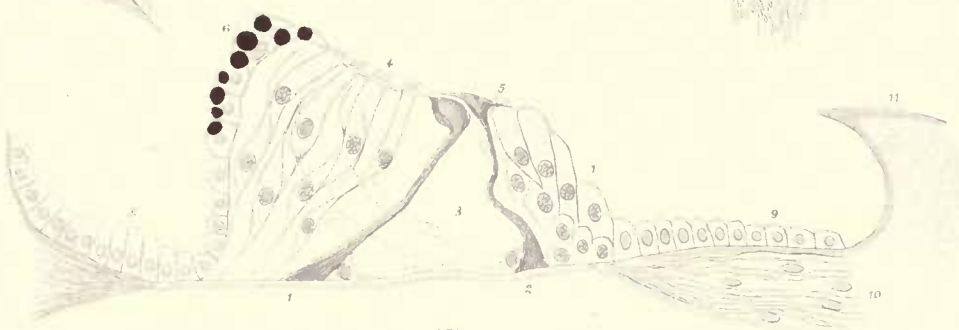

III

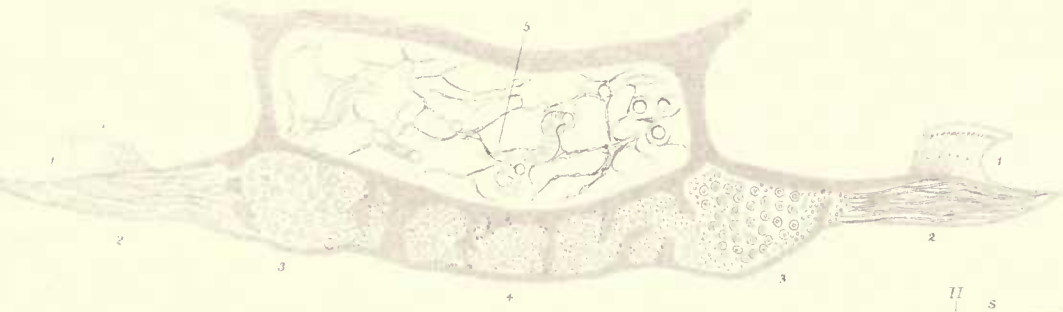

IV



V

VI

VII

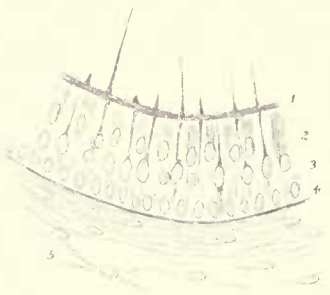

VIII

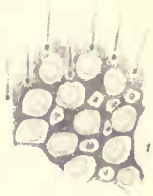

IX

X

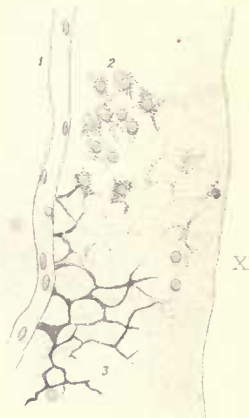

XI

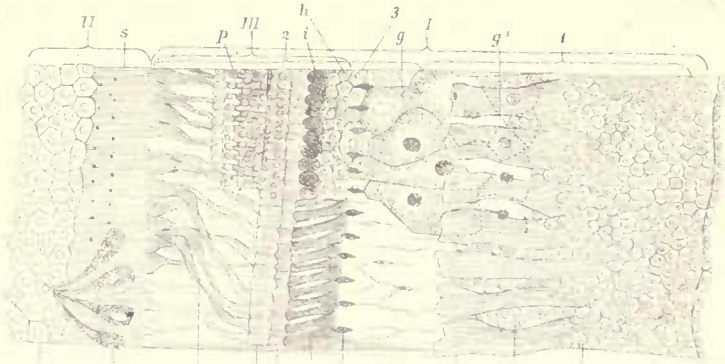

XII

REESE LIBRARY
OF THE
UNIVERSITY
OF
CALIFORNIA.

7. Membrana basilaris.
8. Reissner's membrane.
9. Sulcus spiralis internus. Over it passes the Membrana tectoria of Corti.
10. The tunnel of Corti's arch.
11. Stria vascularis.
12. Ligamentum spirale.
13. Crista spiralis.
14. Nerve fibres in the lamina spiralis ossea.
15. Ganglion spirale.
16. Part of the cochlear nerve in the modiolus.
17. Channels in the bone, containing blood-vessels and lymphatics.
18. Osseous lamellæ of the modiolus.
19. Bony capsule; the details of its structure are not represented.
20. Cupola.

Fig. II. From a longitudinal section through the cochlea of the guinea-pig, showing the cochlear canal of the second turn. Magnifying power about 150.

1–15. The same as in fig. I.
16. The vestibular lamella of the lamina spiralis ossea.
17. Bony capsule.

Fig. III. From a longitudinal section through the cochlea of the guinea-pig, the same as in fig. I.; showing the organ of Corti and the adjacent parts. Magnifying power about 300.

1. The outer pillar of Corti's arch.
2. The inner pillar.

The foot, body, head, and head-plate and the nucleated protoplasm at the foot are well shown. The latter stretches across the floor of the tunnel.

4. The cells of Corti of the outer hair-cells and the spindle-shaped cells of Deiters are well shown. The cilia of the hair-cells project through the lamina reticularis shown in profile on the surface of the organ of Corti.

5. The inner hair-cell; underneath it the 'granular' cells of Waldeyer.

6. The outer supporting cells of Hensen; most of them contain fat-globules stained black by the osmic acid.

7. The inner supporting cells.

8. The epithelium lining the sulcus spiralis externus.

9. The epithelium lining the sulcus spiralis internus; not complete.

10. The medullated nerve fibres in the lamina spiralis ossea.

11. The crista spiralis; its detailed structure is not represented.

Fig. IV. From a longitudinal section through the cochlea of the guinea-pig, showing the lamina spiralis of the first turn cut twice transversely. Magnifying power about 150.

1. Sulcus spiralis internus.

2. Lamina spiralis ossea, containing the medullated nerve fibres.

3. Ganglion spirale.

4. The root of the lamina spiralis internal to the ganglion spirale; its canals contain medullated nerve fibres, shown here in transverse section.

Fig. V. From a transverse section through part of the wall of the utricle of the labyrinth of the guinea-pig; showing the periphery of the macula acustica. Magnifying power about 300.

A. The peripheral part of the macula acustica.

B. Portion of the lateral wall of the utricle.

1. The epithelium; there is still left here a rudiment of the superficial cuticle covering the epithelium.

2. The subepithelial hyaline basement membrane.

3. The fibrous coat with capillary blood-vessels.

Between 1 and 2 of the lateral wall is a layer of pigment cells.

Fig. VI. Part of the membrana basilaris and ligamentum spirale of a similar preparation as in fig. II. Magnifying power about 450.

1. Ligamentum spirale with capillary blood-vessels.

2. The hyaline limiting membrane underneath the epithelium of the sulcus spiralis externus.

3. Bone of the outer capsule, not represented in detail.

4. Epithelial-like cells on the tympanic surface of the membrana basilaris.

The bulk of the tissue of the ligamentum spirale passes into the membrana basilaris and forms the matrix of this latter.

5. A fold of the hyaline limiting membrane on the upper surface of the membrana basilaris, continuous with the limiting membrane of the ligamentum spirale.

Fig. VII. From a transverse section through the macula acustica of the utricle of a guinea-pig's labyrinth. Magnifying power about 250.

1. Part of the bony masses of the lamina cribrosa, not represented in detail.

2. Medullated nerve fibres.

3. The superficial layer of nucleated cells of the tunica propria, forming a special nuclear layer.

4. Network of fine nerve fibrils situated already in the epithelium.

5. The sensory epithelium, drawn diagrammatically but without the covering cuticle; it consists of the superficial layer of conical epithelial cells and a deep layer of spindle-shaped cells, each of the latter is possessed of an acoustic hair projecting over the free surface.

Fig. VIII. From a transverse section through the peripheral part of the macula acustica of the utricle of the same preparation as in the preceding figure. Magnifying power about 300.

1. The superficial cuticle, i.e. the lamina reticularis, seen in profile.

2. The superficial layer of conical epithelial cells.

3. The layer of the spindle cells, their acoustic hairs projecting over the free surface.

4. A deep layer of epithelial cells.

5. The fibrous coat.

Fig. IX. The sensory epithelium of the macula acustica seen from the surface; from the same preparation as in the preceding figure. Magnifying power about 300.

1. The superficial cuticle (lamina reticularis) seen from the surface; it possesses large holes for the tops of the superficial epithelial cells and small holes for the acoustic hairs.

2. The cuticle seen in the oblique view; the acoustic hairs are now seen more or less sideways.

Fig. X. The stria vascularis of the first turn of fig. I. shown under a higher power, about 350.

1. Ligamentum spirale accessorium, including a blood-vessel.

2. Stria vascularis, pigment and capillary blood-vessels amongst the epithelial cells.

3. A sort of superficial cuticle.

Fig. XI. Part of the membrana basilaris seen from the tympanic surface; from a similar preparation as fig. VI. Magnifying power about 300.

1. A capillary blood-vessel.

2. The epithelial-like cells.

3. Reticulum of cell processes.

The hyaline subepithelial membrana propria of the tympanic surface is shown as the slightly stained ground.

Fig. XII. Copied from Waldeyer in Stricker's 'Handbook,' fig. 324. Tympanic wall of the cochlear duct of the dog, viewed from the scala vestibuli after removal of Reissner's membrane. Magnifying power about 300.

I. Zona denticulata Corti.

II. Zona pectinata Todd-Bowman.

1. Habenula sulcata Corti.

2. Habenula denticulata Corti.

3. Habenula perforata Kölliker.

III. Organ of Corti.

d. Insertion of Reissner's membrane.

e and *e'*. The epithelium of the crista spiralis.

f. The acoustic teeth with the interdental furrows.

g. g'. Large swollen epithelial cells of the sulcus spiralis internus; wanting on the left side of the figure.

h. The inner supporting cells.

i. The inner hair-cells.

k. Holes through which the nerve fibres pass.

l. Inner pillars.

m. Their heads.

n. The heads of the outer pillars.

o. The body of the outer pillars.

p. The lamina reticularis.

q. A few mutilated outer hair-cells.

r. The epithelial cells of Claudius, being the outer epithelium of the ductus cochlearis, removed at *s* so as to show the points of insertion of the outer hair-cells.

PLATE XLVI.

Fig. XIII. From a vertical section through the cartilaginous part of the tuba Eustachii of the guinea-pig. Magnifying power about 250.

1. The columnar epithelium; the superficial cells are ciliated. Goblet cells are amongst them.

2. The rudiment of the mucosa, almost entirely cellular.

XIII

XIV

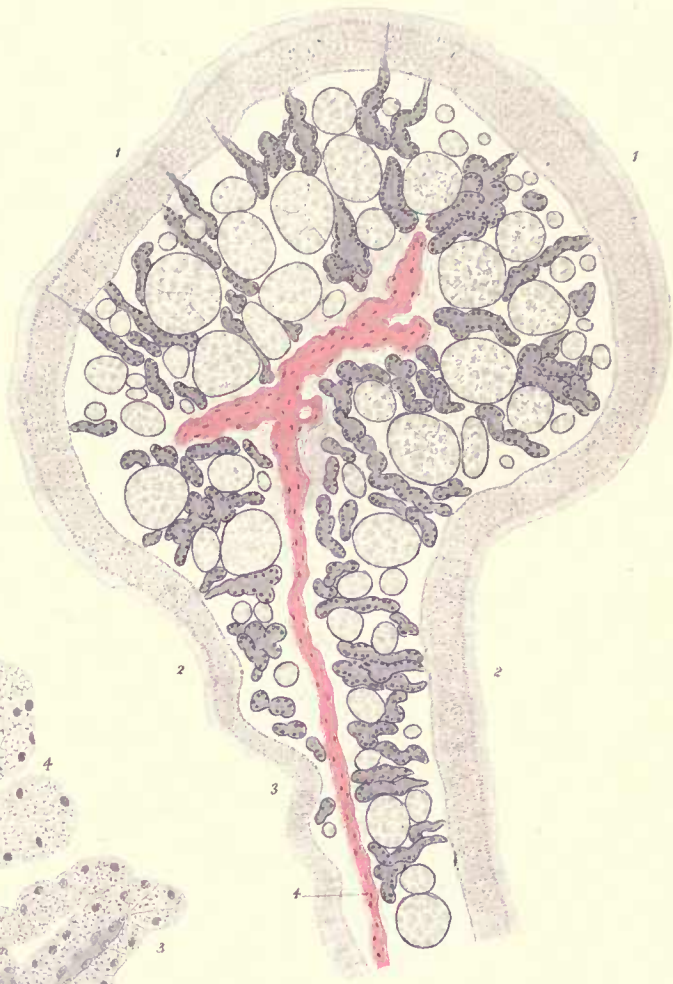

XV

XVI

XVII

XVIII

XIX

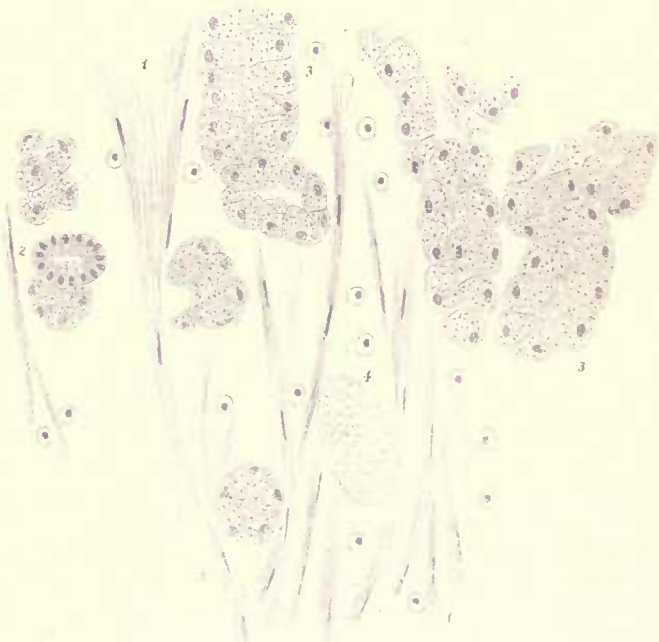

XX

F.E. Kolbach del.

Mintern Bros. Lith.

REESE LIBRARY
OF THE
UNIVERSITY
OF
CALIFORNIA

3. The hyaline cartilage; numerous elastic fibrils in its ground-substance.

Fig. XIV. From a vertical section through the olfactory mucous membrane of the guinea-pig. Magnifying power about 350.

1. The olfactory epithelium.
2. Nerve bundles in transverse section.
3. A tubular gland of Bowman.
4. The mouth of the duct.

Fig. XV. Transverse section from the olfactory region of the guinea-pig. Magnifying power about 100.

1. Thick olfactory epithelium.
2. Thin olfactory epithelium.
3. Ciliated columnar epithelium.
4. Bone.

The tubular glands of Bowman and the nerve bundles of the olfactory nerve, in transverse section, are very abundant in those parts that are covered with the olfactory epithelium. The larger the nerve bundles, the longer the glands and the thicker the olfactory epithelium.

Fig. XVI. Transverse section through the nasal mucous membrane in the respiratory region. Magnifying power about 150.

1. The columnar ciliated epithelium.
2. The mucosa containing diffuse adenoid tissue.
3. The alveoli of a serous gland.
4. Alveoli, the epithelium of which is filled with fatty matter.

Fig. XVII. Part of a serous gland as in the previous figure, more highly magnified, about 300.

1. Part of an intralobular duct.
2. The same branching into several 'intermediary' ducts.
3. Alveoli lined with a layer of columnar or polyhedral epithelial cells.
4. Tubular anastomosing alveoli, showing in some places the continuations of the lumen between the lining epithelial cells. The details of the structure of the duct are not represented.

Fig. XVIII. From a longitudinal section through the olfactory membrane of the guinea-pig. Magnifying power about 400.

1. The olfactory epithelium consists of: a superficial layer of conical epithelial cells each with an oval nucleus; then follow several layers of spindle-shaped cells, each with a spherical nucleus: these are the olfactory cells. Their one extremity is prolonged beyond the free surface as rod-shaped cilia. In the depth is a layer of inverted conical epithelial cells each with a flattened nucleus. The external limiting membrane of v. Brunn is not represented.

2. Plexus of olfactory nerve fibres.

3. Alveoli of serous glands.

Fig. XIX. Part of a serous gland, from a similar preparation as Fig. XVII. Magnifying power about 350.

1. An intralobular duct in transverse section. The columnar cells lining its lumen show well the longitudinal striation. Nucleated fibres, perhaps nerve fibres, surround the duct and appear connected with its epithelium. The lumen of the duct is filled with globules of fatty matter, seen here only in outline.

2. The alveoli; the reticulum in the lining epithelial cells is well shown. Nucleated fibres, perhaps nerve fibres, are seen in the interalveolar tissue, and they appear connected with the epithelium lining the alveoli.

Fig. XX. From a similar preparation as the preceding figure. Magnifying power about 350.

1. Plexus of bundles of unstriped muscle cells.

2. A minute duct.

3. Alveoli of the serous gland.

4. Vein filled with blood.

The ground-substance contains numerous lymph-corpuscles.

CHAPTER XLII.

THE SPLEEN.

THE *framework* of the spleen of man and mammals comprises the capsule, the tissue that is carried into the interior through the hilum and the trabeculæ.

The capsule is a relatively thick membrane covered on its free surface with an endothelium identical with that of the peritoneum. Underneath it is a delicate layer of connective tissue containing numerous networks of elastic fibrils. This is the proper serosa; underneath it is a feltwork of trabeculæ of connective tissue, crossing each other in various directions and containing a network of blood-vessels and numerous medullated nerve fibres. In the capsule of most mammals, underneath the serosa, there exists a great amount of unstriped muscle tissue in bundles (Kölliker). These are arranged in most instances as a deep longitudinal and a superficial transverse layer. But the bundles within the same layer are connected into plexuses.

They are very conspicuous in the capsule of the spleen of the pig, horse, and ox (Billroth, Kyber), but also in that of the dog. In the spleen of the ape there exists a thin longitudinal layer of muscle cells only in the deeper part.

In the human spleen there exist only thin bundles of muscle cells (W. Müller, Kyber) arranged in plexuses.

In connection with the capsule are the trabeculæ. These are of various sizes, and, passing into the interior of the organ, i.e. into the parenchyma, divide repeatedly, and the branches reuniting form a dense plexus pervading the parenchyma in all different directions. The trabeculæ are of very various thicknesses and lengths, and hence also the meshes are of various sizes and shapes. Most of the trabeculæ are cylindrical, but some of them are also flattened, bandlike. Very fine branches come off from them, and terminate freely in the parenchyma.

The trabeculæ are at the same time the carriers of the vascular trunks, both blood-vessels and lymphatics, and of the nerve branches, and as such form a continuity with the trabeculæ passing in at the hilum.

The trabeculæ of the human spleen are made up chiefly of fibrous connective tissue, but there exists also a considerable amount of unstriped muscular tissue (W. Müller, Meissner, Frey, Kyber), longitudinally arranged, both in the large and

small trabeculæ. I have seen them even in the finest trabeculæ. In the large trabeculæ they are met with as longitudinal bundles belonging, as it were, to the adventitia of the large vessels embedded in the trabeculæ.

The trabeculæ of the spleen of the ape contain a great amount of longitudinal bundles of unstriped muscle cells, and in most mammals the trabeculæ are almost entirely muscular.

The *parenchyma* consists of the Malpighian corpuscles and the pulp.

To understand the former it is necessary to follow the arterial branches of the spleen. The splenic artery, having entered the organ in company with the vein, is embedded in trabecular continuations of the tissue of the hilum, which, as mentioned above, consist of connective tissue and a variable amount of unstriped muscle tissue. The artery soon leaves the vein and divides dendritically into smaller branches. Most of these are ensheathed not in fibrous connective tissue but in adenoid tissue. As long as the larger branches of the artery are embedded in the trabeculæ, there exists in and around their adventitia a continuous system of lymph-spaces, interfascicular spaces, and lymph-vessels (Kyber). But on the smaller arterial branches these lymphatics are replaced by a solid mass of adenoid tissue which now surrounds the vessel like a cylindrical sheath. These adenoid sheaths are supplied from their respective arteries with elongated meshes of capillary blood-vessels. The tissue thus constituted represents what is commonly described as the Malpighian corpuscles.

As a rule the amount of the adenoid tissue around the same arterial branch varies from place to place, now becoming reduced to a very thin layer, then again suddenly enlarging into a conspicuous oval or cylindrical body. But in all instances it is simply an accumulation of vascular adenoid tissue in the sheath of the arterial branches. The latter are surrounded by it in an unequal manner; in most instances there is a greater amount of the adenoid tissue on the one side of the vessel than on the other, only in few cases the tissue ensheathes the artery in an uniform manner. Hence in the majority of cases a transverse section through the artery and its sheath shows the former in an excentric position. In man and mammals these adenoid masses form, as just mentioned, in some places spherical or oval enlargements, but they always retain the character of sheaths around the arterial branches, supplied by these latter with networks of capillaries. The apparently isolated spherical or oval masses of adenoid tissue seen in sections through the spleen, on careful examination always show the artery transversely or obliquely cut; they are therefore transverse or oblique sections through cylindrical masses. And for this reason it is incorrect to describe the Malpighian corpuscles, as is occasionally done, viz. as isolated spherical or oval masses of adenoid tissue. Many arterial branches terminate in these adenoid masses, breaking up ulti-

mately into networks of capillaries, but in a good many instances, especially towards the periphery of the spleen, the adenoid sheath suddenly ceases, and the arterial branch, reduced in size, and, to a certain extent, also in structure, is continued beyond the sheath (see below).

As regards the structure of the Malpighian corpuscles they contain adenoid tissue of the same nature as in other lymphatic organs, viz. a honeycombed adenoid reticulum with the flattened endotheloid plates fixed on it; each of these latter possesses a large oval flattened nucleus; in the meshes of the reticulum lie the ordinary lymphoid cells, most of them with one or two spherical nuclei surrounded by protoplasm.

The capillary blood-vessels are not so numerous as in other adenoid tissues, e.g. in the cortical lymph-follicles of the compound lymphatic glands. But, just as in these, they obtain a special sheath from the adenoid reticulum and its endotheloid plates.

The Malpighian corpuscles are everywhere on their periphery in immediate contact with the pulp, but the reticulum is here denser, its meshes smaller, and the lymphoid cells are closer (W. Müller).

The *pulp* is no doubt the most difficult portion of the spleen. A small bit of fresh pulp teased out shows lymphoid corpuscles of various sizes, some with one, others with two or more nuclei, and all possessed of amœboid movement (Cohnhein, Frey, and others); amongst them are some that contain in their interior coloured blood corpuscles or groups of smaller or larger clumps and granules of yellowish-brown pigment.

Then there are flattened endotheloid plates, some larger, others smaller; some with one, others with two or more nuclei; then spindle-shaped or club-shaped cells.

In a section through the well-hardened spleen the matrix of the pulp is a honeycombed structure, composed of flattened endotheloid plates, each with one or two oval flattened nuclei (Klein).

In the pulp of the young spleen, especially in man, pig, rat and mouse, dog and guinea-pig, some of the cell plates contain a huge nucleus, lobed or beset with numerous knoblike prominences as if small nuclei were budding from it; it is finally split up into three, four, or more small nuclei (Kölliker, Klein).

The cell-plates are possessed of finer, more fibrous, or as is more commonly the case, broader membranous processes coming off from them in various directions; by the anastomosis of these processes the honeycombed nature is produced. The spaces are of various sizes, some not larger than a coloured blood corpuscle, others three, four, and more times the size.

The cell-plates vary in size in different animals, and even in the various places of the spleen of the same animal. They are well shown in the pig, dog, and man. When

they are small and their nucleus conspicuous, as in the rat, guinea-pig, and ape, their nature as cell-plates arranged as a honeycomb is not easy to ascertain.

The substance of the cell-plates is transparent, and contains in many instances smaller or larger clumps of finer or coarser yellow-brown pigment. Both the cell-plates and the spherical or oval lymphoid cells (see below) contain sometimes coloured blood-corpuscles in variable amount. These are the cells filled with blood-corpuscles first pointed out by Kölliker. Their occurrence is not a constant one; in the human spleen they are occasionally missed. They are very conspicuous in size and number in the spleen of the pig and man in cases of great congestion during life.

In connection with these cell-plates are spherical or oval corpuscles identical in aspect, size, and nucleus with lymphoid cells; they are either connected with the cell-plates by a shorter or longer stalk, or are altogether free of them, hence it is probable that they are developed from them by a process of gemmation.

In some places the meshes of the honeycombed matrix become enlarged and fused into a continuous canal-like sinus; in this case the cell-plates arrange themselves like an endothelial lining of the sinus, the cells becoming at the same time more spindle-shaped or club-shaped, and imbricated with their outer extremity. Such a sinus represents a venous radicle of the pulp (see below), and its endothelium, when seen in transverse section, appears therefore like a layer of polyhedral cells. But, as mentioned before, they are continued outwards by membranous processes into the honeycombed matrix.

Immediately outside the endothelium of these sinuses, in the pulp of man and ape, is a layer of delicate elastic fibrils arranged circularly around the sinus, so that when this is viewed from the surface it appears surrounded by rib-like fine fibrils. When viewed in transverse section the endothelium appears bordered on its outside by a row of dots. These fibrils are the supporting fibrils seen already by Billroth, Frey, and Kyber. I do not miss them on the venous sinuses of the pulp of man and ape, but do not find them in those of other mammals.

The most important part of the spleen pulp are the blood-vessels.

As has been mentioned above, the arteries divide dendritically, and having parted company with the veins, are all ensheathed in the adenoid tissue of the Malpighian corpuscles; to these they give off the capillary blood-vessels which, as mentioned above, are characterised by their special sheaths. They form a uniform network (Schweigger-Seidel, Kyber), with wide meshes (Schweigger-Seidel, Stieda).

Some of the arterial branches of the Malpighian corpuscles do not lose themselves altogether in these latter but pass beyond them into the pulp.

There are, in addition, arterial branches in the pulp which never had anything to

do with the Malpighian corpuscles (Basler, Fenenko, Kyber). They anastomose with one another (Basler, Kyber). In man, ape, and pig I find that they do not possess an adenoid sheath but a sheath of a special kind in which more or less concentrically arranged endotheloid plates form a conspicuous portion; between these are a few lymph-cells. Billroth, Schweigger-Seidel, W. Müller, Fenenko, Kyber, and others, have seen these vessels and considered them as capillaries; their sheath has been called by Schweigger-Seidel the 'capillary sheath'; but I do not agree with these observers as regards the nature of these vessels, since I think they are not simple capillaries but minute arteries.

All capillary blood-vessels belong to the Malpighian corpuscles, and at the margin of these they open into the spaces of the honeycombed matrix of the pulp. These lead into the venous sinuses above described (cavernous veins of Billroth), and these again into the large venous trunks embedded in the trabeculæ. The venous sinuses form beautiful plexuses (Billroth, Frey, Schweigger-Seidel, Kölliker, and others); in the pulp of man and ape the individual sinuses are of an elongated tubular nature, and the matrix between them appears therefore more distinctly of the nature of tracts, the intervascular tracts of Billroth. In the spleen of man and ape there is always an appreciable amount of pulp tissue without venous sinuses to be met with in the immediate circumference of many Malpighian corpuscles.

According to Billroth, Grohe, Sasse, Kölliker, and, more recently, Kyber, the intervascular tracts of the pulp tissue contain capillary blood-vessels, and these form the connection between the arterial system of the Malpighian corpuscles and the venous sinuses (see above); but according to W. Müller, Frey, and many others, with whom on this point I completely agree, the pulp tissue between the venous sinuses does not contain any capillaries, and the spaces of the honeycombed matrix are the inter-communicating spaces between the arterial branches including the capillaries of the Malpighian corpuscles, and the venous radicles or sinuses.

The Malpighian corpuscles, are identical with the lymph-gland structures of other regions, e g., in the alimentary and respiratory organs. But the pulp is considered by some as the tissue in which coloured blood-corpuscles are destroyed, hence the presence of the clumps of the blood pigment; in the very slow passage of the blood through the honeycomb of the pulp matrix the blood corpuscles can be readily taken up by the cell-plates and lymphoid cells, in which by and bye they become broken up. The pulp is at the same time most probably also the birthplace of colourless or lymphoid cells, as mentioned above.

According to the more recent researches of Bizzozero and Salvioli it appears that coloured blood corpuscles are also newly formed in the spleen pulp.

The Lymphatics.—As has been shown by Tomsa and Kyber, the capsule contains a plexus of large lymphatic vessels, the superficial lymphatics of Tomsa or the capsular lymphatics of Kyber. They are continuous with the lymphatics of the trabeculæ. These latter appear as dense plexuses either of real tubes or of lymph clefts situated within the trabeculæ, or at their margin between their surface and the adjacent pulp tissue.

The lymphatics of the trabeculæ anastomose with the plexus of the lymphatics situated in the sheath of the arterial trunks, the perivascular lamphatics of Kyber. These latter are either tubular lymphatics or merely a network of intercommunicating lymph-sinuses. They extend along the arteries, and penetrate also as minute clefts and lacunæ into the adenoid tissue (Tomsa).

The pulp tissue does not contain any lymphatics (Tomsa, Kyber), except at the margin of the trabeculæ. In the hilum large lymphatics of the capsule are directly connected with the perivascular lymphatics (Kyber).

The nerves occur as pale non-medullated fibres in the immediate neighbourhood of the arteries. According to W. Müller they seem to terminate in the capillary sheaths of Schweigger-Seidel, above mentioned.

PLATE XLVII.

Fig. I. From a vertical section through the spleen of the guinea-pig; the blood-vessels are injected with carmine gelatine. Magnifying power about 60.

1. The arterial branches are ensheathed in the Malpighian corpuscles, indicated as densely aggregated nuclei.

2. Between the Malpighian corpuscles is the pulp tissue, showing a dense network of minute spaces.

3. The venous radicles or sinuses.

Fig. II. From the spleen of the ape; the blood-vessels are injected with carmine gelatine. Magnifying power about 300.

1. Trabeculæ containing unstriped muscle cells.

2. The network of venous sinuses, lined with endothelium.

3. Venous sinuses in transverse section; the outer supporting fibrils are shown as if cut away obliquely. The pulp tissue shows the minute blood-spaces and channels very well injected.

Fig. III. From the same preparation as fig. I. but more highly magnified; about 350.

1. Part of a Malpighian corpuscle; its vessels are well shown.

2. Pulp tissue immediately around the Malp. corpuscle. The capillaries of this latter open into the network of spaces of the pulp.

3. A venous vessel.

Fig. IV. From the same spleen as in fig. II. Magnifying power about 100.

1. Trabeculæ.

2. Malpighian corpuscle.

3. Pulp tissue; the venous sinuses are seen in transverse section.

Fig. V. From a section through the normal spleen of a monkey. Magnifying power about 350.

1. An arterial branch injected with carmine gelatine.

2. Part of a Malpighian corpuscle. The artery within this latter is surrounded by concentric layers of flattened endotheloid cells, spindle-shaped looking in the profile view. The outlines of the cells are not well shown.

This condition precedes the obliteration of the artery. In some of the Malpighian corpuscles of the ape the arterial branch is altogether replaced by a larger or smaller concentric body composed of nucleated flattened cells.

Fig. VI. From a vertical section through the spleen of a rat, showing the endotheloid cells forming the matrix of the pulp. Magnifying power about 350.

1. A trabecula, containing numerous unstriped muscle cells, indicated by their nuclei.

2. Endotheloid plates of the pulp, containing large budding nuclei.

3. A large endotheloid cell-plate filled with coloured blood corpuscles.

4. A large endotheloid cell whose nucleus is dividing, being in the stage of the 'Monaster.'

Some of the endotheloid cells contain clumps of blood-pigment. Between the endotheloid cells are small nuclei. These belong either to colourless blood corpuscles or to lymphoid cells more or less connected with the endotheloid cells.

The endotheloid cells are more or less branched and connected into a honeycombed spongy substance, not well shown here.

Fig. VII. From a vertical section through a monkey's spleen. Magnifying power about 60.

1. The capsule.

2. The trabeculæ.

3. Malpighian corpuscles in longitudinal section.

4. The same transversely cut.

5. Pulp tissue containing clumps of blood-pigment.

Fig. VIII. From a section through the pulp of the human spleen. Magnifying power about 250.

a. Venous sinus, lined by a layer of endothelial cells.

b. The nucleated cell plates forming a honeycombed reticulum, the matrix of the pulp.

The endothelial cells of the venous sinus and the cells of the matrix form a continuity.

Fig. IX. From a vertical section through the peripheral portion of the spleen of the pig. Magnifying power about 300.

1. The circular layer of unstriped muscle cells of the outer capsule.

2. The longitudinal layer of the capsule.

3. The pulp tissue next to the capsule. The spaces of the matrix are much distended by blood corpuscles. The endotheloid plates are well shown; many contain in their interior coloured blood corpuscles.

Fig. X. From a section through the spleen of the pig. Magnifying power about 350.

1. Last outrunners of trabeculæ.

2. Endotheloid plates forming the honeycombed matrix of the pulp. The nuclei of the endotheloid plates are well stained. A few spherical or oval lymphoid cells appear connected with the matrix.

Fig. XI. From a section through the pulp of the human spleen. Magnifying power about 450.

1. Endothelial cells of a venous sinus seen from the surface.

2. The circular supporting fibrils of the venous sinuses.

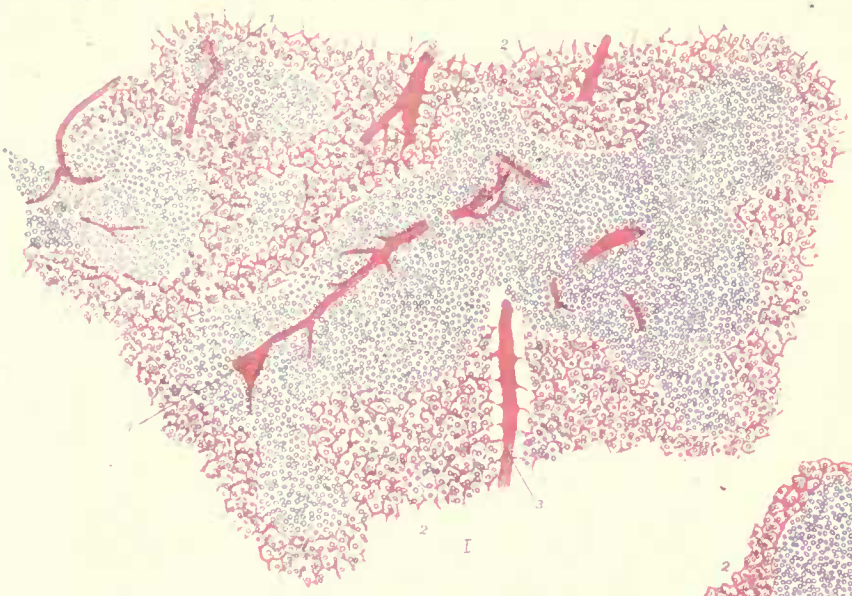

I

II

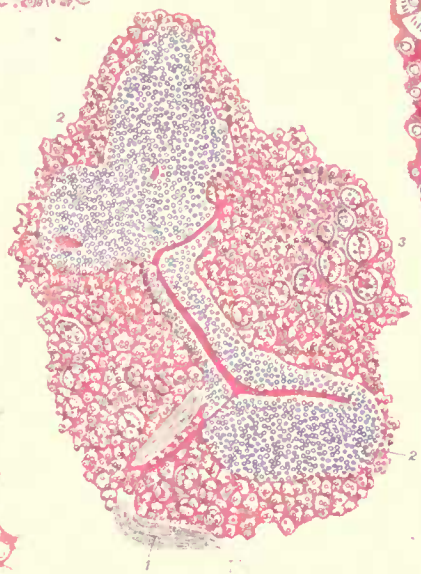

V

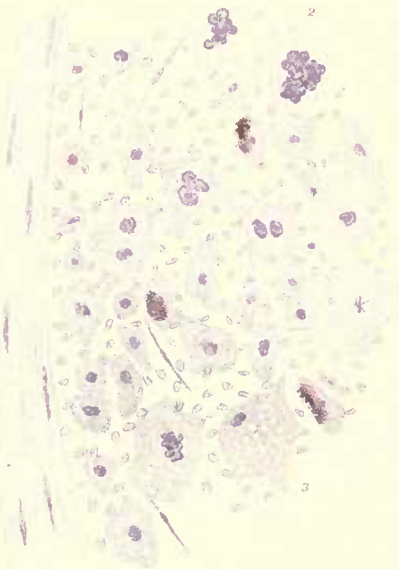

VI

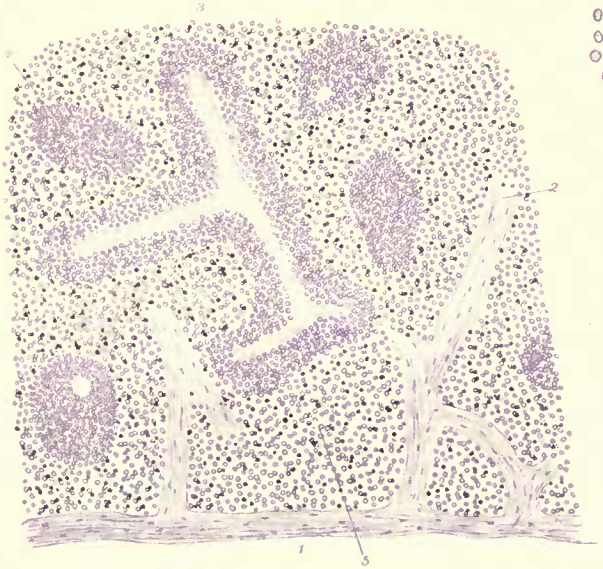

VII

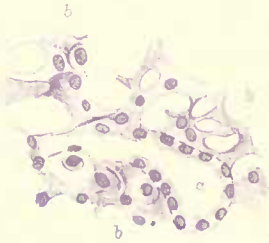

VIII

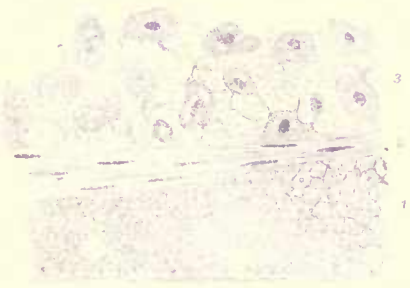

IX

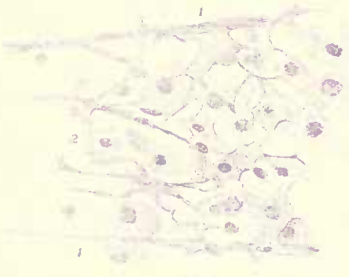

X

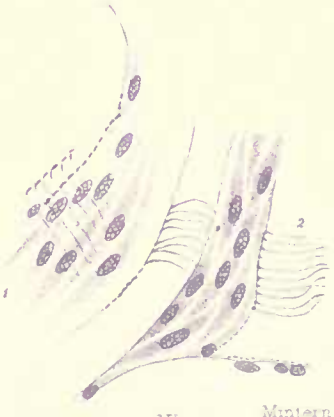

XI

REESE LIBRARY
OF THE
UNIVERSITY
OF
CALIFORNIA.

CHAPTER XLIII.

THE DUCTLESS GLANDS.

THESE are: the frontal or large lobe of the pituitary gland or hypophysis cerebri, the thyroid gland, the carotic gland of Luschka, the suprarenal body and the coccygeal gland of Luschka. These organs have the same developmental history, and resemble each other in structure in many respects. They are all derived from the hypoblast forming the wall of the fœtal alimentary canal in its earliest stage, and are therefore of epithelial origin. The hypophysis is an outgrowth of the cephalic extremity of the alimentary canal (the upper wall of the pharynx), the thyroid gland and carotic gland of its cervical part, the suprarenal body of the trunk part, and the coccygeal gland of the caudal end of the alimentary canal.

In all of them the epithelial structures, derived from the hypoblast, and the vascular connective tissue, derived from the mesoblast, form the two chief constituent elements, and in this respect they resemble other secreting glands. Unlike these latter they do not possess any special ducts to carry away the secretion, but this is probably effected by their lymphatics (see below).

1. THE HYPOPHYSIS CEREBRI.

All that will be said here of this organ refers only to its frontal or larger lobe, since the posterior or smaller lobe is altogether of a different origin and nature, being derived, with the infundibulum, from the central nervous system.

A relatively thick capsule composed of lamellæ of fibrous connective tissue is connected with the connective tissue in the interior. This latter is composed of fine lamellæ which by branching and reuniting form a dense plexus with smaller or larger, spherical or oblong or even cylindrical spaces. These lamellæ are very delicate, and consist of fine bundles of connective-tissue fibres and on their free surface, i.e. that facing the spaces, appear lined with a layer of flattened endotheloid (connective-tissue) cells. The spaces, the alveoli, contain spherical or oblong or cylindrical masses of the parenchyma. In some places, especially in the periphery near the anterior or convex surface, these masses seem connected with one another, so that they form a more or less continuous plexus of cylindrical streaks, but in most other places they seem isolated from one another by the connective-tissue septa.

The boundary of the alveoli is formed by a delicate membrana propria, which in some places includes staff-shaped nuclei and is in connection with branched nucleated cells of the interior of the alveoli (see below).

The structure of the alveoli is an uniform one, they being composed of relatively large epithelial cells, each with a single oval or spherical nucleus. The size of the epithelial cells is, however, subject to considerable variations, some being twice as large as their neighbours. In some alveoli they appear as if in a single row and forming a complete lining, the centre of the alveolus is then found occupied by a branched nucleated corpuscle, connected on one or the other side with a similar nucleated cell. The nucleus of the latter kind of cells is small, oblong, staff-shaped or angular, and always stains very deeply in dyes ; the cell substance is always small in amount as compared with that of the epithelial cells. In this respect the appearance is similar to that presented by an alveolus of the pancreas, the centre of the alveolus in both cases being occupied by a centro-acinar cell of a different aspect and nature from the lining epithelial cells (see the chapter on the pancreas).

But there are a great many alveoli in which this simple arrangement is altered, the epithelial cells occurring in more than a single row and also the interepithelial cells being then more numerous.

In some alveoli there exists a central cavity of variable but small dimensions, identical in appearance to the lumen of other gland alveoli. In other instances it is, however, filled up by a homogeneous gelatinous substance, slightly staining in dyes and extending from the lumen a short distance between the lining cells.

The interalveolar septa contain capillary blood-vessels, which, as in other glands, surround the alveoli as a rich network.

Between the interalveolar connective tissue, or, more correctly speaking, between the endotheloid lining of the interalveolar septa and the alveoli themselves, there are distinct lymph-spaces which surround the alveoli in the same way as was described in former pages of other glands, as testis, salivary glands, lachrymal glands, &c. They form an intercommunicating system. Near the capsule these interalveolar lymph-spaces are seen in distinct connection with lymphatic vessels. These are very numerous and form plexuses. They are the efferent vessels and are comparable to the superficial lymphatics of other glands, while the circumalveolar lymph-spaces represent the deep lymphatic system.

2. The Thyroid Gland.

As in the pituitary gland so also here we find a connective-tissue capsule with elastic

fibrils, forming the boundary of the organ. In connection with it are thicker or thinner septa of the same structure subdividing the contents of the gland into lobes and lobules. These septa are the carriers of the large blood-vessels and lymphatics. The interlobular septa give off fine lamellæ which penetrate into the interior of the lobule and repeatedly branching form a network with smaller or larger, spherical or polyhedral, or oblong meshes containing the gland-alveoli or gland-vesicles.

The amount of the interalveolar connective tissue varies greatly in different animals; it is greater in man than in mammals (Kölliker).

The alveoli within the same lobule are of various sizes and shapes, some being spherical, others oval, some large, others small. This in a certain degree depends on the amount of secretion present in their cavity. Most of them possess a central lumen or cavity. Each lobule of the growing thyroid contains a greater or smaller number of alveoli, which are conspicuous by their smallness and by the minuteness of their lumen. Some alveoli appear more tubular and branched, that is to say, two or three appear to communicate with one another (Zeiss, Baber).

Such branched or tubular alveoli are more commonly found in the young than in the adult state (Baber). They are easily explained thus (Baber): In the earliest stage the thyroid is composed of a plexus of solid cylindrical masses of small polyhedral epithelial cells, derived from the hypoblast of the cervical part of the foregut; these cylindrical masses are separated from one another by connective tissue with blood vessels derived from the mesoblast, just as is the case in other glands (lung, ovary, salivary glands, mucous glands, &c.). As development proceeds, the epithelial cylinders, while continuing in their growth, become gradually subdivided into alveoli by the ingrowth of the connective tissue; the alveoli are at first connected with one another, but sooner or later they become severed and isolated. But there always remain a few which retain their mutual connection. The alveoli by and bye become provided with a central cavity.

It is quite probable that as long as the thyroid grows there is a new formation of alveoli, hence the great number of minute alveoli and the greater frequency of branched or intercommunicating ones in the young than in the old gland.

Each alveolus is limited by a membrana propria. This is a network of nucleated flattened cells, as in other glands; it is connected with minute nucleated spindle-shaped or branched cells, extending between the epithelial cells lining the lumen up to this latter.

The epithelial cells are of various shapes, according to the size of the alveoli; and they differ also in different animals. In man and mammals they are more or less columnar cells, each with a slightly oval nucleus. Where the alveoli are large, owing to a great

quantity of secretion distending them, the epithelial cells are shorter, and look more like polyhedral cells; their nucleus is then spherical.

The contents of the alveolar cavities or lumen are homogeneous, transparent, albuminous, viscid, semi-fluid, and slightly tinged yellow (Kölliker, Frey, Baber); and its amount greatly influences the size of the alveoli. Under pathological conditions there are spherical or oval, larger or smaller, highly refractive, colloid, globular masses to be met with in the cavity of some of the alveoli.

In the contents of some alveoli may be met with nucleated cells in various states of degeneration. They are derived from large, granular, nucleated cells, contained in the interalveolar connective tissue, and called by Baber parenchymatous cells. Their number varies greatly in the thyroid of different animals; in that of the dog Baber saw them comparatively often. They appear to migrate through the epithelial lining of the alveoli into the cavity of these latter. Here they swell up and disintegrate, and thus help to increase the amount of the alveolar contents.

One of the most interesting facts discovered by Baber, and which will be published by him in a forthcoming paper, is the presence of large quantities of blood in the alveolar cavities of the thyroid of man, mammals, and lower vertebrates. The coloured and colourless blood corpuscles, the former of course in overwhelming superiority, are seen to become gradually disintegrated and lost in the alveolar contents. The yellow tinge of the alveolar contents is thus easily explained, being probably hæmoglobin or a derivation of it.

The great quantity of coloured blood corpuscles that is met with in the alveoli of perfectly normal glands of man and animals no doubt proves that one at least of the functions of the thyroid gland is the removal and destruction of the coloured blood corpuscles.

The capillary blood-vessels form rich networks around the alveoli, but they, i.e. the capillary vessels, are contained in the interalveolar connective tissue. Between the alveoli and the interalveolar connective tissue exists, in man and mammals at any rate, an inter-communicating system of lymph-spaces surrounding like sinuses a greater or smaller part of the circumference of the alveoli (Baber). They empty themselves into lymphatic vessels with valves contained in the interlobular septa and closely following and ensheathing the arterial branches (Baber). The efferent trunks form a network on the surface, i.e. in the capsule, of the gland.

The lymphatics of the thyroid gland, both the interalveolar as well as the interlobular and capsular lymphatics, contain occasionally a tenacious semifluid homogeneous transparent substance identical with the contents of the alveoli (Baber), and it must

be therefore assumed that the lymphatics are concerned in the removal of the contents of the alveoli.

The alveoli of the thyroid gland being surrounded by a dense network of capillary blood-vessels, just like the alveoli of other secreting glands, it is highly probable that the epithelial lining also of the former, i.e. of the alveoli of the thyroid gland, pours out a secretion into the alveolar cavities ; this helps to macerate, as it were, and to break up the blood thrown into them (cavities).

The so prepared alveolar contents are absorbed by the interalveolar lymphatics and finally carried away altogether through the efferent lymphatic vessels.

The absorption of the alveolar contents by the interalveolar lymphatics is, no doubt, effected in the same manner as in other organs, viz. through the interstitial cement-substance between the epithelial cells (see Chapter XXII. p. 175).

3. The Suprarenal Body.

This organ is the least understood, being the most complex of the ductless glands. In the suprarenal body of man and mammals the *cortex* is distinguished from the *medulla*. The first shows an outer, a middle, and an inner zone. The middle zone is always the most conspicuous one, and on account of its general aspect is called zona fasciculata (Arnold) ; but there is less reason for calling the outer zone zona glomerulosa ; the inner zone is the zona reticularis. The medulla is conspicuous by the dense plexuses of its blood-vessels ; it is well developed, and forms a continuous central mass throughout the organ in most mammals ; but in man I do not find it of this nature, since in many places it is wanting, or is reduced into insignificant thin patches ; thus in the marginal portions very little of it is to be met with.

The *framework* is made up of the capsule and the connective tissue of the interior. The capsule is of variable thickness, and composed of trabeculæ of fibrous connective tissue with numerous networks of elastic fibrils between. The deepest layer of it contains slender bundles of unstriped muscle cells. In connection with the capsule are thinner and thicker septa and trabeculæ passing inwards ; these contain longitudinal bundles of unstriped muscle cells ; they are especially distinct and numerous in the dog. In the outer zone of the cortex the connective-tissue septa and trabeculæ are relatively thick and anastomose into a plexus. In the zona fasciculata they become very attenuated, and possess a longitudinal arrangement, i.e. radiating from the capsule towards the interior ; they are very numerous and arranged more or less regularly, so that longitudinal spaces are left between them of very nearly equal diameter. In the inner zone of the cortex the connective-tissue septa become again arranged into plexuses

with small uniform meshes. The framework of the medulla is a more or less uniform dense plexus, or rather honeycomb of septa and trabeculæ, which always contain a number of unstriped muscle cells.

The connective tissue supporting the large venous branches in the centre of the suprarenal body always contains numerous bundles of unstriped muscle cells running longitudinally, i.e. parallel, with the veins. In the human organ these bundles are very conspicuous by their number and size; they are continued into the medulla.

As regards the *parenchyma*, the following is to be noticed: In each of the meshes of the framework of the outer zone of the cortex lies a spherical, oval, or elongated mass; the latter is generally much convoluted, and extending more or less parallel to the surface. Each of these masses is composed of granular-looking, small, polyhedral, or larger elongated columnar or conical epithelial cells, each with a spherical or slightly oval nucleus.

These masses are of various sizes, and are directly continuous with the cell-streaks of the next following zona fasciculata. But in this latter zone the cells are as a rule more opaque, and their nucleus is smaller and stains readier in dyes.

In the horse and dog the cell-masses of the outer zone are band- or trough-shaped, and more or less looplike. They are composed of beautiful slender columnar cells, arranged transversely (Kölliker, Eberth).

In the suprarenal body of the human fœtus, and in that of the adult guinea-pig, I have in isolated cases seen a homogeneous gelatinous substance contained in a continuous space within one or the other of the cell groups, so that these latter looked then like tubes or alveoli lined with epithelium, their lumen being filled with that homogeneous gelatinous secretion. Possibly Grandry's tubes and vesicles are to be explained in this way.

The middle zone or zona fasciculata contains in each of the elongated spaces of the framework a cylindrical streak of polyhedral transparent cells, each with a relatively large spherical transparent nucleus. The streaks are anastomosing with one another. This is especially conspicuous as we pass into the inner zone.

The cell substance contains in most instances smaller and larger oil globules. *Between the cells exists an anastomosing system of narrower and broader clefts, channels, and lacunæ*, which belong to the lymphatic system (see below). The appearance of these spaces between the polyhedral cells is very similar to that presented by the bile capillaries between the liver cells.

The inner zone or zona reticularis is directly continuous with the previous one, and is composed of smaller or larger groups of polyhedral cells, whose outlines are generally more or less rounded off.

These groups appear as single cell-rows or as cylindrical cell-masses anastomosing into a plexus, or they appear as small spherical or oval cell-clusters.

The cells are slightly larger and their substance is more opaque than in the zona fasciculata, and they show as a rule in the human organ a more or less distinct yellowish brown tint.

The meshes of the medulla contain cylindrical or irregularly shaped anastomosing streaks of very transparent epithelial cells; their shape is columnar or polyhedral or angular, or even branched, and their nucleus is spherical. These cells are directly continuous with the cell groups of the inner zone of the cortex, but very much more transparent and fragile.

In the guinea-pig they contain clumps of smaller or larger brownish pigment granules.

In all parts of the parenchyma, viz. cortex and medulla, minute branched cells extend from the connective tissue separating the cell groups into these latter, and they appear here situated between the epithelial cells as minute branched corpuscles, each with a deeply stained nucleus.

Those portions of the human suprarenal body that do not contain any medulla, and where consequently, between the central venous trunks and the outer capsule, there exists only cortex, show in many places the following peculiarity of structure: the part that in other places corresponds to the inner zone of the cortex, and, owing to the absence of the medulla, ought to lie here centrally, i.e. next to the large venous trunks of the centre, is separated from these latter by a layer of cells in aspect and arrangement very similar to the zona fasciculata, except that the cells form cylindrical or oval cell streaks grouped together into lobules, whose rounded surface faces the central vein; see fig. IV. of Plate XLVIII.

The cortex is very richly supplied with capillary blood-vessels which form dense networks; the meshes of these vary of course in the three different zones, being more polyhedral in the outer and inner, more elongated in the middle or fascicular zone. The medulla is supplied with a very rich network of wide capillaries, which may be almost called veins. But in all parts the blood-vessels are embedded in the framework.

Between the septa and trabeculæ of the framework on the one hand, and the cell groups on the other, we find lymph-spaces and lymph sinuses which in the zona fasciculata possess the shape of clefts and channels. They distinctly take up the intercellular spaces and lacunæ above mentioned. These latter are best seen between the cells of the zona fasciculata, but I do not miss them also in other parts of the cortex.

In the capsule (Kölliker, Arnold) and in the connective tissue around the central veins lie the efferent lymphatic vessels with valves; they are connected into a plexus. Moers and Arnold saw also lymphatics around the arteries.

The nerves are very numerous, and composed of non-medullated fibres; and in the medulla they form rich plexuses. In connection with these are isolated or groups of ganglion cells (Holm, Eberth).

In the capsule of the suprarenal body of the dog I find real ganglia in connection with nerve bundles.

It seems probable that the cells of the suprarenal capsule, at any rate those of the cell groups and streaks of the cortex, secrete something which, in the first place, is poured out into the intercellular canals and lacunæ, and from here is brought into the lymph sinuses between the cell groups and the framework, and finally is carried into the efferent lymphatics. The muscle bundles of the septa and trabeculæ are no doubt of great value in furthering this current.

4. The Glandula Coccygea and Glandula Carotica.

The glandula coccygea, situated in front of the apex of the os coccygis, has been discovered by Luschka, who justly considered it as a gland. It is composed of a framework and parenchyma. The first consists of a capsule of fibrous-connective tissue, which sends into the interior trabeculæ and septa, dividing and subdividing, so that the interior is cut up into an intercommunicating system of spherical oblong or cylindrical spaces. The septa and trabeculæ contain in some places bands or bundles of unstriped muscle cells (Sertoli).

The spaces of the framework are occupied by the parenchyma. This last consists of spherical or cylindrical masses of cells, the gland vesicles and tubes of Luschka, connected into a plexus. The cells are polyhedral epithelial cells, each with a spherical nucleus. According to Luschka the cells in the newborn child are ciliated. Each of the spherical or cylindrical masses contains more or less in its centre a capillary blood-vessel possessed of its own endothelial wall (Sertoli, Eberth), so that, unlike other gland alveoli and gland tubes, which are surrounded by a network of capillaries contained in the framework, in this instance the capillary blood-vessels are within the alveoli. The capillaries are much convoluted and wavy and are derived from the arteria sacralis media.

Of the lymphatics nothing satisfactory is known.

Numerous bundles of non-medullated sympathetic nerve fibres enter the gland and in the stroma form rich plexuses. Their termination is not known. Luschka described special budlike terminations of them similar to Pacinian corpuscles, but they, as well as the existence of the ganglion cells mentioned by Luschka, are questioned by Krause, Arnold, and Eberth.

The glandula carotica of Luschka (ganglion intercaroticum auctorum) is of the same structure as the glandula coccygea.

CHAPTER XLIV.

THE INDIRECT DIVISION OF THE NUCLEUS OF THE EPITHELIAL CELLS.

In former chapters it has been repeatedly mentioned (see the seminal epithelial cells, the epithelium of the mucous membranes, the epidermis of the skin, the endothelium, &c.) that the nucleus of the epithelial cells undergoes a complicated series of structural changes which lead to the division of the mother nucleus into two daughter nuclei.

This mode of division is the indirect one as opposed to the direct one, or that of Remak, viz. when the nucleus at once, without any intermediary structural changes, becomes segmented into two, three, or more daughter nuclei.

In the process of indirect division also the cell-protoplasm, which we have described as of a reticulated structure, becomes divided into two daughter-cells, each including one daughter-nucleus. This division of the cell itself takes place only after the mother-nucleus has nearly or completely divided.

Not intending to give here a lengthy description of all those cases in which an indirect division of the nucleus has been observed, I must be content to mention them here by name only, referring the student for a detailed summary of them to Strassburger's great work on 'Cell-formation and Cell-division,' third edition, Jena, 1880.

Bütschli saw it in the ova of nematodes, snails, and in the sperm cells of blatta. Auerbach in the ovum of ascaris nigrovenosa and strongylus auricularis. Fol in the ovum of pteropodes, heteropodes, and sagitta. Strassburger in a great many different vegetable cells. O. Hertwig in the ovum of toxopneustes lividus, hirudo, asteracanthion, and in the ovum of a number of other invertebrates (cœlenterata, vermes, mollusca), and in the ovum of the frog. Mayzel in the normal and regenerating epithelium of the cornea of the frog, newt, lizard, rabbit, cat, dog, ape, in various birds, in the epidermis of the skin of man and rabbit, in the epithelium of the human œsophagus, in the corneal corpuscles, in cancer cells, in the cells of the hyaline cartilage, in Descemet's endothelium of the frog, in the ovum of fishes and newts, and in the embryo-cells of these animals. E. van Beneden in the embryo-cells of the rabbit. Balfour in the blastoderm-cells of the elasmobranchs, in the germinal epithelium of the young ovary and in the young ova of the rabbit. Bobretzky in the ovum of gasteropodes. Balbiani in the ovary of the larvæ of the orthoptera. Eberth in the normal and regenerating epithelium

and in the Descemet's endothelium of the cornea of the rabbit and pig, and in the branched corpuscles of the inflamed cornea. Grobben in the seminal cells of astreus. Selenka in the ovum of toxopneustes variegatus. Schleicher in the cartilage cells. Peremeschko in the epithelial and connective-tissue cells and in the blood corpuscles of the embryo newt. Flemming in a great variety of cells of the embryo salamander, as epithelial and connective-tissue cells, in the nuclei of blood corpuscles, and of nerve fibres, in the sperm cells of the adult salamander, and in vegetable cells. I myself described it in the epidermis of the adult newt, in the epithelium of the bladder of the frog, and in the epithelium of the tail of the tadpole. Perez saw it in the ovum of helix aspera. Bergh in the ovum of cœlenterata. J. Arnold in morbid growths, as sarcomata and carcinomata. Mark in the ovum of limax. Jakimovitsch in the unstriped muscle cells of the stomach of amphibia and mammals.

The most extensive observations in the vertebrates are those by Mayzel and Flemming. The treatises of this latter observer on the subject of the indirect division of nuclei, are those which I consider the most thorough and exhaustive, they are very copiously and beautifully illustrated and are published in the 'Archiv f. Mikrosk. Anatomie,' vol. xvi. p. 302, and in the same Archiv, vol. xviii. p. 151.

As regards the indirect division of the nuclei in the cells of the vegetable kingdom, Strassburger was the first who observed it here, and together with Bütschli is indeed the first who at all noticed and described it; in his admirable book above quoted he has treated this subject very thoroughly.

I shall describe in the following the indirect division observed by myself in the nuclei of the epithelial cells of the skin of the tadpole, of the skin and bladder of the adult newt, in those of the epithelium and endothelium of the cornea of the newt, frog and toad; in the nuclei of the endothelium of the mesentery of the newt, in those of the epidermis of the sheep, and in those of the seminal epithelium of the mammalian testis. In all these instances I find my observations coincide in the more essential points with the description given by Flemming.

On Plate XLVIII. I have illustrated the most important stages in this indirect division.

With Flemming we may speak of the whole process as of the Karyokinesis, since a spontaneous movement of the nucleus and of its parts is of great importance and indeed is essential for the whole process of the indirect division. Such movement has been directly observed in the vertebrates by Mayzel, Schleicher, Flemming, and Peremeschko.

The nuclei of the epithelium of the bladder of the newt are very typical for those of

epithelial cells, and being very large afford a good opportunity for observing their structure and changes during the karyokinesis.

The nucleus of the epithelial cells of the superficial layer is more or less oval, is limited by a distinct membrane, and contains amongst a mass of minute fibrils, which are convoluted and connected into a network, several larger irregular or spherical or oval or curved corpuscles, which always stain much readier in dyes than the other fibrils and are much coarser; they are intimately connected with the latter and appear generally merely as thickenings of them. They correspond to the nucleoli.

The cell substance is a mass of minute fibrils, either much convoluted and loop-like, or connected into a reticulum. They stand in a direct connection with the fine fibrils of the nucleus, with which they are identical in appearance and arrangement.

Both in the intracellular and intranuclear fibrils are seen minute bright dots, they are merely fibrils seen endwise, i.e. in optical section.

The nucleus of the cells of the deep layer is a little larger than the former, and similar in structure except that many of them possess no nucleoli. Such a nucleus will be spoken of as a ripe resting nucleus.

The first step towards the karyokinesis consists in the disappearance of the nuclear membrane, in the greater distinctness and thickness of the intranuclear fibrils; they at the same time stain more readily in dyes. The fibrils become more separated from one another, hence they are more distinct and the nucleus as a whole is larger. Of nucleoli there is generally nothing to be seen.

Owing to these facts, the convoluted nature of the intranuclear fibrils is now much more distinct than previously in the resting nucleus, but it existed already in the latter, as mentioned above. But there is now much less of an anastomosis i.e. of a network of the fibrils noticeable.

This phase is the phase of the 'convolution' *par excellence.*

The fibrils may be uniformly distributed or they may have a more or less transverse arrangement, especially in the peripheral part of the nucleus. And if in this case the latter is of an oblong shape, it obtains a peculiar ribbed appearance.

In the next phase the fibrils become thicker and more separated from one another, i.e. more loosely aggregated, so that this makes the nucleus still larger. The fibrils are still much convoluted, but there is already a distinct indication of their forming long loops, whose individual members are very wavy and coiled. Some of the fibrils are not of a uniform thickness and appearance, but at some places appear as if there were two thinner fibrils running closely side by side, or as if a thick fibril were hollowed out, i.e. tubular. These will be spoken of as the 'double threads' observed by Flemming in this and later phases, and considered by him as due to a longitudinal division of the

threads. But even with good high powers, $\frac{1}{12}$ and $\frac{1}{18}$ oil immersion of Zeiss, $\frac{1}{12}$ and $\frac{1}{16}$ oil immersion of Powel and Lealand, $\frac{1}{25}$ water immersion of Powel and Lealand, L water immersion of Zeiss and good illumination (Abbé's or Powel and Lealand's condenser), I am not able to definitely settle whether the 'Double threads' are really two separate fibrils or one hollow tubular fibril.

They are 1892

In the next phase the separation into loops is still more distinct and uniform; but the loops are very long and not simple, one and the same thread contributing to form a number of them.

The arrangement of the loops resembles now a 'wreath' or 'rosette.' One thread having formed a loop in the centre, turns radially towards the periphery, forms here again a loop, and returns radially towards the centre, here forms again a loop, &c.

The nuclei of this phase are also larger than in the previous one, and their size in some instances is little less than that of the cell itself, the outlines of both being then close together. In this phase it is noticed that the fibrils are very thick or very thin; and in the latter case they appear either as double threads or not. In most cases the fibrils forming the wreath are compressed into a relatively thin plane; the nucleus, or what corresponds to it, does not now form any more a spherical or oval body, but is greatly flattened. When seen from the surface the arrangement of the threads as a wreath is very distinct, but when viewed in profile it appears of course altogether different.

This condition corresponds to the form which is called by Strassburger nuclear plate (Kernplatte), and by Flemming Æquatorial plate (Aequatorialplatte).

In the next phase the threads appear separated into single open loops; the bend of the loops are situated in the centre of the nucleus, while the ends of their limbs are directed towards the periphery. Thus a distinct star-shaped figure is produced, the Monaster. Different monasters vary in the length and thickness of the limbs of the loops. In some instances all loops consist of double threads, in others the threads appear very thick and short. The threads of the monaster are generally compressed into a relatively thin plane, the nuclear plate.

In those kinds of cells which I have examined, I am inclined to think that this form of the monaster is much rarer than I first thought, and as also Flemming assumes, the phase of the wreath in many instances changing at once into the one to be described next.

In the wreath, as mentioned above, the threads form loops in the centre and at the periphery, but they are all compressed into the nuclear plate. We have now to imagine that the single centre separates into two, one above the other, that is to say, the loops previously all contained in a single plane and radiating towards a single centre now separate as it were into two groups, one above the other; in each group the loops

radiate towards the centre, but their members still remain connected at the periphery. This separation proceeds gradually so far that instead of a flat wreath, as previously, we obtain a large oval or spherical form, at each of the two poles of which the threads form single loops, but in the equator of this form the threads of the two hemispheres pass into each other. A form of this phase is naturally much larger in bulk than many of the previous ones.

Gradually the connection of the threads is severed in the equator, first in the peripheral parts, then also in the centre, and we obtain then two separate stars or the Dyaster. In those cases in which the wreath changes into a monaster, the loops of this latter, compressed into the nuclear plate, also gradually separate into two planes, and they become further apart, until a form is reached which is similar to the above Dyaster, viz. a spherical or oval form with two poles, each of which forms the centre for its own group of loops, but the threads of the two hemispheres are not continuous with one another. In many of them double threads are still noticeable. In some of the Dyasters the threads are very much shorter and thicker than in others.

The most interesting forms of Dyasters are those in which the threads in each of the two hemispheres assume a peripheral, i.e. meridional, situation, so that each of the latter has now the shape of a basket, and consequently the Dyaster that of a double basket. The two baskets touch at their opening, while the bottom of each of the two baskets corresponds to one of the poles of the Dyaster.

Generally in the phase of the Dyaster, either during, or shortly after the severance of the two daughter stars, the cell itself becomes constricted in a line which, when completed, passes right across between the two daughter stars.

In the newt there exists this exceptional condition, that neither during the phase of the nuclear plate, i.e. the wreath and Monaster, nor before or after, is there any sign of what in other animals, invertebrate and vertebrate ones, and in plants, is known as the 'nuclear spindle' of Bütschli, i.e. an elongated spindle-shaped body longitudinally and finely striated and possessed of more or less pointed poles. This spindle makes its first appearance in the phase of the wreath, and it bears a very intimate relation to the threads forming the wreath, inasmuch as this latter, forming the nuclear plate, occupies the equator of the spindle, hence Flemming terms it the equatorial plate. As the wreath and the Monaster pass into the phase of the Dyaster, the looped threads of the former rise along the fibrils of the spindle, using them, as it were, as guide and support on their migration from the equator of the latter to its poles. The daughter stars of the Dyaster are thus ultimately situated one at each pole of the spindle. The division of the cell itself necessitates also a division of the threads of the spindle in the equator. The spindle has been observed by almost all observers, in the

division of the nucleus of the ovum and of other cells in invertebrates, in that of the frog and mammals, and especially in plants, but not in the newt. Flemming saw them also in the salamander.

In many instances the fibrils of the cell substance, during the stage of the wreath and monaster, appear as if radiating towards the latter. In those cases in which the spindle occurs, the poles of this latter are each connected with a system of radiating fibrils. In the segmenting ova of invertebrates such a radiating system of cell fibrils has been known through many observers since many years. Fol first noticed two such radiating systems, or 'suns,' of cell fibrils, and Auerbach brought these suns in connection with the division of the nucleus; according to him this latter is the connecting link between the two suns, and he called the whole the 'karyolitic figure,' thinking that each of the two suns indicates the direction in which the nuclear juice becomes fused into the cell substance. Bütschli, Strassburger, and Mayzel very minutely described them. There can be no doubt that these systems of radiating fibrils of the cell substance are continuous with the fibrils of the spindle, and hence, I think with Strassburger, that this latter, i.e. the spindle, is, properly speaking, a part of the cell substance. Flemming, however, considers it as part of the nucleus, viz. the part which does not stain with dyes; he calls it the achromatin, as distinct from the chromatin, i.e. the fibrils above described as forming the 'convolution' wreath, star, and double star.

Each of the daughter stars of the Dyaster, or rather single baskets of the double basket, undergoes the following changes: the loops of threads, which, by the way be it mentioned, are relatively thick, become arranged alternately, so that the appearance of a transversely ribbed oval or spherical corpuscle is produced; then the threads become gradually convoluted; then they form anastomoses; each daughter nucleus now resembles a 'convolution' as described as the first phase of the mother nucleus. Of course such daughter nuclei are easily distinguished from a mother nucleus by their small size and by being in couples.

After this each daughter nucleus gradually enlarges, and its fibrils become separated by a membrane from the cell substance. The intranuclear fibrils become gradually paler, less liable to take to staining, and in connection with them are seen two, three, or more large masses, the same as the nucleoli mentioned at the commencement of this chapter.

But in some also these nucleoli disappear and the daughter nuclei cannot then be distinguished from their neighbours, neither in size, aspect or structure.

REESE LIBRARY
OF THE
UNIVERSITY
OF
CALIFORNIA

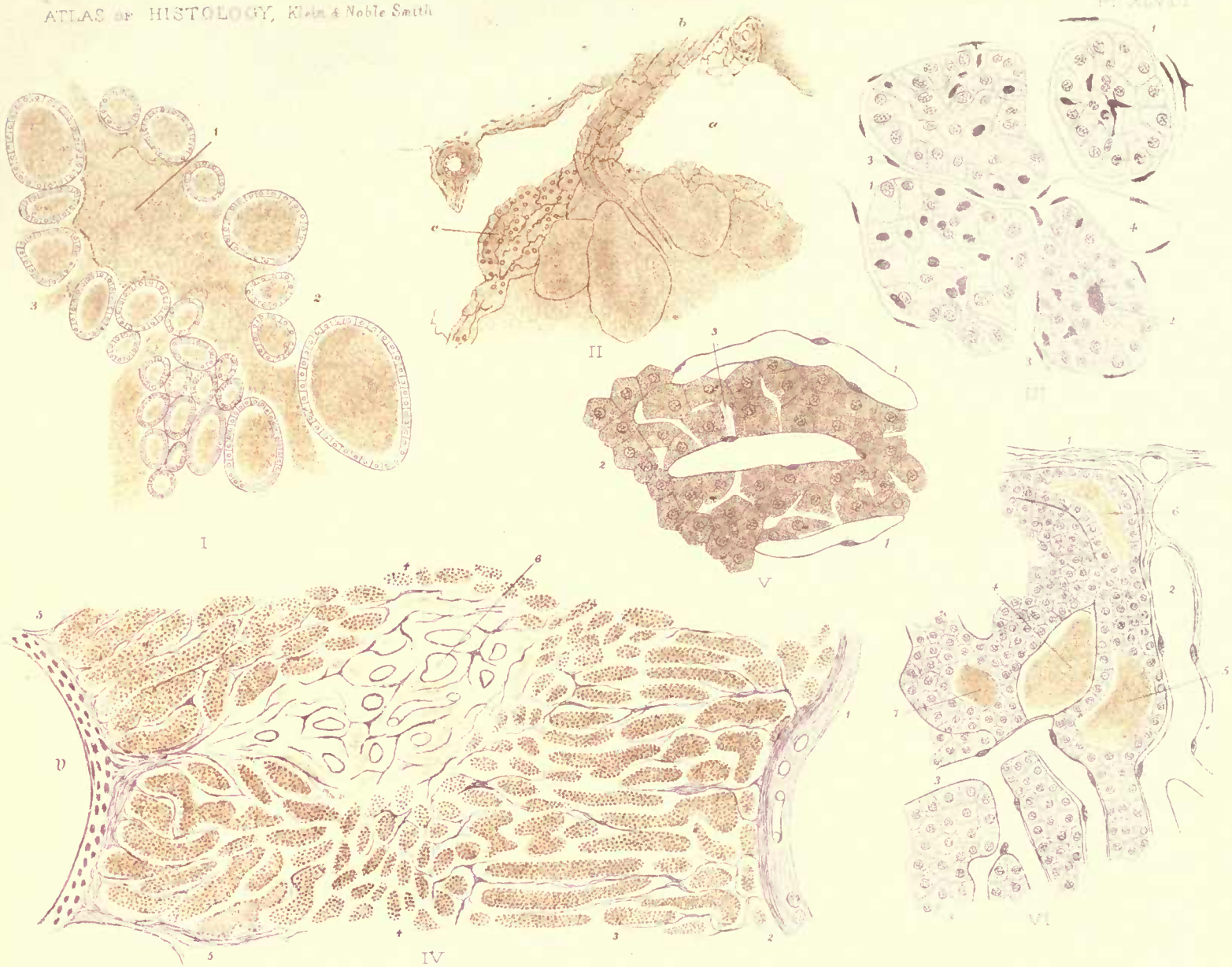

I II III V VI IV

a b c d e f g h i k l

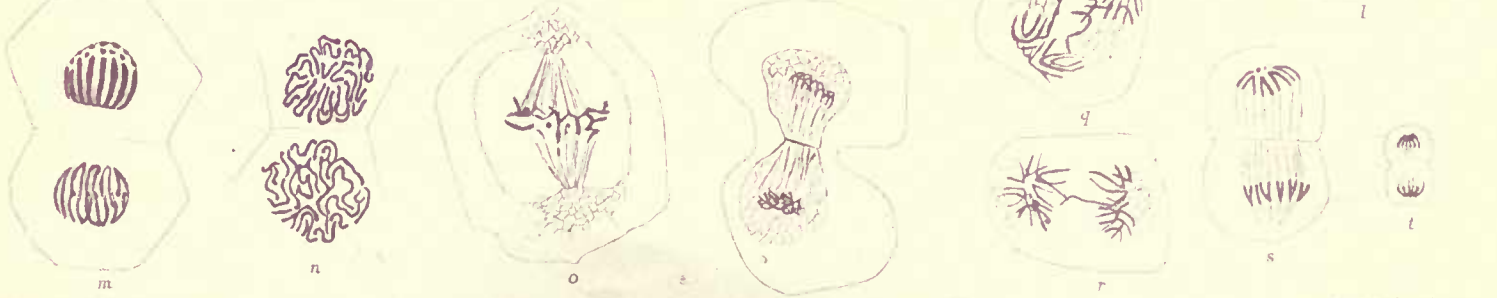

m n o p q r s t

PLATE XLVIII.

Fig. I. From a section through the thyroid gland of the dog.

The section had been prepared by Mr. Creswell Baker. Magnifying power about 150.

1. A lymphatic vessel filled with the same homogeneous viscid material as the alveoli.

2. The alveoli or vesicles are lined with a single layer of polyhedral nucleated cells, the cavities of the alveoli are much distended.

3. Lymph-sinuses around the alveoli, the interalveolar lymphatics.

Fig. II. Copied from Mr. Creswell Baber, 'Philosophical Transactions,' 1876, II. Plate 47, fig. 5.

From a transverse section of the dog's thyroid gland; the lymphatics had been injected with nitrate of silver. Magnifying power about 90.

a. Interior of a large lymphatic cut across.

Running across its cavity is seen an artery (*b*) which is surrounded by the endothelial wall of the lymphatic. This endothelial layer is also seen investing the outer surface of the neighbouring vesicles. The nuclei of their lining epithelium are represented at (*c*) only.

Fig. III. From a section through the frontal lobe of the human hypophysis cerebri. Magnifying power about 300.

1. Alveoli in section. They are lined with large more or less columnar epithelial cells. Between these are smaller cells with small and deeply stained nuclei.

2. Homogeneous gelatinous substance contained in a central cavity of an alveolus.

3. Endothelial membranes between the alveoli.

4. A venous capillary in transverse section.

Fig. IV. From a transverse section through the human suprarenal body. Magnifying power about 45.

1. The outer capsule.

Part of a section of a large vein of the centre; around it are numerous bundles of unstriped muscle cells in transverse section, i.e. running parallel to the long axis of the vein.

2. The cell masses of the outer zone of the cortex.

3. The cell streaks of the zona fasciculata.

4. The inner zone of the cortex.

5. Cell streaks similar to those of the zona fasciculata, but shorter, and grouped as lobules.

6. Medulla with large capillary veins.

Fig. V. From a section through the zona fasciculata of the suprarenal body of the dog. Magnifying power about 350.

1. Capillary blood-vessels.

2. The streaks composed of polyhedral epithelial cells. The intercellular lymph spaces are well shown at 3.

Fig. VI. From a transverse section through the outer part of the cortex of the suprarenal body of a new-born child. Magnifying power about 300.

1. The outer capsule.

2. A minute vein.

3. Capillary blood-vessel.

4. Homogeneous gelatinous material contained in a lymph space between the cell groups.

5, 6. The same material contained in a space within the cell groups. The two spaces in which they lie appear as if belonging to a canal twice cut; the limiting small polyhedral cell would in this case form in reality a tubular structure, whose cavity is shown at 5 and 6.

7. The same material contained in a space which looks like the lumen of a tubular alveolus cut transversely.

8. The polyhedral cells of the zona fasciculata.

The remainder of this Plate illustrates the process of indirect division, or the Karyokinesis (Flemming).

All figures have been drawn with Zeiss's $\frac{1}{12}$ oil immersion.

a. A nucleus of the superficial layer of the epithelium lining the mucous membrane of the urinary bladder of the newt.

The nucleus contains numerous fine fibrils in convolution, and connected as a reticulum. Several large looplike or irregularly shaped thickenings, nucleoli.

b. An epithelial cell of the deep layer.

The intracellular fibrils are very distinct; like those in the nucleus with which they are directly continuous, they are much convoluted and also connected in a network.

c. The first phase; in it the fibrils of the nucleus are much thicker and uniformly arranged as a 'convolution.'

No limiting membrane of the nucleus is visible.

d. In this next phase the nucleus has become much enlarged, the fibrils being still convoluted; some of these are much thicker than others; some appear as 'double threads' (see Text).

e. The fibrils form distinct loops arranged as if radiating towards a centre, like a wreath; this is the stage of the wreath or rosette.

The fibrils form also loops at the periphery.

f. A later phase; the loops are separated into two layers; in each they radiate towards a separate centre. In the drawing this is not well shown.

The fibrils of the nucleus of the preceding figures, as well as those of the present one, are compressed into a relatively thin plane, thus forming what is called the 'nuclear plate,' or the 'equatorial plate.'

The fibres are almost all double-threads. The nucleus is much larger than in the previous stage.

g. A later stage, or the stage of the Dyaster. The nucleus is larger than before.

The loops are distinctly separated into two stars. The loops of the two stars are already severed in the central part, but are still connected in the periphery.

h. The severance of the loops belonging to the two daughter stars is complete. Some of the threads are double-threads. The cell outline in this and all the following figures is only indicated.

i. Profile view of a Dyaster, in which the threads of the daughter stars are pressed against one another; this is a stage immediately following the stage of the nuclear plate, i.e. when the two stars begin to move away from one another.

k. The two stars of the Dyaster have completely separated. Each is still composed of separate loops.

l. The daughter stars have changed, the loops of each having become alternating. The cell itself exceptionally shows here no indication yet of division.

m. Two daughter nuclei, the cell has already divided. The loops of the nuclei are still recognisable.

n. A further stage in which the threads of the daughter nuclei are arranged as the 'convolution.'

The next stage would be this, in which each of the daughter nuclei presents the same appearances as the nucleus figured in *a*.

o. An endothelial cell of the membrana Decemeti of the frog (Rana esculenta), drawn from a preparation of Dr. Mayzel of the University of Warsova.

The nucleus is in the phase of the equatorial plate, in which the original threads are compressed into a thin stratum, seen here in profile. From this equatorial plate fine threads apparently radiate towards two opposite poles, thus forming what is called the nuclear spindle. From the poles of the spindle numbers of fine fibrils are seen radiating; they belong to the intracellular network.

p. From a similar preparation of Dr. Mayzel, representing a further stage than in the previous figure. The threads of the former equatorial plate have moved from the equator towards the poles; they now form a Dyaster, in which the two stars are separated from one another. If viewed from the surface, the radiating arrangement of the loops would be as well seen as in *k*.

In the dividing nuclei of the epithelium of the bladder of the newt nothing is seen that would correspond to the spindle of *o* and *p*.

In *p* the cell itself has commenced to divide.

q, *r*, and *s* are obtained from the epithelium of the bladder of the common frog, showing the stars of the Dyaster separated partially (*q*, *r*) or wholly (*s*). In *s* the spindle is well shown, and the loops of the upper aster have already reached the upper pole; those of the lower aster are near, but not quite at the lower pole.

The cell is on the point of dividing; so is also the spindle itself.

t. A similar dividing cell and nucleus of the deep layer of the stratum Malpighii of the skin of the sheep. The identity in the appearance is very striking, but the nucleus is much smaller.

LONDON: PRINTED BY
SPOTTISWOODE AND CO., NEW-STREET SQUARE
AND PARLIAMENT STREET

ATLAS
OF
HISTOLOGY.

BY

E. KLEIN, M.D., F.R.S.
LECTURER ON HISTOLOGY AT ST. BARTHOLOMEW'S HOSPITAL MEDICAL SCHOOL;

AND

E. NOBLE SMITH, L.R.C.P., M.R.C.S.
FORMERLY SENIOR HOUSE-SURGEON TO ST. MARY'S HOSPITAL.

THE ILLUSTRATIONS BY MR. NOBLE SMITH, FROM PREPARATIONS BY DR. KLEIN; THE TEXT BY DR. KLEIN.

Royal 4to. containing 48 *Coloured Plates, bound in Half-leather, price* £4. 4*s.*; *or, in* 13 *Parts, price* 6*s. each.*

OPINIONS OF THE PRESS.

MEDICAL TIMES AND GAZETTE, March 15, 1879.

'The work, of which the first instalment now lies before us, is one which promises to be not only a work of art, but one of exceeding usefulness. It will constitute a sort of standard of excellence up to which men may endeavour to work to surpass if they can, but, at all events, indicating a point which they should eagerly and industriously try to reach.'

JOURNAL OF ANATOMY AND PHYSIOLOGY, April, 1879.

'This is the most handsome and best work on the subject which has yet appeared in this country. . . . . The illustrations are excellent, and do great credit to the skill and accuracy of the authors, and to the artistic powers of Mr. E. Noble Smith, by whom they were drawn and executed. The text is clear without needless verbosity, and comprises, besides the explanations of the illustrations themselves, a good deal of other matter, and, indeed, forms an excellent treatise on Histology.'

THE BRITISH MEDICAL JOURNAL, April 5, 1879.

'This is one of the most creditable and valuable books which has for many years been issued in this country. It is a thoroughly admirable and perfect work, indicating much technical skill and profound knowledge.

'The illustrations are of very high order of merit, in respect alike of fidelity, of

---

London: SMITH, ELDER, & CO., 15 Waterloo Place.

clearness, and of artistic beauty. The two parts of the Atlas now before us give sure promise of a work on Histology such as no other country yet possesses, and which may be considered absolutely necessary to every student of the inanimate structure of the tissues.'

LANCET, April 26, 1879.

'We are much pleased with these plates. They give very faithful delineations of the objects described in the text, and they are not overcharged. They should be on the table of every practitioner who desires to make himself familiar with the progress of Histology.'

DUBLIN JOURNAL OF MEDICAL SCIENCE, June, 1879.

'In the parts before us we have a first instalment of a work which promises, as far as illustration goes, to be the most magnificent systematic work on animal Histology which exists in any language.'

. . . . . .

'Both as regards the faithfulness with which the objects are delineated, and the artistic beauty of the execution, we can speak of them only in terms of the highest praise. . . . . The work is one of great originality.'

MEDICAL PRESS, August 13, 1879.

'Judging from the first three numbers, this work promises to be of the greatest interest and value. Its purpose is to give a representation and a description of the tissues of man and other vertebrates as they are understood in the present day; and if the later numbers sustain the high standard of those already published, this purpose will be most satisfactorily accomplished. As regards the illustrations, Mr. Noble Smith must be congratulated on his great skill in delineation; the plates appear both graphic and truthful. . . . . The work appears to be one which is likely to occupy a very important place amongst our English text-books, and is one which is highly creditable to those concerned in its "production."'

BRITISH MEDICAL JOURNAL, Oct. 4, 1879.

'This admirably executed Atlas is rapidly progressing to a conclusion, ... it has throughout maintained the high promise with which it started, and fulfils all that could be expected from the joint work of our best histologist and the most accomplished of British medical draughtsmen. The illustrations of the last two parts, especially devoted to the display and brief description of the intimate structure of the nervous centres and nerve ganglia; are admirable for the perfection and beauty of the sections and the choice of specimens, as they are for the delicate skill and intimate knowledge of the draughtsman. The text is only too short, for it is full of accurate, recent, and lucid information. It is long since any work of more entirely satisfactory conception and execution has issued from the English medical press. This is very high praise; but the rare merits of this standard production deserve no less.'

EDINBURGH MEDICAL JOURNAL.

'Of the greatest value . . . . . the illustrations betoken high artistic skill, as well as the accuracy of perception necessary for the delineation of objects histologically,' &c. . . . . .

London: SMITH, ELDER, & CO., 15 Waterloo Place.

NOV 22 1948

UNIVERSITY OF CALIFORNIA LIBRARY
BERKELEY

Return to desk from which borrowed.
This book is DUE on the last date stamped below.

Biology Library

NOV 20 1950
DEC 2 1953
De2'58TD
JUL 6 1959
JL1'59MS
APR 6 1961
31 Mr'61GC

LD 21-100m-11,'49(B7146s16)476

U.C. BERKELEY LIBRARIES
C039320103

20357 fQM551 K59

BIOLOGY
LIBRARY
G

THE UNIVERSITY OF CALIFORNIA LIBRARY